

# THE BRITISH JOURNAL OF OPHTHALMOLOGY

JULY, 1950

---

---

## COMMUNICATIONS

### FURTHER CASES OF A FUNDUS DYSTROPHY WITH UNUSUAL FEATURES \*

BY

R. A. BURN

*Assistant to the Ophthalmological Research Unit, Royal College of  
Surgeons and Royal Eye Hospital*

RECENTLY Sorsby and Mason (1949) described an unusual fundus dystrophy. The outstanding features were a bilateral central lesion of late onset and clearly genetic origin, with oedema, haemorrhages and exudates in the early stages, developing into generalized choroidal atrophy. The disease first came on in the early forties with a defect of central vision which intensified and spread to the periphery, though only in the most advanced cases did total blindness ensue. The genetic nature and dominant heredity of the lesion were shown by evidence of direct transmission over four generations.

The present report of a further family group, clearly belonging to the same clinical entity, serves to confirm and amplify the earlier description.

---

\* Received for publication February 20, 1950.

### Case Reports

Forty-four members of the family were examined and of these seven were found to be affected. Four more, now dead, were probably affected according to the evidence of several of their relatives. The significant findings concerning these affected individuals are summarized below and the available information about all those shown in the pedigree is given in the Appendix.

#### Living Members Found Affected

(1) *Mrs. Hy (III, 5 in pedigree), aged 68.*—Her left eye began to fail gradually between the ages of 40 and 45, the right followed between 45 and 50. Central vision failed rapidly. When examined her visual acuity was less than 6/60 in each eye, though her peripheral vision was good and she was able to move about freely. Her fundi are illustrated in Fig. 6 (a) and (b). The outstanding features are central scarring with masses of pigment, marked choroidal sclerosis spreading outwards from the centre, and a zone of relatively normal retina at the periphery. The disk is not atrophic, and the vessels, except where they supply the scarred central area, are not attenuated.

(2) *Mrs. Hd (III, 7 in pedigree), aged 63.*—Both eyes began to fail together at the age of 48. Central vision failed rapidly. When seen she was unable to read the largest type on the Jaeger reading chart, but her peripheral vision was good and she could get about her house easily. Her fundi, illustrated in Fig. 5 (a) and (b), were essentially the same as Mrs. Hy's.

(3) *Mrs. A. (III, 8 in pedigree), aged 57.*—Her left eye failed suddenly overnight, when she was 49; the right eye did the same at the age of 53. She says she was examined by an ophthalmic surgeon at that time, who found a macular haemorrhage in the right eye. Deterioration was rapid and when seen she had visual acuity of less than 3/60 in each eye and was registered blind. Nevertheless her peripheral vision was good and she could go about. The ophthalmoscopic appearances are illustrated in Fig. 4 (a) and (b). The lesion is rather less advanced than those of her sisters, and is seen to consist of three zones: a central scarred area, a zone of choroidal sclerosis spreading outwards, and a zone of relatively normal retina with some patterned exudates ahead of it.

(4) *Alfred B. (III, 10 in pedigree), aged 69.*—Both eyes began to fail at the age of 49 with black spots, photopsiae, and a central blur. Central vision failed quickly and he had to give up his work as a delivery-man within 4 years. When seen his visual acuity was less than 3/60 in each eye and he was registered blind, though his peripheral vision was good and he could move about freely. His fundi are shown in Fig. 7 (a) and (b). There is very extensive choroidal atrophy and sclerosis, but a narrow zone, less severely affected, persists at the periphery.

(5) *Edward B. (III, 13 in pedigree), aged 56.*—A central blur developed in both eyes together at the age of 51. When seen at the age of 56 his visual acuity was less than 3/60 in each eye and he was registered blind, but his peripheral vision was good enough to allow him to get about and do some work. His fundi (Fig. 3 (a) and (b)) showed a fairly early stage of the lesion with a considerable amount of normal peripheral retina and choroid.

(6) *Henry B. (III, 17 in pedigree), aged 48 (Proband).*—A shadow developed suddenly before both eyes at the age of 48, when he was first seen. He had to "look through it". Central vision was 6/9 part in the right eye and 6/12 in the left. Peripheral vision was unaffected. His fundi are illustrated in Fig. 1 (a) and (b). They represent the earliest stage observed in this family. The left eye shows only fine pigmentary mottling and white dots in the central area. In the right there is also some grayish oedema of the retina. No haemorrhages or massive exudates were seen. When he was re-examined after two years the fundi appeared unchanged and the visual acuity was the same. He complained, however, that the shadow was getting worse.

(7) *Harry Br (IV, 4 in pedigree), aged 52.*—A nephew of Mrs. Hy's and the only member of the younger generation affected so far. His right eye failed

suddenly with a central blur at the age of 49, and the left quickly followed it. Within three years he was unable to read even very large type, and this was his condition when seen. His peripheral vision was good and he could get about well. His fundi, illustrated in Fig. 2 (a) and (b), show the lesion still localized to the central area.

#### Deceased Members Reputed Affected

According to several of their children, George B. (II, 1), Frederick B. (II, 2), and Mrs. Br (III, 1) were all "blind" before they died, from a central defect allowing them to get about easily, which came on between the ages of 40 and 50. All three were parents of affected children and there can be no doubt they were affected themselves.

According to her son, Mrs. L. (II, 4) died at about the age of 70, having been blind for 25 years from a disease which came on suddenly in both eyes together. It is probable that she was affected also.

### Survey of Findings

#### Clinical Features.

*Age of Onset.*—In almost all the living affected members the trouble began between the ages of 45 and 55. The only exception was the left eye of Mrs. Hy which, she thinks, began to give trouble when she was between 40 and 45.

In the case of the deceased members reputed to have been affected the age of onset appears to have been between 40 and 50.

*Mode of Onset.*—In three cases this was described as sudden (Mrs. A. III, 8; Henry B. III, 17; and Harry Br IV, 4); in the others it was more gradual. The defect was central from the start, a central blur or "shadow", black spots or photopsiae being the usual complaint.

*Course.*—Failure of central vision was rapid in all cases and the four in which the times could be accurately established had central blindness within five years (Mrs. A. III, 8; Alfred B. III, 10; Edward B. III, 13; and Harry Br IV, 4). Peripheral vision, on the other hand, was not lost in any case. Even those certified blind were able to get about easily. No patient complained of night blindness.

*Ophthalmoscopic Appearances.*—The range of appearances in the living affected members is shown in the illustrations, which are arranged in order of age from the youngest, Fig. 1, to the oldest, Fig. 7.

The development of the lesion can be clearly seen. In the earliest stage observed (Fig. 1 (a) and (b)) the lesion involves the central area only with fine pigmentary mottling, white dots, and some oedema (Fig. 1 (a)). The macula becomes converted into a white scar with masses of pigment (Fig. 2 (a) and (b)) and the lesion spreads outwards with "unmasking" of the choroidal vessels and choroidal sclerosis preceded by fine patterned exudates (Fig. 4 (a) and (b)). The end stage is one of extensive choroidal

atrophy and sclerosis with massive pigment deposits, leaving always, in the cases here illustrated, a narrow peripheral zone of retina fit to function (Fig. 7 (a) and (b)). The disks do not become atrophic and the vessels remain of normal calibre except where they supply grossly atrophic retina.

#### Genetic Behaviour.

*Direct Transmission.*—This is shown over three generations. Affected individuals have been observed in two. Information as to whether either of the individuals in Generation I was affected is inconclusive. There is a family rumour of affected sibs on one side or the other in this generation who had affected descendants but it was not possible to trace them.

In no case was an affected individual known to have normal parents.

*Proportion of Affected to Normal Sibs.*—The significant data are summarized in the following Table.

TABLE  
*Individuals reaching the Age of 40, Offspring of Affected Parents*

Generation	Unaffected			Affected		
	M.	F.	Total	M.	F.	Total
II ... ..	2	1	3	2	1	3
III ... ..	3	5	8	3	4	7
IV ... ..	2	6	8	1	-	1
Total ... ..	7	12	19	6	5	11

If the offspring of affected parents who have reached the age of 40 are taken, assuming that one of the parents in Generation I was affected, the proportion is 11:19, considerably lower than the 1:1 expected in a dominant affection. As has been seen, however, the age of onset in this family is nearer 50 than 40, so that genetically affected individuals in Generation IV may not have developed the lesion yet. If Generation II and III only are taken the proportion is 10:11, almost exactly the expected figure.

*Sex Incidence.*—Of the affected individuals, six were men and five women. Amongst the normal members of the family the proportion is 44:51.

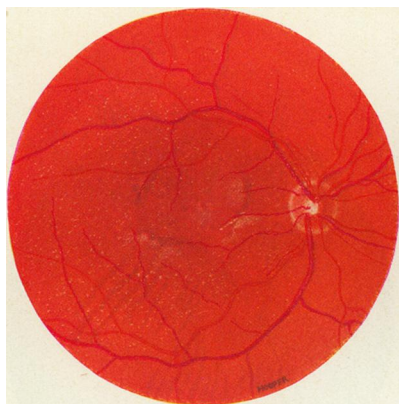


FIG. 1(a).—Henry B. (III, 17), aged 48, right eye.

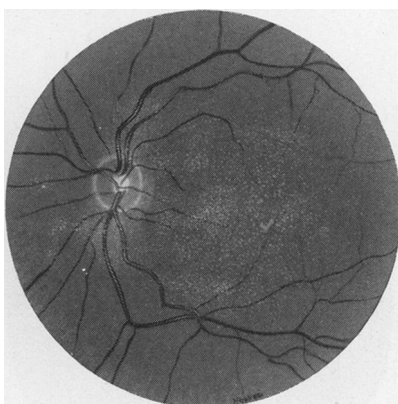


FIG. 1(b).—Henry B. (III, 17), aged 48, left eye.

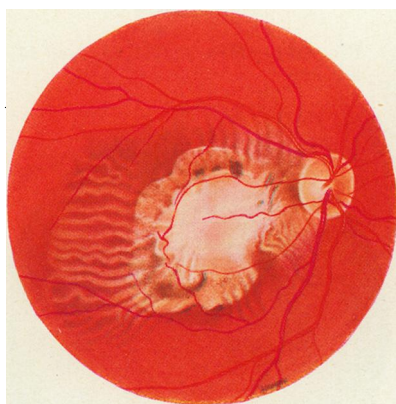


FIG. 2(a).—Harry Br (IV, 4), aged 52, right eye.

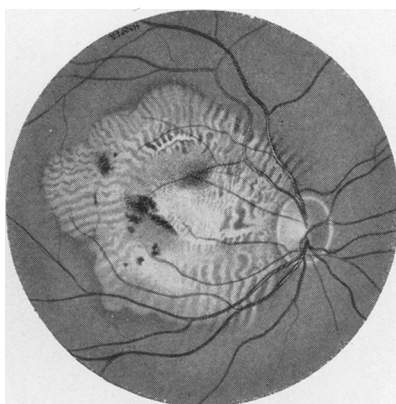


FIG. 2(b).—Harry Br (IV, 4), aged 52, left eye.

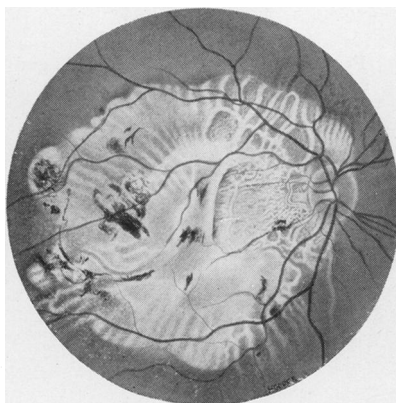


FIG. 3(a).—Edward B. (III, 13), aged 56, right eye.

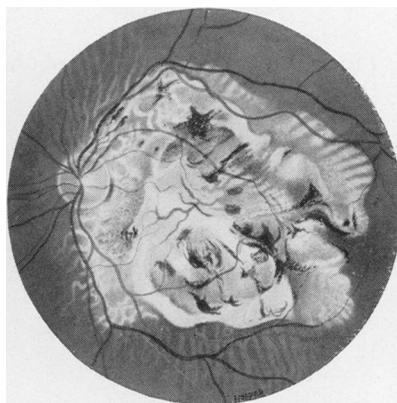


FIG. 3(b).—Edward B. (III, 13), aged 56, left eye.

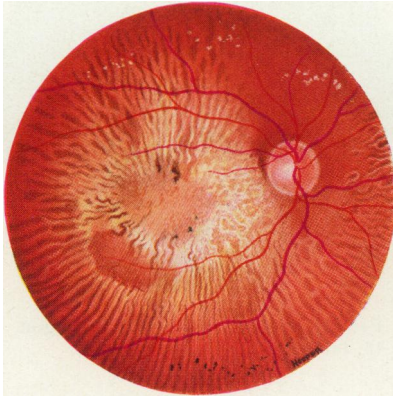


FIG. 4(a).—Mrs. A. (III, 8), aged 57, right eye.

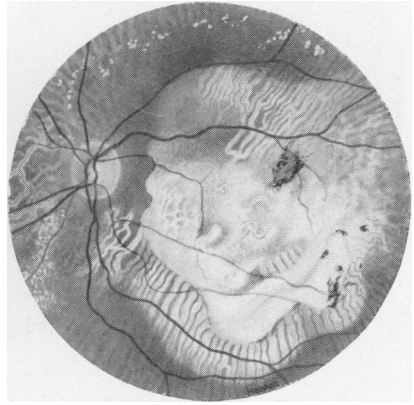


FIG 4(b).—Mrs. A. (III, 8), aged 57, left eye.

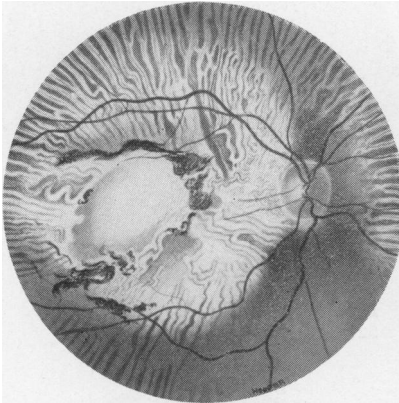


FIG. 5(a).—Mrs. Hd (III, 7), aged 63, right eye.

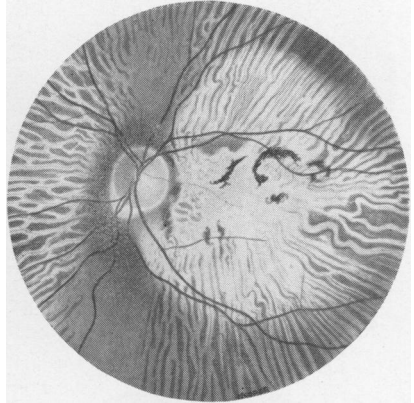


FIG. 5(b).—Mrs. Hd (III, 7), aged 63, left eye.

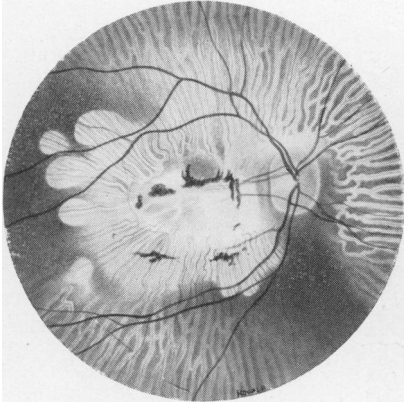


FIG. 6(a).—Mrs. Hy (III, 5), aged 68, right eye.

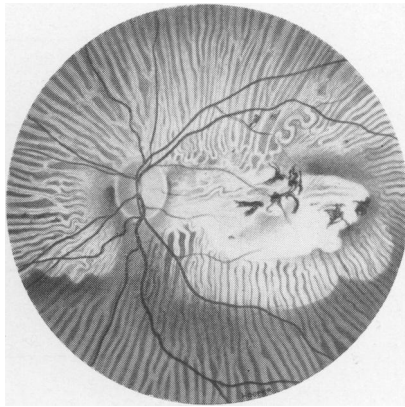


FIG. 6(b).—Mrs. Hy (III, 5), aged 68, left eye.

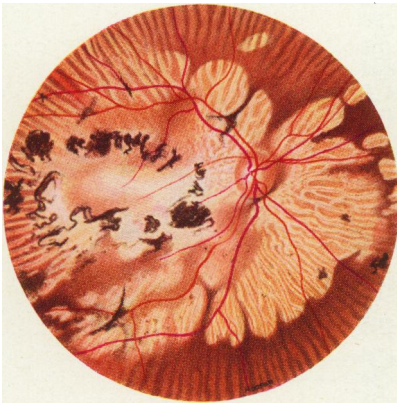


FIG. 7(a).—Alfred B (III, 10), aged 69, right eye.

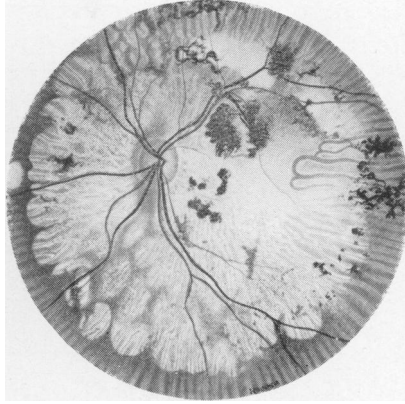


FIG. 7(b).—Alfred B. (III, 10) aged 69, left eye.





*Consanguinity.*—None of the affected individuals is the offspring of a consanguineous marriage.

The genetic behaviour, in fact, corresponds well with that of an autosomal dominant gene.

The clinical and genetic characteristics in this family then, can be summarized as follows: *a central fundus lesion coming on in the late forties, of genetic origin and dominant transmission, progressing to central blindness but leaving peripheral vision free up to an advanced stage.*

### Discussion

#### Comparison with the Cases of Sorsby and Mason.

No important differences exist. Certain minor variations may be mentioned.

*Age of Onset.*—In the earlier recorded cases this was more often in the late thirties or early forties than the late forties. The difference is not significant and only indicates that each family may have its own characteristic age of onset around which individuals vary.

*Choroidal Sclerosis.*—This feature is marked in all stages of the present family except the earliest (Henry B., Fig. 1). It is also an important feature of all the more advanced cases in the earlier report.

*Haemorrhages and Exudates.*—These were observed in the early stages of several of the previously recorded cases. No massive exudates were seen in this family but Fig. 1 (b) shows some oedema and Mrs. A. (III, 8) says she was examined in the early stages and found to have a macular haemorrhage. In a lesion running a subacute course, it is not surprising that the stages observed in one family do not exactly correspond with those seen in another. Over the whole range, and even excluding the history of macular haemorrhage given by Mrs. A., the ophthalmoscopic findings correspond closely to those in the earlier report.

*Course and End Stage.*—In both series loss of central vision within approximately five years was the rule, while peripheral vision was retained much longer, in the majority of cases up to the time of death. No member of the present family has yet become so blind as to be unable to get about. Four of Sorsby's cases, however, were reduced to total blindness or perception of light only. Two of these were complicated by glaucoma and the other two had had the disease for five to ten years longer than the longest affected member of the present family.

The course and end stage is, in fact, essentially the same in the two series of cases.

*Proportion of Affected to Normal Sibs.*—In Sorsby's families the proportion of affected to unaffected is higher than in the present family. Taking individuals over 40 years old the proportion of affected to unaffected was 60:45 as against 11:19 respectively. The difference is no greater than might be expected in so small a sample, and the combined figure (72:64) is quite compatible with the expected 1:1 ratio seen in simple dominant transmission.

Taking the picture as a whole, the resemblances between the groups of cases are so striking and the differences so insignificant that they are certainly examples of the same condition.

#### **A Definite Clinical Entity.**

The characteristics of this condition, of which there are now reports in six family groups, are so clear cut and so constant that it undoubtedly constitutes a definite clinical entity, which raises the following issues.

*Frequency.*—The frequency of the condition amongst the central fundus lesions of elderly people is difficult to assess. One case, the proband of this family, has been recognized during the last year at the Royal Eye Hospital.

*Differential Diagnosis.*—Sorsby and Mason have emphasized the fact that these lesions, although of abiotrophic nature, cannot be differentiated from inflammatory or metabolic disorders on ophthalmoscopic grounds. It can be seen from the illustrations that, depending on the stage at which the lesion is seen, a number of different diagnostic problems are raised. In the early stages, for example Fig 1 (a), the lesion may resemble the acute stage of a central choroiditis of toxic or infective origin; later it resembles the end result of such a choroiditis (Fig. 4). Disciform degeneration of the macula is suggested by Fig. 2 (a) and it is possible that Fig. 1 (b) might be dismissed as a senile lesion in a somewhat older man.

*Prognosis.*—Once the diagnosis is established the prognosis both for the patient and his children is clear cut. The progressive nature of the lesion emphasized by Sorsby is borne out in the series of illustrations given here. In the great majority of cases a severe central defect, often amounting to central blindness, developed within a few years. Since, however, the initial defect is central and spreads outwards, peripheral vision is the last to go. In most cases the patient remains able to get about until he dies. Of 39 observed cases in the two series only four were reduced to perception of light or total blindness, and two of these were complicated by glaucoma. The prognosis for the patient then is that he will lose central vision in both eyes within a few years but will probably always be able to get about.

If he has children there is an even chance that any given child will be affected later in life.

*Possible Choroidal Origin.*—Ophthalmoscopically the prominence of choroidal sclerosis in all but the early cases suggests that it may be the primary lesion and that the oedema, exudates, haemorrhages, and pigmentary disturbances seen in the early stages may be due to an underlying choroidal change. The orderly peripheral spread of the lesion, well illustrated in Fig. 4 (a) and (b) where a zone of choroidal sclerosis appears to be preceded by one of exudates, points in the same direction. The absence of night-blindness and the facts, already noted, that there is no optic atrophy and that the retinal vessels are not attenuated, support the view that the condition is probably not primarily retinal.

*Theoretical Importance.*—The theoretical importance of the recognition of this condition as a clinical entity lies in the fact that it is a disease of late onset with appearances usually ascribed to affections of environmental origin, and yet is clearly genetic. It is always difficult to establish the genetic origin of diseases coming on late in life because sibships are dispersed, sibs have died, and parents are dead. The recognition of one such disease in the mass of central fundus lesions of uncertain origin seen after middle-age points to the possible existence of others.

## APPENDIX

### Case Records (Pedigree Fig. 8)

**Generation I.**—Evidence concerning this generation is based on hearsay.

*I, 1*, reputed to have normal sight.

*I, 2*, reputed to have had some eye trouble but no details known. There was an unsubstantiated report that a sister of *I, 2* named *Bn.*, living at Flaunden, was affected and transmitted the affection to her children. An effort to trace this line was unsuccessful.

### Generation II.

*II, 1. George B., senior.* Died aged 74 from a stroke. Reputed affected. He was blind but able to get about. A photograph of him as an elderly man in the possession of his daughter, *Mrs. A. (III, 8)*, supports this idea.

*II, 2. Frederick B., senior.* Died aged 79. Reputed affected. He was blind before he was 50 and from "a similar condition".

*II, 3. Mrs. Bt.* Died aged 75. Not affected. She had some eye trouble, but was able to read and was not affected with the family disease.

*II, 4. Mrs. Lt.* Died aged about 70, probably affected. According to her son, she had been blind for 25 years before she died. Both eyes became affected suddenly.

*II, 5 and 6.* Two more sons of *I, 1*. According to their niece (*III, 15*), they had normal sight.

### Generation III.

(1) *Children of George B., senior (II, 1, reputed affected).*

*III, 1. Mrs. Br.* of Chesham. Died aged 51 of stroke. Reputed affected. She was blind for three years before she died, with a central defect; she was unable to sew, but able to get about.

III, 2. *Mrs. Bs*, of Chesham. Aged 74. Was examined and found not to be affected. She is highly myopic,  $-15$  and  $-20$  D, but with glasses was able to read J4 with the right and J6 with the left eye. The fundus showed some myopic degeneration.

III, 3. *Mrs. N*. Died between the ages of 60 and 70. Reputed normal.

III, 4. *Mr. George B., junior*, of Chesham. Age 71. Was examined and found not to be affected. There is an old patch of juxtapapillary choroiditis in the right eye. The left eye was normal.

III, 5. *Mrs. Hy, senior*, of Chesham. Aged 68. Was examined and found to be affected. Her left eye was affected first between the ages of 40 and 45 and her right failed between 45 and 50. The onset was gradual. When seen, her central vision was quite gone but she was able to move about her house freely. See Fig. 6 (a) and (b).

III, 6. *Mrs. Hs*. Died at the age of about 65. Reputed normal.

III, 7. *Mrs. Hd*, of Chesham. Aged 63. Was examined and found to be affected. Started at the age of 48, both eyes more or less together. On examination her central vision was almost gone; she could not read Jaeger test types J18 but she moved about her house freely. See Fig. 5 (a) and (b).

III, 8. *Mrs. A.*, of Chesham. Aged 57. Was examined and found to be affected. Her left eye failed suddenly overnight in June, 1940, when she was 49. She was seen by an ophthalmologist in November, 1940, who found haemorrhages at the macula. Her right eye failed suddenly, again overnight, in 1944 when she was 53. When examined she had central vision of less than 3/60 in each eye and was on the Blind Register. She had a good peripheral field and moved about easily but complained much of subjective disturbances such as photopsiae and black spots, more marked on slight exertion. See Fig. 4 (a) and (b).

(2) *Children of Frederick B., senior (II, 2, reputed affected)*.

III, 9. *William B.*, of Chesham. Died aged 32 of tuberculosis. Reputed normal.

III, 10. *Alfred B.*, of Chesham. Aged 69. Examined and found to be affected. His trouble started at the age of 49 with black spots, flashes of light and central blur. He was obliged to give up his work as a delivery man at the age of 53. When seen his vision was less than 3/60 and he was registered blind. His peripheral field was good and the defect was central, for he saw better in a dim light and could get about easily. See Fig. 7 (a) and (b).

III, 11. *Edith B*. Died of tuberculosis, under 40. Reputed normal.

III, 12. *Frederick B., junior*. Died of tuberculosis, aged 38. Reputed normal.

III, 13. *Edward B.*, of Uxbridge. Age 56. Was examined and found to be affected. His trouble first started at the age of 51. He is now registered blind but his peripheral vision allows him to get about and do some work. See Fig. 3 (a) and (b).

III, 14. *Albert B*. Aged 54. Seen by Dr. Joan Haythorne at the Royal Eye Hospital in December, 1948, and found to be normal with a visual acuity of 6/6 in each eye.

III, 15. *Mrs. Florence D.*, of Harrow Weald. Aged 52. Was examined and found to be normal.

III, 16. *Mrs. Hl*, of Co. Durham. Aged 50. Reputed normal.

III, 17. *Henry B.*, of Wandsworth. Aged 46 (Proband). Seen at the Royal Eye Hospital in September, 1947, when the trouble first started, complaining of a shadow in front of the eyes. Visual acuity unaided 6/9 part in the right eye and 6/12 in the left. Fundus pictures Fig. 1 (a) and (b) were made at this time. When seen again in December, 1949, visual acuity was unchanged and the fundus appeared the same. He complained, however, that the shadow was rather worse.

(3) *Children of Mrs. Bt (II, 3, reputed normal)*.

III, 18. Female. Died before she reached the age of 40. Reputed normal.

III, 19. Male. Died aged 49 of heart disease. Reputed normal.

III, 20. Male. Died before he reached the age of 40. Reputed normal.

III, 21. *Mr. Bt.*, of Chesham. Age 68. Was examined and found not to be

affected. His visual acuity was 6/12 in the right eye and 2/60 in the left. He had glaucomatous cupping of both discs; fundi were otherwise normal.

(4) *Child of Mrs. Lt (II, 4, reputed affected).*

III, 22. *Mr. Lt*, of Uxbridge. Aged 60. Was examined and found to be normal with a visual acuity of 6/6 in each eye unaided.

**Generation IV.**

(1) *Children of Mrs. Br (III, 1, affected).*

IV, 1. *Mrs. U.*, of Amersham. Aged 59. Examined, normal.

IV, 2. *Mrs. R.*, of Amersham. Died aged 56. Reputed normal.

IV, 3. *Edward Br.* Killed age 21. Reputed normal.

IV, 4. *Harry Br.*, of Chesham. Aged 52. Examined, affected. His right eye failed suddenly in August, 1945, at the age of 49. The left became affected soon afterwards. He has been quite unable to read since April, 1946. On examination he had a severe central defect but good peripheral vision and was able to get about easily. See Fig. 2 (a) and (b).

IV, 5. *Mrs. Rl.* of Chesham. Aged 48. Examined, normal.

IV, 6. *Mrs. M.*, of Chalfont St. Peter. Aged 45. Examined, not affected. Her fundus showed a fine generalized white mottling behind the retinal vessels in the equatorial and peripheral areas. The maculae were normal. Moderate myopia, reads J2.

IV, 7. *George Br.*, of Chesham. Aged 42. Examined, normal.

IV, 8. *William Br.*, of Chalfont St. Peter. Aged 36. Reputed normal.

(2) *Children of Mrs. Bs (III, 2, not affected).*

IV, 9. *Mrs. Bl.* of Chesham. Aged 53, reputed normal.

IV, 10. *Mrs. W.*, of Chesham. Aged 51. Examined, not affected. Signs of old iritis in the left eye, otherwise normal.

(3) *Children of George B., junior (III, 4, normal).*

IV, 11. *Mrs. Hy, junior*, of Chesham. Aged 46. Examined, normal.

IV, 12. *Leonard B.*, of Amersham Common. Aged 44. Reputed normal.

IV, 13. *Sidney B.*, of Chesham. Aged 36. Examined, normal.

(4) *Children of Mrs. Hy, senior (III, 5, affected).*

IV, 14. *Jack Hy*, of Chesham. Examined, not affected. There were a few white spots in the macular area, probably within normal limits. Reads J1 with each eye.

IV, 15. *Mrs. Ws.* of Wendover. Aged 40. Examined, normal.

IV, 16. *Mrs. Rd.* of Chesham. Aged 39. Examined, normal.

IV, 17. *Dennis Hy*, of Chesham. Aged 26. Examined, normal.

IV, 18. *Roy Hy*, of Chesham. Aged 22. Examined, normal.

(5) *Children of Mrs. Hd (III, 7, affected).*

IV, 19. *Mrs. Wn.* of Maida Vale. Aged 40. Reputed normal.

IV, 20. *Leon Hd.* of Chesham. Aged 36. Reputed normal.

IV, 21. *Terence Hd.* of Chesham. Aged 30. Examined, not affected. Moderate myopia. Visual acuity 6/6 in each eye, with glasses. Normal fundi.

(6) *Children of Mrs. A (III, 8, affected).*

IV, 22. <i>Bertram A.</i> , of Chesham. Aged 32.	} Reputed normal.
IV, 23. <i>Raymond A.</i> , of Chesham. Aged 27.	
IV, 24. <i>Mrs. B.</i> , of Berkhamsted. Aged 45.	

(7) *Children of Alfred B. (III, 10, affected).*

IV, 25. *Mrs. He.* of Chesham. Aged 37. Examined, normal.

IV, 26. *Freda B.*, of Chesham. Aged 34. Examined, not affected. Moderate myopia, few vitreous opacities, normal fundi.

- IV, 27. *Mrs. Mr.*, of Chesham, Aged 32. Examined, normal.  
 IV, 28. *Cecil B.*, of Chesham. Aged 26. Examined, normal.
- (8) *Children of Edward B. (III, 13, affected).*  
 IV, 29. *Frederick B., tertius*, of Hillingdon. Aged 28. }  
 IV, 30. *Phyllis S.*, of Kingsbury. Aged 25. }  
 IV, 31. *Dennis B.*, of Chesham. Aged 23. } Reputed normal.  
 IV, 32. *Peter B.* Aged 16. }  
 IV, 33. *Pauline B.* Aged 15. }
- (9) *Children of Albert B. (III, 14, normal).*  
 IV, 34. *Mrs. Sn.*, of Wandsworth. Aged 26. Reputed normal.  
 IV, 35. *Marjorie B.* Aged 22. Reputed normal.  
 IV, 36. *Edna B.* Aged 18. Reputed normal.
- (10) *Children of Mrs. Florence D. (III, 15, normal).*  
 IV, 37. *Female.* Aged 28. Examined, normal.  
 IV, 38. *Male.* Killed aged 9. Reputed normal.
- (11) *Children of Mrs. Hl (III, 16, normal).*  
 IV, 39. *Female.* Aged 25. } Reputed normal.  
 IV, 40. *Female.* Aged 21. }
- (12) *Children of Henry B. (III, 17, affected).*  
 IV, 41. *Male.* Aged 21. Reputed normal.  
 IV, 42. *Male.* Aged 5½. Examined at Royal Eye Hospital. Normal.
- (13) *Children of Mr. Bt (III, 21, normal).*  
 IV, 43. *Mrs. E.*, of Chesham. Aged 42. Reputed normal.  
 IV, 44. *Male.* Died age 22. Reputed normal.  
 IV, 45. *Miss Bt*, of Chesham. Aged 37. Reputed normal.
- (14) *Child of Mr. Lt (III, 22, normal).*  
 IV, 46. *Female*, of U.S.A. Aged 26. Reputed normal.

#### Generation V.

- (1) *Child of Mrs. U. (IV, 1, normal).*  
 V, 1. *Female.* Aged 29. Reputed normal.
- (2) *Children of Harry Br (IV, 4, affected).*  
 V, 2. *Brenda Br.* Aged 15. Examined, normal.  
 V, 3. *Christine Br.* Aged 10. Examined, normal.
- (3) *Children of Mrs. Rl (IV, 5, normal).*  
 V, 4. *Female.* Aged 27. }  
 V, 5. *Female.* Aged 25, approximately. } Reputed normal.  
 V, 6. *Male.* Aged 11. }  
 V, 7. *Female.* Aged 8. }
- (4) *Children of Mrs. M. (IV, 6, normal).*  
 V, 8. *Male.* Aged 18. Reputed normal.  
 V, 9. *Female.* Aged 13. Reputed normal.
- (5) *Children of George Br (IV, 7, normal).*  
 V, 10. *Male.* Aged 14. }  
 V, 11. *Male.* Aged 10. } Examined, normal.  
 V, 12. *Female.* Aged 2. }
- (6) *Child of Mrs. Bl (IV, 9, normal).*  
 V, 13. *Male.* Aged 29. Reputed normal.

- (7) *Child of Mrs. Hy, junior (IV, 11, normal).*  
*V, 14. Male. Aged 26. Examined, normal.*
- (8) *Child of Leonard B. (IV, 12, normal).*  
*V, 15. Male. Killed aged 19. Reputed normal.*
- (9) *Children of Sidney B. (IV, 13, normal).*  
*V, 16. Female. Aged 6. Examined, normal.*  
*V, 17. Male. Aged 3. Examined, normal.*
- (10) *Child of Jack Hy (IV, 14, normal).*  
*V, 18. Tony Hy. Aged 12. Examined, normal.*
- (11) *Children of Mrs. Ws (IV, 15, normal).*  
*V, 19. Joyce Ws. Aged 20. } Reputed normal.*  
*V, 20. June Ws. Aged 18. }*  
*V, 21. Keith Ws. Aged 17. }*
- (12) *Children of Mrs. Rd (IV, 16, normal).*  
*V, 22. Peter Rd. Aged 14. Examined, normal.*  
*V, 23. Gillian Rd. Aged 6. Examined, normal.*  
*V, 24. Pauline Rd. Aged 3. Reputed normal.*
- (13) *Child of Dennis Hy (IV, 17, normal).*  
*V, 25. David Hy. Aged 2½. Reputed normal.*
- (14) *Children of Mrs. He (IV, 25, normal).*  
*V, 26. John He. Aged 8. Examined, normal.*  
*V, 27. Female. Reputed normal.*
- (15) *Children of Mrs. Mr (IV, 27, normal).*  
*V, 28. Female. Aged 3½ } Reputed normal.*  
*V, 29. Male. Aged 18 months. }*
- (16) *Child of Cecil B. (IV, 28, normal).*  
*V, 30. Female. Aged 14 months. Reputed normal.*

**Generation VI.**

- Children of V, 1. (female, normal).*  
*VI, 1. Male. Reputed normal.*  
*VI, 2. Female. Reputed normal.*

**REFERENCE**

SORSBY, A. and MASON, MARY E. JOLL (1949). *British Journal of Ophthalmology*, 33, 67.