

## COMMUNICATIONS

### THE SCOPE OF CORNEAL GRAFTING\*†

BY

B. W. RYCROFT

*From the Corneo-Plastic Unit and Eye-Bank, Queen Victoria  
Hospital, East Grinstead, Sussex*

IN considering corneal grafting it must surely be in the thoughts of all of us that we are offering our own special tribute as ophthalmologists to the pioneer work of our colleague and President, Mr. Tudor Thomas. For it was in Cardiff that he carried out that experimental and clinical work which not only inspired ophthalmic surgeons in many parts of the world to study corneal grafting, but which also went far to establish keratoplasty as an effective method of ophthalmic surgery in the treatment of corneal blindness (Tudor Thomas, 1951).

#### Historical Survey

The idea of corneal grafting in Great Britain may be said to have begun with the remarks of Darwin (1794-96):

*After ulcers of the cornea which have been large, the inequalities and opacity of the cicatrix obscure the sight: in this case could not a small piece of the cornea be cut out of a kind of trephine about the size of a thick bristle, or a small crow-quill, and would it not heal with a transparent scar?*

This is not the earliest record of the idea of corneal grafting, but it is probably the first to have appeared in the English language. The first attempts to perform the operation were made in the first half of the 19th century; they were handicapped by constant infection, crude instruments, no anaesthesia but a bottle of brandy, no idea of selection of cases suitable for grafting, and complete confusion of thought between the biological problems of homoplasty and heteroplasty. But this new idea suggested vast potentialities; there was no scarcity of donor material and many patients were suitable for treatment as a result of indifferent methods of treating war injuries and widespread blindness from venereal infection. Many trials were made and many failures were recorded, but here and there in the literature glows the spark of a successful case (e.g., Bigger, 1837). Such cases caused Marcus (1841) to postulate that:

- (1) there should be an exact correspondence in the size and form of the graft and opening;
- (2) the graft must be rapidly transferred and there must be ready fixation;
- (3) the internal structures of the eye must be prevented from being pushed forwards on the opening on the cornea.

\*Based on the opening paper at the Section of Ophthalmology, Annual General Meeting of the British Medical Association, Cardiff, July, 1953.

† Received for publication August 31, 1953.

Even though Dieffenbach (1830) described the idea of corneal transplantation as an "audacious fantasy", yet the important fact had been established that an animal cornea would accept other animal grafts without great disturbance, although the objective of transparency in a corneal transplant had not yet been achieved.

So unsuccessful and discouraging were the results of these early attempts that the second half of the 19th century commenced as a period of gloom. A few attempts were made to cross-graft animals, but beyond this little experimental work appears to have been carried out. Though keratoplasty did not prosper, the gloom was not quite unrelieved, for other branches of ophthalmic surgery were making progress: von Graefe (1856) demonstrated the value of iridectomy, cocaine came into use, and shortly afterwards steam sterilization, and the principles of antisepsis were being accepted. Between 1878 and 1888 von Hippel carried out experiments with corneal grafts in animals and man, and devised his clockwork corneal trephine which did so much to stimulate and facilitate graft surgery. Furthermore, he actually recorded and showed a patient at Heidelberg in 1886 and 1887 on whom he had carried out a successful animal graft which retained some degree of transparency. By the end of the century the principles of homoplasty had been soundly defined by Fuchs (1901), and the prospects for accurate corneal graft surgery, with the possibility of some improvement of vision, were bright.

The 19th century ended on an optimistic note and, though there had been many fruitless experiments, there were occasional reports of a successful case, infection was becoming less of a menace, and the idea of homoplasty was established. Better instruments were in use, and thus different techniques could be tried, so that, although there was a certain amount of confusion as to the best method, more trials of different methods were made. As yet, however, on account of the limited number of successes, there could be no adequate selection of cases.

Soon after the turn of the century Zirm succeeded in grafting the eye of a man with severe lime burns, and he followed the case for over 2 years with accurate records of improved vision. Zirm (1906) enumerated the principles on which much of modern corneal graft surgery is based:

- (1) The exclusive use of young and healthy human cornea.
- (2) The use of the von Hippel trephine together with eserine.
- (3) Adequate anaesthesia, strict asepsis, and the avoidance of anti-sepsis.
- (4) Protection of the graft between layers of gauze material and adequate retention by overlay sutures.

### Recent Progress

Since that time corneal graft surgery has made rapid progress, although hindered by the two wars. Between the wars, Filatov (1934) pointed out the value of the cadaver graft, asserting that this material was as good, if not better, than fresh material, and Elschmig (1930) published a large series

of successful cases which in themselves were an inspiration. Alterations in technique came with experience: Tudor Thomas urged the bevel edge of the graft with variations in the overlay sutures, and correlated the safety of this method with careful animal experimental work. In the U.S.A. Castroviejo (1939) demonstrated a large series of successful results. More recently Franceschetti (1949) in Switzerland and Paufigue and his co-workers (1948) in France have revived lamellar keratoplasty with modern technical advancements.

Thus we may now say that infection has been controlled, excellent instruments of beautiful precision are generally available, and safe anaesthesia is the rule. The selection of cases has also become more definite and the assessment of results more uniform and accurate. It is safe to say that about half the selected patients who undergo full-thickness transplantation may now expect improvement of sight with clear grafts up to 60 per cent., and that those for whom the partial thickness operation is preferred have a higher expectation of improved vision with clear grafts up to about 80 per cent.

### Present-Day Problems

The difficulties which still remain may be enumerated under the headings of Technique, Administration, and Biological Problems.

(1) **Technique.**—As in every branch of surgery, now that principles have been firmly established there are many methods whereby successful results can be achieved. In the old days the occasional successful case created excitement, but to-day the emphasis must be placed on accurate statistical results.

(a) *Fixation of the Graft.*—This is still a matter of choice. Some, including our Unit, incline to the old view that the graft should be almost untouched and that fixation should depend on overlay sutures from which the graft is protected by egg membrane. We use a "Union Jack" pattern of overlay sutures giving adequate fixation around the perimeter; it is believed that this is better than the simple right-angle cross sutures which tend to cause localized distortion by uneven tension. Others feel that the graft is best secured in the bed by the insertion of separate interrupted radial sutures which hold it in place, but we consider that each stitch separates the corneal lamellae, thereby allowing oedema to develop and setting up a local area of potential vascularization. Moreover, unless these stitches are exactly at right angles to the section, a good section can be converted into a bad one as the stitches are tightened. Other surgeons have felt the need to employ splints of various materials to secure the grafts in place and obtain successful results by different techniques. Figs 1 (a, b), 2 (a, b), 3, and 4 (overleaf) show examples of modern corneal graft surgery by different methods.

(b) *Cutting the Graft.*—This is an important consideration because an accurate section line is of great importance if rapid reformation of the anterior chamber is to be achieved and iris inclusion avoided. Individual surgeons again have different methods. In our view the edge of the graft should be traumatized as little as possible and we prefer to cut it by the punch method which compresses

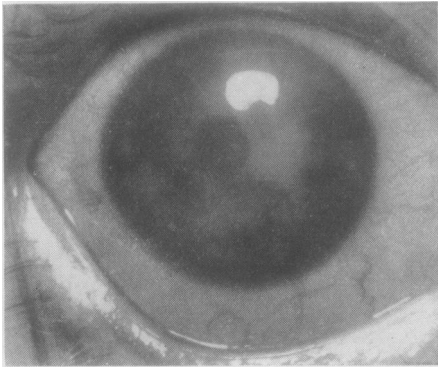


FIG. 1 (a).—“Primrose” keratitis.—Diffuse corneal scar not extending to Descemet’s membrane.

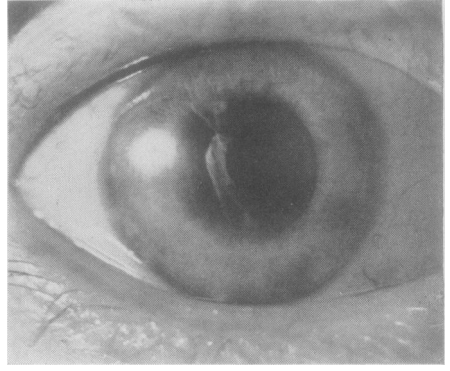


FIG. 1 (b).—8-mm. lamellar graft, vision 6/9. Note image of white-coated photographer and iris pattern.

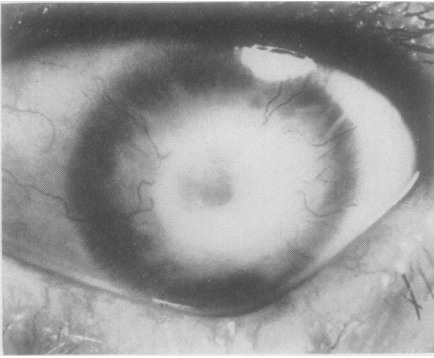


FIG. 2 (a).—Old traumatic burn keratitis.—Before operation, previous corneal graft in 1934.

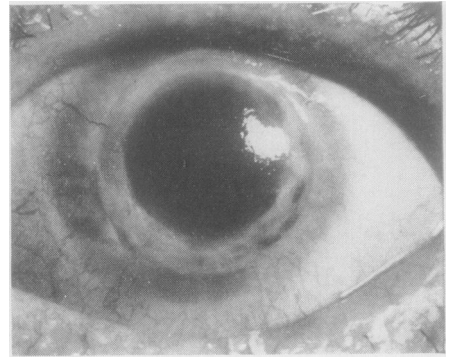


FIG. 2 (b).—Full thickness 6/8-mm. flange graft, vision 6/12. Re-graft.

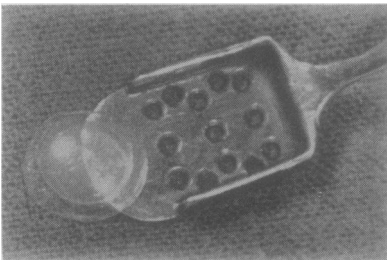


FIG. 3.—Flange graft.—Centre circle 6 mm. and full thickness; corneal lamellar frill for sutures 2 mm.

the fibres at the edge of the graft. If the graft is cut by a trephine which is not exquisitely sharp these fibres are separated. Since excellent

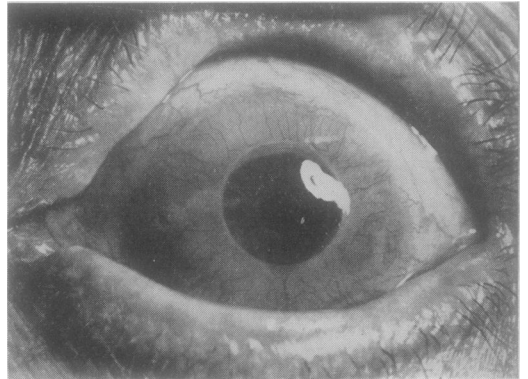


FIG. 4.—Interstitial keratitis.—Full-thickness 6-mm. cylinder graft one month after operation, fixation by author’s technique, vision 6/36 (Senile cataract). Re-graft.

results are now obtained by various methods, details of technique no longer form a major problem.

(c) *Selection of Cases.*—Where the scar can be seen by the narrow slit-lamp beam to invade the corneal stroma to the level of Descemet's membrane, a penetration graft is the method of choice. Lamellar keratoplasty is more suitable for cases in which a clear area of cornea can be seen to overlay Descemet's membrane. Mustard gas cases have always presented difficulties when an initial full-thickness graft is used, owing to the sharp irregularities which occur in a mustard gas cornea. At one point the thickness may be little more than Descemet's membrane, whereas at another point in the same cornea there may be an actual increase in thickness. Ocular pemphigus where the cornea is dry has given uniformly unsuccessful results in eight cases at our Clinic, and it is also felt that where a symblepharon does not invade corneal tissue it should be left alone if an optical graft is contemplated on that cornea. Keratitis acne rosacea has occasionally been found to invade successful grafts some months after operation, but this should not prevent treatment of such cases by keratoplasty; repetition grafts have been strikingly successful in acne keratitis, corneal dystrophies, and interstitial keratitis. Even with modern improvements in the operation, it is felt that a penetration graft is only justified where binocular vision is no better than a poor 6/36. A unilateral penetration graft where the other eye has good vision is rarely indicated.

(2) **Administration.**—The supply and preservation of donor material is another major problem, but one which is diminishing in gravity.

(a) *Supply of Donor Material.*—Before 1939 the supply of donor material from eyes which had had to be excised was adequate for the limited number of corneal transplantations which were then undertaken, but since 1945 the stimulus provided by the work of Castroviejo, Franceschetti, Paufique, and others has caused the demand for donor corneae to outstrip the supply. Filatov had shown that cadaver material was just as good as fresh, but as the law stood in Great Britain, it was not possible to obtain such supplies legally. Yet if corneal graft surgery was to advance an adequate donor supply was necessary for trials, treatment, and training. It was therefore decided to try either to amend the existing Anatomy Act of 1832 or to bring in a new Act of Parliament. By careful factual propaganda the people were shown by the press, radio, and television what corneal graft surgery could be expected to do for blindness, and when the Corneal Grafting Act came before Parliament it was passed without opposition in September, 1952. This Act, which permits eyes to be removed from a corpse where no objection has previously been made by deceased or relatives, or where the eyes have been bequeathed, promises to solve the donor problem (Rycroft, 1953).

(b) *Selection and Preservation of Donor Material.*—The best eyes come from aged persons who have died a natural death. They should be removed within 10 hours of death, and after removal may be kept under conditions of sterile refrigeration for at least a fortnight. It is most essential that a culture of donor eyes should be taken immediately on receipt at the Eye Bank and again 48 hours before use; in about 10 per cent. of cadaver eyes after several days' refrigeration at 4° C. pathological organisms have been cultured. At the East Grinstead Unit the eyes are received in liquid paraffin and an immediate culture is taken. They are then transferred to the Eye Bank in a mixture of liquid paraffin, streptomycin, and peni-

cillin. The container holding this medium and the eye is then placed in the refrigerator at 4° C. until required for use when a further culture is taken. Eyes have given successful optical grafts after preservation by this method for as long as 3 weeks.

(c) *Training of Personnel.*—This has become a problem for the future now that adequate donor material is available. In our view this type of surgery should only be undertaken in selected centres. To carry out corneal grafts at random intervals at hospitals of all types is not only extravagant in the provision of expensive instruments and wasteful in donor material, but also exposes the patient to risks of inadequate technique and donor supply. At least three donor corneae should be at hand before any graft case is undertaken. The operation is one of great precision demanding much practice in technique and a long clinical training in the selection of cases. If anyone is to practise it with consistent success he must work under conditions where the patient has adequate safeguards. Then again, the arrangements for the collection and banking of donor material are better carried out in special centres than in miscellaneous hospitals: donor material is still too valuable to waste.

### (3) Biological Problems.

(a) *Antibody-Antigen Reaction.*—This problem, which confronts all branches of reconstructive graft surgery, depends broadly on the reactions of the host to grafts of foreign tissue. Under normal conditions the body will not accept a true graft of another person's tissue, except in the case of uni-ovular twins. A homo-plastic skin graft from another person invariably disintegrates at the end of about 3–4 weeks, but the cornea and certain pieces of cartilage are favoured materials and behave differently, since a corneal graft is not cast off and cartilage apparently remains unchanged. The present view is that such a corneal graft loses its cellular characteristics at the end of a fortnight but retains basic membranes. Invasion of these membranes by cells from the host, of which there are not many, reconstitute the graft: thus this is not a true graft but a scaffold graft which becomes integrated with the membranes and cell contents of the host. It is also considered that the presence of cells in the corneal graft stroma is essential for transparency. Loss of transparency constitutes failure of the graft; vascularization and oedema are the main dangers.

(b) *Vascularization.*—This may occur in the first week, when it is irritative, superficial, and due to operative trauma: this is of little consequence and generally subsides. Deep vascularization, however, is another matter; it may be caused by premature operation when the initial disease has hardly subsided; it may also be caused by defects of technique, broad iris adhesions, or the infiltration of existing vessels. There still remain, however, a considerable number of cases in which the graft fails from vascularization when the technique has been entirely successful, and it is possible that this group of failures is due to the antigen-antibody reaction. Local cortisone is definitely helpful in neo-corneal vascularization but it has little effect on established vessel systems.

(c) *Oedema.*—This is also a menace, and though it is frequently associated with vascularization there are cases in which blood vessels are not unduly prominent. Again, deficiencies of technique which do not allow an accurate edge-to-edge alignment of the graft and host frequently account for oedema, but often after

successful technique there may be a severe and persistent oedema with bullous formations in the graft epithelium which begins about the third week without any sign of undue irritation and which causes a failure of the graft: in such cases tissue allergy is probably the cause also (Fig. 5*a* and *b*). The solution of these problems is our responsibility for the future, but already there are signs of encouragement.

Billingham and Medawar (1950) in London and Maumenee and Kornblueth (1948) in San Francisco have proved beyond doubt that the insertion of a skin or corneal graft into the host will produce an antigen-antibody reaction and that there is some definite relationship between the two. This biological problem and confirmation of the work of Maumenee is at present being studied in our Unit and in the laboratory.

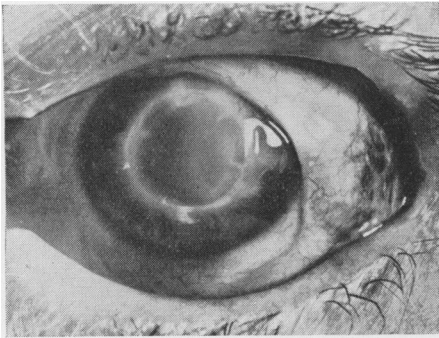


FIG. 5 (*a*).—Graft oedema 8 weeks after operation.

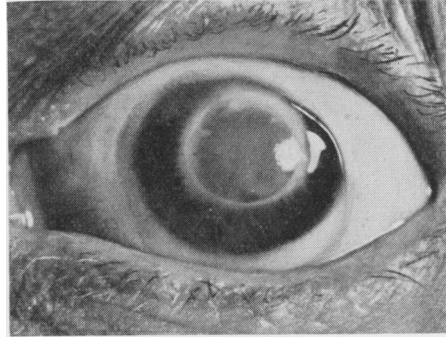


FIG 5 (*b*).—12 weeks after operation. Graft 6.1 mm. and interrupted suture fixation. Note absence of host vascularization and oedema of suture tracks.

But the initial failure of a graft from the antigen-antibody reaction does not necessarily constitute a permanent failure. Grafts have been repeated in several cases after one or two failures with a final successful clear graft (Fig. 6*a* and *b*). At each attempt the technique was identical but in the failures oedema or vascularization intervened whereas the final graft produced no reaction and remained clear.

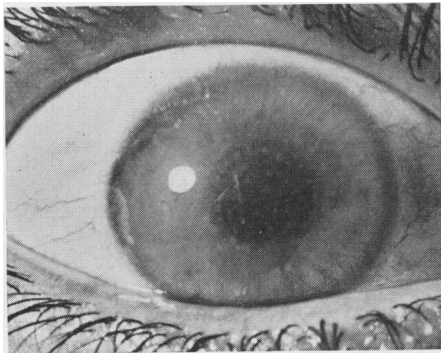


FIG. 6 (*a*).—Corneal dystrophy before operation.

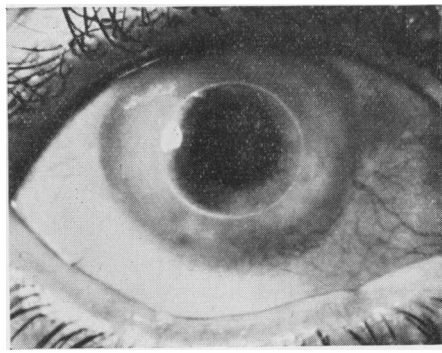


FIG. 6 (*b*).—Full-thickness 6-mm. cylinder graft 6 months after operation, fixation by author's technique, vision 6/9, re-graft.

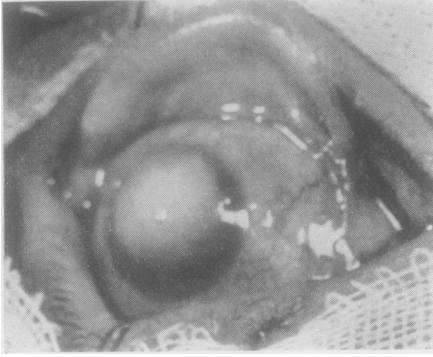


FIG. 7 (a).—Total corneo-scleral transplantation.—Eye before operation, large leucoma adherens.

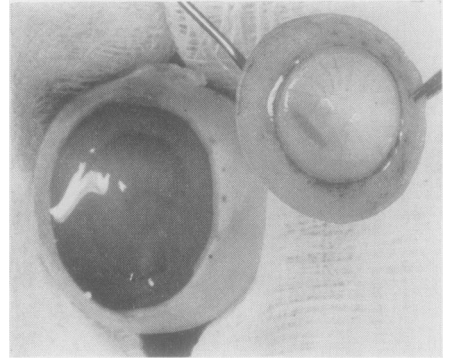


FIG. 7 (b).—Graft cut from cadaver eye.

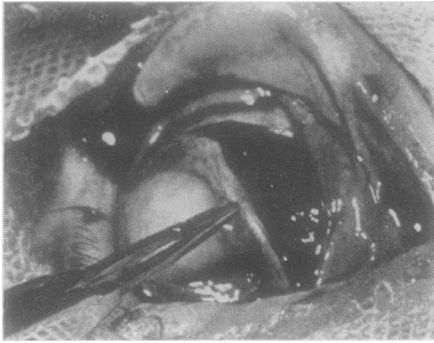


FIG. 7 (c).—Scarred cornea and scleral frill excised under low-pressure anaesthesia: the intra-ocular pressure was very low and there was no bleeding.

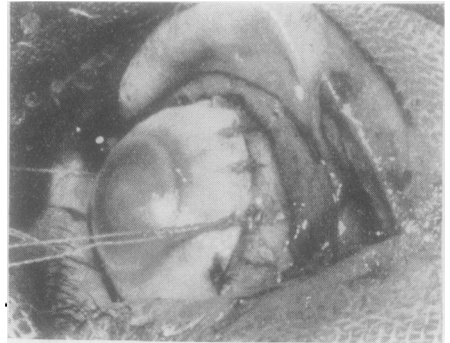


FIG. 7 (d).—Graft sutured in position.

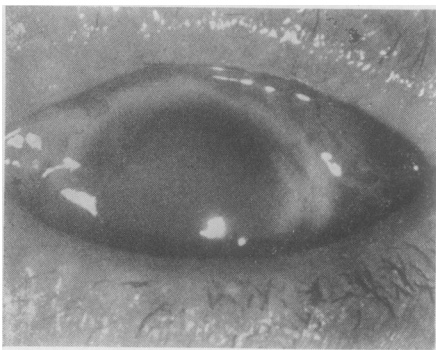


FIG. 7 (e).—Grafted eye 3 weeks later; at 6 weeks the cornea was totally opaque but there was no infection.

Section of the enucleated eye showed good union of the incision and diffuse corneal oedema.

The investigation and solution of these reactions of tissue transplantation are of paramount importance for all branches of reconstructive surgery, for this is likely to be the era of surgical transplantation in several parts of the body. The eye, because of its ready accessibility and individual reaction, will prove most useful in future studies.

Future developments may include grafts of the whole of the cornea with some part of the sclerotic also. Technically it is now possible to graft the whole of the cornea and part of the sclera in one piece without undue difficulty, but it is not yet possible to maintain such a grafted cornea



in permanent transparency. Always at the end of three weeks, in a very similar manner to a skin graft, the cornea has become opaque and fibrosed, not from infection but from innate biological causes. When a whole graft of this kind remains clear it will represent a major step in the treatment of corneal blindness (Figs 7a-e).

The words of de Wecker (1897) are as true to-day as they were when written:

We have no right in these cases to refuse the slightest aid to sufferers who have but this one remaining chance to recover a little sight: neither should we be deterred by the reproach of eccentricity which will certainly be levelled at anyone who therefore attempts to graft a cornea.

I wish to thank Mr. Giles Romanes and my staff for their constant help, Mr. Gordon Clemetson and the staff of the Photographic Unit for their assistance and expert photography, and Mr. LeFanu, librarian of the Royal College of Surgeons of England, for his assistance. It is a pleasure also to acknowledge the assistance this Unit has received from many ophthalmic surgeons and pathologists in the South of England with the supply of donor eyes.

#### REFERENCES

- BIGGER, S. L. L. (1837). *Dublin J. med. Sci.*, **11**, 408.  
 BILLINGHAM, R. E., and MEDAWAR, P. B. (1950). *J. Anat. (Lond.)*, **84**, 50.  
 CASTROVIEJO, R., (1939). *Arch. Ophthal. (Chicago)*, **20**, 114.  
 DARWIN, E. (1794-96). "Zoonomia". Johnson, London.  
 DIEFFENBACH, J. F. (1830). (v. Ammon) *Z. Ophthal.*, **1**, 172.  
 ELSCHNIG, A. (1930). *Arch. Ophthal. (Chicago)*, **4**, 615.  
 FILATOV, V. P. (1934). *Ann. Oculist. (Paris)*, **171**, 721.  
 FRANCESCHETTI, A. (1949). *Trans. ophthal. Soc. U.K.*, **69**, 17.  
 FUCHS, E. (1901). *Z. Augenheilk.*, **5**, 1.  
 GRAEFE, A. VON (1856). v. *Graefes Arch. Ophthal.*, **2**, pt 2, 202.  
 HIPPEL, A. VON (1878). *Ibid.*, **24**, pt 2, 235.  
 ——— (1888). *Ibid.*, **34**, pt 1, 108.  
 MARCUS (1841). *Schmidts m-u. ansl. ges. Med.*, **29**, 89.  
 MAUMENEE, A. E., and KORNBLUETH, W. (1948). *Trans. Amer. Acad. Ophthal. Otolaryng.*, **52**, 331.  
 PAUFIQUE, L., SOURDILLE, G. P., and OFFRET, G. (1948). "Les greffes de la cornée". Masson, Paris.  
 RYCROFT, B. W. (1953). *British Journal of Ophthalmology*, **37**, 349.  
 THOMAS, J. W. TUDOR (1951). XVI Concilium ophthalmologicum 1950, Acta, vol. 2, p. 993. B.M.A., London.  
 WECKER, L. DE (1879). "Ocular Therapeutics", trans. L. Forbes, p. 145. Smith Elder, London.  
 ZIRM, E. (1906). v. *Graefes Arch. Ophthal.*, **64**, 580.