

VASCULAR SUPPLY OF THE OPTIC PATHWAY*

II. FURTHER STUDIES BY MICRO-ARTERIOGRAPHY OF THE OPTIC NERVE

BY

J. FRANÇOIS, A. NEETENS, AND J. M. COLLETTE†

*From the Ophthalmological Clinic, University of Ghent (Director, Prof. François),
and the Institute of Radiology, University of Liège (Director, Prof. Leroux)*

THE literature gives few details of the intimate vascularization of the optic pathway. Leber (1903) found in the optic nerve a vascular network, composed of round meshes; he described other vessels running obliquely along the whole length of the optic nerve, which became smaller with more closely woven meshes at the level of the lamina cribrosa.

Wolff (1948) agreed with Leber that the distribution of the septa containing the vessels between the nervous tissue bundles reflected the vascular pattern. The branches, which derived from the very rich pial vascular network, penetrated dichotomously into the optic nerve, the septa gradually disappeared towards the intracanalicular and cranial sections, and in the centre the capillaries were less frequent and the meshwork looser (*cf. also* Behr, 1935).

Fazio and Farina (1940) deduced from horizontal sections (not from injection) the existence of an irregular quadrangulated meshwork, orientated lengthways, built up by very small capillaries, and of equal density at the periphery and centre. Towards the optic foramen the capillaries and meshes were wider and still more irregular, and in the intracranial section a great number of very small vessels ran parallel.

Eisler (1930) indicated the possibility of a network with longitudinal meshes in the sheath of the optic nerve.

The subject obviously requires further investigation.

Technique

At *post mortem*, the orbital contents are separated from the bone together with the periosteum, and after the superior wall of the optic foramen has been trephined, the orbital roof is removed from the inner side of the skull. The bone of the sella turcica is incised and the sphenoid bone chiselled; the internal carotid artery is taken over as long a distance as possible, and the orbit is removed complete with the optic nerve and its whole vascular supply. In the laboratory the specimen is irrigated for a few minutes; then the internal carotid artery is dissected until the opening of the ophthalmic artery is reached, or, if it is intended to inject the central retinal artery, as far as the branching of this vessel. In some specimens a branch is seen to arise from the ophthalmic artery before the central retinal artery is observed; this is described by Magitot (1908) as running to the dura mater, but in some cases (about one in four) we were able to identify it as a central artery of the optic nerve.

Next a fine cannula is inserted into the artery to be injected, and without previous

*Received for publication August 3, 1954.

†Candidate of the Belgian Fund for Scientific Research.

irrigation with water the injection is made immediately with Heyden thorotrast solution:

Colloidal thorium oxide 3 gr.
Amyl. semi-invertum 3 gr.
Aqua ad 12 ml.

The injection is done without previous irrigation for three reasons:

- (1) To make a better contrast;
- (2) Because eventual clotting is avoided by the haemolysis produced by the thorotrast;
- (3) Because thorotrast solution mixes easily with blood.

The injection is carried out very slowly and under a constant pressure of 25 to 30 mm. Hg without clamping the venous outflow. The particle size of thorotrast being of the order of 0.1μ , the solution penetrates into even the smallest vessels. Injecting slowly prevents the collapse of the small vessels.

The specimens must be fixed as soon as possible, because diffusion out of the vessel-walls may occur even *post mortem*. Formalin solution 2-3 per cent. is not used, as this would prevent the fixation of the thorotrast. A special fixative is used which has been found entirely satisfactory:

Formalin 10 per cent.	8 parts
Alcohol 96 per cent. saturated with picric acid	6 parts
Acetic acid	1 part
Chloroform	1 part

This fixes the thorotrast and does not make the specimens rigid or more fragile than those fixed with formalin 10 per cent.

The apparatus has already been described (François and Neetens, 1954).

The technique of micro-angiography is new and its application so far very restricted (Collette, 1953; Bellman, 1953; Bellman and Engström, 1952; Engström, 1949, 1951; Engström and Wegstedt, 1951; Barclay, 1951; Bohatyrtshuk, 1944; Brasseur, 1945; Tirman and others, 1951).


(1) Radiology.—The preliminary injection of the vascular system with substances of high atomic weight simplifies the application of the method, on account of the absorption which occurs at the site of the injected vessels as compared with the surrounding medium. Yet it remains necessary to use long-wave rays to obtain sufficient contrast. Our micro-radiographic unit (generator and tube) is very convenient in use.

Generator.—This holds in the same container the high voltage transformer and the transformer used for heating the filament. The primary coils are fed by variable transformers; this permits a continuously variable range of 0-50 kV maximum and 0-35 mA.

Tube.—We use a Machlett A2 tube with iron target and beryllium window. It is known that the intensity of the continuous spectrum emitted by an x-ray tube is proportional to the atomic number of the element used at the anode. The intensity is low in this case, since the atomic number of iron is only 26. However, the Fe target emits characteristic lines of high intensity and long wave-length ($K \alpha 1: 1.936 \text{ \AA}$; $K \alpha 2: 1.932 \text{ \AA}$). The intensity of these characteristic lines increases with the voltage, but the wave-length remains constant. Therefore, in the low-voltage range, the intensity of the continuous spectrum will be negligible compared with the characteristic radiation. The latter, however, is soft and rapidly absorbed by air. This makes it necessary to use a short focal length in order to take full advantage of the intense monochromatic radiation.

Accessories.—Our tube is equipped with a 1.5-mm. focus, but the beryllium window has a small diameter and reduces the effective beam angle to 10° .

The film-holder has been designed to permit the coverage of a circular field 25 mm. in diameter (Fig. 1). The least distance from source to object is 13.5 cm.



Long exposures are necessary and require all parts of the system to be firmly joined together. The film-holder (Fig. 2, III, IV, V) is joined to the tube by a number of intermediary components. First an adapter (Fig. 2, VI) is screwed onto the tube window and

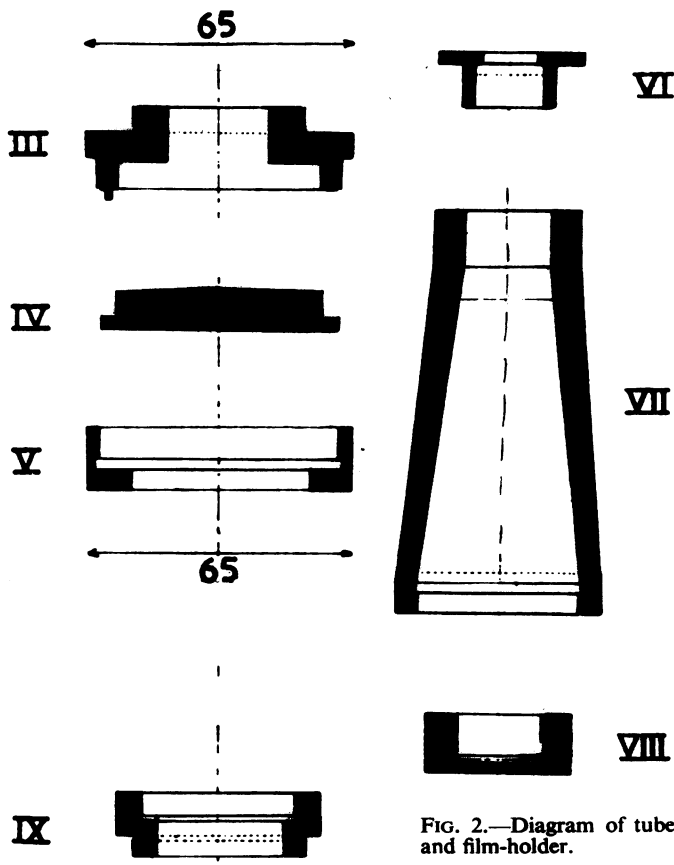


FIG. 2.—Diagram of tube and film-holder.

holds an intermediary cone (Fig. 2, VII). The film-holder itself may be screwed directly to this cone, but it is also possible to use extension rings (each 1 cm. wide) between the film-holder and the cone to give a greater focal length.

A disk holding the histological sample and the film is inserted into a circular hole bored in the cover of the film-holder. There must be a close contact between the film emulsion and the sample. The latter is never completely dry and a non-hygroscopic support separates it from the film. We usually put the sample between two sheets of "Styrafoil" 1/100 in. thick, the upper sheet providing the close contact required when the film-holder is closed.

The sample is removed from the fixing solution immediately before being x-rayed. The excess fluid is eliminated, but the preparation must remain moist as desiccation may cause change in volume with consequent motion during exposure.

(2) **Photography.**—The main photographic problem is to find a film with a fine enough grain. Two emulsions have been found suitable: "Maximum Resolution" film (Kodak) resolution 1,000 lines, and "Lippman" film (Gevaert) resolution 500 lines. The latter was used in this study. The grain of an emulsion is roughly proportional to its speed, and this fine-grain film requires long exposures. The following conditions were observed throughout:

- (1) thickness of preparation never above 400 μ;
- (2) dimensions of preparation small;
- (3) preparation richly vascularized;
- (4) outside opacified vascular bed, x-ray absorption kept to a minimum.

When the ideal values of the variable elements are contradictory, a compromise must be adopted observing the following conditions:

- (1) the monochromatic radiation should have a large wave-length;
- (2) its intensity should be as great as possible compared with the continuous spectrum, to take advantage of the characteristic radiation and to keep the exposures as short as possible;
- (3) the focal distance should be as short as is compatible with sufficient field coverage and acceptable geometrical diffusion.

The first two conditions are respected when $V=2V_0$, V =actual voltage, and V_0 =lowest voltage for characteristic line. In this case, $V=12.8$ KV. In these conditions, with a current of 18 mA and a focal distance of 13.5 cm, the length of exposure varies from 2 to 5 minutes.

Calculation of the geometrical projection makes it possible to evaluate the relative importance in the picture of shadow (U) and dimness (P) as in Fig. 3:

$$U = \frac{a \cdot d - b \cdot f}{a - b} \quad \text{and} \quad P = \frac{b}{a - b} f.$$

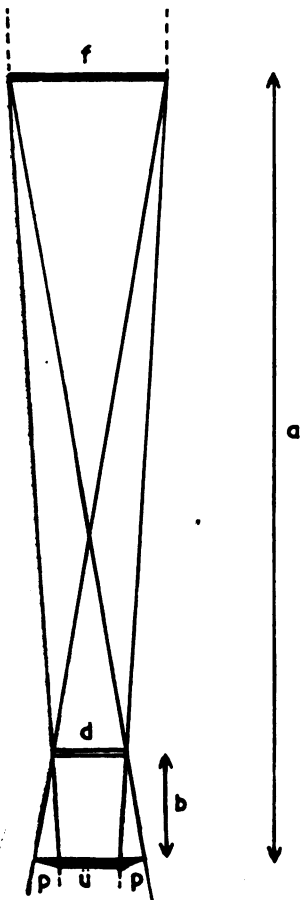


FIG. 3.—Diagram illustrating calculation of U (shadow) and P (dimness).

These formulae show that the picture-size is slightly smaller than the object itself while the dimness is practically negligible.

Results

The horizontal and parasagittal sections are exactly identical and present a picture of rectangles, squares, or more rarely irregular circles; their size depends on the relative length of the collateral branches of the vessels running in an antero-posterior direction.

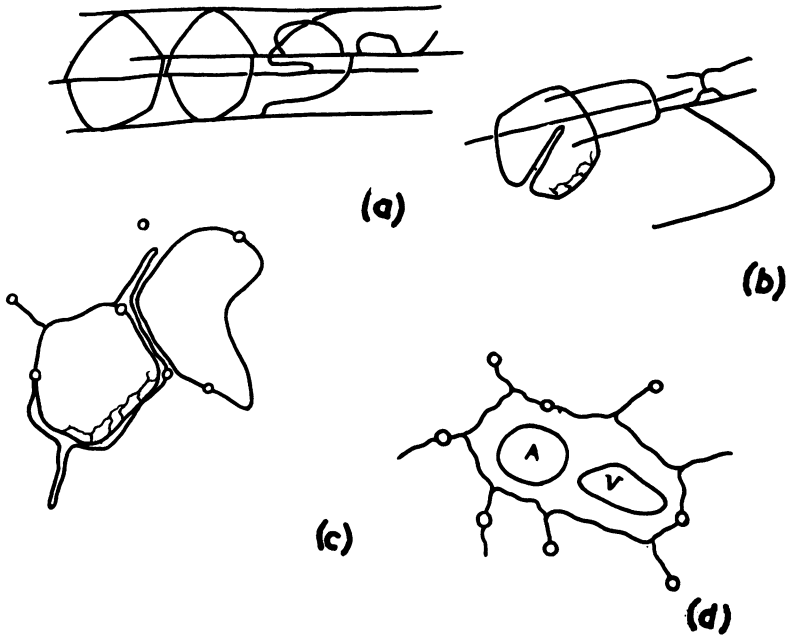


FIG. 4.—Scheme of vascular patterns in optic nerve:
 (a) Building up of pentagons from L.C.U.
 (b) Splitting of L.C.U. and structure of circular unit.
 (c) Structure of circular unit in transverse section.
 (d) Nutrition of central retinal artery and vein

Two definite types of unit (Fig. 4) were found to compose the vascular pattern of the optic nerve:

(1) *Transverse*.—These have a pentagonal form, and encircle the nerve-bundles as complete or incomplete rings over its whole length at regular distances (Fig. 5, opposite).

This circular unit should be compared with the arterial circle of Zinn, with the distinction that the latter serves the whole nerve, the former only part of a single bundle.

(2) *Longitudinal*.—These run in an antero-posterior direction, and all branches responsible for further vascular patterns disposed between different bundles in the interfascicular spaces derive from them. They may be called longitudinal capillary units (L.C.U.) (Fig. 6, opposite).

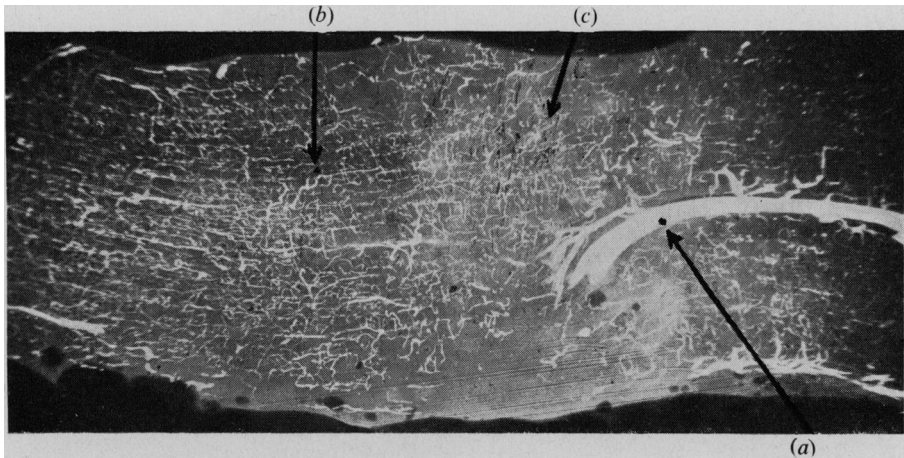


FIG. 5.—Or. $\times 12$. Anterior. Longitudinal section.
 (a) Right, central artery and vein superimposed.
 (b) Quadrangulated form.
 (c) Curved vessels.

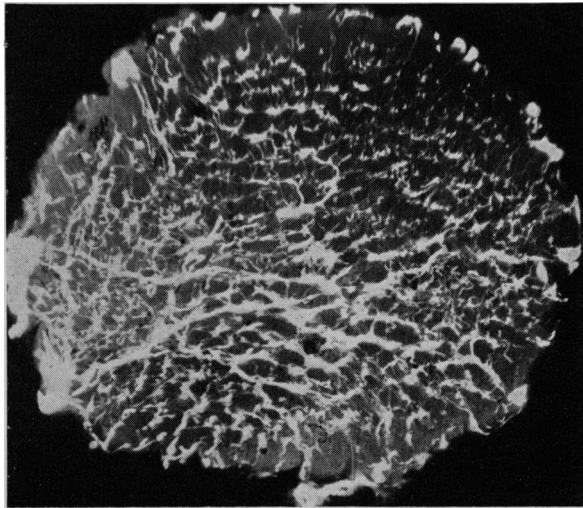


FIG. 6.—Or. $\times 22$. Posterior part. Transverse section (slightly oblique). Meshes a little wider centrally.

These structures may not all be situated in the same perpendicular plane.

The arteries which enter the optic nerve arise from the pial network where they anastomose frequently to build up a plexus. Hence they give off capillaries, and these, branching dichotomously at first, irrigate the optic nerve-fibres, forming L.C.Us. Other arteries penetrate into the optic nerve at the arteriole stage, and, running to the centre, give rise to collateral vessels (L.C.Us) which anastomose with capillaries from the pial network.

The most important of these arteries, the central artery of the optic nerve, does not branch off haphazardly, but participates in building up regular vascular units.

These arteries do not subdivide progressively, but undergo a rapid transition to the capillary stage. This, like the choroidal circulation, recalls the

embryological development of the optic vessels, the abrupt transition to the arterioles indicating that the capillary network developed before the different arteries existed, the hyaloid artery having no nutritive connection with the optic pathway.

The collateral vessels from the L.C.U. may vary in length; they may anastomose with other collaterals from other L.C.U.s and then form a pentagon (Fig. 6).

After running longitudinally close to the L.C.U., the collateral vessel derived from another L.C.U. may bend at right angles and return to the same L.C.U., or it may pass beyond one pentagon and help in constructing other pentagons further on (Figs 7 and 8).




FIG. 7.—Or. $\times 32$. Middle. Longitudinal section. Regular network.
 (a) Large transverse veins.
 (b) Quadrangulated appearance of meshes.
 (c) Different L.C.U. in single space.

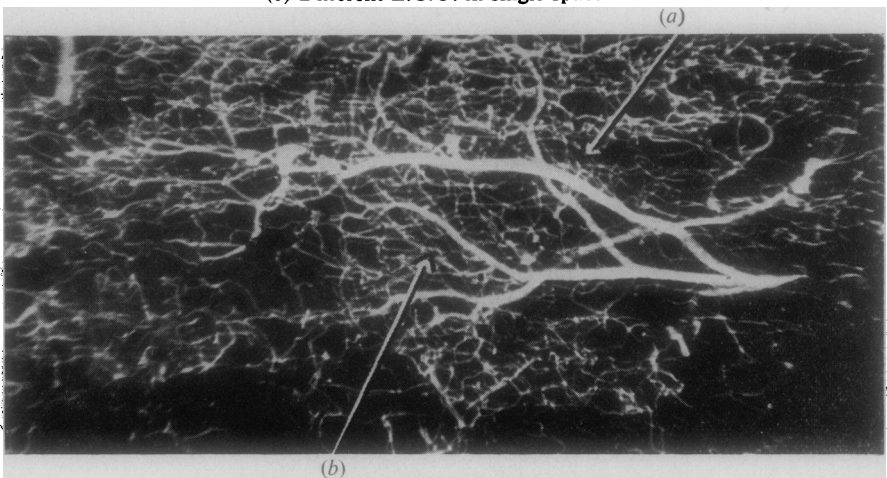


FIG. 8.—Or. $\times 32$. Posterior. Longitudinal section.
 (a) Posterior branch of central artery of optic nerve.
 (b) Capillary system stream-lined.

The L.C.U. may also give off smaller branches running longitudinally; it may subdivide transversely or longitudinally with no change in calibre, and no anastomosis apparently interrupting the continuity of the vascularization.

Capillaries may also arise from the L.C.U. and curve transversely over one or more bundles like the fingers of a hand; these may combine and other vessels may arise from their union. An L.C.U. may not correspond with the angles of the pentagon, and some structures may arise from the sides.

On the outer side we see oval loops and figures of eight. Both on the outer and inner sides vessels may run parallel to the side of a pentagon and rejoin it after some distance (Fig. 9). The outer collaterals form communicating links between the pentagons, or form one or more sides of new pentagons. Vessels may even be seen to start from an angle and run to the opposite side, dividing the pentagon into two unequal parts. On the inner side, the pentagons may give rise to tiny vessels forming in the centre (Fig. 10).

FIG. 9.—Or. $\times 95$. Middle. Transverse section. Note fine detail of building up of pentagons, forming oval adnexa (arrow) to supply efferent nerve fibres for another bundle. General structure more irregular than in posterior part.

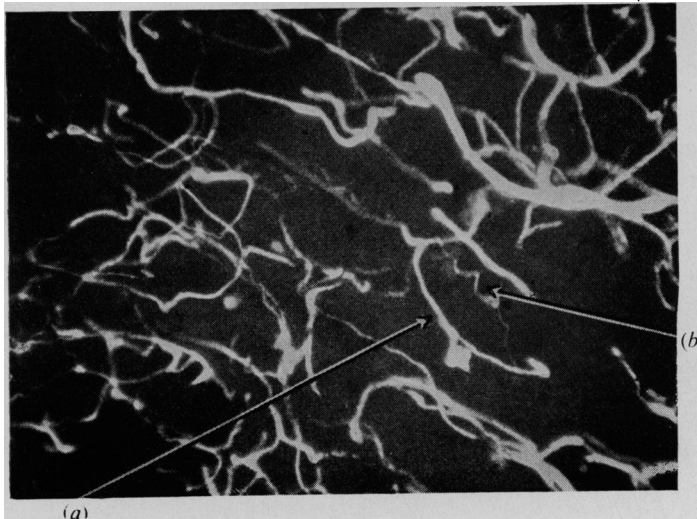
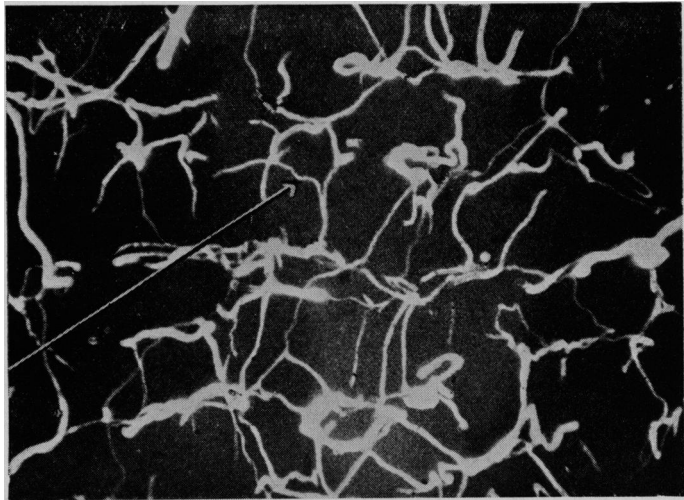


FIG. 10.—Or. $\times 95$. Anterior. Transverse section (oblique).

(a) Curved vessels given off by L.C.U.

(b) Corkscrew capillaries starting from inner side of pentagon.

The pentagons become more circular and the original pattern is progressively lost towards the papilla.

FIG. 11. — Or. $\times 95$. Middle. Longitudinal section. L.C.U.s, circular vascular units, and their collaterals are all tangled together.

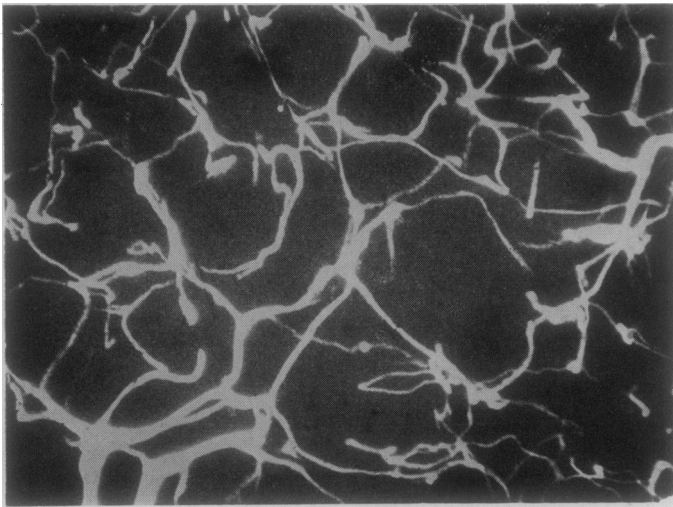
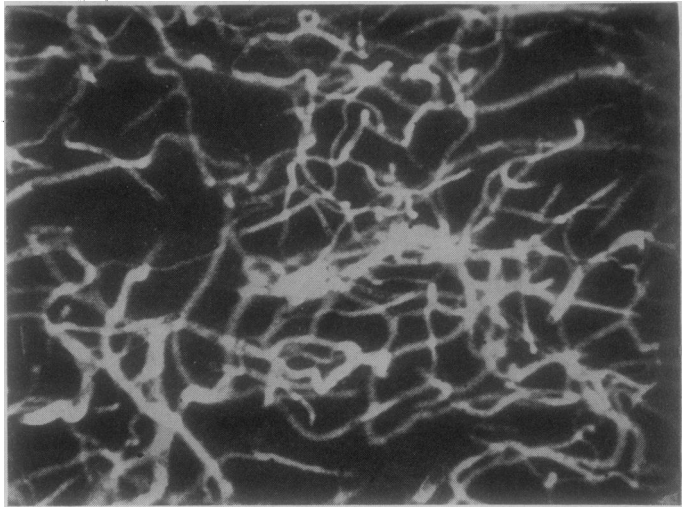


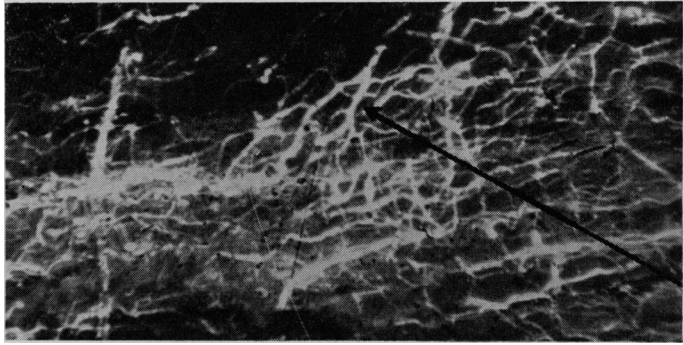
FIG. 12. — Or. $\times 95$. Posterior. Transverse section. Meshes larger.

This vascular pattern corresponds with the nervous tissue structure and the myelo-architecture, confirming the ideas of Leber (1903), Wolff (1948), and Fazio and Farina (1940). The oval capillary meshes appear to surround nerve fibres which leave one bundle and join another, the bundles not being neural units (Behr, 1935).

In the interfascicular spaces, capillaries of different sizes may be found; the large ones are venous return-capillaries, the middle-sized are mostly arteries, and the small ones form a subsidiary nutritional system for the nerve bundles.

At the periphery of the optic nerve the outermost bundles are surrounded by a special vascular ring formed by the pia mater capillary-plexus, by the

FIG. 13.—Or. $\times 65$. Transition of vessels from optic nerve sheath to optic nerve. Characteristic encircling of outer bundles after dichotomous branching (arrow).



penetrating capillaries, and by the branches of the first dichotomously dividing vessels (Fig. 13). At the centre of the optic nerve, the network seems to be a little denser. The description of these structures is most typical of the middle third of the intra-orbital portion of the optic nerve (Figs 7-11).

Approaching the lamina cribrosa the capillaries become tortuous, corkscrewed, and curly, and they wind spirally into the optic nerve itself. (Fig. 14).

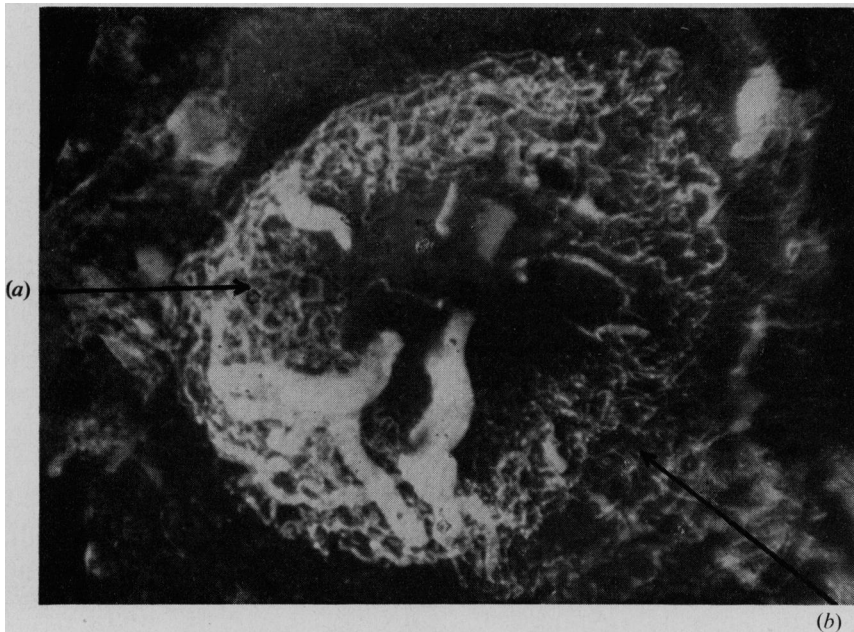


FIG. 14.—Or. $\times 48$. Papilla, lamina cribrosa, and central retinal vessels.
(a) Heavily curled appearance, centre constituting physiological excavation
(b) Transition of vessels from circle of Zinn to lamina cribrosa.

At the lamina cribrosa this subdivision is no longer seen. Many other capillary branches (probably deriving from anterior ramifications of the central artery of the optic nerve, and from vessels of the ciliary system)

create a very dense, tortuous network. The nerve bundles are reduced to single fibres, and numerous tiny capillaries by irregular anastomoses form minute meshes, passing between and surrounding the nerve fibres.

In contrast with the middle third, the network is not so rich, and towards the papilla at the region of the physiological excavation the capillaries disappear. In the periphery the capillaries are larger, and form a lace-like pattern winding round in multiple anastomoses. Between the curves of these arabesques pass even finer capillaries leading straight to the retinal circulation.

In the posterior part of the optic nerve, the meshes are equally wide in the periphery and centre and the collateral vessels of the L.C.Us are fewer. Larger arterioles come from the sheaths and penetrate into the optic nerve. The meshes are wider than in the middle third, and less tortuous (Fig. 12). The vascularization becomes gradually less dense from the papilla to the optic foramen, as more single fibres aggregate into bigger bundles.

In the interfascicular spaces, the vessels are surrounded by glial cells: there is little opportunity for such contraction as occurs in the bone capillaries. When enucleation is performed, the optic nerve should be sutured and afterwards sectioned between the globe and the ligature.

The nutrition of the central retinal artery and vein is maintained by the transverse and longitudinal sections of the pentagons situated in their immediate neighbourhood. This sometimes leads to these being mistaken for collaterals of the central retinal artery, *which do not in fact exist*; none of our injections into the central retinal artery alone showed any branch in its intraneural part. If the central retinal artery does give off a few fortuitous branches at the level of the lamina cribrosa, they are destined to reach the retina and papilla and *not* the optic nerve. The retina, in the immediate neighbourhood of the papilla, contains capillaries from the L.C.Us of the optic nerve and from twigs of the central retinal artery, the remains of supernumerary embryonic buds, which all anastomose with the retinal capillaries; thus anastomoses between the retinal system and the optic nerve system may occur in the retina but *not* in the optic nerve, and *not by transverse branches* deriving from the circle of Zinn.

The situation of the central retinal artery and of the lamina cribrosa is to be discussed in a forthcoming paper.

The return of the venous blood is very important in the optic nerve and its sheaths. The venous capillaries start from the circular transverse units and rapidly develop into larger vessels, entering the central retinal vein or a larger venous channel further back.

All the collecting veins run transversely, whereas the arterial supply runs mainly in a longitudinal direction. The parting and rejoining characteristic of the veins in the choroidal circulation, also of ciliary origin, are seen in the vascular system of the optic nerve. The venous return by way of the pial network is less important.

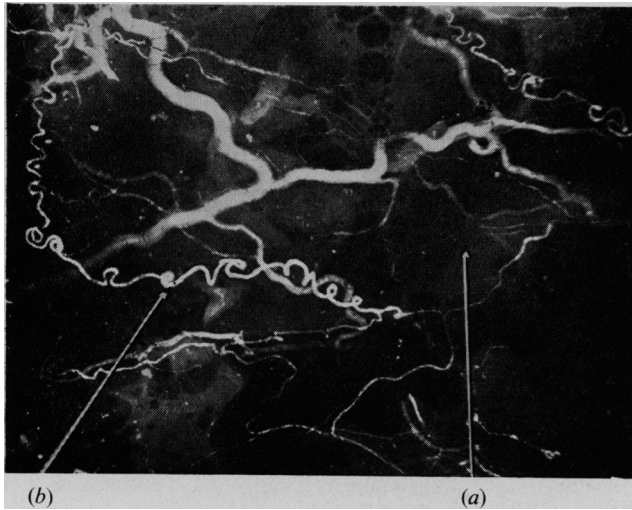


FIG. 15.—Or. $\times 13$. Types of vessel found in sheath.
 (a) Fine cobweb.
 (b) Irregular network.

In the optic nerve *sheaths* (Fig. 15), only the dural and arachnoidal sections will be discussed, because the pial plexus intimately attached to the optic nerve is described with the latter.

The vessels bifurcate here in different ways. The arterioles anastomose frequently, winding spirally, and building up wide meshes round the optic nerve, perpendicular to the meshes of the nerve bundles. The larger vessels do not anastomose before entering the optic nerve, but numerous smaller vessels deriving from them form regular cobweb-meshes after anastomosis. The arteries produce the most bizarre patterns, winding forwards and doubling back, forming twists, double spirals, and corkscrew meanders, their width diminishing as they approach the pial vessel plexus.

Before entering the optic nerve, the vessels curve away from it to form anastomosing capillaries. The larger diameter of the irregular oval meshes lies in the longitudinal direction.

These highly complicated bifurcations, splittings, twistings, and dilatations form an intricate maze which may become very important during inflammatory or mechanical obstructions of the circulation.

Arteriovenous anastomoses or shunts have nowhere been encountered.

Summary

After the injection of Heyden thorotrast into the vessels of the optic nerve, micro-angiograms were made of transverse and horizontal slides (thickness 250-400 μ).

The existence of two basic vascular patterns has been established :

(a) *Transverse*, having the form of a pentagon, encircling single nerve bundles at regular distances.

(b) *Longitudinal*, running in the interfascicular spaces in between the bundles from front to back.

The latter pattern builds up the circular pentagons. Collateral vessels branching off from these two vascular units create an apparently inextricable capillary meshwork. All the vessels contributing to the vascularization of the optic nerve anastomose in a very intimate manner.

The venous blood returns chiefly through the central retinal vein.

In the optic nerve-sheath, where special forms of vessels may be observed, the capillary network is composed of fine cobweb-like formations and large irregular meshes.

REFERENCES

- BARCLAY, A. E. (1951). "Micro-arteriography". Blackwell, Oxford.
- BEHR, C. (1935). *v. Graefes Arch. Ophthalm.*, **134**, 227.
- BELLMAN, S. (1953). *Acta radiol. (Stockh.)*, Suppl. 102.
- and ENGSTRÖM, A. (1952). *Ibid.*, **38**, 98.
- BOHATYRITSCHUK, F. (1944). *Ibid.*, **25**, 351.
- BRASSEUR, H. (1945). "Les rayons X et leurs applications". Desoer, Liège.
- COLLETTE, J. M. (1953). *J. belge Radiol.*, **36**, 293.
- EISLER, P. (1930). "Kurzes Handbüch der Ophthalmologie", vol. 1, ed. F. Schieck and A. Brückner. Springer, Berlin.
- ENGSTRÖM, A. (1949). *Acta radiol. (Stockh.)*, **31**, 503.
- (1951). *Ibid.*, **36**, 305.
- and WEGSTEDT, L. (1951). *Ibid.*, **35**, 345.
- FAZIO, C., and FARINA, P. (1940). *Riv. oto-neuro-oftal.*, **17**, 38.
- FRANÇOIS, J., and NEETENS, A. (1954). *British Journal of Ophthalmology*, **38**, 472.
- LEBER, T. (1903). In "Graefe Saemisch-Handbüch der gesamten Augenheilkunde", 2nd ed., vol. 2., abt. 2. Engelmann, Leipzig.
- MAGITOT, A. (1908). "Contribution à l'étude de la circulation artérielle et lymphatique du nerf optique et du chiasma", vol. 2, p. 3. Thèse de Paris, No. 228.
- TIRMAN, W. S., CAYLOR, C. E., BANKER, H. W., and CAYLOR, T. E. (1951). *Radiology*, **57**, 70.
- WOLFF, E. (1948). "The Anatomy of the Eye and Orbit", 3rd ed. Lewis, London.