

CASE REPORTS

Spontaneous carotid artery dissection presenting as migraine—a diagnosis not to be missed

Zul Mirza, Philip Hayward, Diana Hulbert

Abstract

Two cases are reported in which the diagnosis of a serious condition was delayed as the symptoms had been attributed to migraine. Spontaneous carotid artery dissection is a serious but treatable cause of headache that may be misdiagnosed as recent onset migraine. The importance of correctly identifying this condition is emphasised.

(*J Accid Emerg Med* 1998;15:187-188)

Keywords: carotid artery dissection; migraine; headache

The presence of severe, often hemicranial headache, nausea, or vomiting associated with photophobia or phonophobia may lead to a diagnosis of migraine in the absence of other signs, particularly pyrexia or neck stiffness.

Case 1

A 39 year old quantity surveyor presented to the accident and emergency (A&E) department with a three week intermittent history of unilateral frontal headache, visual loss, nausea, vomiting, slurred speech, and left arm weakness. He had had identical symptoms one month previously lasting two to three hours with spontaneous resolution, and a diagnosis of migraine was quite reasonably made by his general practitioner, who prescribed Paramax (paracetamol and metoclopramide).

The presenting episode lasted two hours. There was no history of trauma to the head or neck. He had previously been well and was not on any drugs. No abnormality was found on a detailed neurological examination.

He was discharged home and then represented on a further two occasions with identical symptoms and on each occasion a detailed neurological examination was normal. Again a diagnosis of migraine was made and it was felt that outpatient follow up was appropriate.

Ten days after the initial presentation he reattended the A&E department. On this occasion there was objective left arm weakness and he was admitted to hospital. Magnetic resonance imaging (MRI) showed right cerebral hemisphere infarctions and a carotid Doppler and carotid angiograms confirmed that these changes were due to right internal carotid artery dissection with thrombosis (fig 1, A and B).

He received inpatient anticoagulation and the symptoms resolved within 24 hours. He remained asymptomatic two months later.

Case 2

A 27 year old woman had been on an alcoholic binge. The following morning she awoke with a frontal headache and some discomfort in her neck. These symptoms resolved with simple analgesia. The same evening as she was leaning back in her chair extending her neck she suddenly developed paraesthesiae in the left arm and leg. As she got up to walk she limped on her left leg. After two hours she developed a left facial droop and slurred speech. She then attended the A&E department, by which time her symptoms had resolved and a thorough examination was entirely normal.

A diagnosis of migraine was made in the A&E department and she was referred to the neurology outpatient clinic. Once again no signs were detected on clinical examination but an MRI scan of the brain and neck showed a dissection of the right internal carotid artery. There were also two areas of infarction in the right cerebral hemisphere. She was admitted, anticoagulated, and subsequently remained well.

Discussion

Carotid artery dissection is well described after trauma to the neck and in some cases may occur even after relatively minor injury.¹ With modern diagnostic techniques it has been recognised more often and is now known to be a common cause of stroke in the young. Our patients could not recall an injury and thus it was presumed that the dissection was spontaneous.

Non-traumatic cases of carotid artery dissection are increasingly recognised.²⁻⁶ Carotid artery dissection typically presents with fronto-temporal (61%) or hemicranial (23%) headache, 91% being ipsilateral to the dissection. Neck pain is found in 26% and there are fluctuating neurological symptoms and signs. This type of dissection may be completely asymptomatic despite complete occlusion of the lumen because of the collateral circulation provided by the circle of Willis.

Alternatively there may be recurrent transient neurological disturbance in the form of a "stuttering hemiplegia" or the condition may present as epilepsy. Other presenting features

Department of
Accident and
Emergency Medicine,
West Middlesex
University Hospital,
Isleworth, Middlesex,
UK
Z Mirza
D Hulbert

Department of
Accident and
Emergency,
St Mary's Hospital,
London W2, UK
P Hayward

Correspondence to:
Dr Z Mirza, specialist
registrar in A&E medicine,
West Middlesex University
Hospital, Twickenham Road,
Isleworth, Middlesex
TW7 6AF, UK.

Accepted for publication
15 December 1997

include homonymous hemianopia, aphasia, and hemiplegia without any warning. Unusually, as in our cases, patients may present with a clinical syndrome that is misinterpreted as migraine.

On examination up to 45% may have no neurological signs initially.⁷ There may be tender carotid arteries, a pulsatile mass, palpable thrill over the carotids, a reduction in pulsation of the internal carotid artery (palpable in the tonsillar fossa), a carotid bruit (10%), or a Horner syndrome (35%).¹

Carotid artery dissection can present with signs and symptoms indistinguishable from recent onset migraine. However, it is unusual for migraine to start after the age of 30 years. It is potentially dangerous to diagnose migraine in the presence of neurological symptoms and signs, and even hemiplegic migraine carries a significant morbidity in that the neurological deficit may become permanent. Migraine should be a positive diagnosis with a previous history, and if possible a family history, and migrainous headaches should be of reasonably short duration, rarely lasting longer than three days.⁸

Subarachnoid haemorrhage also needs to be considered in the differential diagnosis. Subhyaloid haemorrhages, neck stiffness, photophobia, and most importantly a sudden headache are characteristic features. Computerised tomography (CT) may confirm this diagnosis, but a lumbar puncture may be necessary in the

case of a negative scan; this should ideally be performed more than 12 hours after the onset of the headache, when xanthochromia is more likely to be demonstrated.

INVESTIGATIONS

CT may show cerebral infarction and is a good guide to the prognosis. (The mortality rate is reputed to be 47% if a cerebral infarct is demonstrated, compared to zero with a normal CT.)⁹ If the diagnosis is suspected, the patient should have either a carotid Doppler study or a magnetic resonance angiogram.

Carotid Doppler is an extremely useful screening technique which in the recent past has been underused, but has the limitation of not visualising the distal extracranial and intracranial internal carotid arteries.

TREATMENT

Until recently the treatment of carotid artery dissections had been controversial. It was previously thought that early surgery was most appropriate,¹⁰ but this aggressive approach has now undergone reappraisal owing to a high incidence of perioperative stroke and later reocclusion.¹ Anticoagulation is now preferred. Early diagnosis is important as the sooner anticoagulation can be instituted the better the prognosis.

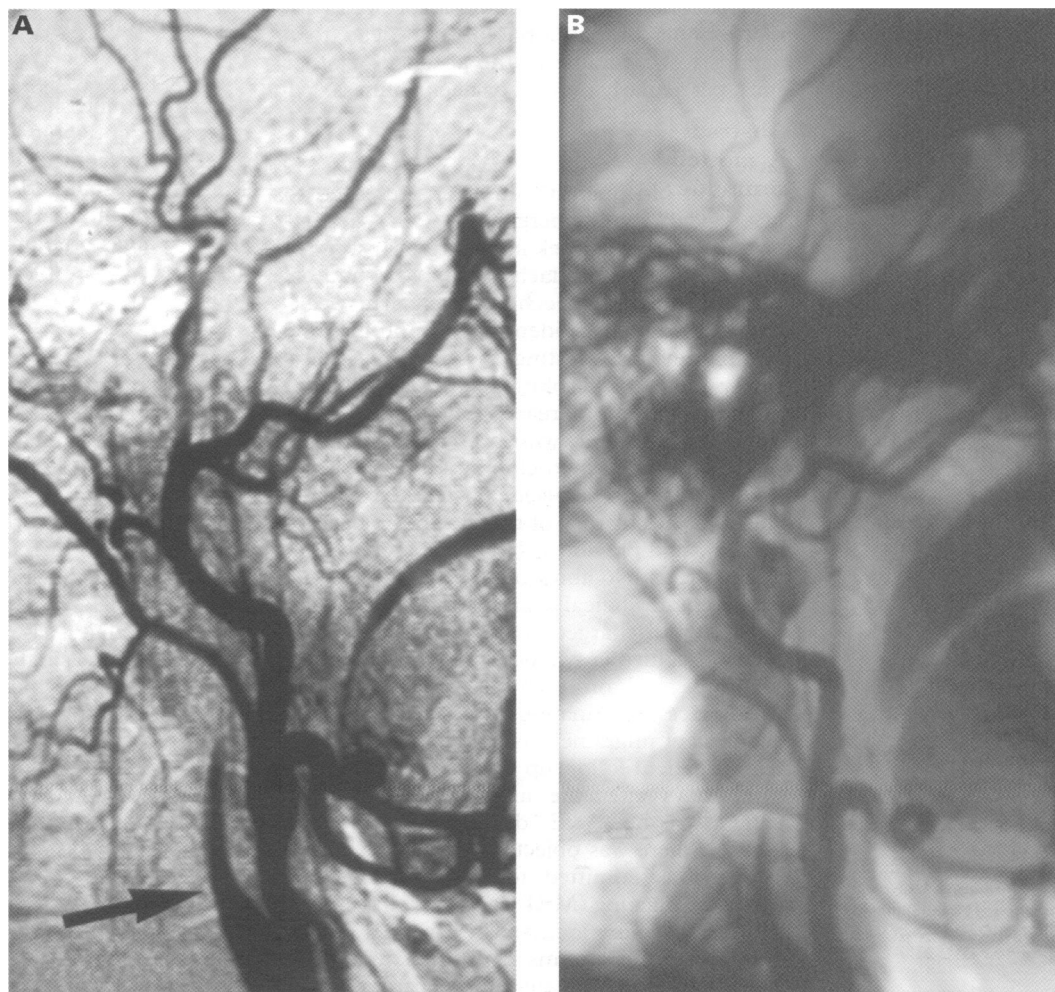


Figure 1 Carotid angiograms from case 1 showing internal carotid artery dissection with thrombosis (arrowed).

CONCLUSION

The diagnosis of carotid artery dissection should be considered in those patients presenting to the A&E department with a migraine-like syndrome (that is, with the characteristic findings of a hemicranial headache, nausea, vomiting, photophobia, and phonophobia) but with atypical features such as recent onset, age over 30 years, and no family history. Other features increasing the likelihood of a carotid artery dissection are a history of neck trauma, which may be very minor, and a sudden onset of neurological symptoms and signs occurring over a few seconds (migraine usually evolves over a period of minutes or focal neurology persists). However, it is quite possible that a small percentage of patients with carotid artery dissection will present with features indistinguishable from migraine.

It is important to consider spontaneous carotid artery dissection in appropriate cases if this serious and treatable condition is not to be missed.

The support and encouragement provided by Dr M W Beckett FRCP, consultant in A&E at the West Middlesex University

Hospital, and Dr P Bain MD, MRCP, consultant neurologist at the West Middlesex University Hospital and Charing Cross Hospital is greatly appreciated throughout the preparation of this paper.

- 1 Cogbill TH, Moore EE, Meissner M, Fischer RP, Hoyt DB, Morris JA, *et al*. The spectrum of blunt injury to the carotid artery: a multicenter perspective. *J Trauma* 1994;37:473-9.
- 2 Patel H, Smith R, Garg B. Spontaneous extracranial carotid artery dissection in children. *Pediatr Neurol* 1995;13:55-60.
- 3 Silbert P, Mokri B, Schievink W. Headache and neck pain in spontaneous internal carotid and vertebral artery dissections. *Neurology* 1995;45:1517-32.
- 4 Sturzenegger M. Spontaneous internal carotid artery dissection: early diagnosis and management in 44 patients. *J Neurol* 1995;242:231-8.
- 5 Schievink W, Mokri B, O'Fallon M. Recurrent spontaneous cervical artery dissection. *N Engl J Med* 1994;330:393-7.
- 6 Duyff R, Snijders CJ, Vanneste JAL. Spontaneous bilateral internal carotid artery dissection and migraine: a potential diagnostic delay. *Headache* 1997;37:109-12.
- 7 Li MS, Smith BM, Espinosa J. Nonpenetrating trauma to the carotid artery: seven cases and a literature review. *J Trauma* 1994;36:265-72.
- 8 Fodden DI, Peatfield RC, Milsom PL. Beware the patient with a headache in the accident and emergency department. *Arch Emerg Med* 1989;6:7.
- 9 Davis JW, Holbrook TL, Hoyt DB, Mackersie RC, Field TO, Shackford SR, *et al*. Blunt carotid artery dissection: incidence, associated injuries, screening and treatment. *J Trauma* 1990;30:1514-17.
- 10 Perry O, Snyder WH, Thal ER. Carotid artery injuries caused by blunt trauma. *Ann Surg* 1980;192:74-7.

Late clotted haemothorax after blunt chest trauma

Priyankar Sinha, Pradip Sarkar

Abstract

A clotted haemothorax can develop any time after blunt chest trauma. Two cases are described in which late clotted haemothoraces developed which were treated by limited thoracotomy and evacuation of clots. Late clotted haemothorax may occur even in the absence of any abnormal initial clinical findings. Early detection and treatment is important to avoid the complications of fibrothorax and empyema with permanent pulmonary dysfunction. After blunt chest trauma patients should be advised to return to the accident and emergency department for assessment on development of any new chest symptom. Under these circumstances a chest x ray is mandatory to exclude a haemothorax.

(*J Accid Emerg Med* 1998;15:189-191)

Keywords: blunt chest injury; clotted haemothorax; thoracotomy

After blunt chest injury, a clotted haemothorax may be present at the time of initial consultation or develop a few days later, either in the hospital or after discharge. Occasionally they are discovered when the patient seeks medical advice for further respiratory symptoms, but some remain totally asymptomatic.¹ Fibrothorax and empyema with permanent pulmonary

dysfunction and disability are the complications of an untreated late clotted haemothorax.¹ Early detection and surgical evacuation of the clots can achieve excellent results with preservation of pulmonary function.²⁻⁶ We present our clinical experience in two such cases.

Case 1

A healthy 75 year old man suffered fractures of the left third to eighth ribs after a fall from a height. Except for the rib fractures, the initial clinical and radiological investigations were normal. Four days later on the medical wards a haemothorax was noted on a routine chest x ray (fig 1). An intercostal tube drain was inserted which drained the haemothorax partially. The chest drain was resited but failed to drain the chest completely. By this time the patient was breathless and further investigations revealed a collapsed lower lobe of the left lung with a large clotted left haemothorax.

On the seventh day after his fall, he underwent a limited left thoracotomy and evacuation of the clots in his left chest, thus allowing full re-expansion of the left lung. There was no active bleeding. He had an uneventful recovery and at follow up one month later he was asymptomatic and clinical examination was normal.

Department of
Cardiothoracic
Surgery, North
Staffordshire Royal
Infirmary, Princess
Road, Hartshill, Stoke
on Trent, UK
P Sinha
P Sarkar

Correspondence to:
Dr Priyankar Sinha,
Department of
Cardiothoracic Surgery,
Walsgrave Hospital, Clifford
Bridge Road, Walsgrave,
Coventry CV2 2DX, UK.

Accepted for publication
1 December 1997