

## CONCLUSION

The diagnosis of carotid artery dissection should be considered in those patients presenting to the A&E department with a migraine-like syndrome (that is, with the characteristic findings of a hemicranial headache, nausea, vomiting, photophobia, and phonophobia) but with atypical features such as recent onset, age over 30 years, and no family history. Other features increasing the likelihood of a carotid artery dissection are a history of neck trauma, which may be very minor, and a sudden onset of neurological symptoms and signs occurring over a few seconds (migraine usually evolves over a period of minutes or focal neurology persists). However, it is quite possible that a small percentage of patients with carotid artery dissection will present with features indistinguishable from migraine.

It is important to consider spontaneous carotid artery dissection in appropriate cases if this serious and treatable condition is not to be missed.

The support and encouragement provided by Dr M W Beckett FRCP, consultant in A&E at the West Middlesex University

Hospital, and Dr P Bain MD, MRCP, consultant neurologist at the West Middlesex University Hospital and Charing Cross Hospital is greatly appreciated throughout the preparation of this paper.

- 1 Cogbill TH, Moore EE, Meissner M, Fischer RP, Hoyt DB, Morris JA, *et al*. The spectrum of blunt injury to the carotid artery: a multicenter perspective. *J Trauma* 1994;37:473-9.
- 2 Patel H, Smith R, Garg B. Spontaneous extracranial carotid artery dissection in children. *Pediatr Neurol* 1995;13:55-60.
- 3 Silbert P, Mokri B, Schievink W. Headache and neck pain in spontaneous internal carotid and vertebral artery dissections. *Neurology* 1995;45:1517-32.
- 4 Sturzenegger M. Spontaneous internal carotid artery dissection: early diagnosis and management in 44 patients. *J Neurol* 1995;242:231-8.
- 5 Schievink W, Mokri B, O'Fallon M. Recurrent spontaneous cervical artery dissection. *N Engl J Med* 1994;330:393-7.
- 6 Duyff R, Snijders CJ, Vanneste JAL. Spontaneous bilateral internal carotid artery dissection and migraine: a potential diagnostic delay. *Headache* 1997;37:109-12.
- 7 Li MS, Smith BM, Espinosa J. Nonpenetrating trauma to the carotid artery: seven cases and a literature review. *J Trauma* 1994;36:265-72.
- 8 Fodden DI, Peatfield RC, Milsom PL. Beware the patient with a headache in the accident and emergency department. *Arch Emerg Med* 1989;6:7.
- 9 Davis JW, Holbrook TL, Hoyt DB, Mackersie RC, Field TO, Shackford SR, *et al*. Blunt carotid artery dissection: incidence, associated injuries, screening and treatment. *J Trauma* 1990;30:1514-17.
- 10 Perry O, Snyder WH, Thal ER. Carotid artery injuries caused by blunt trauma. *Ann Surg* 1980;192:74-7.

## Late clotted haemothorax after blunt chest trauma

Priyankar Sinha, Pradip Sarkar

### Abstract

**A clotted haemothorax can develop any time after blunt chest trauma. Two cases are described in which late clotted haemothoraces developed which were treated by limited thoracotomy and evacuation of clots. Late clotted haemothorax may occur even in the absence of any abnormal initial clinical findings. Early detection and treatment is important to avoid the complications of fibrothorax and empyema with permanent pulmonary dysfunction. After blunt chest trauma patients should be advised to return to the accident and emergency department for assessment on development of any new chest symptom. Under these circumstances a chest x ray is mandatory to exclude a haemothorax.**

(*J Accid Emerg Med* 1998;15:189-191)

**Keywords:** blunt chest injury; clotted haemothorax; thoracotomy

After blunt chest injury, a clotted haemothorax may be present at the time of initial consultation or develop a few days later, either in the hospital or after discharge. Occasionally they are discovered when the patient seeks medical advice for further respiratory symptoms, but some remain totally asymptomatic.<sup>1</sup> Fibrothorax and empyema with permanent pulmonary

dysfunction and disability are the complications of an untreated late clotted haemothorax.<sup>1</sup> Early detection and surgical evacuation of the clots can achieve excellent results with preservation of pulmonary function.<sup>2-6</sup> We present our clinical experience in two such cases.

### Case 1

A healthy 75 year old man suffered fractures of the left third to eighth ribs after a fall from a height. Except for the rib fractures, the initial clinical and radiological investigations were normal. Four days later on the medical wards a haemothorax was noted on a routine chest x ray (fig 1). An intercostal tube drain was inserted which drained the haemothorax partially. The chest drain was resited but failed to drain the chest completely. By this time the patient was breathless and further investigations revealed a collapsed lower lobe of the left lung with a large clotted left haemothorax.

On the seventh day after his fall, he underwent a limited left thoracotomy and evacuation of the clots in his left chest, thus allowing full re-expansion of the left lung. There was no active bleeding. He had an uneventful recovery and at follow up one month later he was asymptomatic and clinical examination was normal.

Department of  
Cardiothoracic  
Surgery, North  
Staffordshire Royal  
Infirmary, Princess  
Road, Hartshill, Stoke  
on Trent, UK  
P Sinha  
P Sarkar

Correspondence to:  
Dr Priyankar Sinha,  
Department of  
Cardiothoracic Surgery,  
Walsgrave Hospital, Clifford  
Bridge Road, Walsgrave,  
Coventry CV2 2DX, UK.

Accepted for publication  
1 December 1997

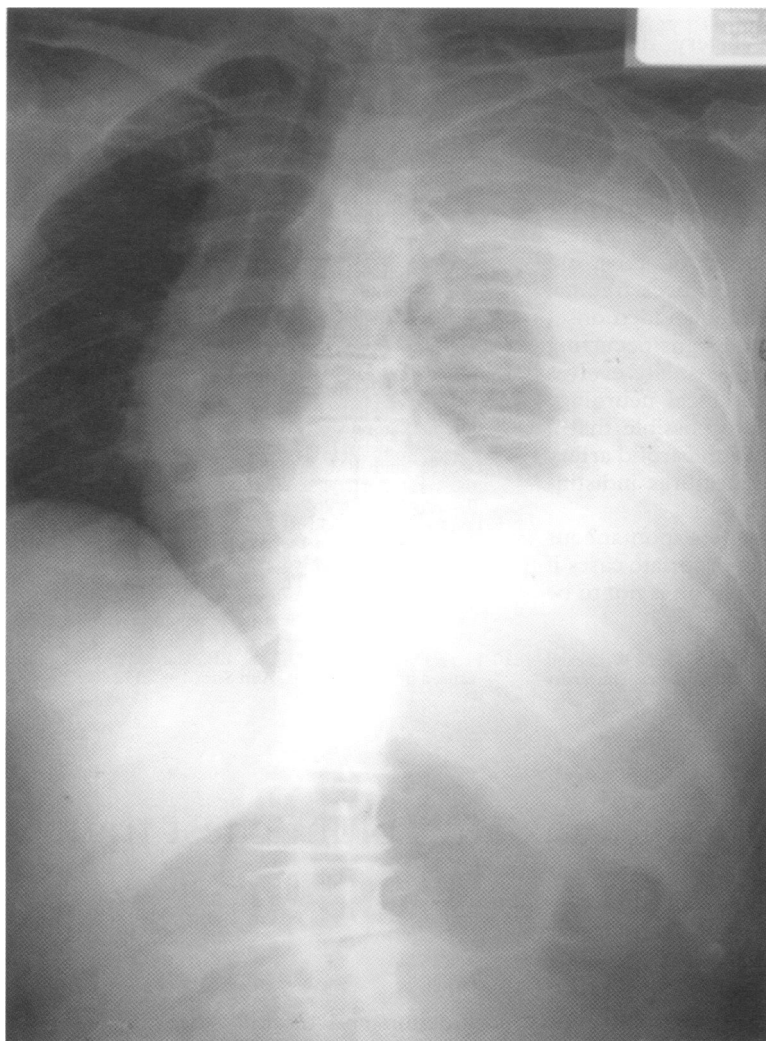


Figure 1 Preoperative x ray showing clotted haemothorax.

### Case 2

A well built 34 year old man suffered fractures to his right eighth and ninth ribs after a fall. When seen in the accident and emergency (A&E) department, no abnormality was detected except for local tenderness and the rib fractures on chest x ray. He was discharged home. He was readmitted as an emergency seven days later with shortness of breath owing to a large right haemothorax. An intercostal tube drain was inserted. This drained 1800 ml of sanguineous pleural fluid but the haemothorax failed to resolve completely. A resited chest drain did not drain any more fluid. Ultrasonography of the chest showed a 1 cm clotted haemothorax between the right lung and the diaphragm with partial collapse of the right lower lobe. He underwent a limited anterior thoracotomy and on evacuation of the clots the right lower lobe expanded fully. There was no active bleeding. He subsequently made an uneventful recovery. On follow up one month after discharge, he was asymptomatic with normal clinical and radiological examination.

### Discussion

A haemothorax may occur after blunt chest trauma. A few such patients with blunt chest injury have normal clinical and radiological features at the first examination. They later

develop a clotted haemothorax days or weeks after the initial event and become symptomatic.

Some authorities feel that if three or more rib fractures are present then a haemothorax is inevitable.<sup>5</sup> A small haemothorax can be reabsorbed completely in a few weeks,<sup>2 3 5</sup> but may also progress to further complications—fibrothorax or infection and empyema<sup>2-5</sup>—in about 3.3% of patients.<sup>3</sup> This can cause significant pulmonary dysfunction, morbidity, and disability. It is therefore imperative to remove the blood from the pleural cavity before it coagulates and fibrin is deposited on the pleural surfaces, leading to an inexpandible lung.<sup>7 8</sup> In the early stages an intercostal tube drain can be effective, but once the blood has clotted this is unsuitable as it only achieves partial drainage.<sup>9</sup> Helling et al have reported an 18% incidence of residual haemothorax following a tube thoracostomy for chest injuries.<sup>10</sup>

The combination of streptokinase and streptodornase has been used for intrapleural fibrinolysis since the 1950s.<sup>8 9 11-18</sup> Reports on the use of these agents have generally been limited to small numbers of patients in the early stages of the haemothorax, and with variable doses. A recent large prospective multicentre study has reported good results.<sup>18</sup> However, enzymatic dissolution can cause fevers, allergic reactions, and prolonged bleeding,<sup>8 11 15 17</sup> though these complications are much less now, with the advent of purified products.

Thoracoscopic evacuation of the retained clots has had variable success.<sup>5 11 13</sup> Thoracoscopic removal is best within 48 to 72 hours of the injury when the clot can be easily disrupted and sucked out. Beyond this period, the clot adheres to the lung and pleura, making thoracoscopic removal difficult.<sup>5</sup> By definition, late clotted haemothoraces present late, with a pleural space filled with clotted blood, and therefore the role of intercostal tube drainage, enzymatic dissolution, or thoracoscopic evacuation is very limited.

An elective thoracotomy and evacuation of the clots is the preferred method of treatment. In our opinion, only open surgery can completely clear the pleural cavity of clots and loculated collections. This allows full re-expansion of the lung. This view has been shared by others.<sup>2 3 5 6 9</sup> Pleural lavage can also be performed. Early elective thoracotomy is also associated with a decrease in hospital stay, morbidity, and mortality, and a reduced incidence of empyema and late decortication.<sup>5 7 11 12</sup> With early evacuation bleeding is decreased and creation of air leaks on the lung surface is minimised.<sup>3</sup> The whole operation can be performed quite easily and satisfactorily through a limited thoracotomy or "mini-thoracotomy."

In conclusion, patients with blunt chest injury and normal clinical and radiological lung findings should be advised to return to the A&E department for reassessment on developing of any new chest symptom. This is important, especially in cases with evidence of bony injury on chest x ray. The need for careful follow up has also been stressed by others.<sup>19</sup>

Under these circumstances a chest x ray is mandatory to exclude a haemothorax. Late clotted haemothorax, once detected, requires an early thoracotomy for complete clearance and best long term results.

We thank Mrs Christina Hill and Mr Farid Khan in their help in preparing this paper.

- 1 Toombs BD, Sandler CM, Lester RG. Computed tomography of chest trauma. *Radiology* 1981;140:733-8.
- 2 Coselli J, Mattox KL, Beall A. Re-evaluation of early evacuation of clotted hemothorax. *Am Surg* 1984;50:21.
- 3 Milfield DJ, Mattox KL, Beall AC. Early evacuation of clotted hemothorax. *Am J Surg* 1978;136:686-92.
- 4 Condon R. Clotted hemothorax. *Surg Gynecol Obstet* 1968;126:505.
- 5 Mancini M, Smith LM, Nein A, Buechter K. Early evacuation of clotted blood in hemothorax using thoracoscopy: case reports. *J Trauma* 1993;34:144-7.
- 6 Feliciano DV. The diagnostic and therapeutic approach to chest trauma. In: Loop FD, McLaughlin JS, eds. *Semin Thorac Cardiovasc Surg* 1992;4:156-62.
- 7 Burford H, Parker EF, Samson PC. Early pulmonary decortication in the treatment of post traumatic empyema. *Ann Surg* 1945;122:163.
- 8 Jones PN. Spontaneous hemopneumothorax: with reference to the use of streptokinase and streptodornase. *Ann Intern Med* 1953;39:907-14.
- 9 McGarry GW. A case of coagulated haemothorax treated by intrapleural Varidase. *Scot Med J* 1988;33:268-9.
- 10 Helling GS, Gyles NR, Eisenstein CL, Sorracco CA. Complications following blunt and penetrating injuries in 216 victims of chest trauma requiring tube thoracostomy. *J Trauma* 1989;29:1367-70.
- 11 Cordice JWV, Cabezon J. Chest trauma with pneumothorax and hemothorax. *J Thorac Cardiovasc Surg* 1965;50:316.
- 12 Maloney JV. The conservative management of traumatic hemothorax. *Am J Surg* 1957;93:533.
- 13 Beall AC, Bricker DL, Crawford HW, Noon GP, DeBakey ME. Considerations in the management of penetrating thoracic trauma. *J Trauma* 1968;8:408.
- 14 Miller JM. Surgical principles involved in the clinical use of streptokinase and streptodornase. *Postgrad Med* 1952;11:188-95.
- 15 Miller JM. The treatment of haemothorax with particular reference to the use of streptokinase and streptodornase. *US Armed Forces Med J* 1952;3:1061-70.
- 16 Sherry S. The use of streptokinase and streptodornase in the treatment of hemothorax. *J Thorac Surg* 1950;20:393-417.
- 17 French SW. Limited thoracotomy and enzymatic therapy in the treatment of early clotted hemothorax. *US Armed Forces Med J* 1958;9:949-56.
- 18 Jerjes-Sanchez C, Ramirez-Rivera A, Elizal de JJ, Delgado R, Cicero R, Ibarra-Perez C, et al. Intrapleural fibrinolysis with streptokinase as an adjunctive treatment in hemothorax and empyema: a multicentre study. *Chest* 1996;109:1514-19.
- 19 Moghissi K. Chest injuries and their management. In: *Essentials of thoracic cardiac surgery*. London: Heinemann, 1986:48-66.

## Out of hospital cardiac arrest and associated injury

Andrew I Jones, M James Stuart, Alastair J Gray

### Abstract

**Three patients are described who sustained injuries around the time of a collapse that led to out of hospital cardiac arrest. In this group of patients the importance of taking a complete medical history and recording the circumstances of the syncopal episode cannot be overemphasised. If cardiac output is successfully restored the possibility of occult traumatic injury must be considered in high risk patients.**

(*J Accid Emerg Med* 1998;15:191-192)

Keywords: cardiac arrest; resuscitation; occult trauma

In the immediate aftermath of a successfully resuscitated out of hospital cardiac arrest the presence of an injury may easily be overlooked. We present three cases which illustrate this point.

### Case 1

A 65 year old male sustained a cardiac arrest in the street. Bystander basic life support was given immediately. The extended trained ambulance crew found him to be in ventricular fibrillation. Defibrillation restored sinus rhythm.

On arrival at the accident and emergency (A&E) department he was drowsy but responding to questions. He remained in sinus rhythm with a systolic blood pressure of 100 mm Hg. He appeared able to move only his shoulder girdle muscles. Bruising to the forehead was noted.

Radiography of the neck showed advanced ankylosing spondylitis with a fracture-dislocation. He was stabilised on the intensive care unit but he died the following day.

### Case 2

A 63 year old male sustained an out of hospital cardiac arrest. A nurse bystander gave basic life support. The attending extended trained ambulance crew found him to be in ventricular fibrillation, and sinus rhythm was rapidly restored by defibrillation. At this stage he was localising to pain and had a Glasgow coma score of 8. Examination at the A&E department showed bruising of his right temple. Radiography of his skull was normal but in view of his persisting reduced level of consciousness computed tomography was performed and showed frontal and temporal contusions. He was subsequently intubated and admitted to the neurosurgical unit. After 10 days he was discharged home.

### Case 3

A 56 year old man suddenly collapsed in the street and was found to be in ventricular fibrillation by the attending ambulance crew. He was immediately cardioverted and cardiac output was restored.

On arrival in the A&E department he was agitated and combative. He was maintaining his own airway and his oxygen saturation was 99% while breathing high flow oxygen. He had