

Inherited Antithrombin-III Deficiency Causing Mesenteric Venous Infarction:

A New Clinical Entity

JAMES C. GRUENBERG, M.D., MAJ. ROBERT C. SMALLRIDGE, M.D., M.C., USAR,* ROBERT D. ROSENBERG, M.D.†

Primary superior mesenteric venous thrombosis is sometimes preceded by peripheral thrombophlebitis. Inherited antithrombin-III deficiency is a recently recognized autosomal dominant trait, which is characterized by thrombophlebitis and pulmonary embolism. This case report illustrates many features of both entities and strongly suggests a causal relationship. While long-term therapy has yet to be established, prophylactic therapy is recommended when asymptomatic individuals with known antithrombin-III deficiency are at increased risk of thrombosis. The efficacy of heparin alone has been unreliable, whereas Coumadin has been encouraging. Antithrombin-III concentrates are being developed and theoretically should be helpful. Patients with thrombophlebitis or pulmonary embolism should be suspected of having antithrombin-III deficiency. Such individuals also represent one mechanism to explain "primary" mesenteric venous thrombosis.

INHERITED antithrombin-III deficiency is a recently recognized entity which presents clinically with thrombophlebitis and pulmonary embolism.³ Infarction of the superior mesenteric vein is considered primary when no concurrent, predisposing condition exists. In two large series of mesenteric vein infarction, 32 and 45% of these patients had a history—sometimes years earlier—of thrombophlebitis.^{9,10}

This report describes a 43-year-old man who had a segmental infarction of the superior mesenteric vein and

From the First Surgical Division, Department of Surgery, Henry Ford Hospital, Detroit, Michigan

a history of thrombophlebitis and a pulmonary embolism. Subsequently he became the propositus in a family with inherited antithrombin-III deficiency. We feel he illustrates one mechanism to explain "primary" mesenteric venous thrombosis.

Case Report

A 43-year-old man (#155 091) was seen initially on 1/7/74 with a 4-day history of right lower chest pain which had spread into the right upper abdomen. His CBC was normal, and arrangements were made to confirm the diagnosis of a mild acute cholecystitis. Thirty-six hours later, his abdominal pain worsened markedly and shifted into the lower abdomen.

Past medical history revealed bilateral simple mastectomies for gynecomastia in 1962. In 1967 he was hospitalized for pneumonia, complicated by bilateral deep leg-vein thrombophlebitis and pulmonary emboli. He was treated with heparin for 2 weeks and Coumadin for 2 months. In 1969 he had another episode of thrombophlebitis.

Physical examination revealed a diaphoretic, obese male in obvious severe pain. His abdomen was obese, soft, silent, and mildly tender in both lower quadrants. Rectal examination revealed normal brown feces, and both legs exhibited painless stasis dermatitis. His blood sugar was 175 mg%, hematocrit 54%, and WBC 14,400 with a mild left shift. Abdominal x-rays revealed an almost gasless abdomen.

Intravenous hydration and antibiotics were begun in preparation for emergency exploratory laparotomy.

Submitted for publication October 24, 1974.

*Department of Internal Medicine, Cutler Army Hospital, Fort Devens, Mass. 01433.

†Assistant Professor of Medicine, Beth Israel Hospital and Howard Medical School, Boston, Mass. 02115

The views expressed by the authors do not necessarily reflect those of the U.S. Army.

Reprint requests: James C. Gruenberg, M.D. First Surgical Division, Department of Surgery, Henry Ford Hospital, 2799 West Grand Boulevard, Detroit Michigan 48202.

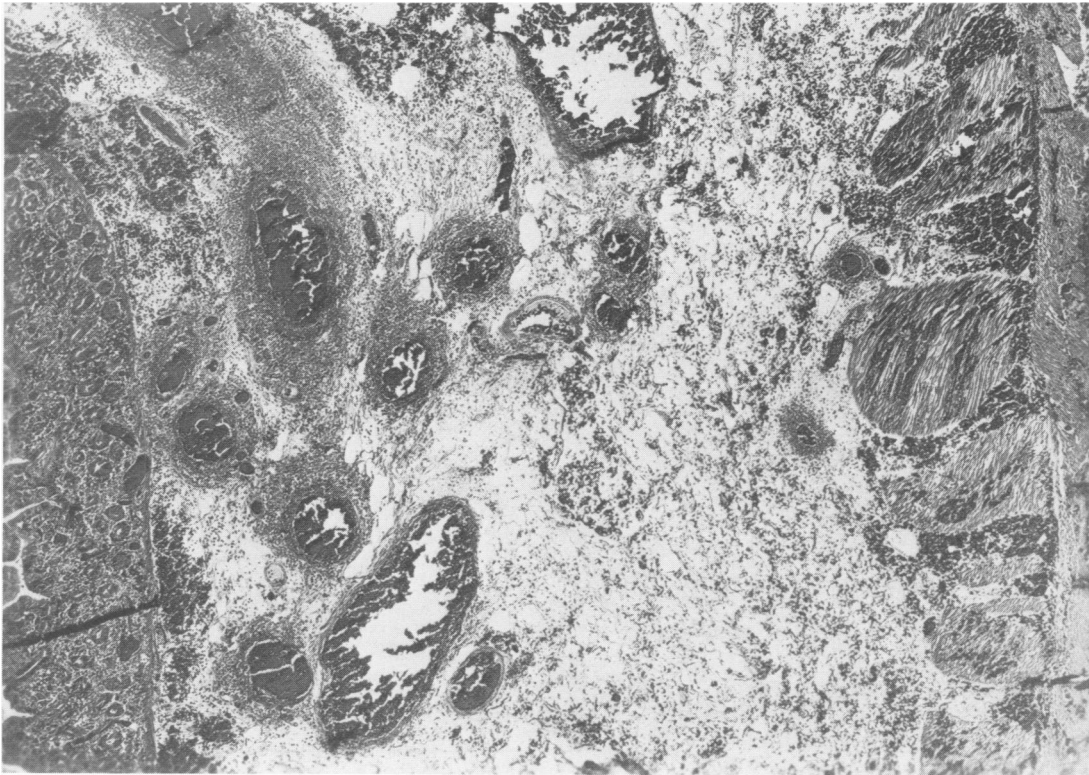


FIG. 1. Hemorrhage and acute inflammation extends through all layers of the small intestine. Severe, acute phlebitis is especially prominent in submucosal veins, and fibrin thrombi are present in mucosal capillaries ($\times 52$).

Operative findings included 1500 cc serosanguinous fluid, a well-demarcated infarction of 85 cm of mid-small intestine, a normal gallbladder, and a diffusely grossly nodular, firm liver compatible with cirrhosis. A 130 cm segmental resection and end-to-end anastomosis of small intestine were carried out.

Thirty-six hours postoperatively his prothrombin time was 14 seconds (control 13 seconds) and partial thromboplastin time was 21.9 seconds (control 31.5 seconds). Intravenous heparin 5,000 μ q4h was initiated. By his 4th postoperative day, he was passing stool and flatus and he was progressed rapidly to a 1500 calorie ADA diet.

Laboratory studies included normal SGOT, bilirubin, alkaline phosphatase, negative LE prep, Bence-Jones protein, antinuclear antigen, cryoglobulins and cryofibrinogen, fibrinogen 300 mg%, platelet count 115,000, IgG 1450 mg% (normal 770-1130), IgA 291 mg% (normal 80-200), IgM 125 mg% (normal 90-170), total serum proteins 8.4 gm% with albumin 48.4% (normal 62-67%), Alpha₁ globulin 3.3% (2.4-4.8% normal), Alpha₂ globulin 15.2% (normal 6.6-13.6%), Beta globulin 13% (9.1-14.7%), and gamma globulin 21.4% (normal 9.0-20.6%).

On his 10th postoperative day, while on heparin and shortly after Coumadin had been initiated, he developed ileofemoral thrombophlebitis of his left leg. This became asymptomatic 5 days later, and he has continued asymptomatic on Coumadin with a prothrombin time which is twice control.

Family History

Antithrombin-III activity of the propositus has ranged from 25% to 31% (normal 85-110%). His daughter (only child) also has antithrombin-III deficiency, while his wife has normal antithrombin-III levels. Currently, plasma from available members of this large family are being examined for antithrombin-III activity. In the absence of consanguinity, an autosomal dominant mode of inheritance is present.

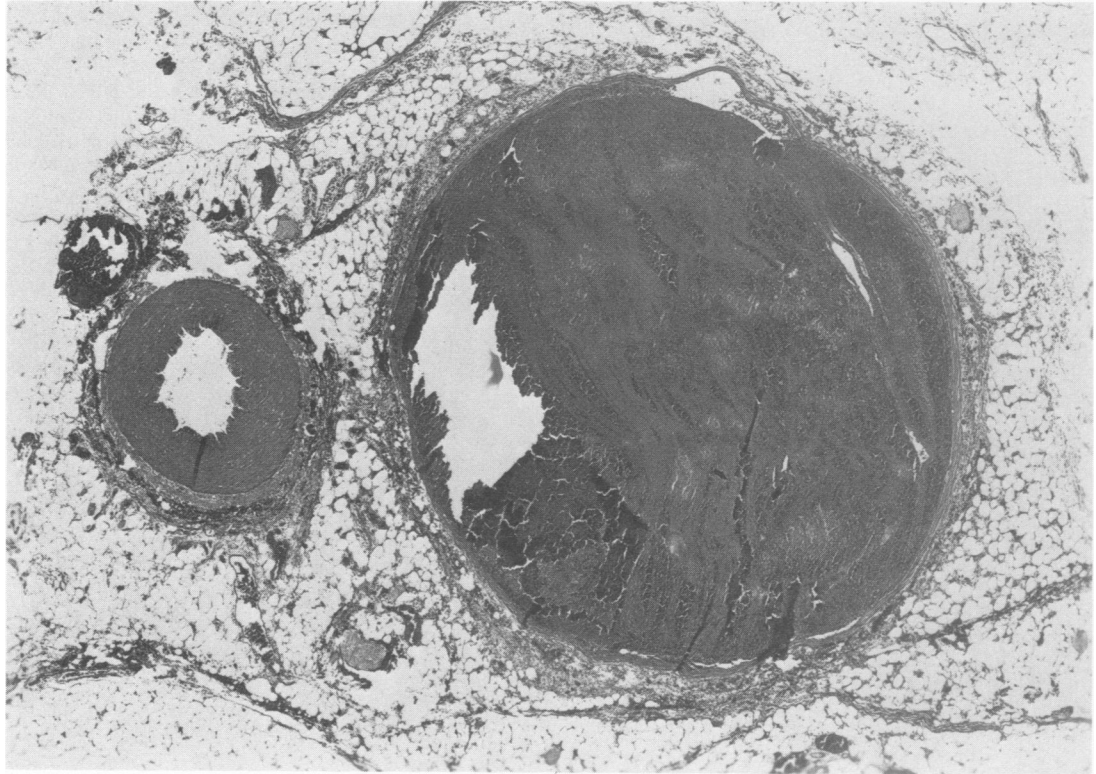
Materials and Methods

Antithrombin-III activity was determined from citrated plasma, using the technique of electroimmunoassay for quantitative analysis of proteins.⁷

Discussion

Since the turn of this century, the activity of thrombin has been known to decrease when exposed to normal serum. This unidentified serum factor was termed "antithrombin."^{12,15} Since then as many as 6 antithrombins have been demonstrated, of which the most important is believed to be antithrombin-III, an alpha-2 globulin of molecular weight 65,000 which is synthesized in the liver.^{12,15} Recently, by electrophoretic and immunoprecipitate biochemical techniques, a 1:1/thrombin: antithrombin-heparin cofactor stoichiometric complex has been demonstrated.¹²

FIG. 2. A large mesenteric vein contains laminations of red cells with fibrin and white cells and exhibits the phlebotic changes present in the previous photomicrograph. The adjacent artery is normal and patent ($\times 18$)



Decreased activity of antithrombin-III has been demonstrated in patients with hepatitis, hepatic cirrhosis, intravascular clotting, shortly after myocardial infarction, venous thrombosis, or pulmonary embolism, and in patients taking estrogen-containing progestational agents.^{1-3,8,15} Increased antithrombin-III activity has been demonstrated in patients with hemophilia, proconvertin deficiency, uremia and congenital or acquired heart disease without hepatic congestion.¹⁵ The significance of the antithrombin-III activity in these situations has yet to be defined.

Of more definite clinical significance is the usual 50% reduction of antithrombin-III activity found in those individuals with inherited antithrombin-III deficiency. Although the usual screening tests for coagulation or fibrinolysis are normal, these people have an increased risk of venous thrombosis of varying severity. These thrombotic episodes generally occur in adulthood and sometimes are associated with conditions having an increased risk of venous thrombosis.^{3,13,14,18}

In vitro testing of plasma and serum of individuals with antithrombin-III deficiency has shown variable resistance to the anticoagulation effect of heparin, and clinical worsening of thrombotic states has been noted on heparin. In view of its variable effect, heparin probably should not be relied upon as the sole agent in treating acute thrombotic or embolic phenomenon. On the other hand, clinical improvement has been noted on oral

prothrombin-depressing agents along with increased or normal levels of anti-thrombin activity.^{1,4,8,15}

While long-term therapy for people with antithrombin-III deficiency has yet to be established, prophylactic therapy definitely should be considered in asymptomatic people with known anti-thrombin deficiency who are in a situation, e.g. elective surgery, post-parturition, where the risk of thrombosis is increased. One possibility is Coumadin employed with care such as not to prolong the prothrombin time beyond twice control. Another possibility is antithrombin concentrates plasmaphoresed from known, high-activity donors. The American National Red Cross currently is developing such a preparation, the half-life of which is yet to be determined.^{16,17}

Earlier reports of mesenteric venous infarction have emphasized the clinical presentation, the significant mortality, the generally segmental intestinal involvement, the importance of wide resection, the tendency of early recurrence, and the importance of postoperative anticoagulation.^{5,9-11} This report illustrates many of these characteristics and demonstrates the autosomal dominant inheritance of antithrombin-III deficiency noted by others.^{3,8,13-15}

Conclusion

People with thrombophlebitis or pulmonary embolism should be suspected of having antithrombin-III deficiency. Such individuals represent one mechanism to explain "primary" mesenteric venous thrombosis.

References

1. Abildgaard, U., Fagerhol, M. K. and Egeberg, O.: Comparison of Progressive Antithrombin Activity and the concentrations of Three Thrombin Inhibitors in Human Plasma. *Scand. J. Clin. Invest.*, 26:349, 1970.
2. Duckert, F.: Behavior of Antithrombin-III in Liver Disease. *Scand. J. Gastroenterol.*, 8, Suppl. 19, 109-112, 1973.
3. Egeberg, O.: Inherited Antithrombin Deficiency Causing Thrombophilia. *Thromb. Diath. Hemor.*, 13:516, 1965.
4. Fagerhol, M. K., Abildgaard, U. and Kornstad, L.: Antithrombin-III Concentration and ABO Blood-Groups. *Lancet*, 2:664, 1971.
5. Jona, J., Cummins, G. M. Jr. and Head, H. B.: Recurrent Primary Mesenteric Venous Thrombosis. *JAMA*, 227:1033, 1974.
6. Jordan, P. H. Jr., Boulafendis, D. and Guinn, G. A.: Factors Other than Major Vascular Occlusion that Contribute to Intestinal Infarction. *Ann. Surg.*, 171:189, 1970.
7. Laurell, C. B.: Electroimmuno Assay, *Scand. J. Clin. Lab. Invest.*, 29, Suppl. 124, 21, 1972.
8. Marciniak, E., Farley, C. H. and DeSimone, P. A.: Familial Thrombosis due to Antithrombin-III Deficiency. *Blood*, 43:219, 1974.
9. Mathews, J. E. and White, R. R.: Primary Mesenteric Venous Occlusive Disease. *Am. J. Surg.*, 122:579, 1971.
10. Naitove, A. and Weismann, R. E.: Primary Mesenteric Venous Thrombosis. *Ann. Surg.*, 161:516, 1965.
11. North, J. P. and Wollenmann, J. O. Jr.: Venous Mesenteric Occlusion in the Course of Migrating Thrombophlebitis. *Surg. Gynecol. Obstet.*, 95:665, 1952.
12. Rosenberg, R. D. and Damus, P. S.: The Purification and Mechanism of Action of Human Antithrombin-Heparin Cofactor. *J. Biol. Chem.*, 248:6490, 1973.
13. Shapiro, S. S., Prager, D., and Martinez, J.: Inherited Antithrombin-III Deficiency Associated with Multiple Thromboembolic Phenomena. *Blood*, 42:1001, 1973.
14. Van der Meer, J., Stoepman-van Dahlen, E. A. and Jansen, J.M.S.: Antithrombin-III Deficiency in a Dutch Family. *J. Clin. Pathol.* 26:532, 1973.
15. Von Kaulla, E. and von Kaulla, K. N.: Antithrombin and Diseases. *Am. J. Clin. Pathol.*, 48:69, 1967.
16. Wickerhauser, M.: Large-scale Preparation of Antithrombin and alpha₁-antitrypsin for Clinical Use, abstracted, International Congress on Thrombosis and Hemostasis, 4th, Vienna, 1973; p. 217.
17. Wickerhauser, M. and Sgouris, J. T.: Development of large-scale Fractionation Methods II. Isolation of a Factor IX Concentrate (Prothrombin Complex) for Clinical Use. *Vox Sang.*, 22:137, 1972.