

# The Anatomic Basis of Parathyroid Surgery

CHIU-AN WANG, M.D.\*

A study of 645 normal adult parathyroid glands in 160 cadavers revealed that there is a definite pattern of anatomic distribution on the basis of the embryologic development of the parathyroid, thyroid, and thymic glands. The sites of predilection of the upper gland (Parathyroid IV) are, in order of frequency, the cricothyroid junction; the dorsum of the upper pole of the thyroid; and the retropharyngeal space. Those of the lower gland (Parathyroid III) are at the lower pole of the thyroid and the thymic tongue; rarely in the upper, the lateral neck, or the mediastinum. An understanding of the developmental relationship of the parathyroid glands to the thyroid and the thymus is fundamental in the delineation of the embryologic origin of the parathyroid glands. The parathyroid gland, located within the surgical capsule of the thyroid (subcapsular), when diseased, remains in place locally. A gland outside of the capsule (extracapsular) is often displaced into the posterior or anterior mediastinum. A collective assessment of the size, weight, color, shape, and consistency of the parathyroid gland is mandatory in the determination of its normalcy. Frozen section examination for stromal and intracellular fatty content is an added assurance of normalcy. That parathyroid glands sink in saline solution, and fat globules float, may aid in differentiating the two types of tissue. Supernumerary, fused, and intrathyroidal parathyroids, albeit rare, are of surgical importance.

THE FOREMOST TASK for the surgeon in parathyroid exploration is localization of the diseased parathyroid gland. Familiarization with the anatomic distribution and characteristic features of the gland under normal conditions is thus essential.

Experience gained from the dissection of 160 cadavers is presented, with special reference to clinical observations made at surgery for hyperparathyroidism.

## Materials and Methods

A total of 645 parathyroid glands were recovered from 160 postmortem subjects of whom 156 had 4, 3 had 5, and 1 had 6 parathyroid glands. Those in whom less than 4

*From the Department of Surgery,  
Massachusetts General Hospital and  
Harvard Medical School, Boston, Massachusetts*

glands were identified were excluded. Within a range of 20 to 80 years, the mean age was 45. There were 95 women and 61 men. In each patient, death had resulted from disease unrelated to parathyroid disorder. None had had chronic renal disease or had been treated over a long period of time with thiazides for hypertension.

The parathyroid glands were obtained by dissection.† Each gland was measured and weighed immediately; its color, shape and consistency were noted; and its position was sketched on a parathyroid chart in relation to such constant anatomic landmarks as the cricothyroid junction, upper pole of the thyroid, thymic tongue, and mediastinal thymus.

## Findings

Twenty-one of the 645 parathyroid glands uncovered were from 4 subjects with supernumerary glands. Data on these glands will be presented separately. Based upon their embryologic derivation, half of the remaining parathyroid glands (312) were classified as the upper (Parathyroid IV) and half as the lower gland (Parathyroid III).

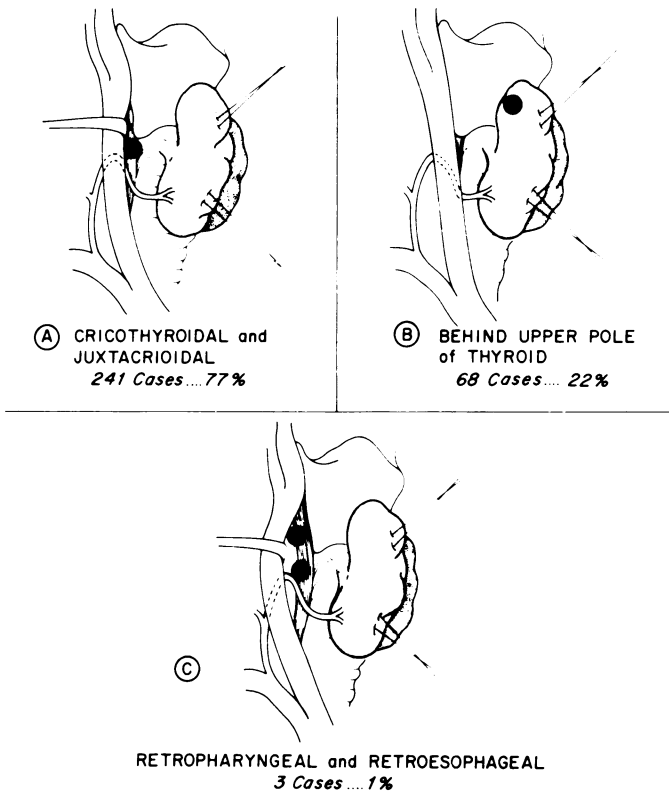
### *Position of the Upper Parathyroid Glands (Parathyroid IV)*

Of the 312 upper parathyroid glands, 241 (77%) were found at the cricothyroid junction posteriorly (Fig. 1a), by far the most common site of Parathyroid IV. Here the

† Dissection was carried out in situ systemically. The tracheoesophageal groove was entered. Search for the parathyroid was begun from the angle of the jaw down to the mediastinum, including the thymus.

Submitted for publication August 15, 1975.

\* Visiting Surgeon, Massachusetts General Hospital; Associate Clinical Professor of Surgery, Harvard Medical School.



FIGS. 1a to c: Anatomic distribution of 312 upper parathyroid glands (Parathyroid IV).

gland was intimately associated with and occasionally hidden by the recurrent laryngeal nerve and the adjacent vascular branches. Most of these glands were suspended by a small pedicle and enveloped by a pad of fatty tissue.

Sixty-eight (22%) of the 312 parathyroids were tucked behind the upper pole of the thyroid (Fig. 1b). In this position, Parathyroid IV was invariably subcapsular, lying underneath the surgical capsule of the thyroid.\* It was readily extruded through the incised capsule. A fine vascular pedicle was noted as coming from the thyroid; none was noted as originating from the capsule. The absence of capsular fixation permits an impressive mobility uniquely characteristic of the parathyroid; a thyroid nodule never moves as freely within the capsule as the parathyroid.

Three Parathyroid IV (less than 1%) were uncovered behind the lower pharyngeal and upper esophageal junction in the midline, encased in a lobule of fatty tissue (Fig. 1c).

#### Position of the Lower Parathyroid (Parathyroid III)

The lower glands (Parathyroid III) were more widely distributed than Parathyroid IV. These glands were dis-

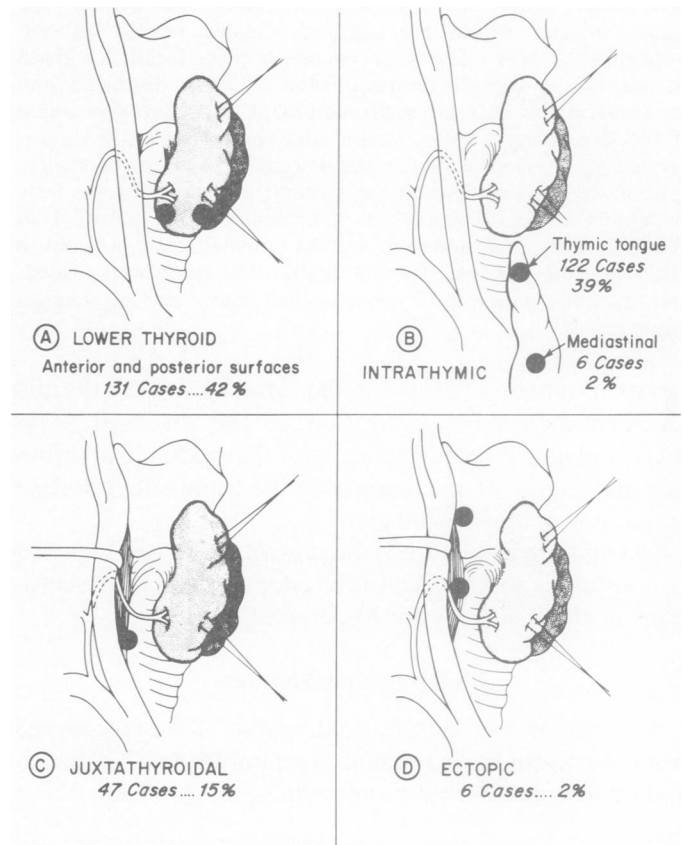
\* Also known as the pretracheal lamina of the cervical fascial sheath.

tributed rather evenly between the lower pole of the thyroid and the thymus. In 131 cases (42%), Parathyroid III was found in an anterior or a latero-posterior surface of the lower pole of the thyroid (Fig. 2a). In these positions, the gland was frequently obscured by vessels or hidden between the thyroid creases. The fact that it was often enclosed in a pad of fatty tissue provides the surgeon with a clue to the identification of the gland.

One hundred and twenty-two Parathyroid III (39%) were located in the lower neck within the thymic tongue, which is a distinct structure at the thoracic inlet, extended from the lower thyroid pole to the mediastinal thymus. Six (2%) were found inside the mediastinal thymus, 3 to 4 cm below the sternal notch (Fig. 2b).

Of the 47 (15%) uncovered some distance lateral to the lower thyroid pole, nearly all were suspended from the vascular tributaries. These glands were invariably embedded in a lobule of fatty tissue (Fig. 2c).

Six (2%) occupied an ectopic position (Fig. 2d). Three were high at the carotid bifurcation and 2 to 3 cm lateral from the upper pole of the thyroid. The other 3 were located in the midthyroid, near but outside of the carotid sheath. All were associated with a small pad of thymic remnant.



FIGS. 2a to d: Anatomic distribution of 312 lower parathyroid glands (Parathyroid III).

### Size, Weight, Color, Consistency and Shape

Stripped of fat, the average parathyroid in this study measured  $5 \times 3 \times 1$  mm. The largest gland was  $12 \times 2 \times 1$  mm and the smallest  $2 \times 2 \times 1$  mm. When the gland was unusually long it tended also to be narrow and thin; conversely, when it was short, it was inclined to be wide and thick.

The average weight of a parathyroid in this series was 35 to 40 mg. It varied somewhat with age and sex, being heavier in the man and in persons between 20 and 30 years of age, and lighter in the woman and in those between 70 and 80. The smallest parathyroid weighed 10 mg and the largest, 78 mg.

The color of the gland ranged from reddish to yellowish tan. In cases of sudden death, as in acute coronary heart disease, the glands were generally reddish brown, possibly as a result of venous stasis. With chronic illness and malnutrition or in the presence of interstitial edema from excessive infusion of fluid, the glands were pale, having a slightly yellowish tinge similar to the color of a lobule of ordinary fat.

The parathyroid gland was soft and pliable in consistency. As a consequence, it was easily shaped and molded by the adjacent tissue. This soft consistency was useful in differentiating a parathyroid gland from a lymph node or a thyroid nodule, both of which were firm and elastic in contrast. On sectioning, the cut surface of a parathyroid was extremely finely granular in texture, similar to that of raw chicken liver.

The inelasticity of the normal parathyroid accounts for its variety of shape and contour (Fig. 3). When the gland was subcapsular, as it was when located at the upper pole of the thyroid, it appeared flattened and resembled a pancake or a leaf. In the cricothyroidal or intrathyroidic position on the other hand, the gland has an oval or spherical shape, such as a teardrop. Occasionally a gland appears to be bean, sausage, or rod-shaped.

A subcapsular gland invariably has a sharp edge; but in an extracapsular parathyroid gland, which was oval or round, there was no sharp edge.

Upon frozen section examination, stromal fat as well as intracellular fatty granules was invariably present in a normal parathyroid. Such fatty content was absent or diminished in a hyperfunctioning gland.

Without exception, a piece of parathyroid tissue sank in normal saline solution, whereas a fatty globule was found to float. This observation serves to differentiate a globule of fat from a parathyroid gland.

### Supernumerary, Fused, and Intrathyroidal Parathyroid Glands

Four subjects had supernumerary glands. Of these, three had 5 and one had 6 glands. In persons with 5 glands, 3 were located in the right side and 2 in the left.

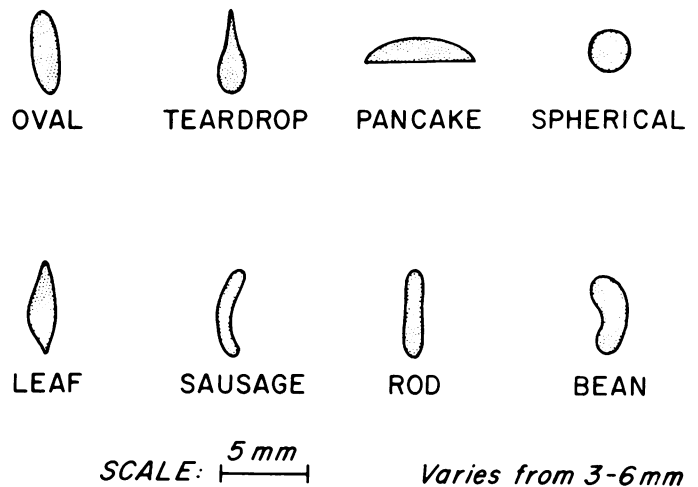


FIG. 3. Variations in shape of normal parathyroid glands.

In the one subject with 6 glands, 3 were located in each side. All these glands were associated with a lobule of thymic remnant. In general they were smaller than the normal glands, being maximally 2 mm in length and 1 mm in width. Fused and intrathyroidal parathyroid glands were not encountered in this study.

### Discussion

The findings just presented are in general agreement with most of the authors cited; but in addition certain anatomic features should be emphasized for their relevance at surgery. I have, therefore, correlated these anatomic findings with clinical observations under the following headings for deliberation.

#### A. Localization and Recognition of the Upper and Lower Parathyroid Gland

This study shows that despite the wide distribution, the parathyroid gland falls into a definite pattern, and can be uncovered in these locations in a great majority of the cases.

Embryologically the upper gland (Parathyroid IV) shares a common primordium in the fourth branchial pouch with the lateral thyroid which subsequently fuses with the lateral wing of the median thyroid.<sup>4,6</sup> It is no wonder, then, that upper parathyroid glands (Parathyroid IV) are invariably found in close proximity to the dorsum of the upper thyroid lobe, either behind the upper pole or at the cricothyroid junction. These are by far the most common positions of the upper parathyroid, although a few of the glands may be located in the retropharyngeal or retroesophageal space.

Similarly, embryologic evidence may be seen in the distribution of the lower parathyroid glands (Parathyroid III). It has been shown that both the lower gland and the thymus arise from the third branchial complex.<sup>4,6</sup> As the complex descends caudally, the lower

gland dissociates from the thymus and, in most instances, is located in the anterior or lateroposterior aspect of the lower thyroid pole. In nearly half of the cases, the lower gland remains within the thymic tongue at the thoracic inlet. A few glands may descend with the thymus into the mediastinum, or may be left high in the neck as a result of early developmental arrest. Thus, the lower gland may be found anywhere from the angle of the jaw to the pericardium. This embryologic variation accounts for the wide distribution of the lower gland.

Because of this embryologic variation the identification of the origin of the gland is not always easy. When the gland is encountered in these exceptional locations, it is difficult to be certain whether it is an upper or a lower parathyroid.

It has been presumed that a gland located high in the neck is always an upper gland (Parathyroid IV) and that one low in the neck is a lower gland (Parathyroid III), a presumption that is generally correct. As noted earlier, however, a lower gland (Parathyroid III) may be left in the upper neck secondary to failure of descent of the third branchial complex. The identity of a misplaced lower gland can be made only by the presence of a closely associated thymic remnant.

On the other hand, an upper gland (Parathyroid IV) may be located in the lower pole of the thyroid. In this situation, the gland is frequently suspended by a long but tenuous vascular pedicle from the inferior thyroid artery and lateral thyroid vein at the cricothyroid junction. The origin of the vascular pedicle may serve as a guide in the identification of a low-lying upper parathyroid gland (Parathyroid IV). By knowing which gland it is, the surgeon may save many hours in search of the missing parathyroid.<sup>5</sup>

### *B. Subcapsular and Extracapsular Parathyroid Glands*

It is well known that the thyroid gland is sheathed in a transparent fibrous capsule which is thick and strong in the upper and middle portions of the thyroid and thin and friable in the lower thyroid pole. When a parathyroid gland is located behind this capsule, it is designated as subcapsular; and one lying outside of the capsule is known as extracapsular. This anatomic feature is of surgical importance because, when diseased, a subcapsular parathyroid usually remains in its place and expands locally within the confines of the surgical capsule of the thyroid. An extracapsular parathyroid, on the other hand, tends to be displaced into an area where it meets little if any resistance. Thus, an enlarged subcapsular parathyroid gland, located behind the upper or lower pole of the thyroid is seldom displaced to any degree, and an extracapsular gland at the cricothyroid junction or within the thymus invariably falls into either the posterior or anterior mediastinum.

### *C. Criteria of a Normal Gland*

Of all the parameters of normalcy in a parathyroid gland, size and weight are usually regarded as the most important determinants.<sup>1,3</sup> As our observations and those of others attest,<sup>4,6</sup> however, there are occasional variations. The average dimension of a normal gland in our series was  $5 \times 3 \times 1$  mm, but one gland was as large as 12 mm and one as small as 2 mm. Even larger glands have been reported.<sup>3</sup> Clearly, size can not always be used as the sole determinant of normalcy in the gland. Moreover, a parathyroid gland in situ is always larger because of its intense vascularity. Once the gland is removed it is no longer hyperemic and instantly becomes smaller. For this reason, the discrepancy in size often arises between the surgeon at the operating table and the pathologist in the laboratory.

The weight of the normal gland is less variable than the size, averaging 35 to 40 mg in our series. The largest gland weighed 78 mg, and was found in a man with three other small glands of 20, 15, and 12 mg respectively. Theoretically, the weight of a gland is a better index of normalcy than size, but it is impracticable to weigh a normal gland at surgery unless the gland is sacrificed.

The color of a parathyroid gland depends on the amount of fatty tissue and the degree of vascularity.<sup>1</sup> A normal cadaveral gland generally appears yellowish-tan, with the exception of those obtained from victims of sudden death whose glands appeared reddish-brown in color, as a result of venous stasis. In life, the gland of a young person has relatively fewer fatty cells and is consequently more reddish-brown than that of an elderly person whose gland has more fat cells and granules, giving rise to a yellowish-tan color. It is the presence of stromal fatty cells and intracellular fatty granules, demonstrated by frozen section examination, that aids in confirmation of the normalcy of the gland.

A normal gland, in the face of a parathyroid neoplasm, frequently appears yellowish-tan in color, such as that of a cadaveral specimen. It is the result of atrophy of disuse, a physiological response to the autonomous diseased parathyroid. Thus, the color of a parathyroid gland may provide the surgeon with a clue to differentiating the pathologic type of hyperparathyroidism.<sup>2</sup> For in neoplasia, particularly the common adenoma, the disease process is localized and only one gland or part of one gland is involved; the remaining three become atrophic and yellowish-tan in color. In hyperplasia, on the other hand, all four glands are diseased and hyperemic and, therefore, all are reddish or beefy-red in color.

### *E. Supernumerary, Fused and Intrathyroidal Glands*

Supernumerary glands vary from 5 to 8 in number.<sup>3,4,6</sup> In our study there were 4 subjects (or 2.5%) with

supernumerary glands, with 5 glands in 3, and 6 glands in 1 subject. Supernumerary glands are frequently associated within a lobule of thymic tissue which suggests its derivation from the same primordium with the thymus, having undergone multiple divisions in the course of embryologic descent. The clinical significance of supernumerary glands lies in the fact that it can be the cause of continuing hyperparathyroidism.

When two parathyroid glands are intimately approximated to each other, and appear fused, they are known as "kissing pairs." A true "kissing pair" is rare and was not encountered in this study. A kissing-paired parathyroid may be differentiated from a bilobular gland by the presence of a cleavage plane which is absent in a bilobular gland. Further, a bilobular gland often has an intact capsule. It is important not to confuse the two at the time of surgical exploration.

An intrathyroid parathyroid is a distinct possibility, though a rarity. None was uncovered in this study. It is generally the upper gland (Parathyroid IV). In this instance, the primordium of the Parathyroid IV in the 4th branchial pouch is trapped between the lateral and

the median thyroid prior to their embryologic fusion. Thus, it is frequently located within the upper thyroid lobe. A true intrathyroidal gland is surrounded with thyroid tissue on all four sides. One that is buried in the crease of the thyroid or located within the surgical capsule of the thyroid may not be defined as intrathyroidal.

### References

1. Castleman, B. and Mallory, T. B.: The Pathology of the Parathyroid Gland in Hyperparathyroidism. *Am. J. Pathol* 11:1, 1935.
2. Cope, O.: The Story of Hyperparathyroidism at the Massachusetts General Hospital. *N. Engl. J. Med.*, 274:1174, 1966.
3. Gilmour, J. R.: The Gross Anatomy of the Parathyroid Glands. *J. Pathol. Bacteriol.*, 46:133, 1938.
4. Norris, E. H.: The Parathyroid Glands and the Lateral Thyroid in Man: Their Morphogenesis, Histogenesis, Topographic Anatomy and Prenatal Growth. *Carnegie Inst.*, Washington, Pub. No. 479, *Contrib. Embryol.*, 159:247, 1937.
5. Wang, C. A.: Surgery of the Parathyroid Glands. *Advances in Surgery*, Vol. 5, Edited by C. E. Welch and J. D. Hardy. Chicago, Year Book Medical Publishers, Inc., 1966, pp. 109-127.
6. Weller, G. L.: Development of the Thyroid, Parathyroid and Thymus Glands in Man. *Carnegie Inst.*, Washington, Pub. No. 443, *Contrib. Embryol.*, 141, Vol. 24, 1933.