

Pheochromocytoma:

Present Diagnosis and Management

H. WILLIAM SCOTT, JR., M.D., JOHN A. OATES, M.D., A. S. NIES, M.D., HENRY BURKO, M.D.,
D. L. PAGE, M.D., R. K. RHAMY, M.D.

In the 25-year period 1950–1975 forty-four patients with pheochromocytoma were observed at Vanderbilt University Affiliated Hospitals. Bilateral adrenal tumors occurred in 3 patients (6.8%) and extra-adrenal tumors occurred in 7 others (16%), 33 patients (75%) had single tumors arising in one of the adrenal glands; in one of these 5 years after operation, a malignant tumor developed in the same renal fossa. Five of the 44 patients (11.3%) proved to have malignant tumors and died with metastases. In 11 patients in the earlier years of this study the clinical diagnosis was not made and the tumor was identified by the pathologist at autopsy. There was a single postoperative fatality among the 33 patients in whom the clinical diagnosis was made. Seventy per cent of all survivors with benign tumors have remained normotensive during followup periods of one to 20 years.

PHEOCHROMOCYTOMA is a most hazardous and dramatic cause of hypertension. This potentially lethal neoplasm originates in most cases in the adrenal medulla and less frequently in the cells of the extra-adrenal paraganglion system which are disseminated along the paravertebral axis from the pelvis to the base of the skull. The cell of origin is regarded by Pearse as part of the neuroendocrine group of cells which he calls the APUD series. The cells of this system secrete polypeptide hormones and are, whether by origin or functional similarity, very much alike in character.^{4,5} Multiple endocrine neoplasia, type 2, is a genetic disorder involving multifocal tumor formation in this system of polypeptide-secreting cells. Its expressions include pheochromocytoma, medullary carcinoma of thyroid, parathyroid hyperplasia, and multiple oral mucosal neuromas which may occur in combination or singly in several members of

*From the Departments of Surgery, Medicine,
Radiology, Pathology and Urology,
Vanderbilt University Medical Center,
Nashville, Tennessee 37232*

a kindred.^{8,3} Familial pheochromocytoma also has an association with the neuroectodermal dysplasias which include von Recklinghausen's disease, tuberous sclerosis, Sturge-Weber syndrome and Lindau-von Hippel disease.² In these various familial syndromes bilateral adrenal pheochromocytomas tend to occur. However, most frequently the tumor presents as a single lesion of adrenal medullary origin without familial associations.⁹

The incidence of pheochromocytoma has been estimated to range from 0.4 to 2% of all hypertensives. Most tumors occur in adults, but about one-fifth of reported cases have been in children. The reported ages range from 5 months to 82 years. ReMine *et al.* recently reported 138 patients with pheochromocytoma operated on at Mayo Clinic between 1926 and 1970. There were 63 males and 75 females. The tumor was extra-adrenal in 10%, bilateral in 4.4%, multiple in 7% and malignant (proven by metastases) in 18 patients (13.4%).⁶

The clinical manifestations of pheochromocytoma are those which result from the release of catecholamines secreted by the tumor. Epinephrine and norepinephrine are both usually present in adrenal medullary tumors and norepinephrine alone more commonly is secreted by extra-adrenal tumors. Since norepinephrine is a relatively pure alpha adrenergic stimulator and epinephrine has both strong alpha and strong beta adrenergic stimulant effects, clinical manifestations range from hypertension alone to various combinations of tachyarrhythmias and

Presented at the Annual Meeting of the Southern Surgical Association, December 8–10, 1975, The Homestead, Hot Springs, Virginia.

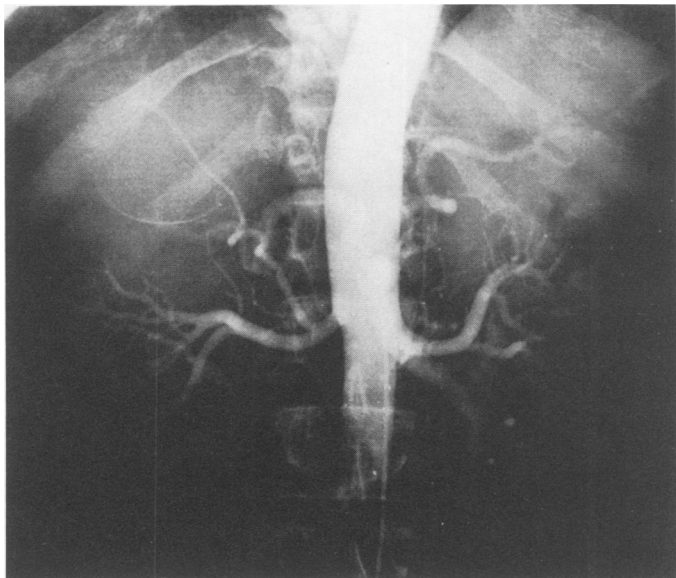


FIG. 1a. Characteristic arteriographic findings in right adrenal pheochromocytoma. Asymmetrically enlarged inferior adrenal artery on right.

hypermetabolic syndromes associated with hypertension. Recognition of the varied clinical manifestations and syndromes is of paramount importance in diagnosis of these tumors. Establishment of accurate diagnosis depends on measurement of abnormal elevations of catecholamines and metabolites in the patient's blood and urine.⁹

This report summarizes the experience in diagnosis and management of patients with pheochromocytoma in the Vanderbilt University Affiliated Hospitals during the last 25 years.

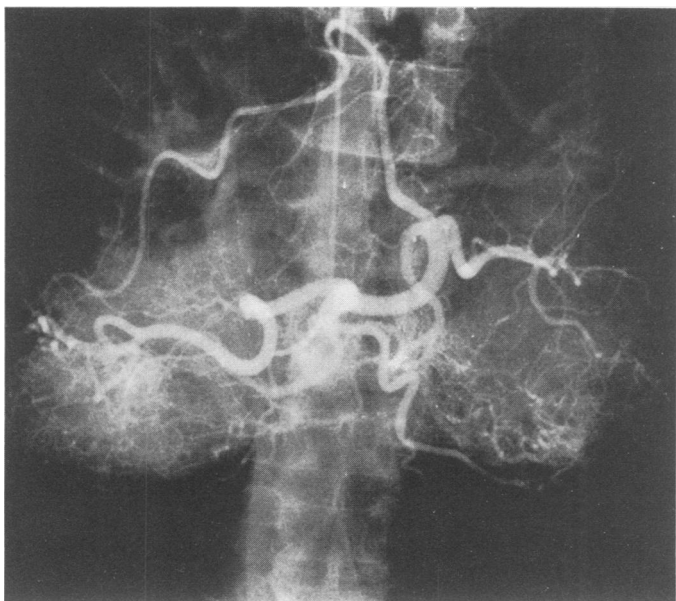


FIG. 1b. Celiac injection with asymmetrically enlarged inferior phrenic artery on right; note tumor vessels below right diaphragm.

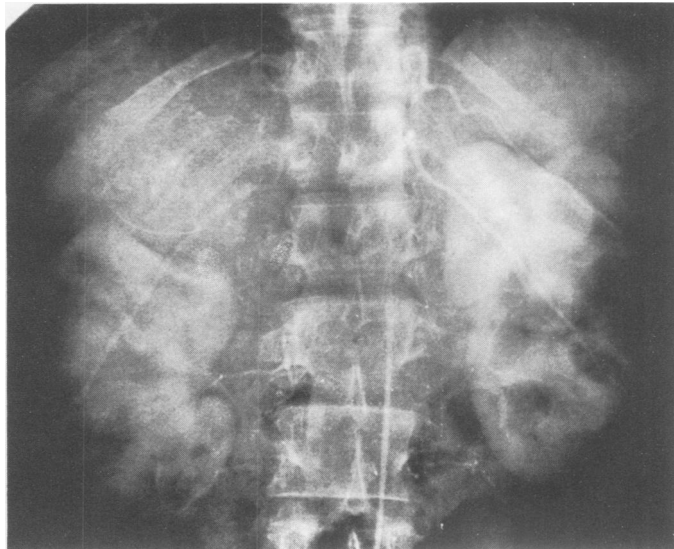


FIG. 1c. Supra-renal mass which flattens upper pole of right kidney. Curvilinear calcification does not indicate true circumference of tumor.

Clinical Experience

In a 25-year period (1950–1975) at Vanderbilt University Affiliated Hospitals (Nashville Veterans Administration Hospital, Nashville Metropolitan General Hospital and Vanderbilt University Hospital) 44 patients with pheochromocytoma were observed. Ages ranged from 9 to 78 years. There were 29 females and 15 males. Familial occurrence of tumors presented as multiple endocrine neoplasia, type 2, in 2 patients and 2 others had the associated findings of von Recklinghausen's cutaneous neurofibromatosis and Lindau-von Hippel disease respectively. The remainder had no familial or neuroectodermal dysplastic associations.

In 11 patients seen in the earlier years of this period of study clinical diagnosis of pheochromocytoma was not made and the tumor was discovered at autopsy by the pathologist.⁷ Seven of this group of clinically undiagnosed patients were normotensive. In four patients the pheochromocytoma was an incidental autopsy finding but in the other 7 the tumor contributed to the death of the patient. Two of the former patients were admitted to the hospital for the first time in a pre-terminal state with leukemia and generalized metastases of carcinoma of the cervix, respectively. In the latter group another patient was in a terminal state when first seen with generalized metastases of a nonfunctional, malignant pheochromocytoma of the right adrenal. The deaths in two other normotensive patients occurred in the immediate post-operative period with tachyarrhythmia and shock after salpingectomy for ruptured tubal pregnancy in one and appendectomy in another. One of four hypertensive patients died in a similar manner following hysterectomy. Another hypertensive patient died with a similar

arrhythmia and hypotensive crisis three days after he was admitted to the hospital for study which included three repeatedly positive histamine provocative tests. The two remaining hypertensive patients were admitted to the hospital in pre-terminal status with massive cerebral infarctions.

In the 33 patients in whom the clinical diagnosis was established, symptoms of pheochromocytoma had existed for one to 30 years in 17 and from one to 12 months in 15 others. Two patients with medullary thyroid carcinoma from kindreds with multiple endocrine neoplasia (MEN), type 2, were admitted for evaluation and search for pheochromocytomas which were essentially asymptomatic. Except for these two patients, all of this group had hypertension. In 9 patients this was of the sustained variety without evident paroxysmal episodes. In the other 22 patients, paroxysmal attacks were superimposed on sustained hypertension in 9 while 13 had the "classic" pattern of paroxysmal hypertension with normal blood pressure between attacks.

Paroxysmal attacks were characterized by extreme levels of hypertension, severe headache, often described as pounding or throbbing, palpitation, tachycardia, sweating, nausea and weakness. Less often vomiting, hot flashes, visual disturbances and trembling accompanied these episodes. Attacks usually occurred abruptly and persisted for a few minutes to a few hours and often ended with profound weakness.

Physical findings of diagnostic value in these patients were limited. Two patients had sustained paralytic strokes. Two others were nearly blind as a result of hypertensive retinopathy in one and the ocular stigmata of Lindau-von Hippel's disease in the other. Another patient had diffuse cutaneous neurofibromatosis and two others had nodular goiters (MEN, type 2). Three patients who proved to have malignant tumors presented with metastatic lesions of scalp and clavicle. Another patient with a large (425 gm) resectable tumor had a 15 × 10 cm mass in the left upper quadrant.

Laboratory evaluation has emphasized 24-hr collections of urine for free catecholamines, vanillyl mandelic acid (VMA) and metanephrines.⁹ Prior to 1955 none of these determinations was available in our laboratories. Urinary free catecholamines were found to be elevated above 100 $\mu\text{g}/24$ hr in 26 patients. In all but two of these the elevations were repeatedly in excess of 200 $\mu\text{g}/24$ hr, most commonly in the range of 300 to over 1,000 $\mu\text{g}/24$ hr. One normotensive patient with MEN, type 2 had low urinary catechols of 118 $\mu\text{g}/24$ hr and another patient with sustained hypertension who was otherwise asymptomatic had urinary catecholamines of 78 $\mu\text{g}/24$ hr. Urinary VMA was elevated above 12 mg/24 hr in 14 patients and was below 10 mg/24 hr in three others. Urinary metanephrines have been measured only in the last two years in our laboratories and have been elevated above the normal limit of 1.3 mg/24 hr in

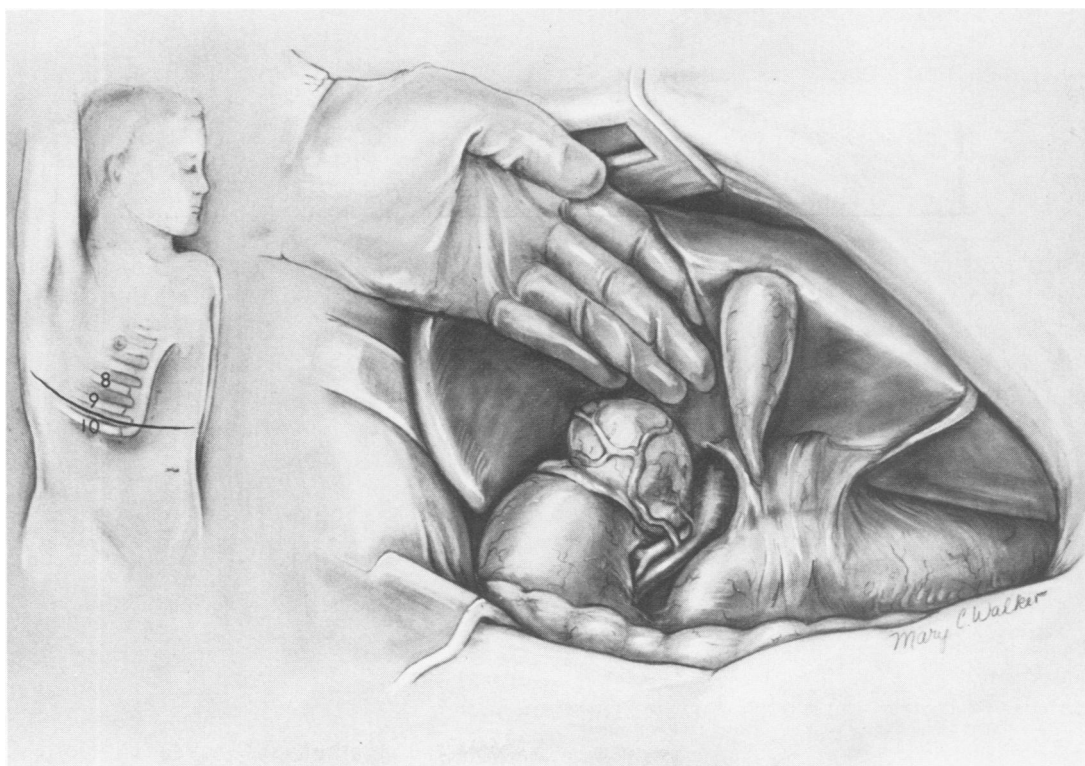


FIG. 2. Exposure of adrenal pheochromocytoma by thoracoabdominal incision, right.

TABLE 1. Location of Primary Pheochromocytomas

	Benign	Malignant
Right adrenal	13	2
Left adrenal	19	1*
Bilateral	3	0
Extra-adrenal	5	2
	—	—
	40	5

* Counted as new malignant tumor 5 years after excision of histologically "benign" pheochromocytoma.

three recent patients. Positive diabetic glucose tolerance tests were found before operation in 9 patients.

Radiographic studies which were helpful in localizing the site of pheochromocytoma before operation included nephro-tomography, intravenous urography, retroperitoneal pneumography, flush aortography and selective arteriography of renal arteries and other aortic branches. Retrograde venous angiography and adrenal vein catheterization for measurement of catecholamines have been rarely used. During the past decade we have come to rely preferentially on contrast arteriography in most patients with suspected pheochromocytoma.^{9,1} While rapid injection of hypertonic iodinated contrast medium is a powerful pharmacologic stimulus for catecholamine release from a pheochromocytoma, if the procedure is carried out with appropriate precautions, including the use of alpha adrenergic blocking agents, monitoring of vital signs and electrocardiogram with full preparation for carrying out whatever resuscitation may be required, excellent results can be safely obtained. Preoperative localization of pheochromocytoma was accurately accomplished in 17 of the 33 patients in whom clinical diagnosis was made (Fig. 1).

Preoperative preparation of these patients in the last decade has usually included the use of alpha adrenergic blocking agents. Phenoxybenzamine and/or Phentolamine have been used for 4 to 10 days in patients with blood pressure of 200/130 or greater or with frequent, severe hypertensive attacks. Beta adrenergic blockade with Propranolol has been added for coexisting arrhythmias, persistent premature ventricular contractions and tachycardia (pulse rate greater than 140/min).⁹

TABLE 2. Pheochromocytoma: Early Survival

	Patients	Deaths
Clinical diagnosis made (Surgical removal)	33*	1†
Clinical diagnosis not made (Autopsy)	11	11
Total	44	12

* Two patients had only biopsy of metastatic tumor.

† Renal failure after removal of tumor and left kidney.

Anesthetic management in recent years has begun with adrenergic blockade. Thiopental and nitrous oxide are used for induction with deep halothane anesthesia for maintenance in most patients. A Lidocaine drip is used to control arrhythmias with Phentolamine supplementation if needed. Aggressive blood and fluid replacement are used during operation in anticipation of hypotension after removal of the tumor. Usually 50 to 75 grams albumin and 2 to 3 liters of Ringers' lactate are given. We have tried to avoid the use of norepinephrine because of the hazard of cutaneous sloughs with extravasation at sites of infusion.⁹

Operative procedure has been based on our preference for wide exposure and non-manipulative dissection in removal of pheochromocytomas. An anterior transperitoneal approach which permits examination of both adrenal glands and a search of the para-spinal axis is desirable. With large (>6 cm diameter) tumors, extension of the incision across the costal margin into the eighth or ninth intercostal space greatly improves exposure. We have used a thoracoabdominal incision in the majority of patients with adrenal pheochromocytoma in this series (Fig. 2). There have been no deaths during operation. We believe the safety and excellence of the exposure justify the slight increase in morbidity which accompanies its use.

The location of primary pheochromocytomas in the 44 patients of this series is summarized in Table 1. One patient whose well localized, non-invasive tumor of left adrenal was excised with all of the gland in 1958 was asymptomatic for 5 uneventful years and then an invasive, non-functioning highly malignant pheochromocytoma developed in the left suprarenal fossa. The latter is listed in the "malignant" column and the former listed as "benign." Whether this was a recurrence or a new malignant tumor cannot be determined. Despite radical removal of this malignant tumor, the patient died with metastases in 9 months.

The 11 patients whose tumors were discovered at autopsy and in whom the diagnosis of pheochromocytoma was not made during life are listed in Table 2. Details of their circumstances have been previously reported⁷ and are summarized earlier in this article.

Among the 33 patients in whom the clinical diagnosis was made, 31 had removal of primary pheochromocytomas with a single postoperative fatality: a 48-year-old man in 1967 under Penthrane anesthesia had removal of a large (8 × 7 × 3.5 cm) localized tumor which had surrounded the left renal vein and required simultaneous left nephrectomy. He was hypotensive for a brief period at the end of the operation. Subsequently, he went into oliguric renal failure and died in uremia 4 weeks later. All others survived operative removal of the pheochromocytoma (Table 2). In two patients with benign tumors

hemorrhagic infarction with spontaneous rupture of the tumor necessitated emergent operations. In two patients with metastatic malignant tumors only biopsy of metastases was done to establish pathologic diagnosis prior to chemotherapy. The primary tumor in these patients was never removed although its site was radiologically localized.

Pathologic classification of pheochromocytomas as benign or malignant (Table 1) is based on the presence or absence of proven metastases. We follow this practice because histologic pattern does not accurately predict biologic behavior. All cases demonstrated the histologic patterns found in pheochromocytoma, including solid alveoli, sheets and anastomosing cords of cells in an endocrine pattern closely related to a rich capillary network.⁹

Non-fatal postoperative complications included atelectasis and pneumonitis in 5 patients; one of these in addition had a persistent pleural effusion and another required reinsertion of a thoracotomy tube because of pneumothorax. In the early years of the study 6 patients required postoperative infusions of norepinephrine for one to 3 days and 2 of these sustained a cutaneous slough at the site of infusion. There were isolated instances of wound infection, urinary tract infection and thromboembolism. One patient sustained a transient hemiparesis. Another who had renal failure prior to excision of the pheochromocytoma developed bleeding from stress ulcers after operation requiring reoperation for control.

The results for patients who survived operative removal

of pheochromocytoma have varied with age, familial relationships and the benign or malignant characteristics of the tumor. Both patients with familial pheochromocytoma and those in the childhood age group have an increased tendency to have bilateral tumors as well as synchronous and metachronous multiple extra-adrenal tumors.⁶

Followup has been completed to date (December, 1975) in all but two patients in this series (Fig. 3). In these exceptions a single benign adrenal pheochromocytoma was removed in 1957 and 1963 and each patient remained normotensive and asymptomatic for a period of 11 years and 18 months, respectively, before our loss of contact with them. Each of the 4 patients with malignant pheochromocytoma who were clinically managed received x-ray therapy and various chemotherapeutic agents and died with disseminated metastases 9 months, 2, 3 and 11 years after the diagnosis was made. In two of these patients an histologically benign pheochromocytoma had initially been removed 11 and almost 6 years, respectively, prior to death from metastatic disease.

In the 25 remaining patients with benign pheochromocytoma, up-to-date followup extends from one to 20 years. In this group are the two adults with MEN, type 2, and the only child in the series, a 9-year-old boy with no identifiable familial associations. Each had bilateral adrenal pheochromocytomas removed with satisfactory courses on maintenance steroids in the last one to 4 years. One of the two patients with MEN, type 2, is known to have widely distributed metastases of medullary

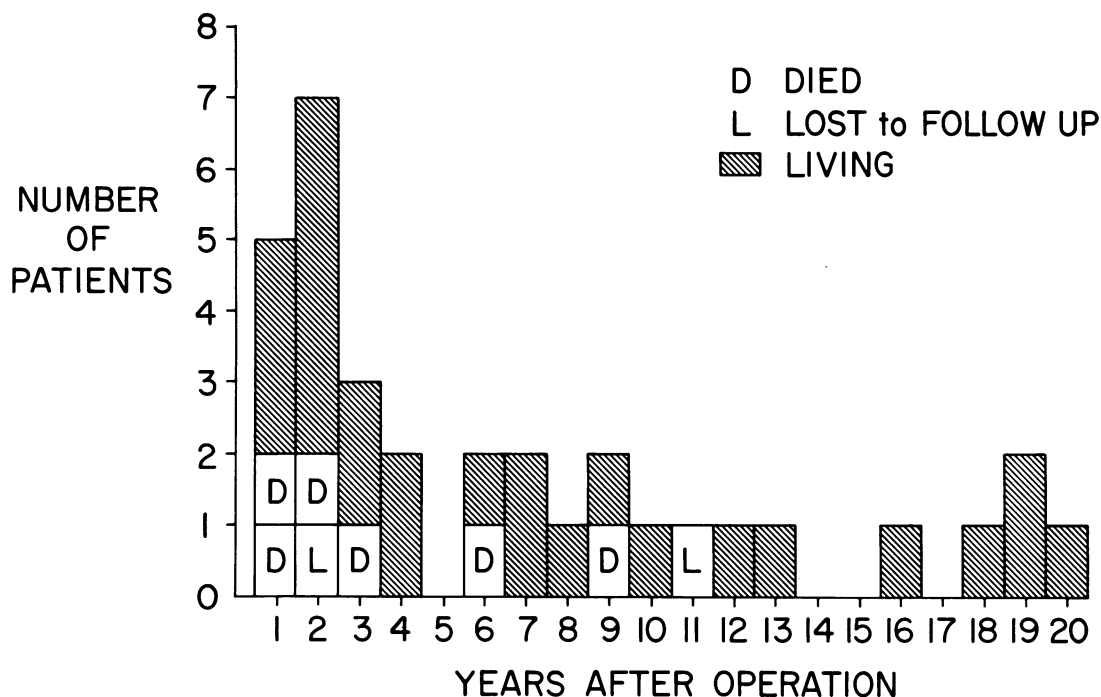


FIG. 3. Followup data in 33 patients with pheochromocytoma in whom clinical diagnosis was made and treatment instituted.

thyroid carcinoma. Each of these 3 patients is normotensive.

Among the 22 other patients who had a single benign pheochromocytoma removed was one woman who had a renal hilar tumor and coexisting renal artery stenosis which was repaired when the tumor was excised. Both she and 12 others in this group who have been followed from 18 months to 20 years have remained normotensive and asymptomatic with no evidence of recurrence of pheochromocytoma. However, in the 9 other patients hypertension has persisted or developed in the period of followup after excision of the tumor. One of these patients had malignant hypertension with diffusely severe renal arteriosclerosis and nitrogen retention at the time her small para-aortic pheochromocytoma was excised. She sustained no improvement from removal of the tumor and died in uremia 3 months later. Catecholamines were normal after operation in this patient and have been within the normal range in each of the other 8 patients who have developed hypertension during the followup period. In each instance the hypertension has been controlled satisfactorily with antihypertensive drugs. Three of these patients are on Digitalis preparations and one also has an enlarged heart which has been attributed to catecholamine myocardiopathy.

Diabetic glucose tolerance tests which existed before operation in 9 patients have reverted to normal in 7 after removal of the pheochromocytoma.

Comment

We have reviewed the clinical experience with pheochromocytoma at Vanderbilt University Affiliated Hospitals over the last 25 years. Between 1950–1975, 44 patients were observed in whom this diagnosis was histologically confirmed. Bilateral adrenal tumors occurred in 3 patients (6.8%), extra-adrenal tumors occurred in 7 others (16%), 33 patients (75%) had single tumors arising in one of the adrenal glands; in one of these a malignant tumor developed 5 years later in the ipsilateral renal fossa. Five of the 44 patients (11.3%) proved to have malignant pheochromocytomas and died with metastases. In 11 patients in the early years of this study the clinical diagnosis was not made and the tumor

was identified by the pathologist at autopsy. There was a single postoperative fatality among the 33 patients in whom the clinical diagnosis was established. Four of these clinically recognized patients died during followup 9 months to 11 years with metastatic disease. Seventy per cent of all survivors with benign tumors have remained normotensive; hypertension has persisted or developed in 30% including one patient with pre-existing malignant hypertension who died in renal failure 3 months after excision of a small pheochromocytoma. All others have normal catecholamines and have been controlled with anti-hypertensive medication.

Pheochromocytoma can simulate any hypertensive syndrome. Although it is an uncommon cause of high blood pressure, all hypertensives should be screened for the tumor. Followup for life is mandatory in all patients with surgically treated pheochromocytoma.

References

1. Christenson, R. H., Smith, C. W. and Burko, H.: Arteriographic Manifestations of Pheochromocytoma. *Am J. Roentgenol. Radium Ther. Nucl. Med.*, In Press.
2. Glushien, A. S., Mansuy, M. M. and Littman, D. S.: Pheochromocytoma: Its Relationship to the Neurocutaneous Syndromes. *Am. J. Med.*, 14:318, 1953.
3. Harrison, T. S. and Thompson, N. W.: Multiple Endocrine Adenomatosis—I and II. *Current Problems in Surgery*, Chicago, Year Book Medical Publishers, Inc. 1975.
4. Pearse, A. G. E.: Common Cytochemical and Ultrastructural Characteristics of Cells Producing Polypeptide Hormones (the APUD Series) and Their Relevance to Thyroid and Ultimobranchial C Cells and Calcitonin. *Proc. R. Soc. Lond. (Biol.)*, 170:71, 1968.
5. Pearse, A. G. E.: The Cytochemistry and Ultrastructure of Polypeptide Hormone-producing Cells of the APUD Series and the Embryologic, Physiologic and Pathologic Implications of the Concept. *J. Histochem. Cytochem.*, 17:303, 1969.
6. ReMine, W. H., Chong, G. C., Van Heerden, J. A., et al.: Current Management of Pheochromocytoma. *Ann. Surg.*, 179:740, 1974.
7. Scott, H. W., Jr., Riddell, D. H. and Brockman, S. K.: Surgical Management of Pheochromocytoma. *Surg. Gynecol. Obstet.*, 120:707, 1965.
8. Steiner, A. L., Goodman, A. D. and Powers, S. R.: Study of a Kindred with Pheochromocytoma, Medullary Thyroid Carcinoma, Hyperparathyroidism and Cushing's Disease: Multiple Endocrine Neoplasia, Type 2. *Medicine*, 47:371, 1968.
9. Van Way, C. W., III, Scott, H. W., Jr., Page, D. L. and Rhamy, R. K.: Pheochromocytoma. *Current Problems in Surgery*, June, 1974. Chicago, Year Book Medical Publishers, Inc. 1974.

DISCUSSION

(Note: Some of the discussants' remarks refer to both this paper and to the preceding one by Dr. Frank Glenn.)

DR. ROBERT M. MILES (Memphis): We are indeed indebted to Drs. Glenn and Scott for calling attention to these unusual tumors and newer methods of diagnosis and treatment. The hospital incidence in our area is about 1.3 per 100,000 admissions—certainly a rare tumor.

With angiography and the laboratory determinations referred to, it's a far cry from the situation twenty-five years ago, when we had to depend upon a high index of suspicion and sometimes misleading pharmacological tests. But even the new methods of diagnosis and localization are not perfect, and despite preoperative identification of what is thought to be a pheo, at surgery, which is preferably done through the transabdominal approach, a careful search should be made for additional tumors. We have been surprised on more than one occasion to find extra-adrenal tumors.

(Slide) In this patient we found one on the right side; and this is it,