

Carcinoid Tumors of the Appendix

Mesoappendiceal Extension and Nodal Metastases

DONALD C. SYRACUSE, M.D., KARL H. PERZIN, M.D., JOHN B. PRICE, M.D., PHILIP D. WIEDEL, M.D., RICARDO MESA-TEJADA, M.D.

Carcinoid of the appendix occurred in 92 of 400,000 surgical pathology specimens covering 70 years, and followed previously reported incidences by age, sex, symptoms, size, location and histology. Invasion of the mesoappendix occurred in 13 cases, and in two of these, a reoperative ileocelectomy demonstrated regional node metastases. No distant metastases or fatalities appeared. Tumor size correlated with mesoappendiceal invasion. Carcinoid invasion of the mesoappendix may provide a valuable marker for more distant tumor spread, and justify an aggressive surgical approach in selected patients.

CARCINOID OF THE APPENDIX was first described by Merling¹¹ in 1808 but it was not until 1880 in a report by Ransom¹⁶ that metastases were associated with the tumor. McDonald⁹ commented in 1956 that only 13 cases of metastases from an appendiceal carcinoid were adequately confirmed and all involved only regional lymph nodes. Since then several additional reports of metastatic appendiceal carcinoid have appeared. By 1972 Cunningham² wrote that of 1,700 reported cases of appendiceal carcinoid, 37 (2%) had metastasized; in 21, the metastases only involved the regional lymph nodes.

We present two additional cases of metastatic appendiceal carcinoid to regional lymph nodes. Both patients underwent a reoperation for removal of possible residual carcinoid when the original specimen on microscopic examination showed mesoappendiceal invasion. A review of our experience with carcinoid of the appendix suggests that invasion of the mesoappendix can be associated with regional node spread and should prompt consideration for a more extensive procedure than simple appendectomy.

From the Departments of Surgery and of Pathology, Division of Surgical Pathology, Columbia University, College of Physicians and Surgeons and the Columbia-Presbyterian Medical Center, New York, New York

Experience

The records of our Surgical Pathology Laboratory contained 92 cases of appendiceal carcinoid tumors examined during the past 70 years. These lesions were found among 196 carcinoid tumors of various sites, which are shown in Table 1. In addition, 14 other carcinoids were identified in the liver, peritoneum or mesentery, their primary sites not having been determined. No ovarian carcinoids were listed since we do not usually receive gynecologic specimens in our laboratory.

The age and sex distribution of our patients can be found in Table 2 and are similar to those reported in other studies.^{12,13,15}

Appendiceal carcinoids rarely could be implicated in the pathologic process which led to abdominal exploration. In only seven patients was the tumor possibly related to the clinical problem: six patients had acute appendicitis in the distal tip with a proximally occlusive carcinoid and one patient had a small bowel obstruction with invasion of the ileum from an appendix encased with carcinoid. In 83 patients, the carcinoid was found incidentally and not related to the pathologic process. Of these, 42 patients were explored for acute appendicitis and 41 patients underwent a prophylactic appendectomy associated with: gall bladder disease (21 cases); gynecologic disorders (8); colonic carcinoma (5); regional enteritis (3); ulcerative colitis (1); peptic ulcer (1); adhesions (1); and urinary tract disease (1). In two cases, we could not determine the reason for the operation.

Reprint requests: Donald C. Syracuse, M.D., Department of Surgery, Columbia University, College of Physicians and Surgeons, 630 West 168 Street, New York, New York 10032.

Submitted for publication: January 17, 1979.

TABLE 1. Sites of Origin of 196 Carcinoid Tumors

Appendix	92
Rectum	45
Small intestine	32
Ileum	23
Jejunum	4
Duodenum	5
Lung	13
Stomach	8
Colon	4
Mediastinum	1
Pancreas	1

The extent of local spread and tumor size are recorded in Table 3. Although penetration of carcinoid to the muscularis and serosa were common, extension to the mesoappendix occurred in only 13 of the 92 cases (14%). The extent of invasion was related to tumor size. When a tumor was described grossly, mesoappendiceal invasion was found in 11 of 43 cases (26%). However, when the carcinoid was identified only microscopically, mesoappendiceal invasion was seen in two of 49 cases (4%). Only four of the 92 carcinoid tumors measured 1.0 cm or more in diameter and in two of these the mesoappendix was involved.

In our series, as in others,^{12,15} carcinoids were found most frequently at the tip of the appendix. In 77 of our 92 cases, the position of the carcinoid was known. Sixty tumors involved the distal tip; 12 occurred in the middle third, and four were found at the base of the appendix. In one case, the tumor involved the entire length of the appendix.

Mesoappendiceal invasion occurred with a distribution which reflected the relative incidence of the tumor at each position along the length of the appendix. Of the 13 carcinoids which invaded the mesoappendix, eight originated in the tip, while one each arose from the central and basal portions of the appendix. In three patients, the original site of the tumor could not be determined.

Six patients underwent an ileocelectomy for reasons unrelated to carcinoid, but the specimens contained an incidental appendiceal carcinoid. None of these specimens showed mesoappendiceal invasion and none demonstrated regional node involvement with carcinoid.

One patient who presented with small bowel obstruction underwent an ileocelectomy for an unusually large carcinoid which appeared to arise in the appendix, although an ileal or cecal primary could not be ruled out. The appendiceal mass measured 4 cm in diameter and had produced a cast of the appendix. The mesoappendix, ileum and cecum were infiltrated with carcinoid. However, despite its local aggressiveness, no regional nodes were involved with tumor.

Two patients underwent a reoperative ileocelectomy prompted by the finding of carcinoid infiltration of the mesoappendix. Both patients had regional node metastases and are detailed below.

Case Reports

Case 1. This 48-year-old man underwent an elective cholecystectomy with an incidental appendectomy. The appendix, small bowel, liver and all other intra-abdominal structures were grossly normal. Postoperatively there were no complications. The pathology report described an appendiceal carcinoid at the distal tip measuring 1 cm in diameter with extension into the mesoappendix (Fig. 1). One mesoappendiceal lymph node was found to contain nests of carcinoid in the marginal sinuses (Figs. 2 and 3). Three months later the patient underwent a reoperation with the findings of a healed appendiceal stump and no enlarged nodes. An ileocelectomy and omentectomy were performed with an end-to-end ileotransverse colostomy. The patient recovered uneventfully. The specimen contained 52 lymph nodes, one of which showed nests of carcinoid cells in a marginal sinus. The immediate area adjacent to the stump inversion was free of tumor. Four years later the patient remains well.

Case 2. This 31-year-old woman underwent an uncomplicated, elective cesarean section. During routine abdominal exploration, all structures were normal, except the appendix which had a central thickening and congestion of its serosal surface. An appendectomy was performed with the impression of subacute appendicitis and the patient recovered uneventfully. The pathology report described a carcinoid measuring 1.5 cm in diameter with invasion of mesoappendiceal fat (Fig. 4). The patient was discharged to return in two months for an ileocelectomy. At the time of reoperation, slightly enlarged mesenteric lymph nodes were identified, otherwise the exploration was unremarkable. An ileocelectomy including the mesentery was performed with an end-to-end ileotransverse colostomy. The patient recovered without difficulty. The specimen showed no residual tumor at the appendectomy site, but two of 67 mesenteric lymph nodes had carcinoid in the peripheral sinuses (Fig. 5). Both of the nodes were found distant to the immediate periappendiceal region. The remaining nodes showed reactive hyperplasia. Four years later the patient remains well.

TABLE 2. Age and Sex Distribution

	Total	10-19	20-29	30-39	40-49	50-59	60-69	70-79	Unknown
Male	30	2	7	4	6	3	2	6	—
Female	62	9	16	12	9	9	2	1	4
Total	92	11	23	16	15	12	4	7	4

TABLE 3. Size and Location of Carcinoid Tumors

	Total	Mucosa or Submucosa	Muscularis	Serosa or Subserosa	Mesoappendix Fat
No tumor recognized or described	49	16	18	13	2
Tumor seen not measured	11	—	2	6	3
1.0 cm or less	28	1	9	12	6*
1.1–1.5 cm	3	—	—	2	1*
1.5 cm or more	1	—	—	—	1
Total	92	17	29	33	13

* Including one case with lymph node metastasis.

Discussion

Controversy continues over the indications for more extensive procedures than simple appendectomy for carcinoid of the appendix. Moertel and associates¹² in an analysis of the world's literature and summary of cases treated at the Mayo Clinic through 1967, concluded that more than a simple appendectomy should be considered only if: 1) grossly metastatic disease were identified, or 2) if the primary carcinoid tumor measured 2 cm or greater in diameter. Pearlman and Srinivasan¹⁴ challenged the 2 cm rule with a case report of an appendiceal carcinoid metastatic to a regional mesenteric lymph node in which the original tumor measured only 1.4 cm in diameter. Dent and coworkers³ reported two patients with nodal metastases from

primary appendiceal carcinoids 1.0 cm in diameter. They concluded that a radical right hemicolectomy is indicated in patients whose tumors measured more than 1 cm in diameter or who had gross evidence of regional lymph node metastasis. We have added two additional cases of metastasizing appendiceal carcinoids measuring 1.0 and 1.5 cm and concur with Dent's recommendations.

Moertel and associates also claimed that simple appendectomy was adequate regardless of the location of the lesion. Ponka and colleagues¹⁵ supported this view, citing a patient who was well 17 years following an appendectomy in which a carcinoid tumor was incompletely excised from the base of the appendix. In contrast, Latham and coworkers⁸ and Kantor and associates⁶ have argued that involvement of the proximal

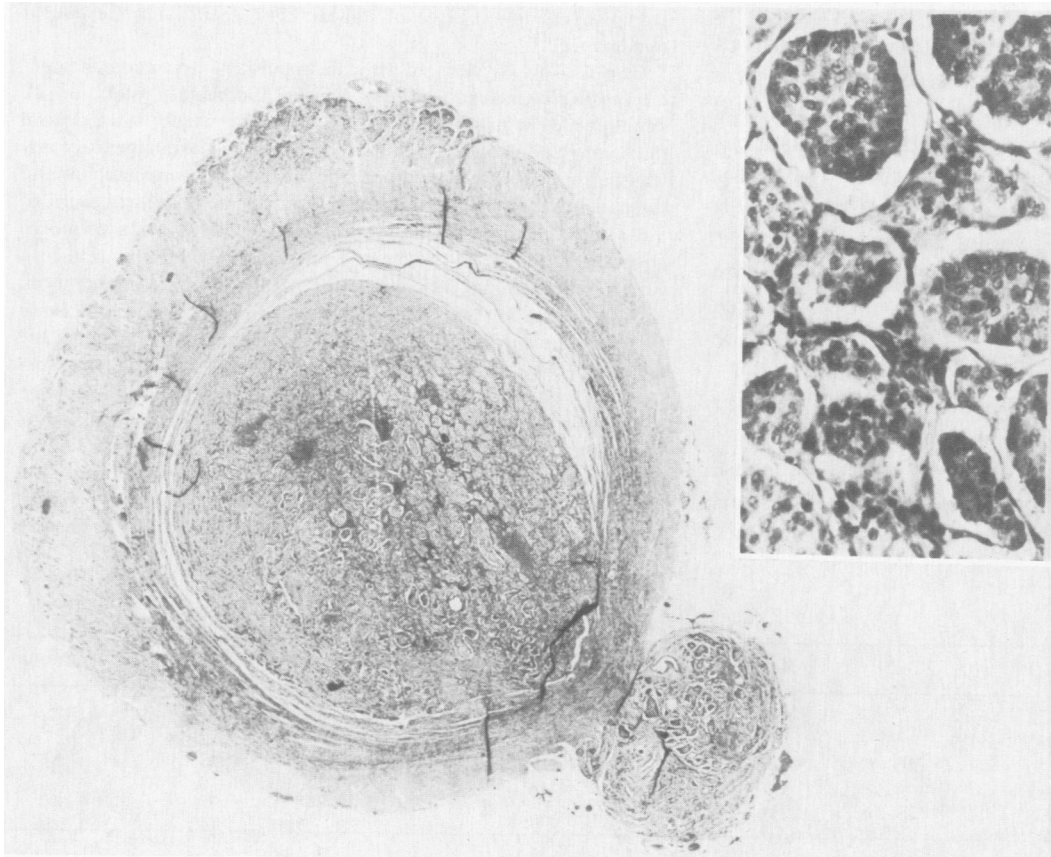


FIG. 1. Case 1. This low power view shows a cross section of the appendix. Tumor has filled the lumen and has replaced the mucosa. On the lower right, the lesion has invaded through the muscularis and has extended into the mesoappendix. The inset in the upper right demonstrates a higher power view of the neoplasm which has the classical features of carcinoid tumor. The lesion produces solid nests of cells with uniform nuclei (C 48279, $\times 16$, inset $\times 160$).

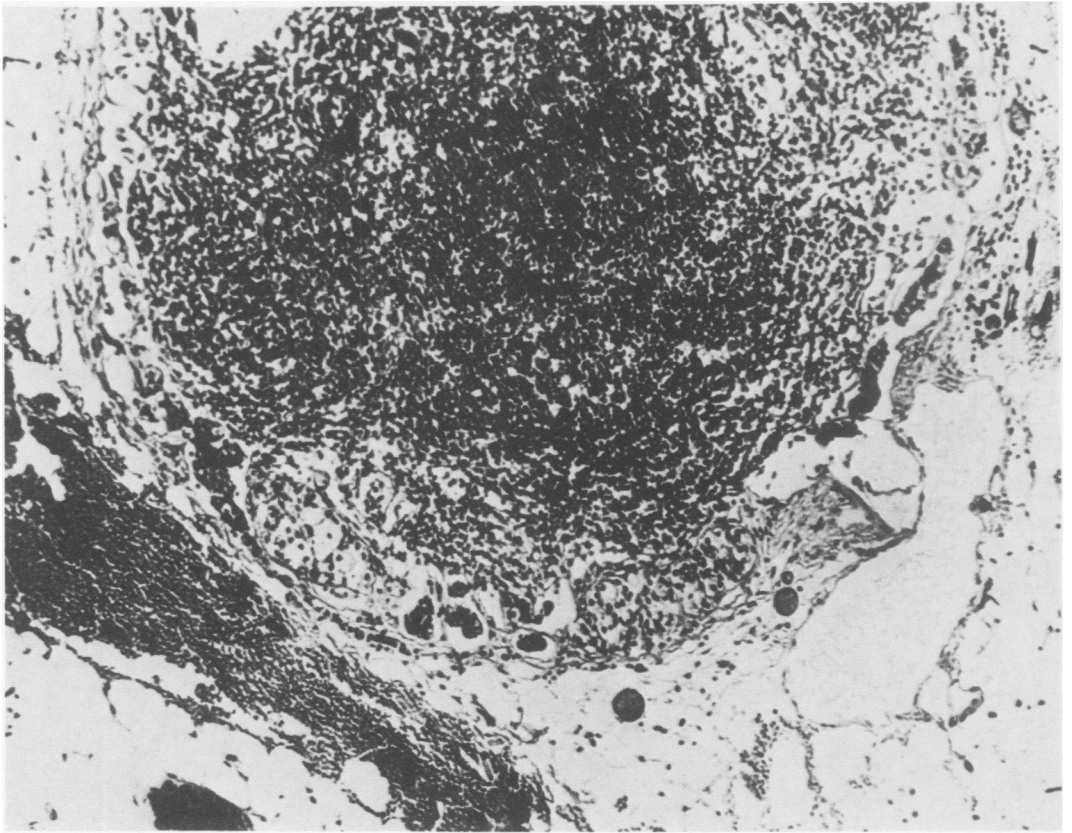


FIG. 2. Case 1. This lymph node which was found in the mesoappendix contains small nests of metastatic carcinoid tumor in a peripheral sinus (C 48279, $\times 90$).

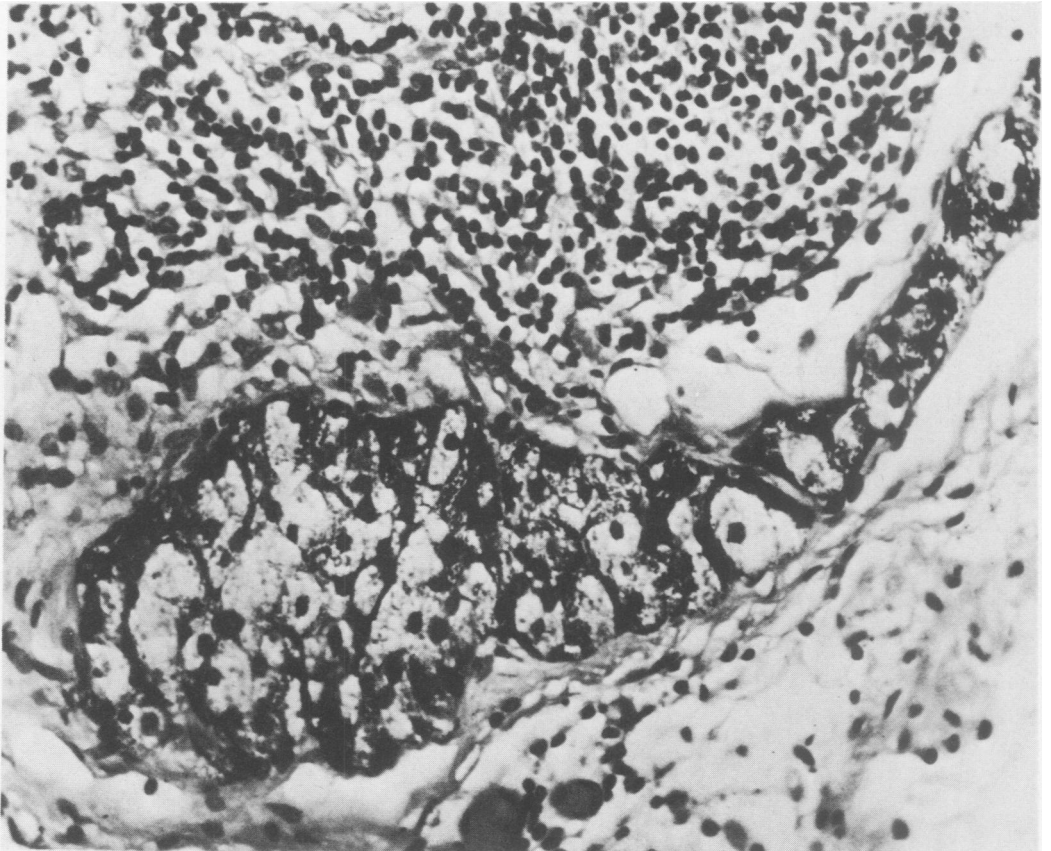


FIG. 3. Case 1. This silver stain shows argentaffin positive black granules in the cytoplasm of tumor cells which are found here in the peripheral sinus of the mesoappendiceal lymph node (C 48279, Long Fontana Silver stain, $\times 300$).

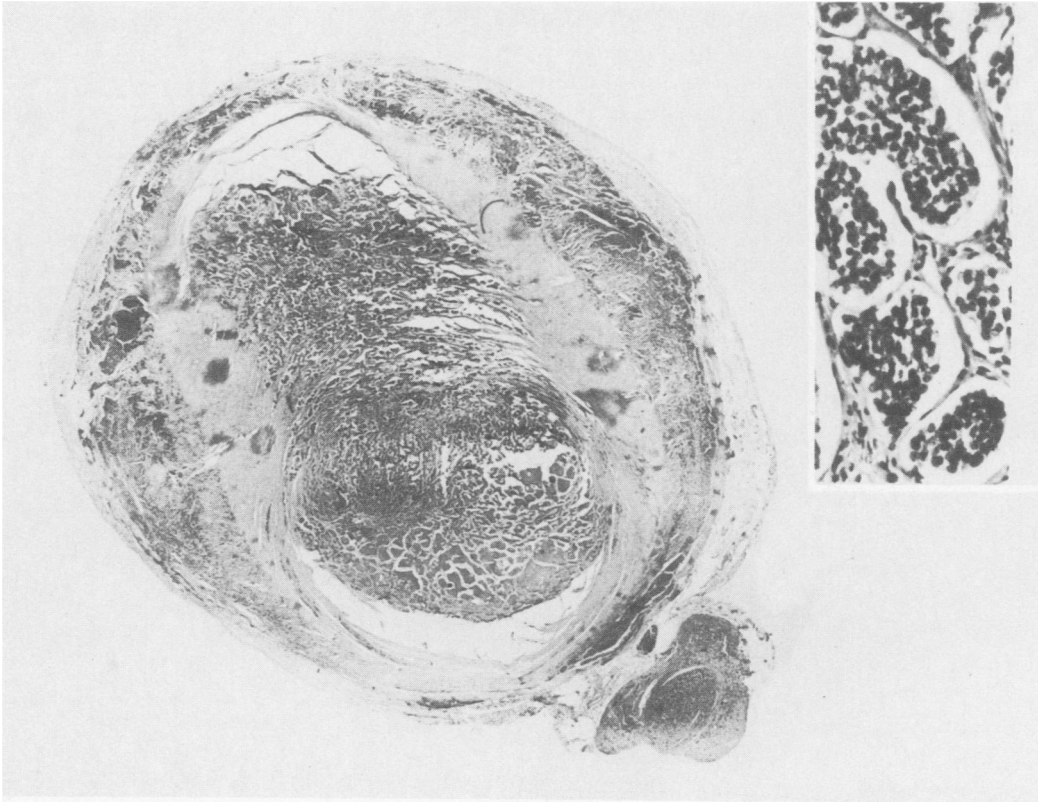


FIG. 4. Case 2. This low power view shows a cross section of the appendix with tumor filling the lumen. On the left, the lesion has extended through the muscularis to the serosa. In the lower right, the neoplasm has invaded the mesoappendix. The inset in the upper right illustrates a higher power view of the lesion which demonstrates the classical features of carcinoid tumor (74-1546, $\times 12$, inset $\times 160$).

appendix with carcinoid should prompt an ileocelectomy. Neither of our two patients had basal involvement of the appendix. Indeed, of the 13 appendiceal car-

cinoids which showed mesoappendiceal invasion, only one arose from the base. Therefore, our data fail to support the importance of the position of origin within

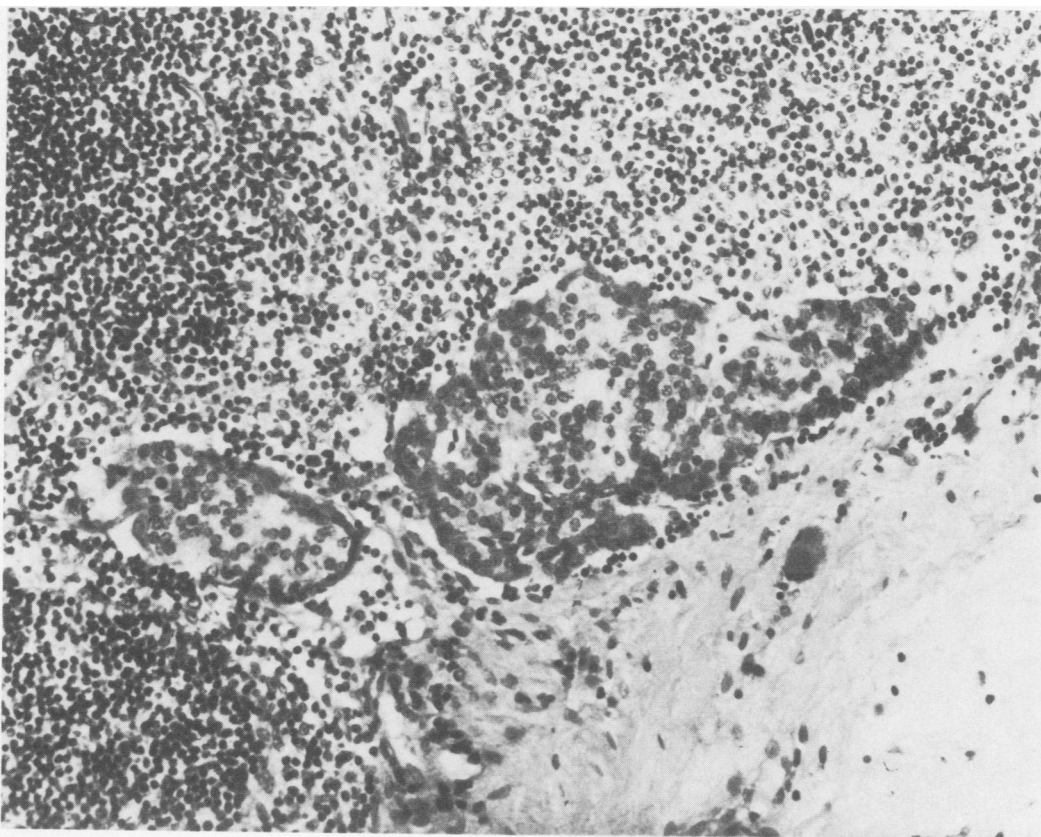


FIG. 5. Case 2. This ileocecal mesenteric lymph node resected with the ileocelectomy contains nests of tumor cells in a marginal sinus. Note the uniform nuclei and the similarity of these cells to those shown in Figure 4. (C52447, $\times 160$).

the appendix as a determinant of the need for more than a simple appendectomy. However, if tumor appears at the line of excision, further resection should be considered.

The strongest challenge to Moertel's findings has evolved over the importance of lymphatic invasion found microscopically. Dent and associates could not confirm the nearly universal lymphatic involvement of appendiceal carcinoid reported by Moertel. When strict criteria of endothelial lined spaces were used to distinguish lymphatics from artifact, Dent and associates found only 5 of 29 cases (17.2%) of appendiceal carcinoids had extension into lymphatics. However, we have found that lymphatic invasion is a difficult histologic criterion. Carcinoid cells tend to cluster and shrink from the supporting stroma making it difficult to decide whether nests of tumor cells are present in stroma or in lymphatic spaces. We consider the finding of any carcinoid cells in the mesoappendix, whether they are located in fat, fibrous tissue or lymphatic spaces, as a possible marker for metastatic disease.

Many questions remain. What is the frequency of positive nodes once carcinoid is found in the mesoappendix? Our series showed positive regional nodes in two patients reoperated upon when carcinoid was found in the mesoappendix. Eleven additional patients with similar mesoappendiceal invasion were found retrospectively, but none underwent reoperation and the state of their regional nodes is unknown.

Can regional nodes be involved without mesoappendiceal invasion? The failure to demonstrate metastatic carcinoid in six patients who underwent an ileocolicectomy for reasons unrelated to an incidental carcinoid suggests that regional nodes are not involved when the tumor does not extend to the mesoappendix. Clearly, more patients are required before a generalization can be reached.

What is the natural history of carcinoid if left behind in regional nodes? In our series, no patient had widespread disease from an appendiceal carcinoid. Moreover, in the records of our surgical pathology laboratory, which include more than 400,000 surgical cases (covering 70 years) we have no instance of an appendiceal carcinoid metastatic to sites other than the regional lymph nodes. However, an occasional case of distantly metastatic carcinoid,^{1,7,17} including the syndrome,¹⁰ has been reported as arising from the appendix. To date, four patients have succumbed to their tumor.⁴ Even in the Mayo Clinic series, two patients who eventually died presented with widespread metastatic disease confirmed at autopsy to arise from an appendiceal carcinoid. Whether an early, extended procedure might have salvaged these patients is conjectural.

The policy we follow emphasizes the presence of tumor invasion to the mesoappendix. Mesoappendiceal

invasion may provide the histologic marker of possible nodal spread. Tumor size influences extension to the mesoappendix. In general, carcinoids greater than 1 cm in diameter should be highly suspect for mesoappendiceal invasion, whereas tumors less than 1 cm infrequently will show such extension. In all cases, the mesoappendix should be carefully examined.

Whenever the mesoappendix is involved with tumor, the question arises whether more than a simple appendectomy should be performed. Unfortunately, the definitive data are still unavailable. For each patient, the risks of leaving tumor behind must be weighed against the risks of an elective ileocolicectomy. In an otherwise healthy patient who can look forward to a long life span, our current policy is to perform an ileocolicectomy when the mesoappendix is invaded by carcinoid. This policy seems particularly appropriate when a mesoappendiceal lymph node is infiltrated with tumor. We suggest that involvement of the mesoappendix may prove a valuable marker for regional node spread and justify our aggressive surgical approach.

References

1. Campanale, R. P. and Prothero, S. R.: Malignant Appendiceal Carcinoid (Argentaffinoma) with Regional Lymph Node Metastasis. *Am. J. Surg.*, 107:855, 1964.
2. Cunningham, P. J., Norman, J. and Cleveland, B. R.: Malignant Carcinoid Associated with Thoraco-Abdominal Aneurysm and Analysis of 31 Cases of Gastrointestinal Carcinoid Tumors. *Ann. Surg.*, 176:613, 1972.
3. Dent, T. L., Batsakis, J. G. and Lindenaue, S. M.: Carcinoid Tumors of the Appendix. *Surgery*, 73:828, 1973.
4. Godwin, J. D., II: Carcinoid Tumors: An Analysis of 2837 Cases. *Cancer*, 36:560, 1974.
5. Hopping, R. A., Dockerty, M. B. and Masson, J. C.: Carcinoid Tumor of the Appendix. Report of a Case in which Extensive Intra-abdominal Metastases Occurred. *Arch. Surg.*, 45:613, 1942.
6. Kantor, S., Crane, R. D. and Gillesby, W. J.: Carcinoid Tumors of the Gastrointestinal Tract. *Am. Surg.*, 27:448, 1961.
7. Kieraldo, J., Eversole, S. and Allen, R.: Carcinoid Tumor of the Vermiform Appendix with Distant Metastasis. *Calif. Med.*, 99:161, 1963.
8. Latham, W. D., Arnold, H. S. and Ede, S.: Kultschitzky-Cell Carcinoma (Carcinoid) of the Appendix with Metastasis. *Am. J. Surg.*, 102:607, 1961.
9. MacDonald, R. A.: A study of 356 Carcinoids of the Gastrointestinal Tract. *Am. J. Med.*, 56:867, 1956.
10. Markgraf, W. H. and Dun, T. M.: Appendiceal Carcinoid with Carcinoid Syndrome. *Am. J. Surg.*, 107:730, 1964.
11. Merling: Cited by Forbus, W. D.: Argentaffin Tumors of the Appendix and Small Intestine. *Bull. Johns Hopkins Hosp.*, 37:130, 1925.
12. Moertel, C. G., Dockerty, M. B. and Judd, E. S.: Carcinoid Tumors of the Vermiform Appendix. *Cancer*, 21:270, 1968.
13. Morgan, J. G., Marks, C. and Hearn, D.: Carcinoid Tumors of the Gastrointestinal Tract. *Ann. Surg.*, 180:720, 1974.
14. Pearlman, D. M. and Srinivasan, K.: Malignant Carcinoid of the Appendix. *N.Y. State J. Med.*, 71:1529, 1971.
15. Ponka, J. L.: Carcinoid Tumors of the Appendix: Report of Thirty-Five Cases. *Am. J. Surg.*, 126:77, 1973.
16. Ranson, W. B.: A Case of Primary Carcinoma of the Ileum. *Lancet*, 2:1120, 1890.
17. Turner, M. Gallager, H. S.: Occult Appendiceal Carcinoid. Report of a Case with Fatal Metastases. *Arch. Pathol.*, 88:188, 1969.