

# Preservation of the Pylorus in Pancreaticoduodenectomy

## A Follow-up Evaluation

L. WILLIAM TRAVERSO, M.D., WILLIAM P. LONGMIRE, JR., M.D.

We have previously reported our efforts to minimize postgastrectomy symptoms in two patients with benign disease who underwent resection of the head of the pancreas and the duodenum. In these cases the pylorus and first portion of the duodenum were preserved during pancreaticoduodenectomy. Our experience has now been extended to encompass 18 patients, eight of whom were available for comprehensive evaluation an average of six months postoperation. These studies have attempted to differentiate malabsorption of pancreatic insufficiency from possible gastrointestinal dysfunction of the new alimentary connection. Pancreatic insufficiency was evaluated by a 72-hour stool collection and radioactive trioctanoate (RATO) test. Gastrointestinal absorption was evaluated by D-xylose excretion and the Schilling test, as well as serum vitamin A, vitamin B-12, carotene, folate, iron, and total iron binding capacity. Gastrointestinal secretion and motility were assessed by using pyloric fluoroscopy, gastric barium emptying, the Hunt test, and gastric acid analysis. Finally, a questionnaire regarding clinical symptoms of postgastrectomy syndromes and malabsorption was answered. Although every patient exhibited marked pancreatic insufficiency by laboratory tests, 88% described normal formed bowel movements, and weight loss was claimed by only 25%. Other test findings were generally normal. While the follow-up period has been limited to three years, the current data demonstrate that gastrointestinal function subsequent to preservation of the pylorus has not thus far predisposed to postgastrectomy syndromes or marginal ulcers. All of the patients required intensive pancreatic enzyme replacement.

**D**URING PANCREATICODUODENECTOMY for pancreatic cancer, a 50–70% gastrectomy with or without truncal vagotomy is customarily performed to prevent marginal ulcer from developing at the gastrojejunostomy and to provide an adequate pancreatic tumor resection. However, removal of the pylorus during pancreaticoduodenectomy for benign disease

*From the Department of Surgery, UCLA School of Medicine, Los Angeles, California*

may needlessly predispose the patient to postgastrectomy symptoms of dumping, diarrhea, or dyspepsia. We previously reported two patients in whom the pylorus as well as the first portion of the duodenum was preserved, one for chronic pancreatitis and the other for a distal duodenal carcinoma (Figs. 1 and 2).<sup>8</sup> Both patients remained free of postoperative complications related to the preserved pylorus; they had no gastric outlet difficulty, nor did they complain of postgastrectomy symptoms. Since then, we have had this experience with 18 patients, and this report concerns the impact that postpancreaticoduodenectomy with pylorus preservation had on gastric secretion, gastric emptying, exocrine insufficiency, and small bowel absorption.

### Materials and Methods

In the two-year period between 1977 and 1979, 18 patients underwent pancreaticoduodenectomy (four total pancreatectomies) with preservation of the pylorus for chronic pancreatitis or for early periampullary carcinoma. Eight patients were available for evaluation from two months to one year postoperation. Six had been diagnosed as having chronic pancreatitis: three total pancreatectomies, three Whipple procedures, one a distal duodenal carcinoma (Whipple), and one a small pancreatic carcinoma (Whipple). All those who had a pancreatic remnant underwent a duct-to-jejunal anastomosis. They were questioned carefully concerning weight loss, nausea and vomiting, postprandial cramping, diarrhea, steatorrhea, and early satiety. Gastric emptying and pyloric function were observed via an upper gastrointestinal series with barium. Gastric emptying was also evaluated by using a standard Hunt test. After fluoroscopy of the nasogastric tube in the stomach, gastric analysis was per-

Presented at the Annual Meeting of the American Surgical Association, Atlanta, Georgia, April 23–25, 1980.

Correspondence: L. William Traverso, M.D., Division of Surgery, Letterman Army Institute of Research, Presidio of San Francisco, California 94129.

Reprint requests: William P. Longmire, Jr., M.D., Department of Surgery, UCLA, Los Angeles, California 90024.

Supported in part by a grant from the Weingart Foundation.

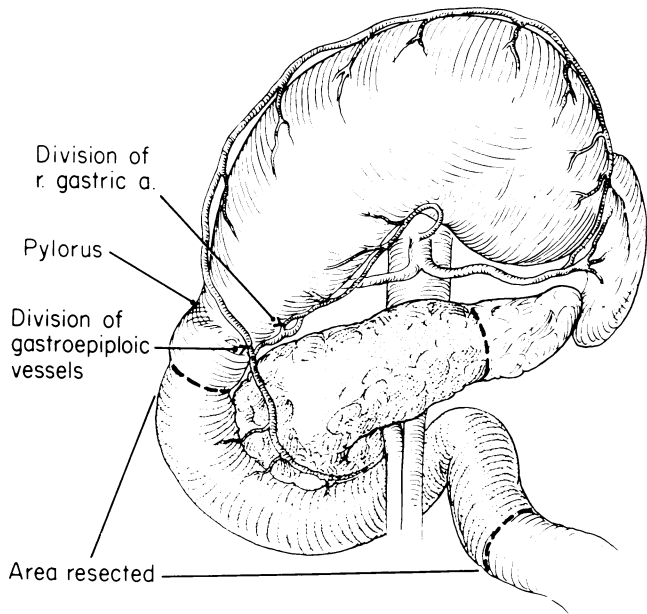


FIG. 1. Area of pancreas and duodenum resected. Ligation of right gastric and gastropyloric vessels to preserve the vascular arcade on lesser and greater curvature of the stomach. An intact neurovascular supply to the pylorus and first portion of the duodenum is mandatory for success (see Discussion section). (Reprinted with permission from Surg Gynecol Obstet 146:959, 1978.)

formed by basal and pentagastrin-stimulated measurements. Exocrine function was assessed with the radioactive trioctanoate test (RATO),<sup>6</sup> a 72-hour stool was checked for fecal fat after a regimen of oral enzyme

supplements on a regular diet, and finally, the Schilling test, showing dependence on exocrine enzymes for absorption of vitamin B-12 in the ileum. The pancreas is thought to provide a third factor essential to B-12 absorption, aside from extrinsic and intrinsic factors.<sup>7</sup> The status of small bowel absorption was evaluated by using serum carotene and the oral D-xylose test with a five-hour urine collection. These methods were employed to evaluate the effect of pancreaticoduodenectomy and pylorus preservation on alimentary function and postoperative exocrine insufficiency.

**Results**

The clinical symptoms listed in Table 1 and the following test results were obtained an average of 5.75 months postoperation (range: 2–12 months). The results of pylorus fluoroscopy and gastric emptying during a gastrointestinal series using barium were normal in all patients. Findings of the Hunt test were normal in all but one patient, who was asymptomatic with normal radiographic gastric emptying. Gastric analysis yielded normal to achlorhydric results in all patients. The basal acid mean output was 1.9 mEq/hr (0–4.1) and the maximum acid mean output was 17 mEq/hr (0.1–24).

Pancreatic exocrine function was found to be abnormal in all patients; 72-hour fecal fat collections averaged 44 grams/24 hours (13–145); normal was

FIG. 2. Reconstruction with lateral pancreaticojejunostomy, end-to-side choledochojejunostomy and end-to-side duodenojejunostomy. (Reprinted with permission from Surg Gynecol Obstet 146:959, 1978.)

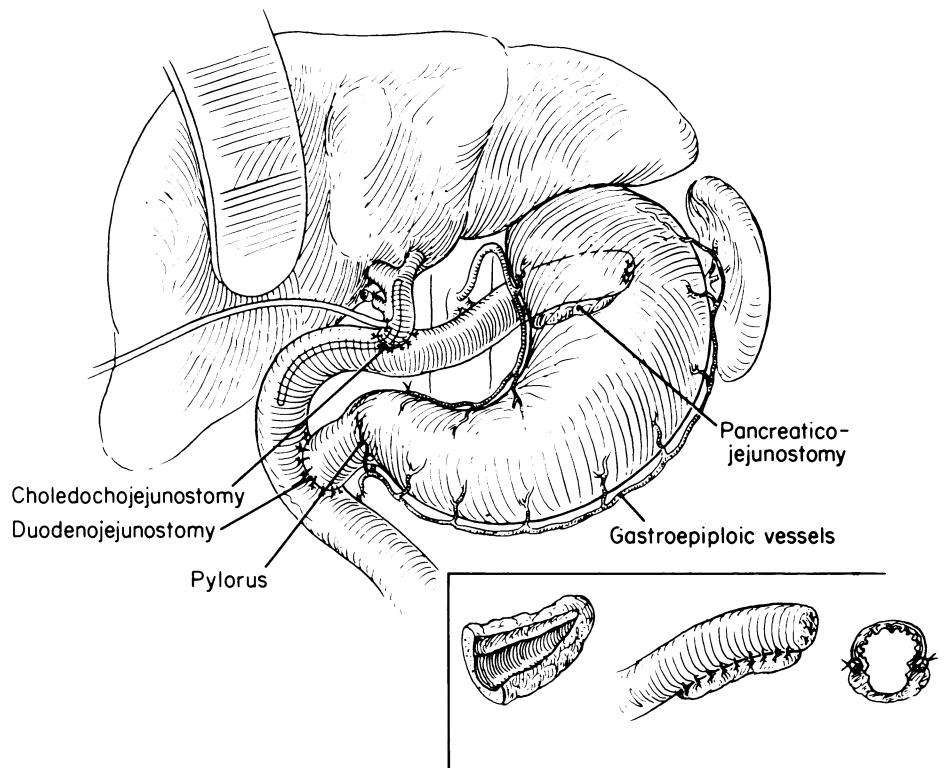


TABLE 1. *Postoperative Clinical Symptoms*

| Symptom                   | Yes | No |
|---------------------------|-----|----|
| Weight loss               | 2   | 6  |
| Vomiting                  | 1*  | 7  |
| Early satiety             | 0   | 8  |
| Postprandial cramps       | 0   | 8  |
| Postprandial diarrhea     | 1   | 7  |
| Increased bowel movements | 1   | 7  |
| Oily stools               | 4   | 4  |
| Improved with enzymes     | 5   | 0† |

\* Cleared after one month.

† Three took no oral enzyme supplements.

less than 7 g/24 hours. Results of the RATO test were markedly abnormal in every patient regardless if pancreatic enzyme supplements were taken: an average 1.15% recovery of isotope (0.0–3.4%) (normal recovery:  $18.6 \pm 2.6\%$ ). The average recovery for total pancreatectomy patients was 1.4% (0.4–3.4%), and for those with cephalic pancreaticoduodenectomy, it was 1.0% (0.0–2.8%).

Findings of the Schilling test were abnormally low in 24-hour urine counts for one patient (1.0% of orally administered labelled vitamin B-12), while the remaining patients averaged 11% (4.8–20.8%) with an abnormal count less than 3%. Results of the D-xylose test for small bowel absorption were abnormal in two patients who had undergone resections for cancer. An average of 6.9 g (3–10 g) of xylose was excreted in a five-hour urine sample after the oral administration of 25 g of D-xylose (normal was greater than 5 g). Serum carotene obtained in six patients was abnormally low in 5, averaging 45  $\mu\text{g}/\text{dl}$  (10–136), normal being 50–250  $\mu\text{g}/\text{dl}$ .

### Discussion

Alimentary and pyloric functions subsequent to pancreaticoduodenectomy and pylorus preservation do not seem to be impaired. The postgastrectomy syndrome was not present in our series. One patient who suffered persistent evening vomiting for one month postoperation was found, on fluoroscopy, to have normal pyloric function and gastric emptying. In all cases, gastric analyses failed to reveal a hypersecretory state that could follow pancreatic or biliary bypass into the small intestine. Normal acid secretion was present in all but one achlorhydric patient. No marginal ulcers were found, although ulceration might have occurred if a functioning pylorus had been removed in the presence of normal gastric acidity.

Grant and van Heerden,<sup>4</sup> in a review of 297 patients who had undergone either radical pancreaticoduodenectomy or total pancreatectomy, found that 18 (6%) patients had developed an anastomotic ulcer and that

total pancreatectomy was more ulcerogenic than the subtotal procedure. The average interval from operation to diagnosis of ulcer was 1.25 years, ranging from one month to 12 years; eight patients developed marginal ulcer in less than one year, five of whom had undergone a total resection. Four patients developed ulcers during the second year, three the third year, and three developed ulcers more than three years after operation.

The marked pancreatic insufficiency (demonstrated by breath test and fecal fat elevation) in all six patients without cancer, in the presence of normal small bowel absorption, is highly significant. This lack of fat assimilation was not always detected clinically, inasmuch as only half of our patients claimed oily stools or increased bowel movements. Although the incidence of weight loss was 25% in our series, the percentage might have increased if patients had not continued a high-calorie intake to overcome the malabsorption. Javid,<sup>5</sup> as well as Wollaeger and colleagues,<sup>10</sup> have shown that fecal fat loss increases to an average of 30% after subtotal gastrectomy alone. A pancreaticoduodenectomy with gastric resection would compound the problem of diminished fat assimilation if oral pancreatic enzymes were not adequately replaced. We have been encouraged by the use of Pancrease®\* in these patients after they are determined to have exocrine insufficiency. Microspheres of enteric-coated pancreatic enzymes are dispersed in the gastric mulch, delivering a highly active product to the jejunum. A double blind study comparing this drug to other commercial enzyme supplements has shown significantly improved weight gain and fat assimilation.<sup>9</sup> Our experience also confirms the fact that refractory steatorrhea and weight-loss are ameliorated with Pancrease.

Alimentary function subsequent to pancreaticoduodenectomy has been rarely assessed because most patients who suffer from pancreatic cancer survive only a short time. Fish and associates<sup>2</sup> studied six patients for periods lasting from 20 to 84 months after the Whipple procedure for periampullary carcinoma, none of whom had undergone a duct-to-jejunal anastomosis. All manifested some pancreatic insufficiency; half were unable to gain weight, yet showed normal intestinal absorption by D-xylose test. All had increased fecal nitrogen and fat levels that improved with more adequate pancreatic enzyme replacement. Four patients suffering from cancer of the duodenum or papilla of Vater were studied by Christiansen and colleagues<sup>1</sup> for periods from eight to 27 months following pancreaticoduodenectomy and a pancreatic

\* Johnson & Johnson Baby Products Co., Piscataway, NJ.

stump-to-stomach anastomosis. Fecal fat excretion was markedly elevated in two patients, and all had low-to-minimum pancreatic enzyme levels in the proximal jejunum. Those with fecal fat elevation also showed the highest peak acid output during gastric analysis. Pancreatic anastomoses, whether constructed to the duct or the stump, functioned poorly in our patients as well as in those reported in the foregoing two studies.<sup>1,2</sup> These data underscore the need for vigorous exocrine enzyme replacement after all pancreaticoduodenectomies until the findings of fecal fat studies approach normal levels.

Although we have observed no postoperative complications with the eight procedures during our limited three-year follow-up period,<sup>†</sup> there have been two reports of postoperative problems. Gall and Gebhardt<sup>3</sup> have performed three pylorus preservation procedures and describe two instances where reoperation was necessary, each associated with jejunal loop strangulation in the mesocolon as the stomach shifted from the subhepatic area through the mesentery. While we routinely suture the retrocolic jejunal loop to the mesenteric defect and do not anchor the stomach, these investigators suggested that the lesser curvature be sutured to the ligamentum teres. Other European surgeons have described gastric erosions following this procedure. Such complications would be best avoided by insuring an adequate neurovascular supply to the pylorus. Otherwise, gastric stasis and ulcers would develop behind a nonfunctioning or strictured pylorus.

### Addendum

Subsequent to the preparation of this report, one patient was admitted 16 months postoperation with a suspected but unproven peptic ulcer and upper gastrointestinal hemorrhage. Her diagnosis has been complicated by a severe fatty liver, abnormal liver function tests, and evidence of moderate portal hypertension.

### Case Report

A 16-year-old girl with a congenital obstruction of the duct of Wirsung, an abnormal glucose tolerance, and three previous operations for pancreatic drainage, underwent total pancreatectomy with preservation of the pylorus for severe chronic pancreatitis on September 6, 1978. When readmitted to the hospital on November

5, 1978 for an elective re-evaluation of her gastrointestinal function, findings of gastric analysis, upper GI series and Hunt test were normal. The RATO test indicated inadequate digestion and absorption of fat. She was asymptomatic, eating well and had regained her usual weight. She was taking 35 units of NPH insulin daily and three Pancrease capsules with each meal.

The patient was readmitted on January 27, 1980 with severe epigastric pain and tenderness about an incarcerated upper midline incisional hernia. Results of an upper GI series were negative and the gastric analysis remained unchanged. Endoscopic examination disclosed moderate esophageal varices and what was thought to be a superficial ulceration in the pyloric channel. Liver function test results were abnormal and severe fatty changes were present in tissue obtained by liver biopsy. On February 8, 1980 she was discharged, taking Cimetidine with antacids and feeling well.

An acute upper gastrointestinal hemorrhage required emergency admission on February 23, 1980, but after her condition was stabilized by the transfusion of 6 units of blood no further bleeding occurred. On endoscopy, a bleeding duodenal erosion was suspected. Three days later at re-exploration, however, no ulcer could be found in the stomach, duodenum or jejunum. The duodenal and jejunal mucosa was quite friable and bled readily. Enlarged veins were noted about the lower esophagus. Vagotomy and antrectomy were performed. No ulcer was present in the resected stomach, duodenum or jejunal margin. The findings suggest that bleeding stemmed from moderate portal hypertension with duodenitis and jejunitis.

### References

- Christiansen J, Olsen JH, Worning H. The pancreatic function following subtotal pancreatectomy for cancer. *Scand J Gastroenterol* 1971; 6(Suppl 9):189.
- Fish JC, Lindsay BS, Williams RD. Digestive function after radical pancreaticoduodenectomy. *Am J Surg* 1969; 117:40.
- Gall FP, Gebhardt C. Ein neues konzept in der chirurgie der chronischen pankreatitis. *Deutsche Medizinische Wochenschrift* 1979; 104:1003.
- Grant CS, van Heerden JA. Anastomotic ulceration following subtotal and total pancreatectomy. *Ann Surg* 1979; 190:1.
- Javid H. Nutrition in gastric surgery with particular reference to nitrogen and fat assimilation. *Surgery* 1955; 38:641.
- Schwabe AD, Valdivieso VD, Ortega C, Bennett LR. The use of a <sup>14</sup>C-labelled medium chain fat in the study of malabsorptive disorders. *Recent Adv Gastroenterol (Tokyo)* 1967; 2:209.
- Toskes PP, Deren JJ. The role of the pancreas in vitamin B-12 absorption: studies of vitamin B-12 absorption in partially pancreatectomized rats. *J Clin Invest* 1972; 51:216.
- Traverso LW, Longmire WP, Jr. Preservation of the pylorus during pancreaticoduodenectomy. *Surg Gynecol Obstet* 1978; 146:959.
- Valerio D, Whyte EHA, Schlamm HA, Blackburn GL. Enzyme replacement therapy in pancreatic insufficiency. *J Parent Ent Nutr* 1977; 1:20B.
- Wollaeger EE, Waugh JM, Pomes MH. Fat-assimilating capacity of the gastrointestinal tract after partial gastrectomy and gastroduodenostomy. *Gastroenterology* 1963; 44:25.

<sup>†</sup> See Addendum.

### DISCUSSION

DR. JOHN WILLIAM BRAASCH (Boston, Massachusetts): Pyloric and gastric preservation has several possible advantages for the patient having a pancreaticoduodenectomy. It is probable that malabsorption after Whipple resection is partly caused by concomitant

gastric resection. It may be possible to avoid some of the digestive and absorptive defects by gastric preservation.

Pyloric preservation markedly reduces operative time since no vagotomy is performed, no dissection of the stomach is necessary and the anastomosis of the duodenum is much simpler than that using stomach.