

# Selective Repair of Neonatal Gastroschisis Based on Degree of Visceroabdominal Disproportion

ERIC W. FONKALSRUD, M.D.

*From the Division of Pediatric Surgery,  
UCLA School of Medicine, Los Angeles, California*

Based on 14 years' experience with the surgical repair of gastroschisis abdominal wall defects in 32 infants at the UCLA Hospital, certain aspects of care evolved which have served to reduce the overall long-term mortality to 6.2%. The severity of gastroschisis defects appears to be related to the length of time the eviscerated intestine has been exposed to amniotic fluid, and the degree of vascular obstruction to the viscera. In contrast to reports by previous authors recommending a specific operative technique for all infants with this malformation, we believe that choice of the optimal surgical repair depends on the degree of disproportion between the size of the eviscerated intestine and the size of the abdominal cavity. Three of the 32 patients with minimal disproportion underwent primary skin and muscle closure followed by early recovery. Twenty-seven who had primary skin flap closure later underwent secondary ventral hernia repair within six to 12 months. Two of the 32 infants had severe visceroabdominal disproportion and required temporary prosthesis coverage in addition to extensive skin flaps during the primary repair. The low morbidity and mortality following gastroschisis repair are apparently related to these factors: avoiding undue compression of the viscera; early coverage of the contaminated viscera with skin or muscle to minimize infection; careful supportive perioperative management to maintain body heat and provide adequate fluid repletion; and the infusion of intravenous hyperalimentation solutions during the lengthy period of postoperative ileus. Prosthetic materials should be reserved for more complex abdominal wall reconstruction in infants who have severe visceroabdominal disproportion.

**G**ASTROSCHISIS IS A FULL-thickness cleft in the abdominal wall resulting from a developmental failure of one of the lateral abdominal plates of the somatopleure.<sup>5</sup> The abdominal defect, characteristically located to the right of the intact umbilical cord, rarely measures more than 2.5–3 cm in diameter. Herniation of the major portion of the intestine, usually extending from the stomach through the sigmoid colon into the amniotic cavity, may occur at varying periods during the third trimester of gestation. Because no amniotic or peritoneal membrane covers the viscera, there

is prolonged exposure of the eviscerated intestine to the amniotic fluid. Congestion and edema accompanied by matting of the intestinal loops occur, presumably from partial lymphatic and venous obstruction in the mesentery combined with visceral exposure to the amniotic fluid. The associated incomplete fixation of the small bowel to the posterior abdominal wall may produce partial torsion of the exposed viscera. The exposed bowel often appears thickened, foreshortened, congested, and even nonviable at birth, although occasionally it may appear almost normal depending on how long the intestine has been exposed to the amniotic fluid and the degree to which the vascular supply is obstructed. Infants with this condition tend to be premature and most are born to mothers younger than 20.<sup>14</sup>

Until 15 years ago, the mortality for infants with gastroschisis exceeded 50%. However, since then, this rate has steadily declined during the past few years due to improved operative techniques and close attention to the details of pre- and postoperative management. The original method of repair proposed by Gross<sup>3</sup> consisting of initial skin flap closure and late secondary ventral hernia repair has largely been replaced by the use of prosthetic materials to cover the eviscerated intestine as suggested by Schuster<sup>13</sup> and Allen and Wrenn.<sup>2</sup> Although many reports recommend one operative repair as being superior to another, our experience indicates that the severity of intestinal edema and the disparity between the size of the eviscerated intestine and the abdominal cavity will determine which operative technique is best for an individual patient. The findings from our review of the 14-year experience at UCLA Hospital in treating 32 patients with gastroschisis suggest that the condition can usually be repaired by using skin flap closure with low mortality. Nevertheless, in certain infants with mild visceroabdominal disproportion the skin and muscle can be closed primarily with minimal risk of morbidity. Another small

Presented at the Annual Meeting of the Pacific Association of Pediatric Surgeons, Mazatlan, Mexico, March 31–April 2, 1979.

Reprint requests: Eric W. Fonkalsrud, M.D., Division of Pediatric Surgery, UCLA Medical Center, Los Angeles, California 90024.

Submitted for publication: June 14, 1979.

TABLE 1. Associated Malformations with Gastroschisis (32 Patients)

Malformation	No. pts.
Malrotation with incomplete small bowel fixation	32
Undescended testes	6
Urinary tract anomalies	3
Duodenal bands	2
Congenital heart defect	2
Bladder exstrophy	1
Jejunal atresia	1
Biliary atresia	1

group of patients, however, may have such extensive disproportion as to require the use of a prosthetic patch in addition to the skin flap elevation.

### Materials and Methods

Thirty-two infants with antenatal gastroschisis underwent surgical repair at UCLA Hospital in the period between 1965 and 1979. Among the 17 males and 15 females, the average birth weight was 2,558 and 15 were premature by weight and gestational age. Twenty-eight of the 32 mothers were 20 years of age or younger. All of the infants had incomplete fixation of the bowel mesentery and intestinal malrotation, although associated malformations were far less common than in those infants treated at our hospital for omphalocele (Table 1). Six of the males had undescended testes, three infants had urinary tract anomalies, had two had congenital duodenal bands causing obstruction. Two suffered associated congenital heart defects; one had jejunal atresia and another had biliary atresia. Approximately half of the infants were believed to have a shorter than normal intestine at the time of surgical repair; however, only the one with jejunal atresia among those who were followed for more than one year or who underwent secondary closure of the ventral hernia showed clinical evidence of having a shortened small intestine.

The gastroschisis defect was surgically repaired in all 32 infants within the first 12 hours after birth. In 27 cases, the linea alba was opened from the xiphoid to the pubis and skin flaps were developed extending to the posterior axillary line. The abdominal muscles were forcefully stretched in order to accommodate the viscera more easily, and the intestine itself was carefully manipulated to push the bowel contents proximally into the stomach where they be removed through a gastrostomy tube, or distally where they were expelled through the anus. The skin flaps were then reapproximated over the viscera with mild to moderate tension depending upon the degree of viscerabdinal disparity (Fig. 1).

In three infants in whom the eviscerated intestine appeared minimally edematous or matted together, it was possible to return all the viscera to the abdominal cavity with primary closure of muscle and skin under minimal tension (Fig. 2)

The intestine was so edematous and congested in two other patients that it was not feasible to provide skin flap coverage without severe tension, and therefore we placed a temporary Silastic prosthesis between the edges of the skin flaps (Fig. 3). Ten days later the prosthesis was removed and the skin flaps were reapproximated over the intestine.

A Stamm gastrostomy tube was inserted at the time of initial operative repair in all of the infants. The jejunal atresia was repaired by resection of the bulbous proximal segment and primary anastomosis at the time of the skin flap closure. In no other patient was it necessary to excise a segment of intestine. The infant with bladder exstrophy was treated by skin flap closure immediately after birth and by ventral hernia repair at the age of one year followed by cystectomy and construction of an ileocutaneous ureterostomy three years later. Second-stage repair subsequent to skin flap closure was performed on 24 infants averaging eight months of age. In two patients who underwent ventral hernia repair less than seven months post-operatively, and in two others who had severe viscerabdinal disproportion as a newborn, it was not possible to approximate the rectus muscles in the midline

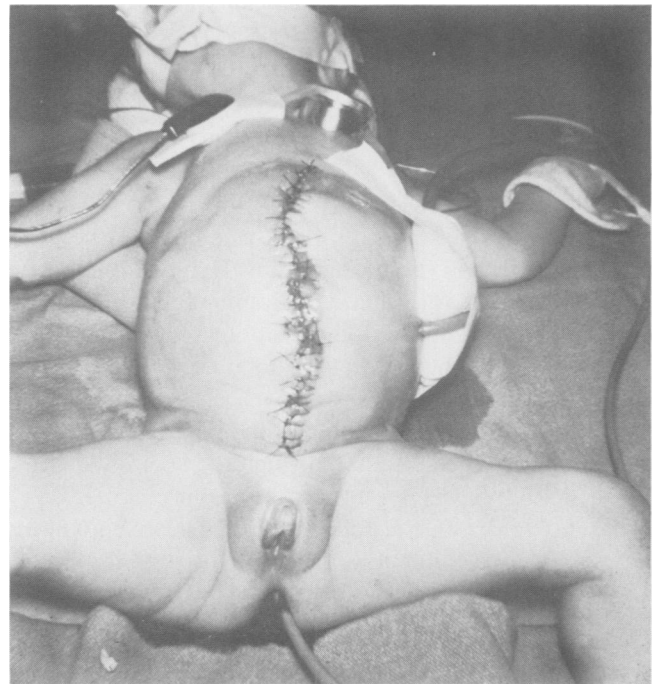


FIG. 1. Infant with moderate viscerabdinal disproportion repaired by skin flap closure. Note moderate abdominal distention.

without severe tension. In each of these four patients a small Silastic prosthesis was temporarily inserted between the muscles and covered with short skin flaps until the third-stage repair with muscle approximation six to 10 months later.

The abdominal wall closure in all cases was performed under only mild tension to minimize post-operative respiratory distress and make it possible to extubate the infant, within four hours in almost every case.

An urgent attempt was made preoperatively to maintain normal body temperature by covering the viscera with a plastic bag and placing the infant in a heated Isolette (Fig. 4). Careful intravenous resuscitation was performed before anesthetizing the infant. Operative hypothermia was minimized by using an overhead infrared heating lamp during the early phase of the study. Moreover, since 1975, warmed humidified anesthetic gases have been used to reduce operative heat loss. Moist sponges were sparingly used to reduce

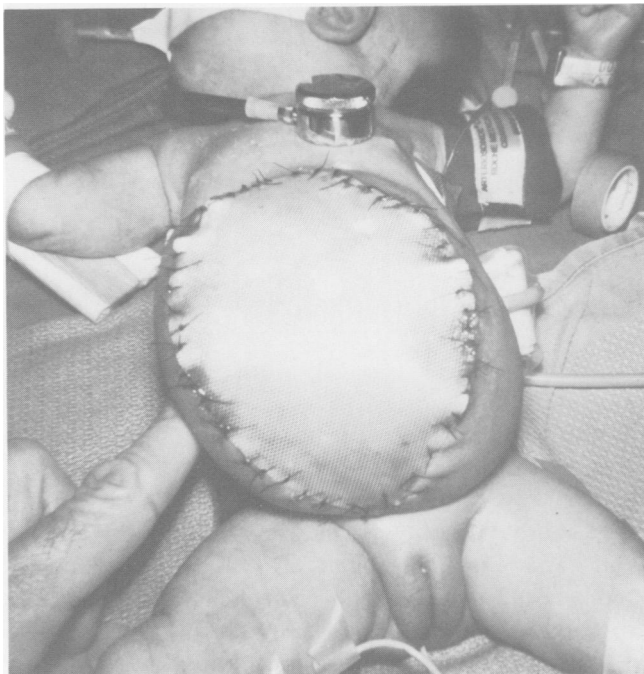

FIG. 3. Infant with severe viscerabdrominal disproportion in whom skin flap closure alone was not feasible and a temporary Silastic prosthesis was placed between the skin flaps.

evaporative heat loss and minimize serosal irritation before and during operation.

Peripheral intravenous hyperalimentation was used

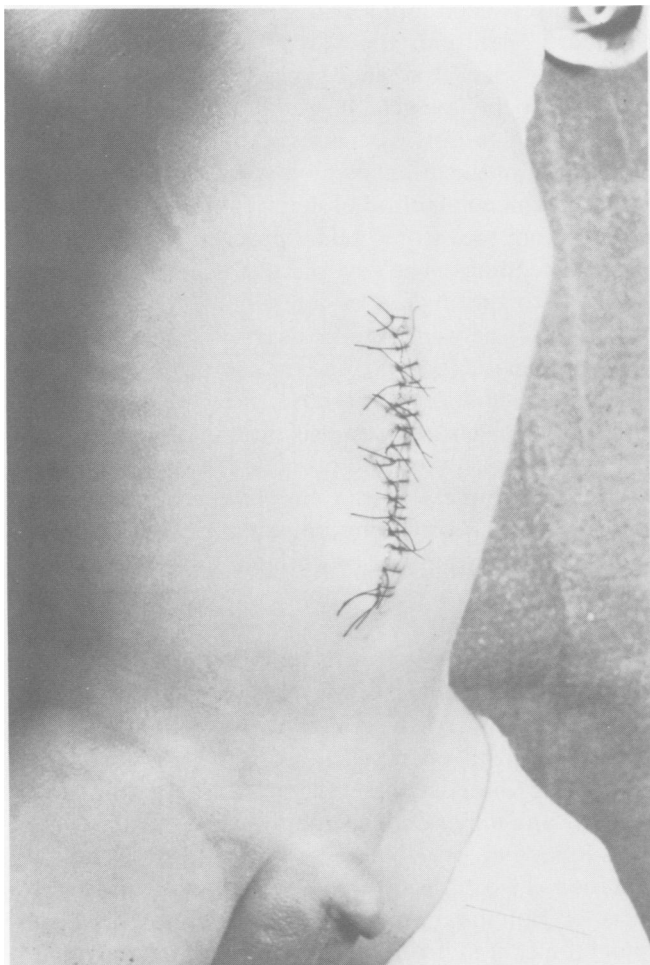


FIG. 2. Abdominal defect in infant with mild viscerabdrominal disproportion repaired by primary muscle and skin repair.

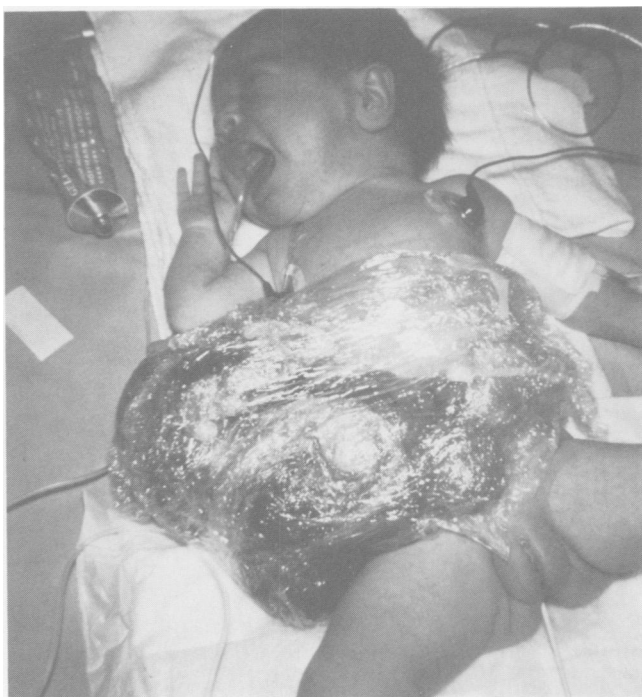

FIG. 4. Plastic (Saran wrap®) covering placed over eviscerated intestine to reduce heat and fluid loss until defect is repaired.

TABLE 2. Postoperative Complications after Gastroschisis Repair

Complication	After initial closure (32)	After secondary repair (24)
Pneumonia	2	2
Wound separation	3	0
Small bowel fistula	1	0
Small bowel obstruction	1	1
Sepsis	2	0
Incisional hernia	0	2
Seizures	1*	0
Liver failure, bleeding disorder	0	1*

\* Died.

in 28 of the 32 infants with no substantial morbidity (average 36 days). Three were treated before hypercaloric parenteral nutrition was available, and another received only electrolyte solution and human plasma protein fraction (Plasmanate). A central venous hyperalimentation catheter was used in only one infant.

Subsequent to skin flap closure, a gastrostomy tube assisted progressive feedings and removed excessive air from the stomach, but was removed an average of four months later. Two infants required surgical closure of persistently draining gastrostomy wounds. An elastic (Ace®) bandage was wrapped around the abdomen after the third month following initial repair to gradually compress the viscera into the abdominal cavity.

### Results

Thirty of the 32 infants are currently alive four months to 14 years after initial repair (average, 4.6 years). Two of the infants (6.2%) died during the first two years after surgical repair of the deformity. One premature infant died unexpectedly 16 days after operation from seizures of undetermined cause; post-mortem examination failed to reveal the cause of death. This infant had no other major defects and was clinically making a good recovery until his sudden death. Another patient, who died at 19 months of age with intrahepatic biliary atresia, had experienced progressive jaundice since the first month of life and shown progressive evidence of portal hypertension with hepatosplenomegaly and abnormal liver function tests, as well as abnormal clotting studies.

During second-stage closure of the large ventral hernia in 24 infants, simultaneous appendectomy was also performed and intestinal adhesions were divided completely in all but five patients, one of whom developed postoperative obstruction that required reoperation. In no case was the intestine sutured to the abdominal wall to prevent volvulus. Three boys under-

went orchiopexy at the time of secondary repair of the abdominal defect, and two others at three and four years of age. A sturdy abdominal closure with good cosmetic result was achieved in each case. Although the weight of every infant was below the 25th percentile at the age of one month, 20 of the 25 patients who are currently more than one year of age showed excellent "catch-up" growth and are above the 50th percentile in weight. The average initial period of hospitalization was 66 days.

The major postoperative complications following initial repair and secondary ventral hernia repair are listed on Table 2. Pneumonia occurred in two patients after initial skin closure and in two others after secondary repair. A minor degree of wound separation occurred in three infants following skin closure, although none required secondary reconstruction. A small bowel fistula developed in one patient subsequent to skin closure, requiring surgical closure and parenteral nutrition with bowel rest. Small bowel obstruction developed in one infant following skin closure and another after secondary repair, each of whom required secondary operations for lysis of adhesions. Two infants experienced transient sepsis subsequent to skin flap closure, believed to be related to pneumonia in one case and to intravenous hyperalimentation in the other. Most of the infants who had extensive evisceration experienced a period of ileus lasting as long as six weeks before they could take appreciable volumes of intestinal feedings. The severity of the ileus correlated closely with the degree of intestinal edema and the severity of visceroperitoneal disproportion. Ileus was minimal in patients who underwent primary muscle and skin flap closure and in those who had skin closure with minimal tension. Emesis in the postoperative period rarely occurred and no patient experienced aspiration, due largely to the effectiveness of the gastrostomy tube in providing intestinal decompression. There were no complications related to the use of the gastrostomy which was removed an average of four months postoperatively.

During the same period of study, seven additional infants with gastroschisis were transferred to UCLA Hospital suffering severe complications following other types of surgical repair. Of three who had more than 50% of the intestine resected because of intestinal necrosis, one experienced superior vena caval thrombosis following prolonged central venous hyperalimentation. Two of these infants subsequently died with sepsis or pulmonary complications. Three of these seven infants are currently outpatients receiving home total parenteral nutrition through a central venous (Broviac) catheter.

## Discussion

In 1963, Moore<sup>9</sup> emphasized that the major factors influencing survival after surgical repair of gastroschisis were prematurity, the presence of additional malformations, the promptness of the operation, and the disparity between the eviscerated mass and the peritoneal cavity. Lewis and associates<sup>6</sup> have reported that early surgical repair minimizes gross bacterial contamination, reducing the likelihood of ischemic injury to the bowel, and deterring heat and fluid loss. As observed previously,<sup>14</sup> successful management of an infant with gastroschisis depends as much if not more on the perioperative management as on the surgical repair itself. Preservation of body heat by using a plastic sheet (Saran wrap<sup>®</sup>) to cover the eviscerated gut prior to operation is more efficient than the use of warm saline-soaked gauze sponges and is less irritating to the exposed intestinal serosa. Moreover, the fluid loss appears to be less when plastic sheet coverage is provided. The need to correct fluid volume deficiency and metabolic acidosis prior to operation has been stressed by Mollitt and associates<sup>8</sup> and should not be deferred until general anesthesia has been initiated. Intravenous antibiotics are beneficial in reducing bacterial contamination and sepsis from the exposed bowel; however, most reported cases of sepsis are apparently more related to compression of the viscera with vascular impairment following surgical closure, or to prolonged close apposition of a foreign body prosthesis to the viscera and skin.

It is apparent from the present case review that the optimal surgical repair for infants with gastroschisis depends upon the relative size of the eviscerated mass of intestine to that of the peritoneal cavity. Maneuvers to distend the abdominal musculature by forceful manual stretching during operation, as well as manipulation of intraluminal contents out from the rectum or up into the stomach for removal, may make it possible to close defects with less tension than otherwise might be the case. However, it is clear that these techniques usually will not make it feasible to close the rectus muscles and skin in the midline without severe compression of the intestine. Indeed, such compression may cause upward displacement of the diaphragm, partial obstruction of venous return through the vena cava, and may also cause ischemic injury to the intestine, particularly when the major portion of the bowel is highly edematous and may tear if kinked under moderate pressure. In our experience, approximately 10% of infants with gastroschisis can undergo complete closure of the muscle and skin at birth without undue pressure on the intestine, and progress very well

with a short hospital stay.<sup>11</sup> The intestine is less edematous and fills the contours of the abdominal cavity much more easily than in other infants whose viscera have been more extensively exposed to amniotic fluid. The majority of patients in the present series underwent the two-stage repair with initial skin flap closure as proposed by Gross,<sup>3</sup> followed by second-stage closure from six to 12 months postoperatively. Repair of the ventral hernia may be performed as early as six months of age in infants with mild visceroperitoneal disparity but should be delayed as long as a year in others with marked disproportion in order to avoid the need for a third operation to complete the abdominal closure. The low morbidity, overall mortality of 6.2%, and the brief initial hospital stay compare favorably with the 20–40% mortality reported by other authors who used the Silon chimney technique for repair.<sup>1,4,7,12</sup> A series of repeated manipulations and operations under general anesthesia during the neonatal period is generally required when the Silon chimney technique is employed.

Infants who suffer severe swelling of the eviscerated intestine are not amenable to skin flap closure (two of 32 patients in the present series). A combination of skin flap mobilization with temporary Silastic sheet prosthesis as in the two reported cases, or the Silon chimney technique alone may be used for closure in such patients. The combination of skin flap closure and temporary Silon mesh prosthesis provides a more rapid skin closure over the intestine and reduces the likelihood of sepsis, similar to a burn patient who has skin coverage of his wound. Both infants in the present report had the prosthesis removed within 10 days after initial repair.

As emphasized by O'Neill and Grosfeld,<sup>10</sup> intestinal malfunction may persist for long periods following gastroschisis repair; the length of the period of poor intestinal absorption appears to be directly related to the severity of the intestinal edema and to compromise in vascularity of the bowel from overcompression during the surgical repair or from sepsis. The variety of repair techniques described in the present report includes a means of repairing each type of gastroschisis, depending upon the severity of evisceration without unduly compressing the intestine, and while minimizing the period of contact between the contaminated bowel and a prosthesis. Sepsis has been rare after this type of repair. It is advisable to minimize the amount of wound manipulation, the number of operations under anesthesia, and the period of endotracheal intubation in the neonatal period. The use of peripheral (and occasionally central intravenous hypercaloric) alimentation during the entire period of postoperative ileus regardless of the type of repair has

greatly reduced the postoperative morbidity and mortality. Late secondary repair of a large ventral hernia in a six to 12-month-old infant appears to carry a much lower risk of morbidity and mortality than if complete repair is performed under adverse circumstances in early infancy. Prosthetic materials should not be used routinely in the initial repair of gastroschisis defects but should be reserved for more complex abdominal wall reconstruction in infants with severe visceroadominal disproportion.

### References

1. Aaronson IA, Eckstein HG. The role of the silastic prosthesis in the management of gastroschisis. *Arch Surg* 1977; 112:297.
2. Allen RG, Wrenn EL. Silon as a sac in the treatment of omphalocele and gastroschisis. *J Pediatr Surg* 1969; 4:3.
3. Gross RW. A new method for surgical treatment of large omphaloceles. *Surgery* 1948; 24:277.
4. Hollabaugh RS, Boles ET, Jr. The management of gastroschisis. *J Pediatr Surg* 1973; 8:263.
5. Hutchin P. Somatic anomalies of the umbilicus and anterior abdominal wall. *Surg Gynecol Obstet* 1965; 120:1075.
6. Lewis JE, Jr, Kraeger RR, Danis RK. Gastroschisis: ten year review. *Arch Surg* 1973; 107:218.
7. Mahour GH, Weitzman JJ, Rosenkrantz JG. Omphalocele in gastroschisis. *Ann Surg* 1973; 177:478.
8. Mollitt DL, Ballantine TVN, Grosfeld JL, Quinter P. A critical assessment of fluid requirements in gastroschisis. *J Pediatr Surg* 1978; 13:217.
9. Moore TC. Gastroschisis with antenatal evisceration of intestines and urinary bladder. *Ann Surg* 1963; 158:263.
10. O'Neill JA, Jr, Grosfeld JL. Intestinal malfunction after antenatal exposure of viscera. *Am J Surg* 1974; 127:129.
11. Raffensberger JC, Jona JC. Gastroschisis. *Surg Gynecol Obstet* 1974; 138:230.
12. Rubin SZ, Ein SH. Experience with 56 silon pouches. *J Pediatr Surg* 1976; 11:803.
13. Schuster SA. A new method for the staged repair of large omphaloceles. *Surg Gynecol Obstet* 1967; 125:837.
14. Thompson J, Fonkalsrud EW. Reappraisal of skin flap closure for neonatal gastroschisis. *Arch Surg* 1976; 111:684.