

Major Hepatic Resection for Malignant Neoplasms of the Liver

RICHARD D. BRASFIELD, M.D.,* LEMUEL BOWDEN, M.D.,
CHARLES J. McPEAK, M.D.

*From the Gastric Service, Memorial Hospital for
Cancer and Allied Diseases, New York City*

ALTHOUGH resection of the liver was sporadically employed during the late 19th and early 20th Centuries for treatment of certain hepatic neoplasms^{13,14,15,22,26,28,29}, it has been only in the past 20 years that certain interested surgeons have aggressively faced the problem of hepatic resection for cancer. Left hepatic lobectomy, with dissection of the *porta hepatis*, selective vascular and ductal ligation, and surgical resection of the left lobe, presents no great technical problem. Comparable resection of the right lobe of the liver is a formidable undertaking, however, and has become a standardized surgical procedure largely due to the endeavors of Quattlebaum²³ in the United States and Lortat-Jacob¹⁸ in France, who independently in 1952 reported their early experience in controlled right hepatic lobectomy. Since 1952 major hepatic resection has been increasingly employed by many surgeons in many parts of the world, and the results of this type of surgical treatment are now becoming evident.^{1,3,4,5,7,8,9,10,11,17,20,21,24,25}

Clinical Material for Analysis

During the 19-year period, 1950–1968, there have been 102 instances of hepatic resection in Memorial Hospital by attending surgeons or residents of the Gastric Service and of the Rectal and Colon Service. Almost half were either marginal excisions of the liver in continuity with a neoplasm of stomach or colon, or were simple wedge excisions of an apparent solitary metastasis in the liver from a primary neoplasm elsewhere. Five excisions were performed for benign lesions. Fifty-three procedures, however, involved resection of a major portion of the liver and all 53 were performed as independent surgical endeavors. Three of these major hepatic resections were

performed by a surgeon who preferred that they not be included in this study. The remaining 50 major hepatic resections* provide the material on which the following analysis is based.

Confusion in nomenclature is occasionally met in a discussion of major hepatic resection. The liver consists of several lobes (Fig. 1), and the time-honored concept of its division into right and left lobes by the falciform ligament is *anatomically* incorrect. The correct anatomical division between right and left lobes is stated to be the plane extending from the fossa of the gallbladder inferiorly to the fossa of the inferior vena cava superiorly.¹⁹ This plane of division lies some 6 to 8 cm. to the right of the falciform ligament, and the anatomical left lobe is thus subdivided in the plane of the falciform ligament into a lateral and medial segment, the latter of which incorporates most of what has been termed in the past the *quadrate* and the *caudate* lobes. The anatomical right lobe is further divided into an anterior and posterior segment. This anatomical division into lobes and segments is based on the distribution of the vessels and ducts as determined by plastic injection studies and dissection of corrosion casts of the liver¹² (Fig. 2).

The intention of the surgeon should not be to resect a specific lobe or segment along anatomical boundaries, but to remove completely and with adequate margins the diseased portion of the liver. For practical purposes, therefore, the terms right hepatic lobectomy and left hepatic lobectomy are used in a surgical sense rather

Submitted for publication August 25, 1971.

* Deceased May 3, 1970.

Reprint requests: Dr. Bowden, 177 East 79th Street, New York, N.Y. 10021.

* One or more hepatic resections was performed by each of the following surgeons (listed alphabetically): Robt. J. Booher, Lemuel Bowden, Richard D. Brasfield, Joseph C. Fortner, Ralph Hertz, Walter Lawrence, jr., Gordon McNeer, Charles J. McPeak, George T. Pack, and Horace Whiteley.

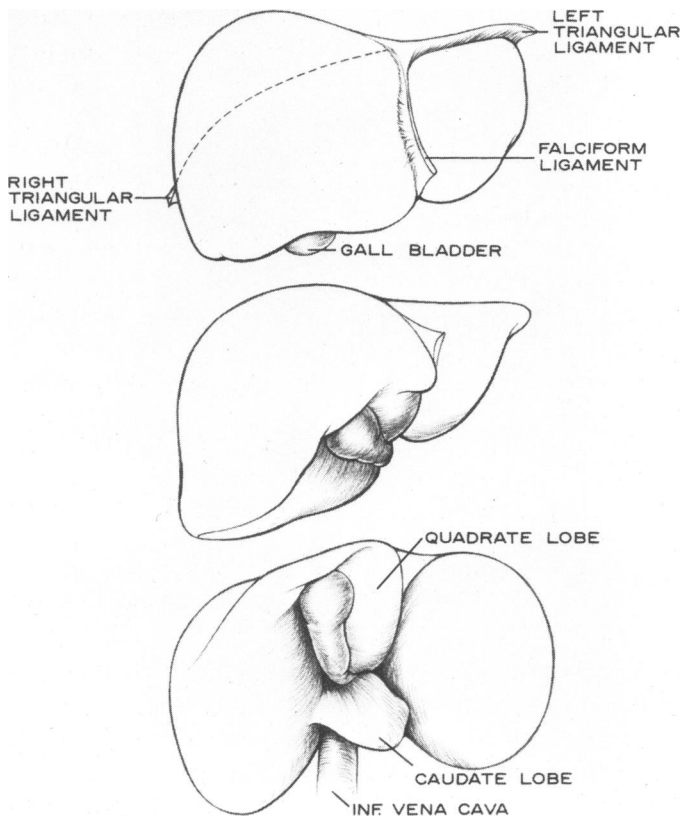


FIG. 1. Diagrammatic representation of the liver in anterior, inferior-oblique, and inferior projections, showing ligaments and lobes as conventionally described.

than in an anatomical sense. Right hepatic lobectomy consists of removing at least the entire anatomical right lobe (including both anterior and posterior segments) and usually a portion of the medial segment of the anatomical left lobe as well. Left hepatic lobectomy consists of removing at least the entire anatomical lateral segment of the left lobe and usually a portion of the medial segment as well. The somewhat arbitrary line of surgical division is dictated primarily by the requirements of the individual case, and is influenced by the line of ischemia which usually demarcates clearly after either the right hepatic artery or the left hepatic artery has been ligated.

In the present material, hepatic lobectomy, whether right or left, is employed in the surgical sense as described above. The smallest surgical specimen recorded was that of a left hepatic lobectomy measuring 16 × 8 × 4 cm. but weighing only 160 Gm., and representing only the lateral segment of the *anatomical* left lobe. The other left hepatic lobectomies were of greater dimensions with weights ranging from 230 Gm. to 1660 Gm., and a median value of 870 Gm. In those right hepatic lobectomies in which weight of specimens was recorded, the median value was 1290 Gm. with a range from 600 Gm. to 4,000 Gm. Three pediatric cases are included in this group.

There were 13 left hepatic lobectomies, including four male and nine female patients with ages ranging from

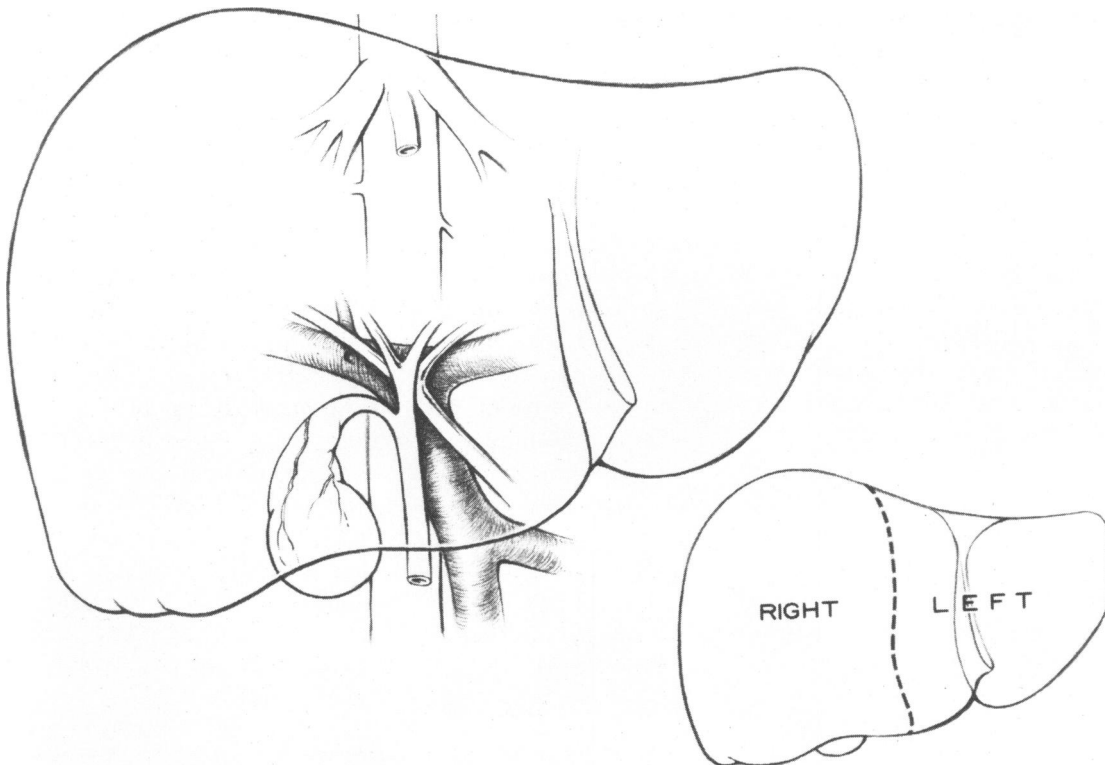


FIG. 2. Ductal and vascular structures of the liver, clearly defining the *anatomical* division between the right and left lobes.

2-2/12 years to 73 years, and with a median age of 53 years. There were 37 right hepatic lobectomies, including 17 male and 20 female patients, with ages ranging from 1-4/12 years to 71 years, and with a median age of 52 years. There were thus 21 male patients and 29 female patients. One male patient was an oriental and one male patient a negro, while all remaining 48 patients were caucasian (Table 1).

Surgical Procedure

All 50 hepatic resections were performed under general anesthesia, and all but one of the 37 right hepatic lobectomies by right laparo-thoracotomy. The one exception was in a child, 16 months of age, who had a sufficiently mobile liver and a sufficiently accessible hepatic vein-vena caval junction to permit right hepatic lobectomy for malignant hepatoma by an extended right subcostal incision alone.

Left Hepatic Resection: Surgical exposure in the 13 left hepatic resections varied depending upon the habitus of the patient, but required laparotomy only without entry into the thorax in all but one patient. One 36-year-old woman underwent left laparo-thoracotomy in order to facilitate left hepatic lobectomy for an unusually large solitary metastasis of carcinoma of uncertain primary origin.

After ligation and division of the left hepatic artery and duct, and ligation and division of the main branch of the portal vein to the left lobe, the falciform ligament, the left triangular ligament, and the gastrohepatic ligament are divided and the left lobe of the liver, thus mobilized, can be displaced into the wound. By placing parallel rows of interlocking sutures along the line of color demarcation, usually evident as a result of the prior vascular ligation and usually developing just to the right of the falciform ligament, the left lobe of the liver is resected through the devascularized tissue between parallel rows of sutures. Care must be taken as the liver is thus divided to identify, expose, ligate and divide the large left hepatic vein draining into the vena cava close to the diaphragm. The finger-fracture technic of Lin may well be employed in dividing through hepatic parenchyma, and may possibly permit a safer left hepatic resection than is provided by the suture *guillotine*

method. However, in our opinion the finger-fracture technic is of much greater applicability to the conduct of right hepatic resection, as will be discussed subsequently.

In these 13 left hepatic lobectomies blood loss varied: Two patients each required only 500 cc. of blood replacement, while one patient required 4,000 cc. of blood replacement. The median value of blood replacement was 1,500 cc. Operating time, likewise, varied from 1½ hours to 5½ hours with a median operating time of 4 hours. One patient died of cerebrovascular disease on the second postoperative day, and postoperative hospitalization in the remaining 12 patients varied from 9 days to 34 days with a median hospital stay of 19 days (Table 2).

Right Hepatic Resection: Surgical exploration of the abdomen was usually performed through a generous right subcostal incision in the 37 patients who underwent right hepatic lobectomy. When resection was considered feasible, a counter incision across the right costal arch into the 8th or 9th intercostal space was subsequently made after portal dissection and ligation and division of the vascular and ductal structures to the right lobe had been completed. Some of these patients underwent abdominal exploration through a right rectus vertical incision which was subsequently extended into the right thorax, and a few were primarily explored through a supra-umbilical transverse incision subsequently extended into the right thorax.

One of us (L.B.) at the time of portal dissection regularly inserts a small caliber T-tube into the common duct with its proximal arm placed well up into the left hepatic duct for the purpose of ready identification and protection of the left hepatic duct when the liver is being transected, as well as for postoperative observation of bile output from the residual liver and for postoperative cholangiograms if these should be required. This technical modification has also been described by Dillard.⁸ Mention should be made of the frequency of vascular anomalies in the *porta hepatis*. No major anomaly was encountered in our 50 cases, yet Michels¹⁹ records 52 aberrant right hepatic arteries and 54 aberrant left hepatic arteries in 200 specimens studied.

When the right thorax has been entered, the lung is packed away and the diaphragm radially incised towards

TABLE 1. Brasfield, Bowden, & McPeak: Major Hepatic Resection—Memorial Hospital, N. Y. C. 1950–1968

	Left	Right	Total
No. cases	13	37	50
Male	4	17	21
Female	9	20	29
Age range	2-2/12—73 yrs.	1-4/12—71 yrs.	—
Median	53 yrs.	52 yrs.	—

TABLE 2. Brasfield, Bowden, & McPeak: Major Hepatic Resection—Memorial Hospital, N. Y. C. 1950–1968

	Features of Operation (Median Values)*	
	Left	Right
Duration of operation	4 hrs.	5-1/2 hrs.
Blood replacement	1500 cc	3500 cc
Postop hospitalization	19 days	25 days
Survival	21 mos.	13 mos.

* Excluding operative deaths.

the caval hiatus. The right triangular ligament can be divided over to the falciform ligament which is usually not divided. Recent recognition of the importance of the umbilical vein for collateral circulation when portal hypertension exists⁶ favors the preservation of the falciform ligament and umbilical vein if possible. As a result of prior vascular ligation there is usually a line of color demarcation evident just to the right of the falciform ligament. In all of the early cases of this series the liver was then displaced into the wound and retracted to the left, and by meticulous dissection along the inferior vena cava the several hepatic veins draining the right lobe into the vena cava could be exposed over a distance of 1 to 2 cm., ligated in continuity, and then divided between ligatures so placed (Fig. 3). Occasional hepatic veins from the right lobe were of such caliber as to require suture-ligature fixation, or continuous suture closure over a vascular (Potts-Satinsky) clamp. When all the hepatic veins draining the right lobe had thus been secured, the liver was allowed to resume its normal anatomical position, and after placing of parallel interlocking sutures in the plane of color demarcation the liver was divided beginning on its antero-superior surface and continuing into the substance of the liver, veering slightly to the right as its posterior aspect is approached so as to complete the transection just to the right of the vena cava.

If through misadventure an hepatic vein or the vena cava itself is lacerated, severe bleeding can occur, and with the hepatic lobe still in place the site of bleeding may be inaccessible. To control such bleeding, tam-

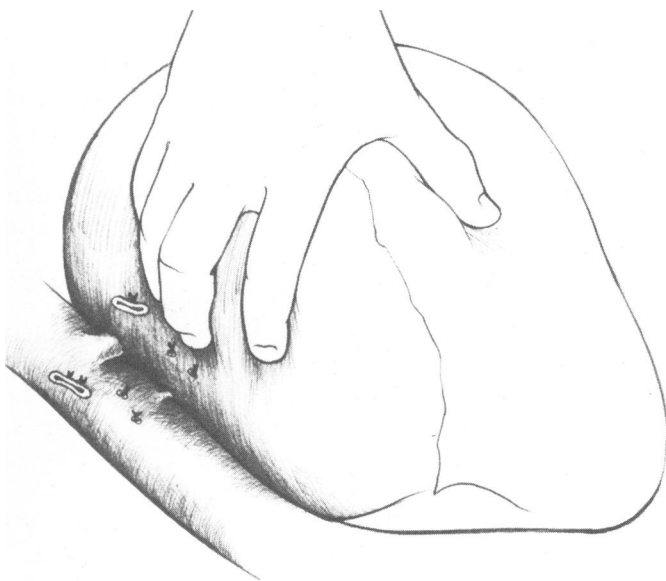


FIG. 3. Gentle traction on the mobilized liver towards the midline exposes the entrance of the several hepatic veins into the inferior vena cava, and permits their ligation and division under direct vision.

ponade of the vena cava above and below the liver may be required with precarious reduction in cardiac return. While maintaining caval compression, the mobilized lobe of the liver must be rapidly resected, with inevitable further bleeding, and the bleeding site or sites in the vena cava properly secured with adequate exposure. This sequence of events cannot be withstood by all patients, and in the 37 patients herein reported there were five deaths believed attributable to cardiac arrest secondary to markedly diminished cardiac return flow, in turn secondary to inferior vena caval tamponade for control of bleeding.

Consequently, in the recent cases in this series, and in our current practice, the finger-fracture technic of Tien-Yu Lin¹⁶ has been employed with slight modifications as follows: Following portal dissection with vascular and ductal ligation, and mobilization of the right lobe of the liver via thoraco-laparotomy, no attempt to ligate the hepatic veins from behind is made. The hepatic parenchyma is entered to the right of the falciform ligament where color demarcation is evident, and by finger-fracture the major venous tributaries are adequately exposed, ligated, and divided as the dissection proceeds (Fig. 4). The vena cava need not necessarily be exposed at all if this technic is followed. The last six right hepatic resections of this series were performed in this manner without a fatality and with no major complication.

Operating time in the 37 right hepatic lobectomies varied from 3 hours to 10½ hours with a median operating time of 5½ hours. Blood replacement in the operative survivors, excluding the two infants in whom loss and replacement were not comparable to the adults, varied from 1,000 cc. to 10,000 cc. with a median value of 3,500 cc. Excluding the 13 patients who did not survive, the postoperative hospitalization in the remaining 24 patients varied from 14 days to 66 days with a median hospital stay of 25 days (Table 2).

Pathology

The lesion for which major hepatic resection was performed in these 50 patients was a malignant neoplasm in all instances. There were 14 resections performed for primary cancer of the liver, nine for primary cancer of the gallbladder, and the remaining 27 for metastatic cancer of varying histologic type and of varying primary origin (Table 3).

Primary Cancer of the Liver: The high incidence of primary cancer of the liver in certain parts of the world is recognized and acknowledged,² but in our experience this tumor is rare. Twelve patients underwent right hepatic lobectomy and two patients underwent left hepatic lobectomy for a localized malignant hepatoma. Eight patients were male and six were female. Hepatocellular carcinoma was more frequently encountered than

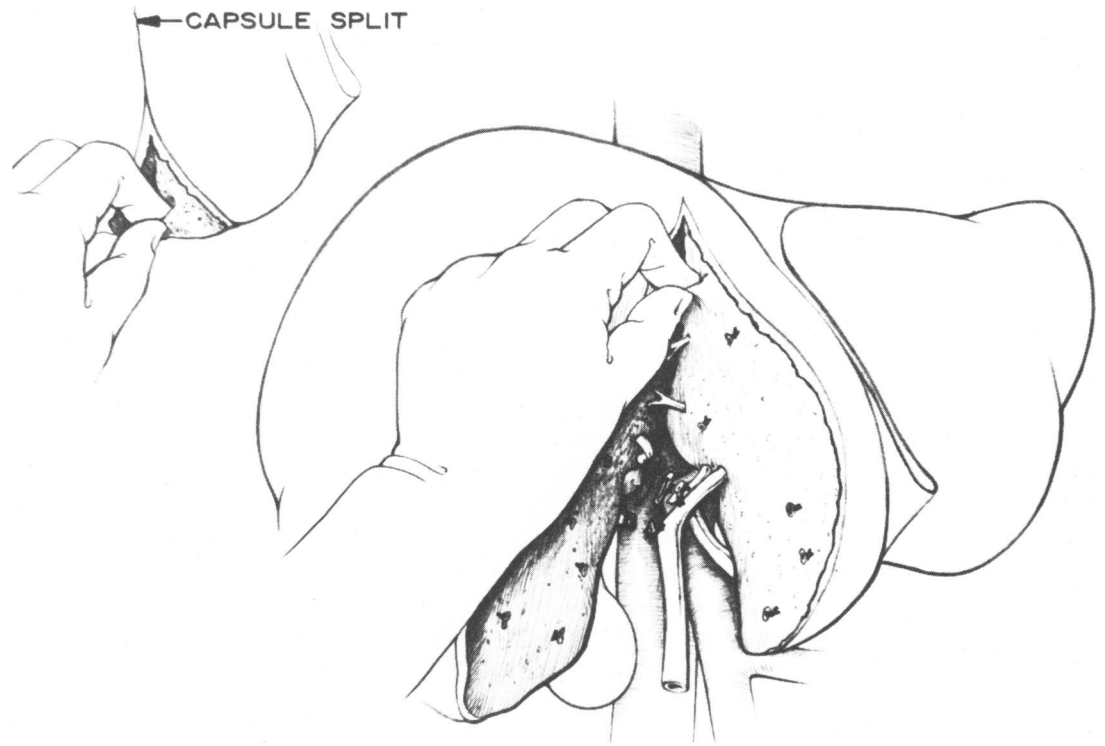


FIG. 4. Finger fracture division of the liver following dissection of the porta hepatis with isolation, ligation, and division of the right hepatic duct, the right hepatic artery, and the right branch of the portal vein.

primary cholangiocarcinoma or primary hepatic sarcoma in a ratio of 3 to 1. All four of the children in this series of 50 patients had primary hepatocellular carcinoma.

Primary Cancer of the Gallbladder: Three men and six women underwent right hepatic lobectomy for primary cancer of the gallbladder. In all nine individuals the diagnosis had been established by biopsy, and the feasibility of hepatic resection was determined by previous laparotomy. The tumor was classified as adenocarcinoma Grade III in four patients, and merely as carcinoma or anaplastic carcinoma in the remaining five patients. Four patients had regional node metastases, two had negative nodes, and in three the status of regional nodes was not recorded.

Metastatic Lesions: Twenty-seven patients underwent major hepatic resection for apparent solitary or localized metastasis from a previously controlled malignant neoplasm of separate and distant origin. All of these resections were performed from 1 month to 7 years following apparently successful surgical treatment of the primary tumor. The majority of these patients, nine male and

ten female, had had previous colon resections for adenocarcinoma, of whom seven underwent left hepatic resection and 12 underwent right hepatic resection.

Three patients had right hepatic lobectomy for metastatic sarcoma. One man had been previously treated at Memorial Hospital for liposarcoma of the thigh, and two women had been previously treated for abdominal leiomyosarcoma, presumably gastric in origin, at other institutions.

The five remaining patients, all women, underwent hepatic resection for metastatic cancer of varying origin. One patient had left hepatic lobectomy for metastatic clear cell-carcinoma of the kidney, one had right hepatic lobectomy for metastatic mammary carcinoma, one had left hepatic lobectomy for metastatic ocular melanoma, and two patients had left hepatic lobectomies for metastatic carcinoma of uncertain origin.

Complications

Mention has already been made of the five deaths encountered in these 50 patients, in every instance believed due to cardiac arrest in a heart already challenged by massive bleeding and further shocked by abrupt reduction in return blood flow as a result of compression of the inferior vena cava to control bleeding. Air embolism may have contributed to these deaths. Nine other patients did not survive the operative procedure, dying from 2 days to 40 days following operation of a multiplicity of causes and complications.

Non-fatal complications were encountered in fre-

TABLE 3. *Brasfield, Bowden, & McPeak: Major Hepatic Resection—Memorial Hospital, N. Y. C. 1950-1968*

	Left	Right	Total
Primary cancer liver	2	12	14
Ca of gallbladder	—	9	9
Metastatic colon ca	7	12	19
Metastatic sarcoma	—	3	3
Other	4	1	5

quency and type as might have been anticipated in any group of patients undergoing major upper abdominal operation. One young woman in whom a segment of adherent transverse colon was removed along with the right lobe of the liver developed a fulminating right subphrenic abscess which necessitated subsequent rib resection and drainage, but ultimately recovered and is a long-term survivor.

Biliary fistula is a non-fatal complication peculiar to this type of surgical procedure. All 45 survivors had adequate drainage of the operative area established at the time of wound closure, and transient biliary drainage occurred in every instance, usually ceasing by the 2nd or 3rd postoperative day. Biliary drainage presented a problem in seven patients undergoing right hepatic resection, and persisted from 10 days to 2 months before spontaneously clearing. Undoubtedly such prolonged drainage comes from an open major biliary duct in the cut surface of the liver, which has not been ligated at the time of resection, or from which the ligature has sloughed. If a T-tube has been placed into the remaining hepatic duct at the time of operation, not only can appropriate cholangiographic studies be obtained, but mild suction may be applied to the T-tube to encourage bile to flow away from the fistula. When a biliary fistula is persisting, furthermore, the gastroduodenal area is left largely devoid of an alkalyzing mechanism and measures must be taken to prevent acute peptic ulceration. Since the finger-fracture technic of Lin has been employed, there has been but one instance of a persisting postoperative biliary fistula.

End Results (1950-1964)

Five-year survival figures are necessarily based on the 33 patients treated by major hepatic resection during the first 15 years of the study period, up to and including 1964 (Table 4).

Of the nine left hepatic resections performed more than 5 years ago, one patient died on the second postoperative day from cerebrovascular disease, probably unrelated to the surgical procedure. The other eight patients survived left hepatic resection, but seven subsequently died of further manifestations of the neoplasms, 9 months to 57 months following operation. The eighth patient has been lost to follow-up after 5 years, but was living and well up to that time.

In the 24 right hepatic resections performed more than

5 years ago there were three deaths, in each instance due to cardiac arrest secondary to massive bleeding from the hepatic veins or vena cava. Five patients died on the 6th, 6th, 7th, 13th, and 28th postoperative days, from bronchopneumonia, pulmonary infarction, acute myocardial infarction, peritonitis, and septic thrombophlebitis, respectively. A 33% operative mortality for right hepatic resection is thus recorded.

Five of the surviving 16 patients underwent right hepatic resection for solitary metastasis from a previously resected colonic carcinoma, of whom four died of further manifestations of cancer from 4 months to 11 months following resection. The fifth patient is living free of detectable cancer more than seven years following resection.

Two patients with metastatic leiomyosarcoma achieved rather striking survival of 64 months and 48 months, but both died of further metastases. The patient with metastatic liposarcoma lived for 4 months before succumbing to hepatic failure.

Three patients with primary carcinoma of the gallbladder survived for 5 months, 25 months, and 15½ years, the latter of whom died apparently of a second primary diffuse cholangiocarcinoma.

The remaining five patients all had primary cancer of the liver, three of whom died at 4 months, 12 months, and 34 months following resection. The other two are living and well 10 years and 13 years following resection.

In these 24 right hepatic resections, therefore, five patients attained 5-year survival. Two have subsequently died, one at 64 months of recurrent leiomyosarcoma and the other at 15½ years of an apparent second primary cancer. One patient undergoing resection for metastatic colonic cancer is living and well for more than seven years, and two patients undergoing resection for primary hepatoma are living and well at 10 years and 13 years.

Conclusions

From this analysis of 50 patients who underwent major hepatic resection for malignant neoplasms of the liver, it is evident that the procedure is characterized by appreciable risk, but may be effective in controlling the malignant process in some patients.

Only one of three survivors with primary carcinoma of the gallbladder lived for more than 5 years, and only two of 16 survivors with metastatic cancer lived for more than 5 years. However, three of five survivors with primary carcinoma of the liver remain living over 5 years, one by left hepatic resection and two by right hepatic resection, leading us to believe that major hepatic resection may be of greatest value in the management of such primary neoplasms.

We believe, furthermore, that significant palliation was afforded many of the survivors of hepatic resection

TABLE 4. *Brasfield, Bowden, & McPeak: Major Hepatic Resection—Memorial Hospital, N. Y. C. 1950-1964*

	Total	Op. Mortality	5-Yr. Survival
Left	9	1 (11%)	1 (11%)
Right	24	8 (33½%)	5 (21%)

for metastatic cancer, and that, if operative mortality can be reduced and maintained at an acceptable level, hepatic resection should continue to be employed for all localized and technically resectable tumors of the liver.

References

1. Adson, M. A., and Jones, R. R.: Hepatic Lobectomy. *A.M.A. Arch. Surg.*, **92**:631, 1966.
2. Berman, C.: *Primary Carcinoma of the Liver*. H. K. Lewis & Co., Ltd. London, 1951.
3. Brasfield, R. D.: Right Hepatic Lobectomy for Carcinoma of the Gallbladder. *Ann. Surg.*, **153**:563, 1961.
4. Brunshwig, A.: The Surgery of Hepatic Neoplasms with Special Reference to Right and Left Hepatic Lobectomies. *Cancer*, **8**:1226, 1955.
5. Brunshwig, A.: Hepatic Lobectomy for Metastatic Cancer. *Cancer*, **16**:277, 1963.
6. Burchell, A. R., Panke, W. F., Moreno, A. H., and Rousselot, L. M.: The Patent Umbilical Vein in Portal Hypertension. *Surg. Gynecol. Obstet.*, **130**:77, 1970.
7. Clatworthy, H. W., Boles, E. J., and Kottmeier, P. K.: Liver Tumors in Infancy and Childhood. *Ann. Surg.*, **154**:475, 1961.
8. Dillard, B. M.: Experience with 26 Hepatic Lobectomies and Extensive Hepatic Resections. *Surg. Gynecol. Obstet.*, **129**:249-257, 1969.
9. Fineberg, C., Goldburgh, W. P., and Templeton, J. Y.: Right Hepatic Lobectomy for Primary Carcinoma of the Liver. *Ann. Surg.*, **144**:881, 1956.
10. Foster, J. H., Lawler, M. R., Welborn, M. B., Jr., Holcomb, G. W., and Sawyers, J. L.: Recent Experience with Major Hepatic Resection. *Ann. Surg.*, **167**:651, 1968.
11. Foster, J. H.: Survival after Liver Resection for Cancer. *Cancer*, **26**:493, 1970.
12. Healey, J. E., Jr., Schroy, P. C., and Sorensen, R. J.: Intrahepatic Distribution of Hepatic Artery in Man. *J. Internat. Coll. Surg.*, **20**:133, 1953.
13. Keen, W. W.: Resection of the Liver, Especially for Hepatic Tumors. *Boston M. and S. J.* **126**:405, 1892.
14. Keen, W. W.: Report of a Case of Resection of the Liver for Neoplasm, with a Table of 76 Cases of Resection of the Liver for Hepatic Tumors. *Ann. Surg.*, **30**:267, 1899.
15. Klose, H.: Totalresektion des linken Leberlappens bei primären Leberkrebs. *Beitr. z. Klin. Chir.*, **74**:1, 1911.
16. Lin, Tien-Yu: The Results of Hepatic Lobectomy for Primary Carcinoma of the Liver. *Surg. Gynecol. Obstet.*, **123**:289, 1966.
17. Longmire, W. P. and Marable, S. A.: Clinical Experience with Major Hepatic Resections. *Ann. Surg.*, **154**:460, 1961.
18. Lortat-Jacob, J. L. and Robert, H. G.: Hépatectomie Droite Réglée. *Presse Med.*, **60**:549, 1952.
19. Michels, N. A.: Variational Anatomy of Hepatic, Cystic, and Retroduodenal Arteries: Statistical Analysis of their Origin, Distribution, and Relations to Biliary Ducts in 200 Bodies. *A.M.A. Arch. Surg.*, **66**:20, 1953.
20. Pack, G. T., Miller, T. R., and Brasfield, R. D.: Total Right Hepatic Lobectomy for Cancer of the Gallbladder. Report of Three Cases. *Ann. Surg.*, **142**:6, 1955.
21. Pack, G. T., and Brasfield, R. D.: Metastatic Cancer of the Liver: The Clinical Problem and Its Management. *Am. J. Surg.*, **90**:704, 1955.
22. Pickrell, K. L. and Clay, R. C.: Lobectomy of the Liver, Report of Three Cases. *Arch. Surg.*, **38**:267, 1944.
23. Quattlebaum, J. K.: Massive Resection of the Liver. *Ann. Surg.*, **137**:787, 1953.
24. Raffucci, F. L., and Ramirez-Schon, G.: Management of Tumors of the Liver. *Surg. Gynecol. Obstet.*, **130**:371, 1970.
25. Smith, R.: Hepatectomy. *Proc. Roy. Soc. Med. (Eng.)*, **57**:547, 1964.
26. Turner, G. G.: A Case in Which an Adenoma Weighing 2 Lbs. 3 Oz. was Successfully Removed from the Liver, with Remarks on the Subject of Partial Hepatectomy. *Proc. Roy. Soc. Med.*, **16**:43, 1923.
27. Wallace, R. H.: Resection of the Liver for Hepatoma. *Arch. Surg.*, **43**:14, 1941.
28. Wendel, W.: Über Leberlappenresektion. *Arch. F. Klin. Chir.*, **114**:982, 1920.
29. Yoemans, F. C.: Primary Carcinoma of the Liver. *JAMA*, **64**:1301, 1915.