

Esophagoplasty for Corrosive Stricture of the Esophagus:

An Analysis of 60 Cases

K. Y. CHIEN, M.D., P. Y. WANG, M.D., K. S. LU, M.D.

From the Department of Surgery, National Defense Medical Center and Veterans General Hospital, Taipei, Taiwan

AQUIRED STRICTURE OF THE ESOPHAGUS from the ingestion of corrosives is relatively common. It has been generally agreed that surgical reconstruction of the diseased esophagus becomes essential if a satisfactory esophageal lumen cannot be maintained by intermittent dilatations or other forms of conservative treatment. Prosthetic tubes and various autologous transplants have been used previously for the re-establishment of esophageal continuity.¹¹ It is not the purpose of this communication to critically evaluate their merits and disadvantages, but to present our clinical data, results and complications of esophagoileocoloplasty and esophagocoloplasty among 60 patients with corrosive esophageal stricture at the Army General Hospital and the Veterans General Hospital, Taipei, Taiwan during the past 14 years from 1958 to 1972.

Clinical Data

Twenty-eight of our patients were male and 32 were female. Their ages ranged from 4 to 64 years and 26 of them (43%) were young adults between 21 and 30 years of age (Table 1).

The interval between ingestion of corrosives and the times of reconstruction varied greatly. They ranged from 2 to 6 months in 20 patients; 6 to 12 months in 18; 1 to 2 years in 7; 2 to 5 years in 8; 5 to 10 years in 4; and 11, 18 and 27 years in the remaining 3 patients. Nineteen of these patients had received antegrade dilatations for the

narrowed esophagus and 15 others each had a feeding gastrostomy or enterostomy before reconstruction.

The level of esophageal strictures measured as follows: 24 patients were in the upper third; 20, in the middle third; and 5, in the lower third. Two of our patients had multiple strictures, one involved the upper and middle third; the other one, the upper and lower third. The exact sites of strictures were not clearly recorded in the remaining 9 patients. Six of these patients were associated with pyloric obstruction which required pyloroplasty for relief.

A variety of corrosive agents were recorded as causes of the esophageal injuries. Twenty patients were injured by ingestion of one of the four acids, i.e., hydrochloric, sulfuric, nitric or carbolic acid; and 40 others, by ingestion of lye. Thirty-seven patients (23 females and 14 males) took corrosives in an attempt to commit suicide; 21 others, by mistake; and the remaining 2 patients for reasons unknown.

Among these 60 patients, 33 were followed for a period from 6 months to a year; 5, 1 to 3 years; 10, 3 to 5 years; 5, 5 to 7 years; 5, 7 to 10 years; and the remaining 2 patients, 13 and 14 years respectively.

Method

Esophagoileocoloplasty and Esophagocoloplasty

The technique of esophagoileocoloplasty is a modification of our own which has been used during the past

Submitted for publication April 30, 1973.

Reprint requests: Dr. K. S. Lu, Professor of Surgery, National Defense Medical Center, and Surgeon-in-Chief, Veterans General Hospital, Taipei, Taiwan 112.

six years with much satisfaction. The operation is done by two teams; one chiefly prepares the intestine for transplantation and the other prepares the esophageal stumps for anastomosis. The abdomen is opened through a median incision and the cervical esophagus is approached through an incision made over the anterior border of the left sternomastoid muscle. After a general examination of the abdominal and cervical viscera, a retrosternal tunnel is made by blunt dissection simultaneously from the abdominal and cervical wounds. The tunnel should be large enough for the operator's hand to pass through from the abdominal to the cervical outlet. The tunnel is then packed with a roll of gauze to stop oozing until the ileocolon is ready. After mobilization of the right colon and terminal ileum, the pedicle of the ileocolic vessels is clamped with Sarot nontraumatic clamp; meanwhile the required length of the transplant is measured.

The terminal ileum is clamped with its mesenteric vessels, 8 to 12 cm. from the ileocecal junction. If the blood flow from the right colic through the communicating arcades proves adequate, the ileocecal pedicle is severed, otherwise both ileocecal and right colic pedicles are cut off, as occasionally is required. Then the appendix is removed and the terminal ileum is divided and its distal end is temporarily sutured, leaving both ends of the suture long enough to be tied up to the end of the gauze roll for traction. The transplant is now gently brought up anterior to the stomach into the cervical wound through the retrosternal tunnel by a bimanual manipulation of pull and push. Any fibrous bands felt at the thoracic inlet are divided. In most cases, there is no more oozing after withdrawal of the gauze roll. If such is not the case, the retrosternal space is drained by urethral catheter (with holes cut on its side) connecting with suction for a few days postoperatively.

The esophagus is divided above the stricture at a level above the left clavicle. The distal stump of the divided esophagus is closed with two layers of silk sutures. When the obstruction is complete and the line of division is more than 1 cm. above the upper limit of the stricture, this part of the esophageal mucosa together with the mucous glands is destroyed with concentrated carbolic acid before closure and the sac is drained with a urethral catheter. The ileal stump of the transplant is anastomosed end-to-end with the proximal stump of the cervical esophagus, using two layers of interrupted fine silk sutures, one for mucosa only and another for other coats of the wall. If the lumen of the proximal stump of the esophagus does not match that of the ileal stump, a longitudinal slit is made in the esophageal stump before anastomosis. Occasionally, the ileal portion of the transplant is found to be compressed at the inlet of the thorax after anastomosis. If such is the case, a part of the manu-

TABLE 1. *Age and Sex*

Age (years)	No. of Patients	Male	Female
4-12	8	5	3
13-20	8	3	5
21-30	26	9	17
31-40	12	8	4
41-50	4	1	3
51-64	2	2	0
Total	60	28	32

brium and the sternal end of the left clavicle are resected. The cervical wound is closed with a Penrose drain left for 3 to 5 days. The whole segment of the esophagus distal to division is left undisturbed.

In dealing with the abdominal wound, the transverse colon is divided to the left of the middle colic vessels. The proximal end of the colon is anastomosed to the side of the jejunum about 15 cm. distal to the ligament of Treitz. The proximal stump of the ileum is anastomosed end-to-end with the distal end of the transverse colon with emphasis that the anastomosis be done with the mesentery of the ileum and that of the transverse colon in opposite directions. The mesenteric rent is closed with sutures. Immediately before closure of the abdominal wound, a temporary Stamm gastrostomy is done for postoperative feeding.

If the pattern of the mesenteric vessels of the right side of the colon is such that the right colon can not be used as the transplant or it is found difficult to free the transplant because of dense fibrous adhesions resulting from previous local infection and/or operation, then the plan of operation is changed and the left-side colon is used instead. (Such situations were encountered in 6 patients) Our technique of left esophagocoloplasty generally resembles that of the Orsoni and Torpet's⁹ except that we place the colon retrosternally instead of using the prethoracic route. The left colon transplant is antiperistaltic.

Our preoperative colon preparation includes daily enema and sulfasuxidine (2 gm. every 6 hours) for 4 days in addition to neomycin (1 gm. every 4 hours) for the last 36 hours. A chest film is always taken shortly after recovery from anesthesia to make sure of the absence of pneumothorax which, if present, needs tube drainage. For the first two weeks after esophageal reconstruction, feeding is given through the gastrostomy tube.

Complications and Mortality

Twenty-one of 60 patients had complications following esophageal reconstructions. Among these 21 patients 15 belong to the esophagoileocoloplasty group; and 6 others, the left esophagocoloplasty group. Many of these 21 patients had 2 complications which occurred either si-

TABLE 2. *Complications*

Complications	Esophagoileocoloplasty Group		Esophagocoloplasty Group	
	(1958-1966)	(1967-1972)	(1958-1966)	(1967-1972)
Transient leakage at cervical anastomosis	4	1	1	0
Narrowing at ileoesophageal anastomosis	11	3	1	0
Mediastinal empyema	2	0	0	0
Cystic dilatation of distal esophageal stump with rupture	1	0	1	0
Regurgitation	0	0	4	2
Pneumothorax	2	1	1	0
Herniation of colon transplant into right pleural cavity	0	0	1	0
Intestinal obstruction	2	0	1	0
Total (complication/patient)	22/10	5/5	10/4	2/2

multaneously or one after another, and all of the double complications occurred in the first 8 years of practice. A list of all of the 39 complications is given in Table 2.

Transient leakage from the cervical anastomosis occurred in 6 patients. It developed within 12 days after esophagoplasty. In 2 of these patients, the leakage was followed by development of empyema in the mediastinum which required surgical drainage. The leakages themselves closed spontaneously in 1 to 2 weeks, but, subsequently, narrowing at the ileoesophageal anastomosis occurred in all of these 6 patients.

The cervical fistula of another patient originated from the closed distal esophageal stump. This patient had complete obstruction at the junction between the upper and middle third of esophagus before reconstruction. The blind segment was cystically dilated and a leak was found at the suture line. The infected pouch was drained and repeatedly irrigated with 18% solution of hydrochloric acid. It took 4 months for the discharging wound to heal. Another case of cystic dilatation of the distal esophageal stump with symptoms of compression occurred in a patient whose stricture was at the lower third. The cyst of this patient was totally excised through a standard thoracotomy incision of the right side.

The most common complication seen in the esophagoileocoloplasty group was narrowing at the site of ileoesophageal anastomosis; this occurred in 14 patients. These patients began to have swallowing difficulty from 2 to 3 weeks after reconstruction. Four of them had a history of transient fistula at the cervical anastomosis before the onset of dysphagia. Of these 14 patients, 11 responded well to bouginage and one recovered after resection of the left sternoclavicular joint which was found to be directly compressing the site of anastomosis. Resection of the stenosed stoma and reanastomosis were done for the other 2 patients. One felt greatly relieved after the second operation, but the other, who had had high cervical stricture before reconstruction, still had swallowing difficulty after reanastomosis. One of 6 patients of the left esophagocoloplasty group had narrowing of coloesophageal anastomosis. This patient had no

more complaint after intermittent dilatation for a period of 4 weeks.

All 6 patients of the left esophagocoloplasty group had some degree of regurgitation and in 2 of them the symptoms still recurred frequently 7 and 14 years after operation. The patients were advised to keep upright or take a stroll after meals and keep the head of the bed slightly elevated while sleeping.

Routine postoperative chest roentgenography revealed pneumothorax in 4 patients. Tube drainage was instituted immediately after diagnosis and the follow-up chest films were normal in all 4 patients. However, one of these patients who received left-colon esophagoplasty subsequently complained of distension in the right lower chest at each meal 3 years after operation. Contrast visualization of the colon transplant with barium meal showed that a segment of the colon had herniated into the right pleural cavity with dilatation of the herniated intestine and barium retention. Thoracotomy was done and a segment of the transplant was found to have protruded through a defect in the mediastinal pleura into the right pleural cavity. The kinked and dilated portion of the colon was resected and the ruptured mediastinal pleura was repaired. The patient did not complain of distension any more after the second operation.

Intestinal obstruction occurred in 3 patients. In one patient, abdominal distension and periumbilical pain developed on the 7th. postoperative day. The roentgenogram of the abdomen showed distension of the loops of small intestine. Laparotomy revealed torsion of the ileocolostomy which was resected and a new ileocolostomy was made after proper alignment. Another case of intestinal obstruction which developed 9 months after operation was caused by fibrous adhesion. The patient recovered after division of adhesions at laparotomy. The third patient came to our emergency unit 18 months after esophageal reconstruction. Laparotomy showed dense adhesion in the region of intestinal anastomosis. Unfortunately, this patient died of cardiac arrest shortly after operation.

The death of another patient occurred suddenly about

15 hours after reconstruction. Autopsy was done but failed to disclose the exact cause of death.

Results

The results of esophagoplasty were evaluated according to whether or not the patient complained of difficulty in swallowing solid, semiliquid or liquid diets after reconstruction or second operation for post-operative complications. They were grouped into 3 categories: 1) good, in 55 patients (91.7%) who could swallow solid and/or semiliquid foods without difficulty; 2) poor, in 3 patients (5%) who had dysphagia when they ate solid and semiliquid foods but who could eat liquid diets with little difficulty; and 3) failed, in 2 patients (3.3%) who could not even eat liquid diets. Of these 2 patients, one had received a second operation but stenosis recurred later at the site of reanastomosis, and the other declined to be reoperated. Both patients depended upon gastrostomy feeding to maintain their lives and both of them, who took corrosives for killing themselves intentionally before admission, committed suicide after leaving the hospital.

A gain in weight was noted in all 55 patients with good results. Physical and psychic development of 8 young patients (aged between 4 and 12) were entirely normal after reconstruction of the diseased esophagus.

Discussion

The experience with these 60 cases suggests that retrosternal esophagoileocoloplasty could be a reconstructive operation of choice for corrosive stricture of the esophagus if done properly. In the early years of our experience, we met with a variety of postoperative complications (Table 2). As a result of repeated modification of surgical technique, these have occurred less and less in recent years.

The complication which occurred most frequently in the early period of our technical development was narrowing at the site of ileoesophageal anastomosis. The second was leakage from the anastomosis which was always followed by a varying degree of stricture at the site of anastomosis after cessation of leakage. Now we feel certain that the main cause of these two related complications was circulatory disturbance at the end of the ileal stump and that this can be effectively prevented if attention is given to the following six points at operation: 1) The transplant should be long enough so that the anastomosis can be done without tension. 2) the retrosternal tunnel should be wide enough for the transplant to pass by without the risk of being compressed or twisted. 3) All the fibrous bands at the thoracic inlet should be divided if present. 4) If the space at the thoracic inlet is still not big enough for the transplant to pass by, a part of the manubrium and the sternal end of the left clavicle should be resected. 5) The tem-

porarily closed end of the ileal stump of the transplant should be cut off before anastomosis instead of untying the sutures and reusing the traumatized stump. 6) If the lumen of the proximal stump of the cervical esophagus does not match that of the ileal stump of the transplant, a longitudinal slit should be made on the esophageal stump to render the circumference of the lumens equal to each other. As the leakage used to occur within the first 12 days after reconstruction, our patients were routinely on tube-feeding through gastrostomy for the first 2 weeks after operation as a measure to safeguard the normal healing of the cervical and abdominal anastomosis.

It is worth noting that the esophageal mucosa above the upper limits of strictures should be destroyed before closure of the distal stump if the obstruction is complete, otherwise it may form a mucous-containing cyst as a result of continued secretion of the esophageal glands. We experienced two such cases; one became infected and ruptured at the suture line and the other developed symptoms of compression which required thoracotomy for total excision of the cyst.

Another technical point worthy of emphasis is concerned with position of the proximal stump of the terminal ileum at the time of ileotransverse-colostomy. Before encountering the first case of postoperative intestinal obstruction, which proved at laparotomy to be due to torsion at the site of ileocolostomy, we did not pay much attention to the direction of the mesentery of the terminal ileum and transverse mesocolon. By a lucky chance we later found that the anastomosis should be done with the mesenteries of the terminal ileum and the transverse mesocolon in opposite directions, i.e., the mesenteric side of the terminal ileum joined with the antimesenteric side of the transverse colon. Since then we have not met with a case of intestinal obstruction caused by torsion at the ileocolic anastomosis following esophageal reconstruction. To our knowledge, this technical point has never been described.

All 6 patients of the esophagocoloplasty group had some degree of regurgitation after operation. Such a complication can hardly be avoided because the transplants were antiperistaltic in their waves of movement. That is why we performed this procedure on only 6 patients in the present series of esophageal reconstruction. All were done out of necessity, not of choice.

Our reason for using a segment of terminal ileum together with the right-side colon is mainly technical. We found that the small space at the thoracic inlet accommodates the ileum much more easily than the cecum or colon and the caliber of the terminal ileum is almost the same as that of the cervical esophagus. This makes the anastomosis much easier than that of an esophagocolostomy. Moreover, by using terminal ileum, only the ileo-

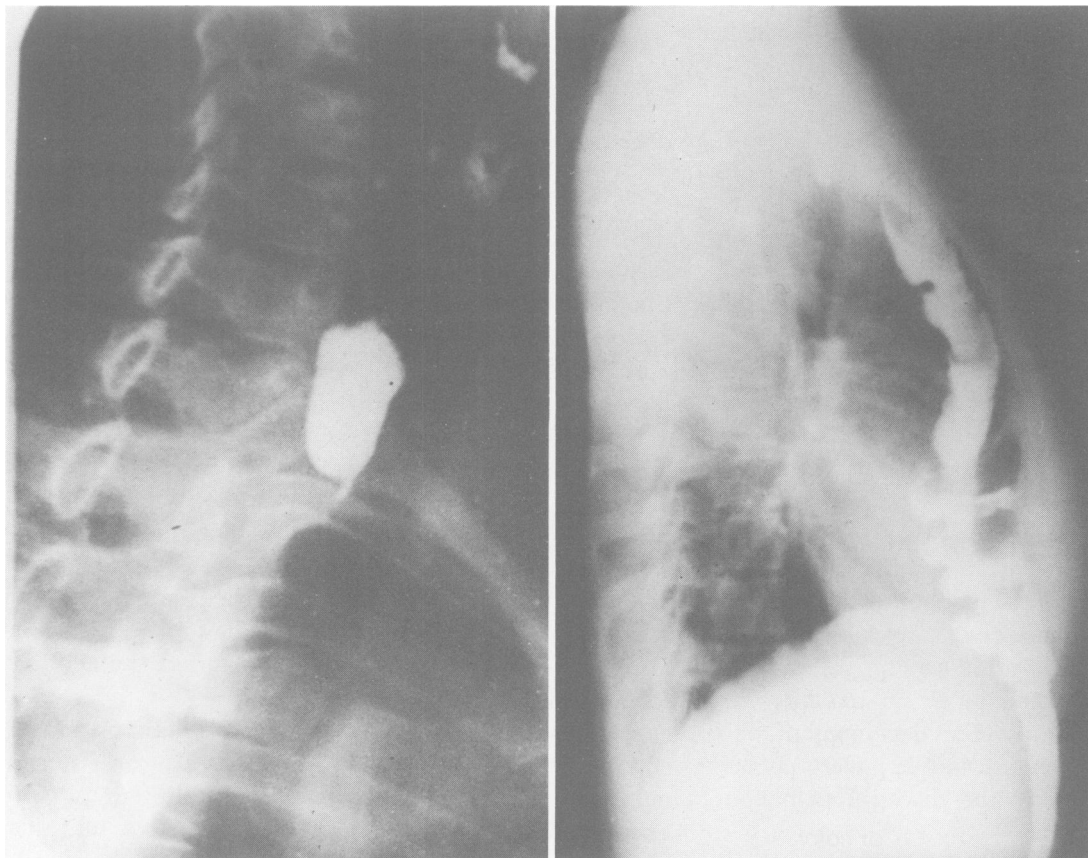


FIG. 1a. (left) Esophagogram of a 25-year-old woman with a history of lye injury. Note complete obstruction in the upper third of the esophagus. FIG. 1b. (right) Roentgenogram of the same patient 2 years after esophagoileocoloplasty showing well functioning retrosternal transplant.

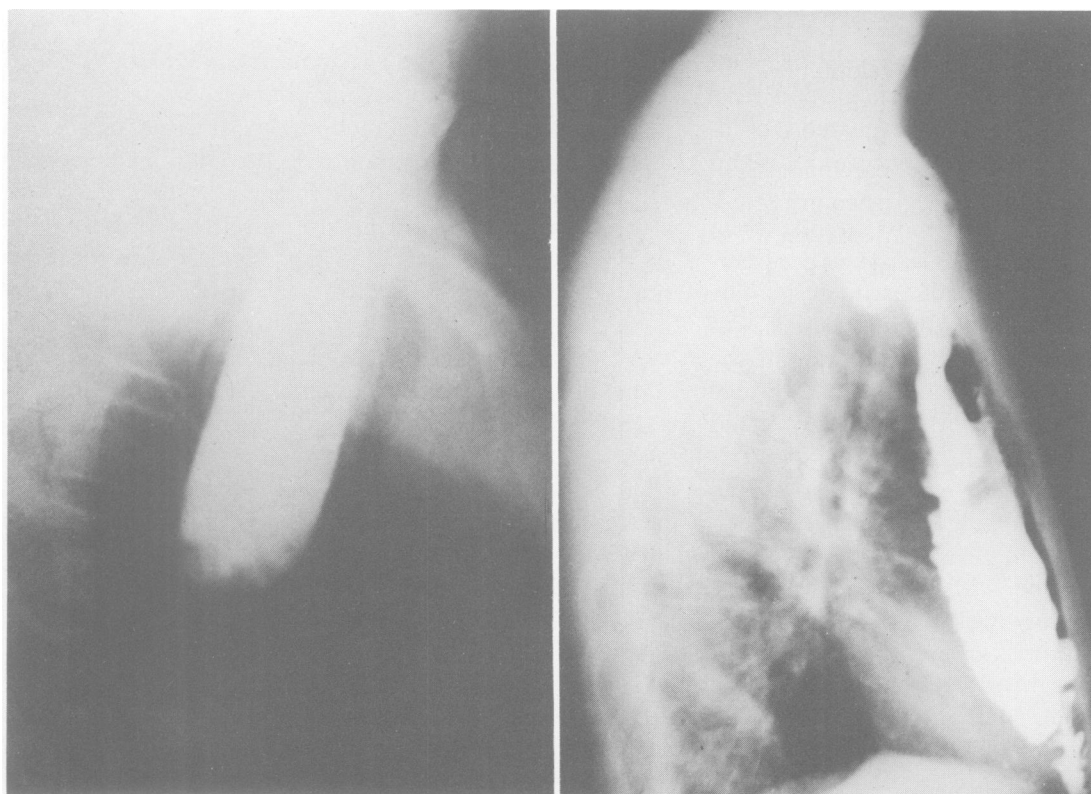


FIG. 2a. (left) Esophagogram of a 16-year-old boy with lye injury in the middle third of the esophagus. FIG. 2b. (right) Roentgenogram of the same patient 5 years after esophagoileocoloplasty showing extensive filling of the transplant.

cecal vascular pedicle is divided, otherwise the right colic pedicle has to be divided also when the ileum is not used.

The rationale of utilizing a retrosternal tunnel has already given by Robertson and Sarjeant.¹⁰ This is certainly a route of choice for bedding the intestine transplant for patients with corrosive stricture of the esophagus, especially when the stenosed esophagus will not be removed. In such cases, the utilization of a transthoracic route not only needs a longer length of the transplant, but it would be difficult to prevent diaphragmatic hernia as a rent has to be made on the diaphragm for the passage of the transplant.

It is a matter for argument whether one should anastomose the distal end of the transplant, i.e., the proximal stump of the transverse colon, end to side into the wall of the stomach or into the wall of the proximal jejunum. As far as food reservoir and digestion are concerned, it is certainly more physiologic to have a cologastrostomy than a colojejunosomy. However, there is risk of developing reflux colitis and peptic ulceration of the colon transplant, especially if the anastomosis is not followed by esophageal resection and/or vagotomy. This type of anastomotic ulcer had been documented in patients after cologastrostomy although its incidence is fairly low, ranging from 2.8 to 7.4 per cent.^{1,5,8} Our results of colojejunosomy are gratifying.

Another moot point worthy of discussion is whether the stenosed esophagus should be removed after esophagoplasty. Joske and Benedict⁴ suggested that a patient with lye stricture has a likelihood of developing carcinoma of the esophagus about 22 times greater than the average person and reported that three of 58 patients with lye stricture subsequently developed carcinoma (an incidence of 5.2 per cent). Carver *et al.*² encountered 2 cases of esophageal carcinoma in 233 patients with lye stricture (an incidence of 0.85 per cent). However, Marchand⁶ failed to find a single case of carcinoma in 135 patients with caustic stricture of the esophagus. However different the incidence may be, one must take notice of the possible difference between a stenosed esophagus which is continuously in use and that which became closed and unused. We are in complete agreement with the suggestion of Nardi⁷ that the technical hazards in attempting removal of a severely scarred esophagus outweigh the theoretical desirability of its removal. If the stenosed esophagus is left *in situ*, the vagi are not interrupted, the distressing sequale of gastric atony, pylorospasm and/or disturbance of intestinal motility are avoided, and the result of esophagoplasty will be more gratifying to the patient.

Summary

The clinical data, results and complications of esophageocoloplasty and esophagocoloplasty among 60 patients with corrosive strictures of the esophagus seen during the past 14 years are presented. Twenty-one of these 60 patients had postoperative complications which occurred mainly in the early years before standardization of our surgical technics. Effective measures for preventing postoperative complications are discussed.

The results are evaluated according to whether the patient complains of difficulty in swallowing solid, semiliquid or liquid diets after esophageal reconstruction or second operation for postoperative complications. Fifty-five of 60 patients (91.7%) were rated as good (no complications); 3 others (5%), poor (could eat liquid diets only); and the remaining 2 patients (3.3%), completely failed. One patient died shortly after operation and the operative mortality in this series is 1.7%.

Acknowledgments

The authors wish to thank Dr. George H. Humphreys II, Professor emeritus of College of Physicians & Surgeons of Columbia University, for his helpful review of the original manuscript.

References

1. Battersby, J. S. and Moore, T. C.: Esophageal Replacement and Bypass with Ascending and Right Half of the Transverse Colon for Treatment of Congenital Atresia of the Esophagus. *Surg. Gynecol. Obstet.*, **109**:207, 1959.
2. Carver, G. M. Jr., Sealy, W. C. and Dillon, M. L. Jr.: Management of Alkali Burns of the Esophagus. *JAMA*, **160**:1477, 1956.
3. Gregorie, H. B. Jr.: Esophagocoloplasty. *Ann. Surg.*, **175**:740, 1972.
4. Joske, R. A. and Benedict, E. B.: The Role of Benign Esophageal Obstruction in the Development of Carcinoma of the Esophagus. *Gastroenterology*, **36**:749, 1959.
5. Malcolm, J. A.: Occurrence of Peptic Ulcer in Colon Used for Esophageal Replacement. *J. Thorac. Cardiovasc. Surg.*, **55**:763, 1968.
6. Marchand, P.: Caustic Strictures of the Oesophagus. *Thorax*, **10**:171, 1955.
7. Nardi, G. L.: Surgical Treatment of Lye Stricture of the Esophagus by Mediastinal Colon Transplant without Resection. *New Engl. J. Med.*, **256**:777, 1957.
8. Nardi, G. L. and Glotzer, D. J.: Anastomotic Ulcer of the Colon Following Colonic Replacement of the Esophagus. *Ann. Surg.*, **152**:10, 1960.
9. Orsoni, P. and Toupet, A.: The Use of Descending Colon and Left Part of the Transverse Colon for Prethoracic Esophagoplasty. *Presse Med.*, **58**:804, 1950.
10. Robertson, R. and Sarjeant, T. R.: Reconstruction of Esophagus. *J. Thoracic Surg.*, **20**:689, 1950.
11. Storey, C. F. and Boyer, J. L.: Lye Stricture of the Esophagus: Esophageal Replacement Using the Right and Transverse Colon. *Amer. J. Surg.*, **100**:71, 1960.