

PHOSPHATASES OF THE GOLDFISH INTESTINE

BY B. C. S. HOLLANDS AND M. W. SMITH

*From The A.R.C. Institute of Animal Physiology,
Babraham, Cambridge*

(Received 3 April 1964)

The active transport of glucose shown to take place in the goldfish intestine (Smith, 1964*b*) is inhibited by ouabain, a specific inhibitor of cell membrane adenosinetriphosphatase. This paper seeks to show the histochemical location of adenosinetriphosphatase in different parts of the goldfish intestine which, to our knowledge, has not yet been investigated. For this work it has been assumed *a priori* that adenosinetriphosphatase, adenosinemonophosphatase and alkaline phosphatase are in fact three different entities and not one enzyme with a wide spectrum of activity. This is difficult to prove especially when more than one phosphatase appears to exist at the same site within a cell (Novikoff, 1958). Unfortunately this situation exists in the luminal border of mucosal cells of higher vertebrates where alkaline phosphatase (Clark, 1961) and adenosinetriphosphatase (Ashworth, Luibel & Stewart, 1963) have recently been shown to exist in the microvillar membranes of the mucosal cells. For this reason experiments reported here were strictly controlled and the interpretations modified where the substrate specificity of a particular enzyme could not be demonstrated.

Very small quantities of uridine triphosphate (UTP) cause a contraction of the goldfish intestine (Gaddum & Smith, 1963), though it is relatively insensitive to adenosine triphosphate (ATP). Experiments were designed to test whether this selectivity in producing a biological effect was reflected in a different pattern of hydrolysis for the two nucleotides within the muscle layers of the intestine.

METHODS

The goldfish alimentary tract appears as a long undifferentiated tube which widens at its oral end to form the intestinal bulb. Its anatomy has been described by McVay & Kaan (1940), who found that variations in the total length of the tract could be accounted for mainly by variations in the length of the intestinal portion. Because of the undifferentiated nature of the intestine and the variability in length, different parts were represented as fractions of the length of this intestinal portion of tract. Thus the first quarter was defined as the anterior intestine, the second and third quarter as posterior intestine and the fourth quarter as the rectum. The intestinal bulb was identified separately by virtue of its larger

diameter and thicker muscular wall compared to the intestine proper. Sections which are said to represent any of these regions have been taken as near as possible to the middle of these defined regions.

Goldfish used measured 7–10 cm and the total length of the tract measured 19–25 cm. Lengths of intestine (4–5 mm) were threaded into blocks of fresh rat liver which were then mounted onto metal microtome specimen holders and completely frozen with solid carbon dioxide. This procedure was used to support the intestine during sectioning. When comparisons were to be made between different parts of the goldfish intestine and rat ileum, the tissues to be compared were mounted as above but in a composite block. In this way any procedure after freezing was common to all tissues studied. Sections were obtained with a thickness of $4\ \mu$ on a cryostat microtome and mounted directly from the microtome knife on to slides or cover-glasses. Most of the work reported was performed on fresh tissue sections which were allowed to dry for $3\frac{1}{2}$ hr at 4°C . In some cases sections were fixed in (a) the buffered formol sucrose described previously by Holt & Hicks (1961) and (b) acetone. In both cases fixation was for $3\frac{1}{2}$ hr at 4°C .

Phosphatase localization was carried out according to the procedure of Wachstein & Meisel (1957) (medium 1) or of Padykula & Herman (1955) (medium 2). The following substrates were used in these incubation media:

Substrate	Abbreviation	Concn. (mg/ml.)		Source
		Med. 1	Med. 2	
Adenosine 5' monophosphate	AMP	0.5	1.5	C. F. Boehringer
Adenosine 5' triphosphate	ATP	0.5	1.5	Sigma Chemical Co.
Uridine 5' triphosphate	UTP	0.5	—	Pabst Laboratories
Glycerophosphate	—	5.0	5.0	Hopkin & Williams

All phosphates were used as their sodium salts.

RESULTS

It is known that when small pieces of rat liver are fixed in formal-calcium there is a loss of adenosinetriphosphatase activity (Novikoff, Hausman & Podber, 1958). The effects of different methods of fixation on the pattern and intensity of the phosphatase reaction in the goldfish intestine were therefore tested. The adenosinetriphosphatase activity of unfixed frozen sections, allowed to dry and kept at 4°C for $3\frac{1}{2}$ hr, was compared with similar sections fixed for $3\frac{1}{2}$ hr and at 4°C in acetone or in buffered formol sucrose, pH 7.2. These sections were incubated subsequently at 37°C for 30 min in the incubation medium of Wachstein & Meisel or that of Padykula & Herman together with ATP as substrate. In the unfixed and acetone-fixed sections ATP was seen to be hydrolysed at the luminal border and basement membrane of the mucosa, in the tunica propria and in the muscle. No difference in the intensity or pattern of staining could be detected between the unfixed and acetone-fixed tissue. Sections incubated in the medium of Padykula & Herman, pH 9.8, showed a heavier deposit of lead at the luminal border of the mucosal cells than that obtained with the Wachstein & Meisel medium, pH 7.2, but again there was no difference between unfixed and acetone-fixed material.

Plate 1*a* shows sections of the goldfish intestinal bulb left unfixed or fixed with formol-sucrose and then incubated in the Wachstein & Meisel or Padykula & Herman media. At pH 7.2 the hydrolysis of ATP by the formol-fixed material is much less than that by unfixed tissue. At pH 9.8 the phosphatase located at the luminal border of the mucosa is seen clearly in the formol-fixed tissue but the rest of the section remains only faintly stained. The great loss of adenosinetriphosphatase activity caused by formol fixation was unacceptable and acetone fixation did not improve the amount or localization of the reaction product and so it was decided to use unfixed, dried, frozen sections in subsequent experiments.

Localization and substrate specificity of goldfish intestinal phosphatases

Fresh frozen sections of the goldfish intestinal bulb, the anterior and posterior intestine and the rectum were incubated for 30 min at 37° C in the medium of Wachstein & Meisel or of Padykula & Herman using ATP, AMP and glycerophosphate as substrates. The sites of hydrolysis for these three substrates are shown in Pl. 2. The two media gave the same distribution of reaction product but the hydrolysis of all three substrates at the luminal border of the mucosa was probably enhanced at the higher pH. Hydrolysis of all three substrates also occurred at this site in the anterior

TABLE I

Tissue	Substrate		
	GP	AMP	ATP
Mucosa			
Luminal border	+	+	+
Basement membrane	-	+	⊕
Tunica propria			
Of the villus	+	+	+
Beneath the villus	+	⊕	+
Muscle layers	-	-	⊕

The distribution of phosphatases within the goldfish intestine. Fresh frozen sections of goldfish intestine were incubated in Wachstein & Meisel (1957) or Padykula & Herman (1955) medium for 30 min at 37° C. The pattern of distribution of phosphatases is valid for both methods using the intestinal bulb, the anterior and posterior intestine, but not the rectum. +, phosphatase activity present; ⊕, phosphatase activity present which exhibits some degree of substrate specificity; -, phosphatase activity absent. GP, glycerophosphate.

and posterior intestine, the reaction was more intense in the crypts compared with the tips of the villi, but in both situations became less towards the rectum. In the rectum little or no hydrolysis could be seen. ATP was hydrolysed at the base of the mucosa and a similar reaction took place in the anterior and posterior intestine and in the rectum. In no case did the amount of reaction product appear dependent upon the pH of the incu-

bation medium. No reaction was seen at this site when glycerophosphate was used as substrate and only a faint reaction was seen when AMP was the substrate used.

The tunica propria and muscle layers of the intestinal bulb hydrolysed ATP. The muscle did not hydrolyse AMP or glycerophosphate and the tunica propria was generally less heavily stained with these two substrates (see Pl. 2). An exception to this occurred in areas adjacent to the muscle and extending slightly into the centre of individual villi where AMP was hydrolysed in preference to ATP or glycerophosphate. The hydrolysis of all substrates in the tunica propria persisted into the rectum if incubation was at a pH of 7.2 but at pH 9.8 hydrolysis was negligible in the rectum. These results are summarized in Table 1.

Adenosinetriphosphatase of the rat and goldfish intestine. A piece of rat ileum and anterior intestine of the goldfish were mounted together in rat liver. The composite block was frozen and unfixed sections taken for incubation in the Wachstein & Meisel medium at 37° C for 30 min. Some of the more diffuse non-specific lead phosphate was removed by rinsing the section briefly in 2% (wt./vol.) acetic acid before immersion in ammonium sulphide solution. Since sections of rat ileum and goldfish intestine were cut and mounted as one block, the treatment of both tissues was identical throughout. The results are shown in Pl. 1*b*. The adenosinetriphosphatase activity of the rat was generally greater than that of the goldfish intestine. Thus the muscle layers and the mucosal luminal borders of the rat ileum showed a heavy lead deposit but were only lightly stained in the goldfish. However, the strong line of hydrolytic activity at the base of the goldfish mucosa was as strong as that within the rat intestinal villus; moreover, no continuous line of staining could be demonstrated at this site in the rat mucosa.

Hydrolysis of UTP and ATP by the goldfish intestine. Unfixed frozen sections of the goldfish anterior intestine were incubated in the Wachstein & Meisel medium for 30 min at 37° C with ATP or UTP as substrate. The concentration of ATP and UTP was the same on a weight basis and consecutive sections were used for comparison. Again 2% (wt./vol.) acetic acid was used to clear the sections before precipitation of the lead phosphate as lead sulphide. The distribution and intensity of phosphatase reaction was very similar for the two nucleotides with one important exception (see Pl. 1*c*). The area at or near the basement membrane of the goldfish mucosa hydrolysed ATP but gave a negative result when UTP was used as substrate. Sections of rat ileum treated as above showed no obvious distinction in the pattern of hydrolysis between ATP and UTP.

DISCUSSION

The hydrolysis of phosphate-containing substrates which has been shown to occur at the luminal border of the goldfish mucosa is not substrate-specific at pH 7.2 or 9.8. Novikoff (1958) has pointed out the difficulties of showing substrate-specific phosphatases in the rat intestinal mucosa and it could be misleading to talk about *an* adenosinetriphosphatase or alkaline phosphatase activity at this site if any particular biochemical or physiological inference is to be drawn from such findings. It may be argued that several enzymes, each one specific for one phosphate-containing substrate, exist in the brush border of the intestinal mucosa and as some support for this view Morton (1955) was able to isolate from calf intestinal mucosa a soluble alkaline phosphatase which did not hydrolyse ADP or ATP. On the other hand adenosinetriphosphatase may not be specific; Tosteson & Blaustein (1961) were able to show that *p*-nitrophenyl phosphate could compete with ATP for this enzyme. ATP and glycerophosphate were hydrolysed at the luminal border of the goldfish intestine with equal facility. From the intestinal bulb to the rectum there was well defined hydrolytic activity but in the rectum itself there was negligible hydrolysis. If more than one enzyme is responsible for these effects, not only do they exist side by side in the mucosa but they also parallel the distribution of each other along the intestine. It would be simpler to assume until proved wrong that one non-specific phosphatase is present at this site in the goldfish intestine.

At the base of the mucosa there was found an adenosinetriphosphatase; AMP gave only a faint reaction and glycerophosphate no reaction whatever. UTP was not hydrolysed at this site in the mucosa. Here was a substrate-specific enzyme which could differentiate between high and low energy phosphates and between the adenosine and uridine parts of the nucleotide triphosphates. The exact location of the enzyme appeared to be in the basement membrane but on occasions nuclei near the basement membrane were also stained. This is probably an artifact due to diffusion of the enzyme; similar phenomena have been noted by Pearse (1960) and it is known that this nuclear staining becomes more pronounced when higher concentrations of substrates are used (Padykula & Herman, 1955). Of the two sites for adenosinetriphosphatase activity within the goldfish mucosa, experiments with ouabain (Smith, 1964*b*) suggest that it is the substrate-specific enzyme located at the base of the mucosa which is implicated in the active transport of glucose.

The muscle layers of the goldfish intestine hydrolysed both ATP and UTP and no difference could be seen between these two substrates although UTP is far more potent than ATP in causing a contraction of the muscle

fibres (Smith, 1964*a*). Also AMP, which is slightly more effective than ATP in causing a contraction of the goldfish intestine (Gaddum & Szerb, 1961), was not hydrolysed at all by the muscle. These results are perhaps not surprising when it is considered that the hydrolysis of a substrate is only one of many factors which determine its final biological effect.

There were differences in the intensity and pattern of the histochemical reaction for adenosinetriphosphatase between the rat and goldfish intestine. It has been assumed that the anterior intestine of the goldfish corresponds anatomically to the ileum of the rat but the results would have been the same if other areas, excluding the rectum, of the goldfish tract had been used for this comparison. The quicker hydrolysis of substrates in the rat ileum might mean that the higher vertebrate has a greater concentration of phosphatases but the temperature chosen for incubation, 37° C, was probably not optimal for the goldfish. The other striking difference between the two intestines was the lack of any pronounced hydrolysis of ATP at the base of the rat intestinal mucosa. Ashworth *et al.* (1963) were able to show in electron micrographs a lead deposit at this site but it was in no way comparable with that seen in the goldfish mucosa. Further work is needed before the physiological function of this apparently highly active, ATP-specific phosphatase can be defined.

SUMMARY

1. The location of phosphatases within the goldfish intestine has been studied using two histochemical methods and four phosphate-containing substrates (ATP, UTP, AMP and glycerophosphate).

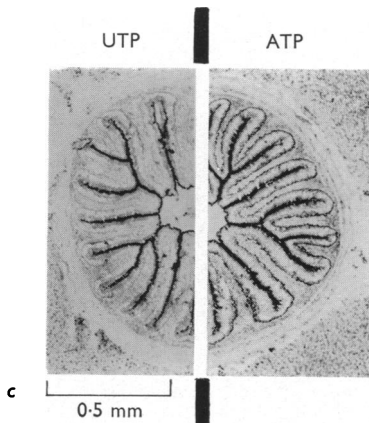
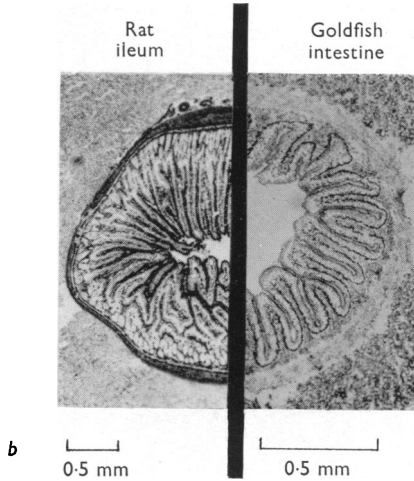
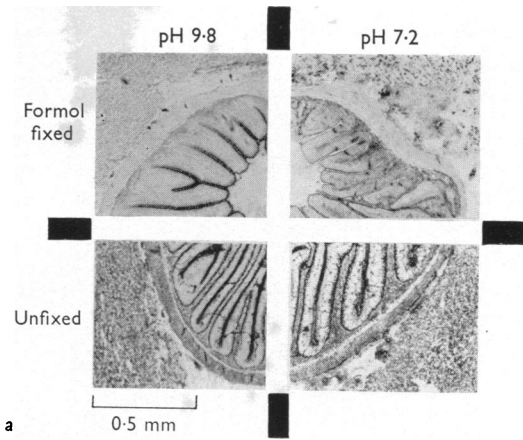
2. ATP, AMP and glycerophosphate were hydrolysed at the luminal border of the mucosal cells in the intestinal bulb and the intestine proper but not in the rectum. UTP was only incubated with sections of anterior intestine where it was hydrolysed at the luminal border of mucosal cells in a way similar to the other substrates.

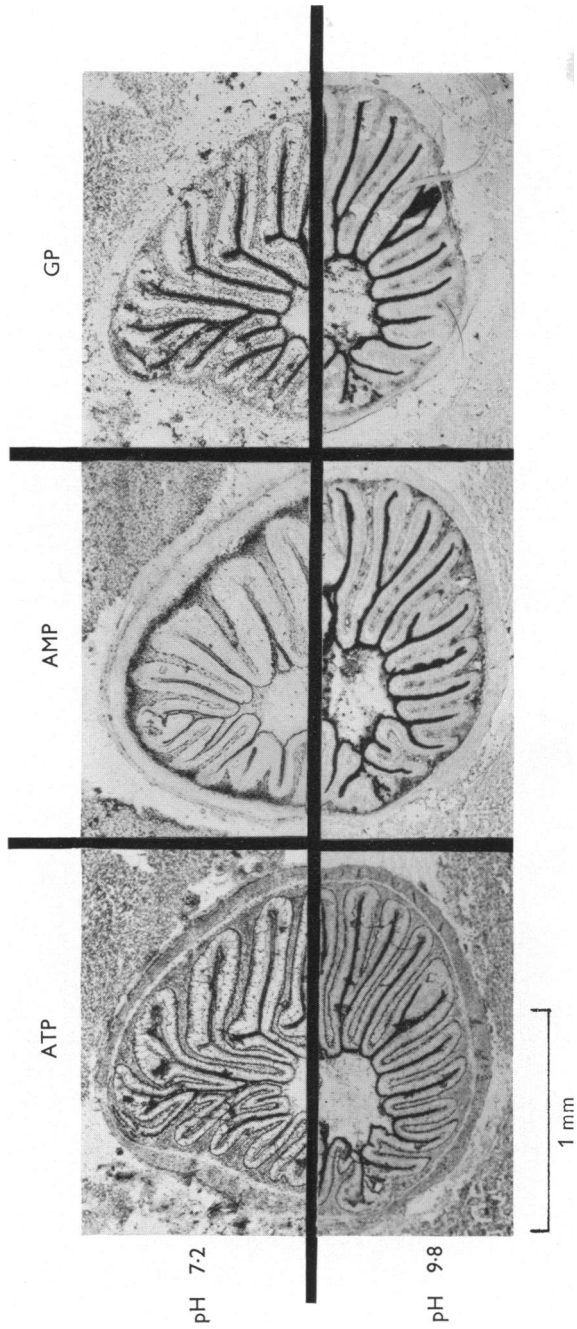
3. ATP and UTP but not AMP or glycerophosphate were hydrolysed by enzymes in the muscle of the goldfish intestine.

4. The hydrolysis of ATP and UTP in the muscle or at the luminal border of the goldfish intestine was less pronounced than for the rat ileum.

5. There was found at the base of the goldfish mucosa an adenosinetriphosphatase which was present along the whole length of the tract and which exhibited a high degree of substrate specificity.

We would like to express our thanks to Mr A. Shaw for his photographic work.





REFERENCES

- ASHWORTH, C. T., LUIBEL, F. J. & STEWART, S. C. (1963). The fine structural localization of adenosine triphosphatase in the small intestine, kidney and liver of the rat. *J. cell. Biol.* **17**, 1-18.
- CLARK, S. L. (1961). Alkaline phosphatase of the small intestine studied with electron microscope in suckling and adult mice. *Anat. Rec.* **139**, 216.
- GADDUM, J. H. & SMITH, M. W. (1963). A pharmacologically active substance in mammalian tissue extracts. *Proc. Roy. Soc. B.* **157**, 492-506.
- GADDUM, J. H. & SZERB, J. C. (1961). Assay of substance P on goldfish intestine in a microbath. *Brit. J. Pharmacol.* **17**, 451-463.
- HOLT, S. J. & HICKS, R. M. (1961). Studies on formalin fixation for electron microscopy and cytochemical staining purposes. *J. cell. Biol.* **11**, 31-45.
- MCVAY, J. A. & KAAAN, H. W. (1940). The digestive tract of *carassius auratus*. *Biol. Bull., Woods Hole*, **78**, 53-67.
- MORTON, R. K. (1955). The substrate specificity and inhibition of alkaline phosphatases of cow's milk and calf intestinal mucosa. *Biochem. J.* **61**, 232-240.
- NOVIKOFF, A. B. (1958). Distinguishing substrate-specific phosphatases. *J. Histochem. Cytochem.* **6**, 251-254.
- NOVIKOFF, A. B., HAUSMAN, D. H. & PODBER, E. (1958). The localization of adenosine triphosphatase in liver: *in situ* staining and cell fractionation studies. *J. Histochem. Cytochem.* **6**, 61-71.
- PADYKULA, H. A. & HERMAN, E. (1955). Factors affecting the activity of adenosine triphosphatase and other phosphatases as measured by histochemical techniques. *J. Histochem. Cytochem.* **3**, 161-169.
- PEARSE, A. G. E. (1960). Histochemistry theoretical and applied. London: J. and A. Churchill.
- SMITH, M. W. (1964*a*). Some pharmacological properties of uridine nucleotides. *Brit. J. Pharmacol.* **22**, 254-266.
- SMITH, M. W. (1964*b*). The *in vitro* absorption of water and solutes from the intestine of goldfish, *carassius auratus*. *J. Physiol.* **175**, 38-49.
- TOSTESON, D. C. & BLAUSTEIN, M. P. (1961). Phosphomonoesterase and Na+K activated ATP-ase. *Fed. Proc.* **20**, 138.
- WACHSTEIN, M. & MEISEL, E. (1957). Histochemistry of hepatic phosphatases at a physiologic pH with special reference to the demonstration of bile canaliculi. *Amer. J. clin. Path.* **27**, 13-23.

EXPLANATION OF PLATES

PLATE 1

- (a) Frozen sections (4 μ) of goldfish intestinal bulb, unfixed or treated with formol-sucrose and then incubated for 30 min at 37° C with ATP in the Wachstein & Meisel (pH 7.2) or the Padykula & Herman (pH 9.8) medium.
- (b) Frozen sections (4 μ) of the rat ileum and goldfish anterior intestine incubated for 30 min at 37° C in the Wachstein & Meisel medium using ATP as substrate.
- (c) Frozen sections (4 μ) of goldfish anterior intestine incubated for 30 min at 37° C in the Wachstein & Meisel medium with ATP or UTP as substrate.

PLATE 2

Frozen sections (4 μ) of goldfish intestinal bulb incubated with ATP, AMP or glycerophosphate (GP) in the Wachstein & Meisel (pH 7.2) or the Padykula & Herman (pH 9.8) medium for 30 min at 37° C.