

SYMPATHETIC NERVOUS CONTROL OF BROWN ADIPOSE TISSUE AND HEAT PRODUCTION IN THE NEW-BORN RABBIT

BY D. HULL AND M. M. SEGALL

*From the Nuffield Institute for Medical Research,
University of Oxford*

(Received 23 March 1965)

The sympathetic nervous system exerts an important influence on fat metabolism in adipose tissue (Shapiro & Wertheimer, 1956). Depletion of fat from the interscapular pad of brown adipose tissue in adult mice is retarded by dividing the mixed nerves to the pad (Hausberger, 1934; Sidman & Fawcett, 1954) and it has been suggested that this is due to the division of sympathetic fibres running with the nerves (Beznák & Hasch, 1937; Clément, 1950). Stimulation *in vitro* of the nerves supplying the interscapular adipose tissue of adult rabbits produces a rise in the free fatty acid content of the medium (Correll, 1963).

The present experiments were undertaken to study the effect of sympathetic denervation on the depletion of fat from brown adipose tissue in new-born rabbits and to investigate the role of the sympathetic nervous system in regulating heat production by the tissue. They show that section of the cervical sympathetic nerve or excision of the stellate ganglion retards the depletion of fat that normally occurs in the tissue when the animal is exposed to cold and that cervical sympathetic stimulation *in vivo* produces a rise in the temperature of the tissue. In the new-born rabbit heat production in response to cold exposure occurs principally in brown adipose tissue (Hull & Segall, 1965*a*) and is due to the local oxidation of fat (Dawkins & Hull, 1964). The conclusion is drawn that this response is mediated by the sympathetic nervous system. A preliminary report of these experiments has been given (Hull & Segall, 1965*b*).

METHODS

Brown adipose tissue was denervated in thirty-three rabbits weighing from 38 to 78 g during the first four days of life. The rabbits had been born normally and suckled. They were anaesthetized with ether or intraperitoneal urethane (1 g/kg body wt.) The operations were carried out with the aid of a dissecting microscope. The cervical sympathetic nerve on one side was cut at the root of the neck in seventeen rabbits, care being taken not to damage the common carotid artery. Twelve experiments were performed on the right side and five

on the left side. The sympathetic ganglia at the thoracic inlet (referred to here as the 'stellate ganglion') were excised in eight rabbits. All these operations were performed on the right side because the division of the brachio-cephalic artery into the right common carotid and subclavian arteries provided a reliable anatomical landmark. The ganglia were approached through an incision immediately above the clavicle. Sometimes the uppermost part of the sternum was removed to aid exposure. The ganglia were identified by their pearly grey appearance and their continuity above with the cervical sympathetic nerve. Filaments could be seen leaving the ganglia to run with the subclavian artery. There was frequently a small ganglion above or in front of the subclavian artery just after its origin, but the main ganglion lay behind and below the subclavian artery in the chest. Removing this ganglion involved making a small hole in the cervical pleura and avulsing it with fine forceps.

Control operations were performed in which the arteries of the region were ligated and the nervous tissue was left intact. The common carotid artery on one side was ligated at the root of the neck in six rabbits. The cervical sympathetic nerve was dissected away from the artery before the ligation. Three experiments were performed on the left side and three on the right side. Ligation of the subclavian artery and of its branch to the brown adipose tissue were found to be unsatisfactory control procedures.

The interscapular brown adipose tissue was denervated on one side in eight rabbits by dividing the spinal nerves entering the pad from the mid line. These nerves are very fine and only just discernible under the dissecting microscope. The right pad was denervated in three experiments and the left in five experiments.

At each operation a small piece of brown adipose tissue was removed for histological examination. If the tissue was found to be depleted of fat at this time, the animal was rejected. After operation the rabbits were kept unfed in an incubator for 48–72 hr at a cool ambient temperature (30° C) and then killed. The gross appearance of the brown adipose tissue was noted. Tissue for histological examination was fixed in 10% formol saline or Helly's fluid (Zenker-formol) and embedded in paraffin; 4 μ sections were cut and stained with haematoxyline and eosin and sometimes with Heidenheim's aniline blue.

The cervical sympathetic nerve was stimulated in seventeen rabbits 8–16 days old weighing from 110 to 450 g. Older rabbits were used for these experiments because they had better thermal insulation and it was easier to maintain constant the deep colonic temperature. Also it was possible to separate the eyelids and observe the size of the pupils. The rabbits were anaesthetized with intraperitoneal urethane (1 g/kg body wt.). The cervical sympathetic nerve was stimulated at the root of the neck above the stellate ganglion usually on each side in turn. The common carotid artery was exposed and reflected so that the cervical sympathetic nerve could be gently dissected away from its posterior aspect. Contusion of the nerve occurred very readily and extreme care in dissection was necessary to avoid this. The nerve was kept moist with physiological saline. A sufficient length was mobilized to allow a stimulating electrode to be inserted comfortably beneath it without causing undue tension. The surrounding tissue was retracted out of contact with the electrode to avoid current spread. Either a unipolar, silver/silver chloride electrode or a bipolar, 'floating', platinum electrode was used and for stimulation the nerve and electrode were immersed in a pool of paraffin. A rectangular constant-current stimulus was applied for periods of 3–8 min. In order to determine the correct stimulus characteristics, an experiment on a new-born rabbit's cervical sympathetic nerve was carried out *in vitro*. A length of nerve 1 in. long was excised and the proximal end draped over a bipolar, platinum, stimulating electrode in a paraffin pool. The distal end was placed over a bipolar, silver/silver chloride, recording electrode connected to an oscilloscope. The stimulus artifact was deleted from the recording by means of a platinum earth placed between the two electrodes. A nerve potential was obtained when the stimulus current exceeded 1.0–1.5 mA and the duration of the stimulus was between 0.25 and 10 msec. At a stimulus frequency of 10/sec the nerve potential decreased in amplitude after about 30 sec, whereas at 3/sec it persisted

unchanged for several minutes. The experiments *in vivo* employed the following stimulus characteristics: current 1.0–2.5 mA, duration 0.5–6 msec, frequency 3–10/sec. The temperature of the ipsilateral anterior cervical lobe of brown adipose tissue was measured by a copper/constantin thermocouple inserted into the tissue and was recorded on a Cambridge slow recorder. The rabbit was warmed by radiant heat and the deep colonic temperature, recorded by a second thermocouple, was kept constant. Care was taken to avoid alterations in the thermal environment during the experiment. In each animal a fresh solution of nor-adrenaline bitartrate (Winthrop Laboratories) in a dose of 2 μ g base/kg.min was infused for 3–8 min into an external jugular vein before the nerve stimulation. If the infusion failed to cause a rise in the temperature of the brown adipose tissue the animal was rejected.

The detailed morphology and blood supply of brown adipose tissue in the new-born rabbit has been described (Hull & Segall, 1965*a*). Briefly, the tissue encircles the neck and extends backwards between the scapulae. The interscapular tissue consists of two pads, one on either side of the mid line. The cervical tissue on each side is divided into four lobes (anterior, posterior, lateral and upper). Despite its name, brown adipose tissue which is replete with fat is yellow in colour. Histological examination of the tissue in this state shows that each cell is filled with a number of fat vacuoles, and only occasional univacuolar cells are seen. This is the condition of the tissue at birth. Brown adipose tissue becomes red-brown in colour only if it is depleted of fat and histologically the cells then have deeply stained cytoplasm containing few or no fat vacuoles. The interscapular brown adipose tissue appears to deplete of fat more slowly than the cervical tissue and may be partially yellow when the latter is completely red-brown. Histologically there are a greater number of univacuolar cells, particularly around the periphery of the pad. When the multivacuolar cells are depleted of fat the univacuolar cells are still seen, frequently as islands of pale cells in the stained tissue.

RESULTS

The effect of fasting and cold exposure on the appearance of the cervical brown adipose tissue

Fasting and exposure to a cool environment (30° C) reduces the fat content of brown adipose tissue. Five rabbits were kept unfed for the first 48 hr of life at an ambient temperature of 35–37° C (i.e. in the thermo-neutral range) and then killed. The cervical brown adipose tissue in these animals was intermediate in colour between yellow and red and histological sections showed that the cells were moderately replete with fat vacuoles. Six further rabbits were kept for the first 48 hr of life at an ambient temperature of 30° C. They fed at the time of delivery and were again placed with the suckling doe at 24 hr of age, when they each took 5–13 g of milk. At 48 hr of age they were killed. In these animals the cervical brown adipose tissue was more red-brown in colour and histologically the cells appeared partially or completely depleted of fat. Hence prolonged exposure of the new-born rabbit to a cool environment is more potent than fasting in stimulating the utilization of the brown adipose tissue fat.

The effect of denervation and arterial ligation on the appearance of the brown adipose tissue

The cervical sympathetic nerve was cut on one side in seventeen rabbits. The animals were kept for 48–72 hr unfed at 30° C and then killed. On the innervated side, the cervical brown adipose tissue was red-brown in colour and on histological section the cells appeared partially or completely depleted of fat. On the denervated side, the anterior lobe, the upper lobe, the cephalic half of the posterior lobe and usually the cephalic tip of the lateral lobe were yellow in colour. (Occasionally a strip along the base of the lateral lobe was also yellow.) These areas were easily distinguished from the remainder of the cervical brown adipose tissue on the operated side, which resembled the tissue on the control side (Pl. 1*a*). Histological sections made from the yellow areas showed that the cells were substantially replete with fat (Pl. 2).

The right stellate ganglion was excised in eight rabbits. The animals were kept for 48 hr unfed at 30° C and then killed. On the innervated side, the cervical brown adipose tissue was red-brown in colour (Pl. 1*b–d*) and the cells appeared partially or completely depleted of fat. On the denervated side, the entire cervical brown adipose tissue was yellow (Pl. 1*b, c, e*) and the cells appeared replete with fat.

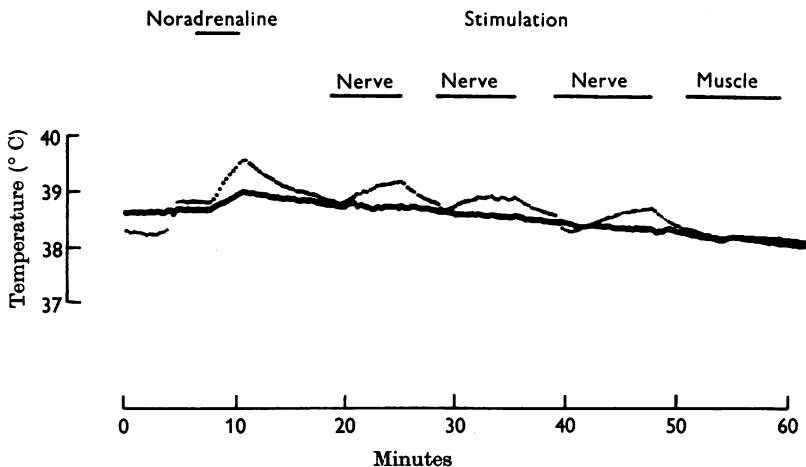
The common carotid artery was ligated in six rabbits. After 48–72 hr fasting at 30° C, the entire cervical brown adipose tissue was red-brown in colour and the cells appeared partially or completely depleted of fat. There was no difference in the appearance of the two sides (Pl. 1*a*).

The interscapular pads of brown adipose tissue were denervated locally in eight rabbits. It was not possible to ensure complete denervation because of difficulty in identifying the very fine nerves. The rabbits were kept unfed for 48–72 hr at 30° C and then killed. In five experiments there was some gross and histological evidence of fat retention in the denervated pad, but the results were not as clear as those from the experiments on the cervical brown adipose tissue.

In two of five rabbits in which the stellate ganglion was removed on one side the cephalic half of the interscapular pad on the denervated side was more yellow than on the unoperated side (Pl. 1*c*) and in four there was histological evidence of retention of fat in this part of the pad. Depletion of fat from the caudal half of the interscapular pad appeared unaffected by the stellate ganglionectomy. In nine rabbits section of the cervical sympathetic nerve had no effect on the depletion of fat from the interscapular tissue.

Stimulation of the cervical sympathetic nerve

The cervical sympathetic nerve was stimulated in twenty-seven experiments on seventeen rabbits. Stimulation usually resulted in dilatation of the ipsilateral pupil. In nine experiments a reproducible rise in temperature ($0.2-0.6^{\circ}\text{C}$, mean 0.31°C) occurred in the ipsilateral anterior cervical lobe of brown adipose tissue. In some instances this was preceded by a small, transient fall in temperature. In eighteen experiments stimulation produced either no effect or only the immediate small fall in temperature ($0.1-0.3^{\circ}\text{C}$, mean 0.18°C). Direct stimulation of the adjacent tissue, including the brown adipose tissue itself, did not cause any alteration in temperature. Deep colonic temperature was always the same or below that of the brown adipose tissue and was not affected by nerve



Text-fig. 1. The temperature of the anterior cervical lobe of brown adipose tissue (top trace) and the deep colonic temperature (bottom trace) in a 10-day-old rabbit during an intravenous infusion of noradrenaline ($2\ \mu\text{g}/\text{kg}\cdot\text{min}$), electrical stimulation of the cervical sympathetic nerve and stimulation of the adjacent muscle. Rectangular constant-current stimulus $1.2\ \text{mA}$, duration $6\ \text{msec}$, frequency $10/\text{sec}$.

stimulation. Intravenous infusion of noradrenaline produced a rise in the brown adipose tissue temperature ($0.3-1.2^{\circ}\text{C}$, mean 0.67°C) and also a small rise in deep colonic temperature.

The response to cervical sympathetic stimulation in a 10 day old rabbit weighing $170\ \text{g}$ is shown in Text-fig. 1. A 3 min intravenous infusion of noradrenaline caused a rise in the brown adipose tissue temperature (top trace) of 0.8°C and also elevated the deep colonic temperature (bottom trace) by 0.3°C . Three consecutive nerve stimulations then produced a rise in the brown adipose tissue temperature of $0.2-0.4^{\circ}\text{C}$, with no effect on

the deep colonic temperature. In each case stimulation had the immediate effect of lowering the temperature of the brown adipose tissue by a small amount and this persisted for about a minute before the rise in temperature began. This is seen most clearly during the third period of stimulation. In the first and third stimulations the temperature of the brown adipose tissue was still rising when the stimulation was discontinued, whereas the temperature reached its peak during the course of the second stimulation and was then remaining constant. In all three instances the brown adipose tissue temperature fell immediately the stimulation ceased. At the end of the experiment the electrode was detached from the nerve and placed in contact with a piece of adjacent muscle. Stimulation for 8 min produced muscle twitching but had no effect on the temperature of the brown adipose tissue.

DISCUSSION

There is considerable evidence that the nervous system influences fat metabolism in adipose tissue (Shapiro & Wertheimer, 1956). Much of the work on this subject has in fact been done on brown adipose tissue. Hausberger (1934) divided the nerves entering one interscapular brown adipose-tissue pad in adult mice and found that depletion of fat during starvation was retarded on the denervated side. This was confirmed by Sidman & Fawcett (1954), who utilized both cold exposure and fasting to stimulate depletion of fat. Beznák & Hasch (1937) showed that mobilization of fat from perirenal adipose tissue in starved adult cats was diminished by cutting the splanchnic nerves, thus demonstrating that the sympathetic nervous system was involved. They further suggested that the results obtained by Hausberger were due to the division of sympathetic fibres running with the mixed nerves to the interscapular fat pads. Clément (1950) refers to the nerves supplying the interscapular brown adipose tissue pads in the adult rat as 'les cinq premiers rameaux sympathiques de la chaîne thoracique'. He confirmed that denervation retards mobilization of fat from the perirenal adipose tissue and the interscapular brown adipose tissue in unfed adult rats. The present experiments demonstrate that depletion of fat from the cervical brown adipose tissue in new-born rabbits is retarded by sympathetic denervation. In these experiments, although utilization of fat was stimulated by both fasting and prolonged exposure to cold, it appears from the preliminary experiments that the predominant stimulus was in fact the cold exposure.

The division of the cervical sympathetic nerve led to retention of fat in the areas of the cervical brown adipose tissue that corresponded to the carotid arterial supply to the tissue (Hull & Segall, 1965*a*). Ligation of the common carotid artery, however, did not retard the depletion of fat. Therefore the retention of fat was not due to operative interference with the

central supply of blood to the brown adipose tissue. Stellate ganglionectomy led to additional areas of fat retention that corresponded to the subclavian (and axillary) arterial supply to the tissue. The pattern of the retention therefore suggests that the sympathetic nerves are distributed to the cervical brown adipose tissue along the arteries. Indeed, under the dissecting microscope fine branches could be seen passing from the stellate ganglion to run with the subclavian artery. The sympathetic influence on brown adipose tissue may be exerted directly on the fat cells or indirectly by affecting the peripheral blood flow in the tissue. These experiments do not elucidate this point, but other evidence (*vide infra*) suggests that the former mechanism is more likely.

The experiments on the interscapular pads were not conclusive. Complete local denervation may not have been achieved, but some evidence was obtained that retardation of fat depletion occurred in the denervated pads. This result agrees with those of similar experiments on adult mice, rabbits and rats (Hausberger, 1934; Clément, 1950; Sidman & Fawcett, 1954). Whereas section of the cervical sympathetic nerve had no effect on the interscapular brown adipose tissue, stellate ganglionectomy appeared to retard the depletion of fat from the cephalic half of the interscapular pad. It seems probable that the interscapular pads of brown adipose tissue are innervated by the upper part of the thoracic sympathetic outflow which is distributed to them by the thoracic spinal nerves. Stellate ganglionectomy destroys the sympathetic supply only to the first one or two thoracic nerves and would therefore be expected to affect only the cephalic part of the interscapular tissue.

Stimulation of the cervical sympathetic nerve led to a rise in temperature of the brown adipose tissue in one third of the experiments. Unlike noradrenaline it did not elevate the deep colonic temperature. Intravenous infusion of noradrenaline stimulates heat production from the entire bulk of brown adipose tissue, whereas the nerve stimulation would affect only the amount of tissue supplied by one cervical sympathetic nerve. Heat produced from this small mass of tissue would not contribute significantly to the body's total heat production and would not affect the deep body temperature.

The cervical sympathetic nerve is extremely delicate in the new-born rabbit and inadvertent damage to it during dissection and manipulation for stimulation could account in part for the failure to obtain a temperature rise in two thirds of the experiments. In some of these, however, stimulation nevertheless produced dilatation of the ipsilateral pupil and/or an immediate fall in temperature of the brown adipose tissue. Possibly the fibres mediating these responses were more easily stimulated. The experiments that did not result in a temperature rise were, however, useful.

They showed that the rise in temperature that occurred in the other experiments was not an artifact due to an electrical effect on the recording thermocouple.

Sympathetic stimulation might affect the temperature of the brown adipose tissue by altering the tissue blood flow alone or by stimulating its production of heat. The immediate small fall in temperature observed in some instance was probably a vasomotor effect. It is unlikely that this mechanism can account for both the fall and the rise in the tissue temperature. The evidence from other sources suggests that the rise in temperature was due to direct sympathetic stimulation of heat production by the brown adipose tissue cells. Thus, the nerve fibrils in brown adipose tissue are non-myelinated (Napolitano & Fawcett, 1958) and appear to end in contact with the fat cells (Hausberger, 1934; Sidman & Fawcett, 1954). Correll (1963) made nerve-fat preparations of the epididymal white adipose tissue of the rat and rabbit and the interscapular brown adipose tissue of the rabbit *in vitro*. He found that stimulation of the nerves led to a rise in the free fatty acid content of the medium. Previous lumbar sympathectomy abolished the response of the epididymal fat preparations, thus demonstrating that the effect was sympathetically mediated. Noradrenaline is present in brown adipose tissue in high concentration, probably mostly in nerve fibres (Sidman, Perkins & Weiner, 1962). Noradrenaline stimulates heat production by brown adipose tissue (Dawkins & Hull, 1964). Adrenaline, which resembles noradrenaline in its effect on fat metabolism, has been shown to activate a lipolytic enzyme system in adipose tissue (Rizack, 1961). The hydrolysis of triglyceride in the adipose tissue cell is followed by re-esterification in a process that involves the oxidation of fatty acids and/or glucose and the production of heat (Ball & Jungas, 1961). There is therefore histological, physiological and biochemical evidence which indirectly suggests that sympathetic activity, by the release of noradrenaline in contact with the fat cell, stimulates heat production by brown adipose tissue. The present experiments provide direct evidence that this is so.

It has been suggested that the sympathetic nervous system may play an important role in the regulation of non-shivering thermogenesis in new-born mammals (Moore & Underwood, 1963). In the new-born rabbit heat production in response to cold exposure occurs principally in brown adipose tissue (Hull & Segall, 1965*a*). The present experiments show that this response is mediated by the sympathetic nervous system and thus support this view.

SUMMARY

1. The effect of unilateral sympathetic denervation on the depletion of fat from brown adipose tissue in new-born rabbits was investigated. Utilization of fat was stimulated by starvation and exposure of the animals to a cool environment (30° C) for 48–72 hr. The gross and histological appearances of the brown adipose tissue on the two sides were then compared.

2. Cutting the cervical sympathetic nerve resulted in marked retardation of fat depletion in part of the cervical brown adipose tissue. The affected areas corresponded to the carotid arterial supply to the tissue.

3. Stellate ganglionectomy resulted in retardation of fat depletion in the entire cervical brown adipose tissue on the operated side. The additional areas affected corresponded to the subclavian arterial supply to the tissue.

4. Carotid arterial ligation did not affect the fat depletion. It is suggested that the sympathetic nerves are distributed to the cervical brown adipose along the arteries.

5. Local denervation of the interscapular pads of brown adipose tissue also suggested that denervation retarded the depletion of fat. Stellate ganglionectomy appeared to retard the depletion of fat from the cephalic half of the interscapular pad. Cutting the cervical sympathetic nerve had no effect on the interscapular brown adipose tissue. It is suggested that the sympathetic supply to the interscapular brown adipose tissue is distributed by the upper thoracic spinal nerves.

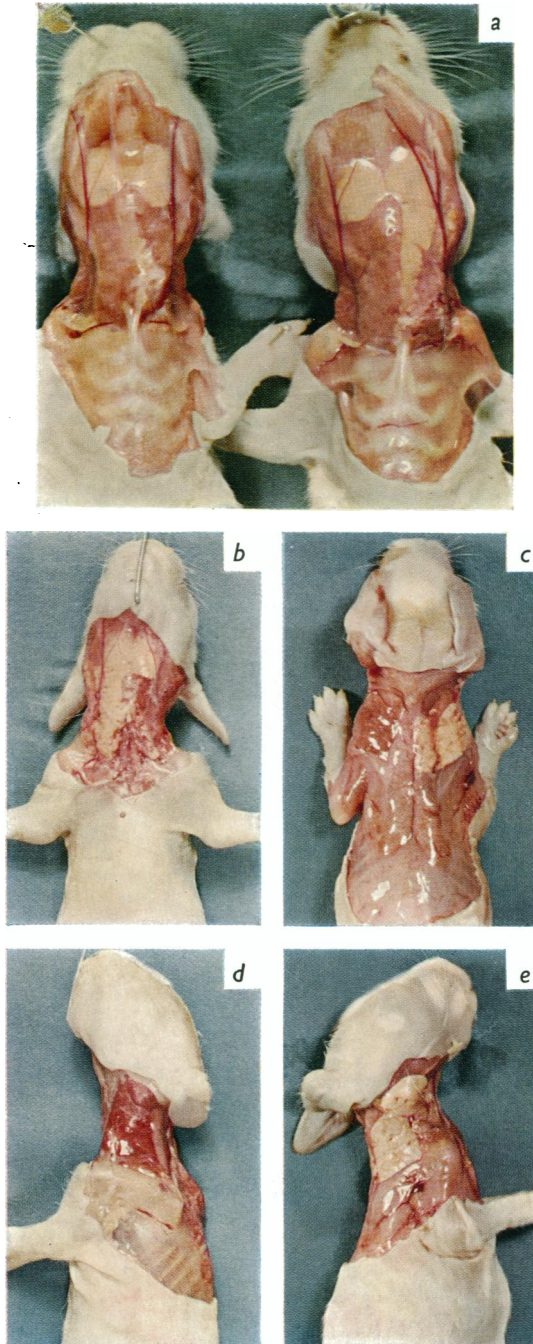
6. Stimulation of the cervical sympathetic nerve *in vivo* led to a reproducible rise in temperature (0.2–0.6° C, mean 0.31° C) of the cervical brown adipose tissue in 9 of 27 experiments. Evidence is reviewed which suggests that this was due to stimulation of heat production by the brown adipose tissue cells.

7. It is concluded that heat production by the new-born rabbit in response to cold exposure is mediated by the sympathetic nervous system.

We wish to thank Dr G. S. Dawes for his kind advice. We are grateful to the staff of the Nuffield Institute for their help, in particular to Mr H. Holt for his technical assistance and to Miss C. Haseler and Mrs J. Storms who prepared the histological sections. One of us (M. M. S.) held a Nuffield Foundation fellowship during this work.

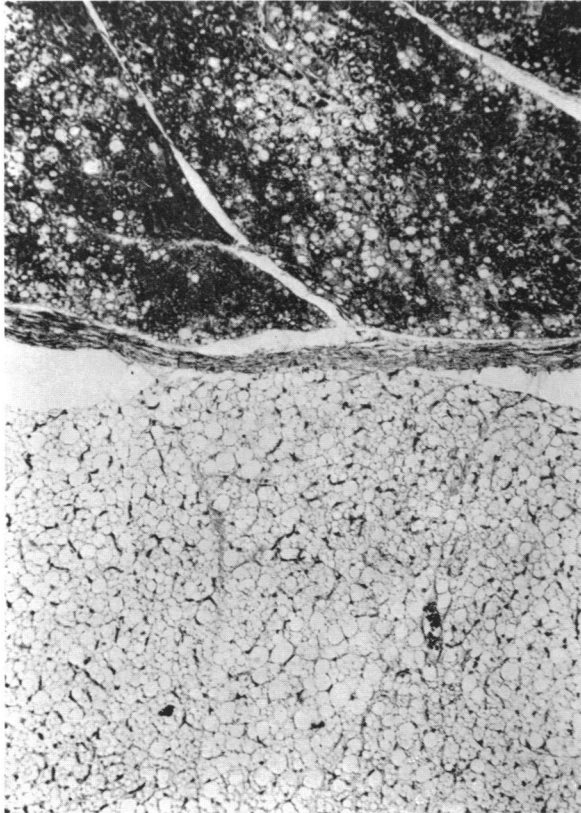
REFERENCES

- BALL, E. G. & JUNGAS, R. L. (1961). On the action of hormones which accelerate the rate of oxygen consumption and fatty acid release in rat adipose tissue *in vitro*. *Proc. nat. Acad. Sci., Wash.*, **47**, 932–941.
- BEZNÁK, A. B. L. & HASCH, Z. (1937). The effect of sympathectomy on the fatty deposit in connective tissue. *Quart. J. exp. Physiol.* **27**, 1–15.
- CLÉMENT, G. (1950). La mobilisation des glycérides de réserve chez le rat. *Arch. Sci. Physiol.* **4**, 13–29.



D. HULL AND M. M. SEGALL

(Facing p. 466)



- CORRELL, J. W. (1963). Adipose tissue: ability to respond to nerve stimulation *in vitro*. *Science*, **140**, 387-388.
- DAWKINS, M. J. R. & HULL, D. (1964). Brown adipose tissue and the response of new-born rabbits to cold. *J. Physiol.* **172**, 216-238.
- HAUSBERGER, F. (1934). Über die Innervation der Fettorgane. *Zschr. Mikr. anat. Forsch.* **36**, 231-266.
- HULL, D. & SEGALL, M. M. (1965*a*). The contribution of brown adipose tissue to heat production in the new-born rabbit. *J. Physiol.* **181**, 449-457.
- HULL, D. & SEGALL, M. M. (1965*b*). The effects of sympathetic denervation and stimulation on brown adipose tissue in the new-born rabbit. *J. Physiol.* **177**, 63-64*P*.
- MOORE, R. E. & UNDERWOOD, M. C. (1963). The thermogenic effects of noradrenaline in new-born and infant kittens and other small mammals. A possible hormonal mechanism in the control of heat production. *J. Physiol.* **168**, 290-317.
- NAPOLITANO, L. & FAWCETT, D. J. (1958). The fine structure of brown adipose tissue in the new-born mouse and rat. *J. biophys. biochem. Cytol.* **4**, 685-692.
- RIZACK, M. A. (1961). An epinephrine-sensitive lipolytic activity in adipose tissue. *J. biol. Chem.* **236**, 657-662.
- SHAPIRO, B. & WERTHEIMER, E. (1956). The metabolic activity of adipose tissue. A review. *Metabolism*, **5**, 79-86.
- SIDMAN, R. L. & FAWCETT, D. W. (1954). The effect of peripheral nerve section on some metabolic responses of brown adipose tissue in mice. *Anat. Rec.* **118**, 487-508.
- SIDMAN, R. L., PERKINS, M. & WEINER, N. (1962). Noradrenaline and adrenaline content of adipose tissues. *Nature, Lond.*, **193**, 36-37.

EXPLANATION OF PLATES

PLATE 1

a. The gross appearance of the cervical brown adipose tissue of two new-born rabbits after 48 hr fasting at a cool ambient temperature (30° C). Right: after section of the left cervical sympathetic nerve. Left: after ligation of the left common carotid artery. After nerve section the ipsilateral anterior lobe remained yellow, in contrast to the red-brown lobe on the other side. After arterial ligation there was no difference in the appearance of the two sides.

b-e. The gross appearance of the cervical and interscapular brown adipose tissue of a new-born rabbit after 48 hr fasting at a cool ambient temperature (30° C) following excision of the right stellate ganglion. The entire cervical brown adipose tissue on the operated side remained yellow, in contrast to the red-brown appearance on the other side. *b*. Front view: the right anterior cervical lobe is shown replete with fat. *c*. Back view: the right lateral cervical lobe is shown replete with fat. In addition, the replete cephalic end of the right interscapular pad can be distinguished from the remainder of the interscapular tissue by its yellow appearance. *d*. Left view: the depleted lateral and upper cervical lobes. *e*. Right view: the replete lateral and upper cervical lobes.

PLATE 2

The histological appearance of innervated and denervated cervical brown adipose tissue of a new-born rabbit after 48 hr fasting at a cool ambient temperature (30° C). The cells of the innervated tissue are largely depleted of fat vacuoles. By contrast, in the adjacent denervated lobe, the cells are still replete with fat.