



## What's New In General Surgery

### Management of Traumatic Retroperitoneal Hematoma

DAVID V. FELICIANO, M.D.

The management of retroperitoneal hematomas remains confusing to many surgeons because the available literature frequently groups patients with blunt and penetrating etiologies together. Because the underlying injuries and their treatment may differ considerably, the nonoperative or operative approach to the common hematomas is based on mechanism of injury coupled with hemodynamic status of the patient and extent of associated injuries. After blunt trauma, selected retroperitoneal hematomas in the lateral perirenal and pelvic areas do not require operation and should not be opened if discovered at operation. Midline, lateral paraduodenal, lateral pericolonic not associated with pelvic, and portal hematomas are opened after proximal vascular control has been obtained, if appropriate. Retrohepatic hematomas without obvious active hemorrhage are not opened. After penetrating trauma, most retroperitoneal hematomas are still opened. Exceptions include isolated lateral perirenal hematomas that have been carefully staged by CT and some lateral pericolonic hematomas. As with blunt trauma, retrohepatic hematomas without obvious active hemorrhage are not opened.

**W**HILE RETROPERITONEAL HEMATOMAS are not rare in hospitals caring for traumatized patients, controversies about appropriate management continue. One reason for this is the policy of many authors to draw conclusions from series combining patients with blunt and penetrating retroperitoneal

*From the Department of Surgery, Strong Memorial Hospital, and The University of Rochester School of Medicine and Dentistry, Rochester, New York*

injuries. This is inappropriate because the sources of hemorrhage and natural history of the hematoma differ considerably depending on the etiology. For example the morbidity and mortality from a retroperitoneal hematoma around a kidney contused by blunt trauma are considerably different from those caused by a gunshot wound to the renovascular structures. Another reason for controversy and confusion has been the advances in radiologic imaging that now allow for a more precise evaluation of injuries to retroperitoneal structures without the need for operation. The management of retroperitoneal hematomas has continued to evolve based on information gained from these newer diagnostic modalities. Finally retroperitoneal hematomas from blunt trauma usually demand multidisciplinary care.<sup>1</sup> Yet communication between the involved specialties, especially in the available literature, appears to be lacking. For example recent surgical papers concerned with the control of retroperitoneal hemorrhage from blunt pelvic fractures continue to suggest that bilateral ligation of the internal iliac arteries remains a viable therapeutic alternative. This will, of course, preclude precise pelvic arteriography and therapeutic embolization of

Address correspondence and reprint requests to David V. Feliciano, M.D., Department of Surgery, University of Rochester Medical Center, 601 Elmwood Avenue, Rochester, NY 14642.

Accepted for publication: September 25, 1989.

deep arterial bleeders by an interventional radiologist in the postoperative period if the bilateral ligation fails.

This review will focus on current diagnostic approaches to injuries in retroperitoneal structures that may cause hematomas and will differentiate between the therapy indicated for blunt *versus* penetrating etiologies of retroperitoneal hematomas.

### Definition

The retroperitoneal space lies posterior to the sac of the peritoneal cavity and contains completely or envelops anteriorly a number of visceral and vascular structures in the gastrointestinal, genitourinary, vascular, musculoskeletal, and nervous systems.<sup>2</sup> Injury to gastrointestinal structures such as the distal esophagus, the second, third, and fourth portions of the duodenum, the pancreas, the posterior parts of the ascending and descending colon and the flexures of the colon, and the rectum may produce retroperitoneal hematomas easy to ignore or miss at operation. Injury to genitourinary structures such as the kidneys, adrenal glands, ureters, and bladder may be obvious on preoperative radiologic screening even before a surrounding retroperitoneal hematoma is discovered at operation. Injury to vascular structures such as the abdominal aorta and inferior vena cava and their branches or retroperitoneal branches of the portal venous system may present with either a contained retroperitoneal hematoma or exsanguinating hemorrhage.<sup>3</sup> Finally injuries to musculoskeletal structures such as the psoas major, quadratus lumborum, and iliacus muscles, the diaphragm, and the vertebral bodies from penetrating wounds or the pelvic bones from blunt trauma are common causes of retroperitoneal hematomas.

### Incidence

The incidence of retroperitoneal hematomas based on etiology in three combined series since 1980 has been blunt—80%, 70%, 67% *versus* penetrating—20%, 30%, 33%.<sup>4-6</sup> In one oft-quoted series of 171 patients admitted with blunt trauma, 44% had a retroperitoneal hematoma documented at laparotomy (97%) or autopsy (3%).<sup>7</sup> Grieco and Perry classified their 80 patients with blunt trauma and a retroperitoneal hematoma into a perirenal group (45%), pelvic group (28.8%), and an “other” group (26.2%).<sup>4</sup> Selivanov et al.,<sup>5</sup> using the classification described at the San Francisco General Hospital, divided 57 patients with retroperitoneal hematomas from blunt trauma into a pelvic group (zone III, 70.2%), flank or lateral group (zone II, 22.8%), and a upper to mid-central group (zone I, 7%).

In patients with penetrating wounds, the incidence of retroperitoneal hematomas is unclear. In 1966 Steichen et al.<sup>8</sup> noted that 5.9% of patients undergoing laparotomy

for penetrating wounds of the abdomen had “hemorrhage in the retroperitoneal space.” At the time of that report, less selective criteria for performing laparotomies after penetrating abdominal trauma were in place. Also recent reports from urban trauma centers caring for large numbers of patients with gunshot wounds of the abdomen have documented a 25% incidence of abdominal vascular injuries at the time of laparotomy.<sup>9,10</sup> Presumably many or most of these patients with abdominal vascular injuries present with retroperitoneal hematomas rather than exsanguinating hemorrhage at the time of laparotomy.

### Mechanism of Injury

The mechanism of injury in patients suffering blunt trauma is best described as a moving or stationary victim striking or being struck by a moving or stationary object or surface. Any of these mechanisms will cause sudden contact with compression, deceleration with deformation, or both.<sup>11</sup> The magnitude of injuries that occur is related to the kinetic energy of the victim at the time of impact. Pelvic fractures result from contact with the inside of the car or femur. A pelvic retroperitoneal hematoma is caused by the loss of blood from sites of fractures, disruption of multiple veins in the posterior pelvis, and disruption of deep pelvic arteries, which are often distal branches from the internal iliac vessels. Perirenal hematomas result from either contact with the inside of the car or adjacent deformed or fractured ribs or from deceleration. Direct contact may lead to contusions, lacerations, polar avulsions, or ruptures, while deceleration may avulse the renal vein or its branches or disrupt the intima of the renal artery with secondary thrombosis. Blunt rupture of the second or third portion of the duodenum presenting as a periduodenal retroperitoneal hematoma is thought to be secondary to a direct blow with compression or shearing against the spine or a closed loop blowout from deceleration. In patients with midline retroperitoneal hematomas from blunt trauma, deceleration with avulsion of small branches from the aorta, inferior vena cava, superior mesenteric artery, or portal vein beneath the pancreas is the most common cause. Less often a midline transection of the pancreas over the spine caused by contact with the lower rim of the steering wheel is present.

The mechanisms of injury in patients suffering penetrating trauma include (1) contact of body parts with a knife; (2) contact of body parts with a missile, its fragments, or secondary missiles such as teeth or spicules of bone; or (3) cavitation as caused by high-velocity missiles. The magnitude of injuries that result depends on the structure and content of the organ that is hit by a knife or missile and on the kinetic energy of the missile at the time of contact or the size of its cavitation field. In civilian life the narrow blade used in most stabbings or the low-

velocity missile fired from a handgun causes a small entrance wound into the retroperitoneum. The previously mentioned tamponading effect of the retroperitoneum is lifesaving in many patients with retroperitoneal injuries from penetrating wounds. This is most noticeable in patients with penetrating wounds to the suprarenal or infrarenal aorta in which the pressure exerted by the retroperitoneal hematoma slows the rate of hemorrhage and allows for salvage rates of 35% and 45%, respectively, in modern trauma centers.<sup>12</sup>

**Classification**

Numerous classification systems of retroperitoneal hematomas now exist and make comparison of management techniques from different centers difficult. Some of the available classification systems are summarized in Table 1.<sup>3,6,13,14</sup>

**Diagnosis**

*Clinical*

The symptoms and signs of a retroperitoneal hematoma are most commonly a reflection of the organs injured in the retroperitoneum rather than of the hematoma itself. Pain in the anterior abdomen, flank, back, or pelvic area may be present, depending on the etiology. On examination signs of hypovolemic shock are usually present in patients with significant pelvic fractures or penetrating wounds to the aorta, inferior vena cava, or major branches. Because a Grey-Turner's sign is usually not present during the first day after injury, it is not helpful in the early diagnosis of a retroperitoneal hematoma. Laboratory findings such as anemia and hematuria from an associated renal contusion or injury to the bladder or male urethra is common when a significant pelvic fracture

has occurred. Hyperamylasemia, especially when it progressively increases during the first 24 to 48 hours after injury, strongly suggests the presence of injury to either the pancreas or duodenum.<sup>15</sup>

*Radiologic Approach—Blunt Trauma*

The radiologic approach to the patient with blunt trauma and a suspected retroperitoneal hematoma is based on the patient's condition and the surgeon's suspicion about which retroperitoneal organs may have been injured. A plain film of the abdomen in which there is obliteration of the psoas muscle shadow or displacement of gas-filled organs by a mass suggests the presence of a retroperitoneal hematoma.<sup>2</sup> This is more likely to be true if associated fractures to the pelvis, lumbar vertebrae, or lower ribs are present. The presence of air in the right upper abdomen outlining the lateral aspect of the duodenum (Fig. 1), coupled with obliteration of the upper psoas muscle border on the right, scoliosis of the lumbar spine to the left, or air in front of the first lumbar vertebra on a lateral x-ray of the abdomen all suggest retroperitoneal rupture of the duodenum under the hematoma.

In the stable patient with a history of a direct upper midline blow but no x-ray findings suggestive of duodenal rupture, it is worthwhile to insert a nasogastric tube and inject air into it. A repeat abdominal x-ray is then performed to see if retroperitoneal air is now present. More commonly water-soluble radiologic dye has been injected into the tube while the patient is lying on his or her right side. Any extravasation of dye on another abdominal x-ray documents the presence of a duodenal perforation. In recent years computerized tomography (CT) performed with a combination of ingested and intravenous contrast (enhanced CT) has been used to document the diagnosis instead of the studies mentioned above.

TABLE 1. Classification Systems of Retroperitoneal Hematomas

Shaftan, 1980*	Kudsk and Sheldon, 1982†	Henao and Aldrete, 1985‡	Feliciano et al., 1988§
Abdominal	Central-medial (zone 1)	Central	Midline supramesocolic (includes lesser sac)
Midline		Vascular	Midline inframesocolic
Flank	Flank (zone 2)	Peripancreatoduodenal	
Perirenal		Flank	Lateral perirenal, paraduodenal, and pericolonic
Pericolonic			
Pelvic	Pelvic (zone 3)	Pelvic	Pelvic
Anterior			
Posterior			
Unilateral			
Bilateral		Combined	Portal and retrohepatic

\* Shaftan GW. Retroperitoneal trauma. *Contemporary Surgery* 1980; 16:25-35.

† Kudsk KA, Sheldon GF. Retroperitoneal hematoma. In Blaisdell FW, Trunkey DD, eds. *Abdominal trauma*. New York: Thieme-Stratton, 1982: 279-93.

‡ Henao F, Aldrete JS. Retroperitoneal hematomas of traumatic origin. *Surg Gynecol Obstet* 1985; 161:106-16.

§ Modified from Feliciano DV, Burch JM, Graham JM. Abdominal vascular injury. In Mattox, KL, Moore EE, Feliciano DV, eds. *Trauma*. East Norwalk: Appleton & Lange, 1988. pp. 519-36.

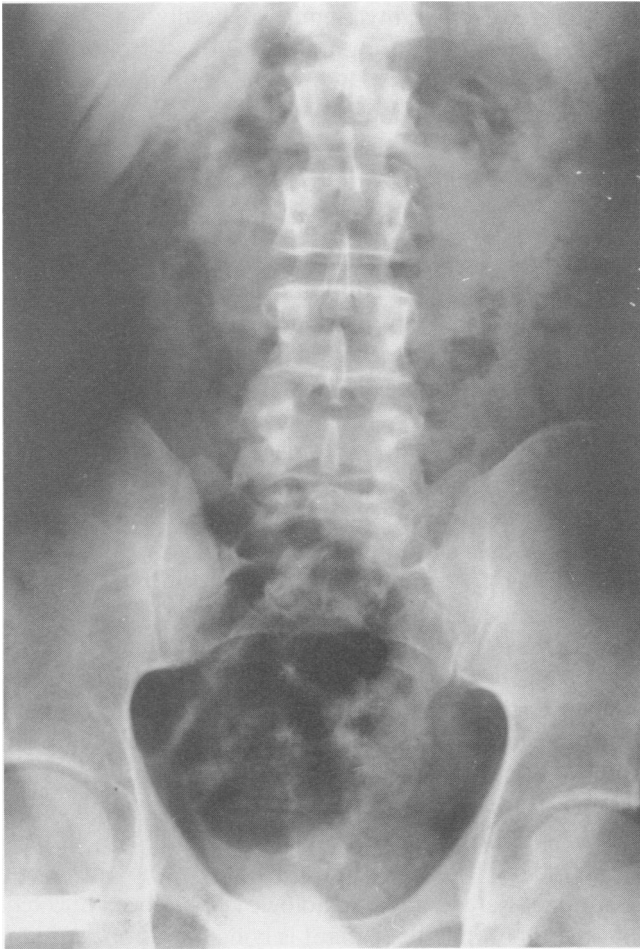

FIG. 1. Retroperitoneal air in right upper quadrant outlining C loop of the ruptured duodenum.

As previously mentioned, persistent or progressive hyperamylasemia after blunt upper-abdominal trauma in the absence of other indications for laparotomy mandates further radiologic studies. CT is an excellent technique to evaluate the pancreas, and Jeffrey et al.<sup>16</sup> have been able to distinguish between mild traumatic pancreatitis involving diffuse swelling of the gland and transection of the organ (Fig. 2). AN ERCP is useful when CT is not available or is equivocal, and there is a continuing concern about the presence of a pancreatic ductal injury in the mildly symptomatic patient.<sup>17-19</sup>

Hematuria in the stable patient who has sustained a direct blow to the flank has most commonly been evaluated by intravenous pyelography (IVP) in the past. A recent study has suggested that this examination is worthwhile only in patients with more than 30 red blood cells per high-power field, but it continues to be used liberally in most centers.<sup>20</sup> An IVP confirms the presence of two functioning kidneys and may document an injury in either a kidney or ureter. CT is preferred by many urologists as the next diagnostic step in a patient with significant hematuria and an abnormal IVP because the examination is highly sensitive and accurate<sup>21</sup> (Fig. 3). The presence of hematuria and nonvisualization of one kidney on an IVP has usually prompted a selective renal arteriogram to rule out the presence of thrombosis of a renal artery secondary to deceleration; however CT has been used with increasing frequency in recent years when this diagnosis is suspected. If a soft-tissue image of the kidney is present but there is no enhancement or only modest cortical enhancement from adrenal arteries when intravenous contrast is given, then renal arterial flow is absent. It has also

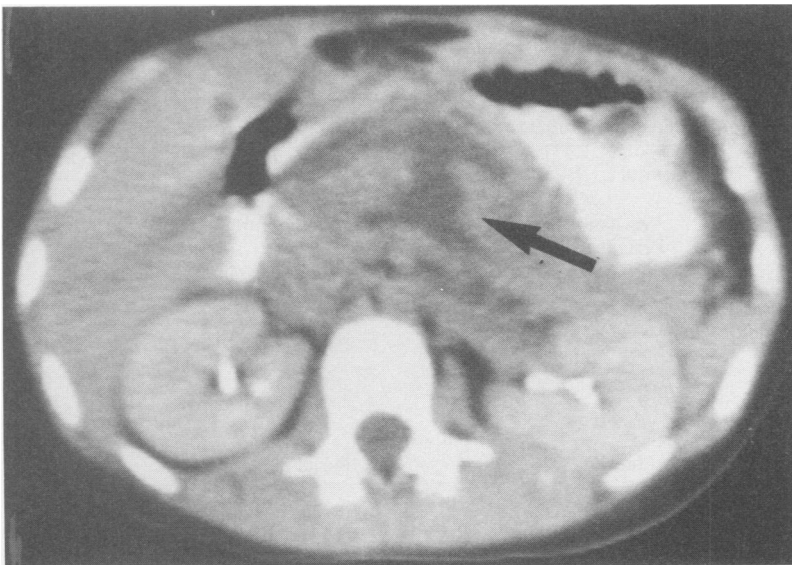
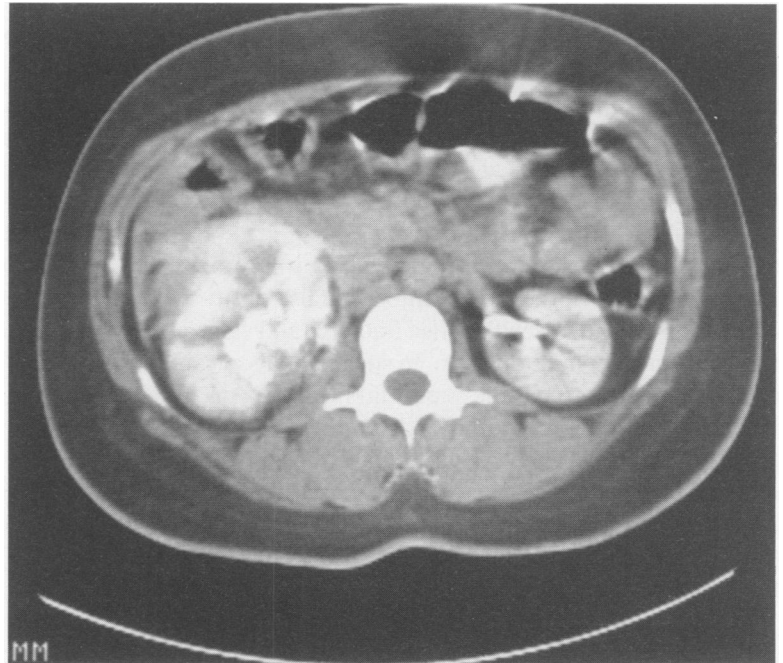


FIG. 2. Transection of the body of the pancreas over the spine on CT (From Feliciano DV. *In* Schwartz SI, Ellis H, eds. *Maingot's Abdominal Operations*, 9th ed. East Norwalk, CT: Appleton & Lange, 1989; publication pending. Reprinted with permission.)

FIG. 3. Right renal laceration on CT performed after abnormal IVP.



been suggested that the absence of hematuria in a patient with significant abdominal trauma strongly suggests the need for an IVP to determine if renal artery flow is intact.<sup>22</sup>

Should a pelvic fracture be present in a patient with hematuria, a retrograde cystogram is indicated to rule out a rupture of the bladder in an anterior retroperitoneal hematoma. This is preceded by a retrograde urethrogram in patients who cannot void, have a floating prostate gland, and blood at the urethral meatus. In the past, an intravenous pyelogram would then be used to complete the evaluation of the genitourinary system. CT is now used in place of an IVP in such a patient in many centers because both the kidneys and the pelvic fractures can be rapidly evaluated.<sup>23</sup>

In an occasional (2% to 3%) patient with a pelvic fracture, persistent need for transfusion, and no evidence of intra-abdominal visceral injury on DPL and CT, pelvic arteriography is performed. Deep pelvic bleeding from distal branches of the internal iliac artery such as the superior gluteal, internal pudendal, or obturator arteries can be diagnosed and treated (to be discussed).

#### *Radiologic Approach—Penetrating Trauma*

A plain film in a patient with a penetrating wound from a missile will localize the site of the missile and give some indication of which retroperitoneal visceral or vascular structure might be injured.

In the stable patient with hematuria after a penetrating wound near the kidney, an IVP is performed for the same

purposes as in the patient with blunt trauma and hematuria. The stable patient with hematuria and a transpelvic stab or gunshot wound will also undergo a preoperative retrograde cystogram to rule out perforation of the bladder in some centers.

One area of major concern in asymptomatic patients with stab wounds to the back is that an occult penetrating injury to the posterior surface of the duodenum, pancreas, ascending colon, descending colon, kidneys, or a vascular structure may have resulted. Hemorrhage can be tamponaded by the retroperitoneum with posterior stab wounds to any of these organs, and symptoms of organ penetration may be minimal for days or even weeks in certain individuals. One radiologic technique that has been used is administration of dye through nasogastric tube, enema, and IV before a CT scan to visualize all the retroperitoneal structures that might be injured by the stab wound. This so-called contrast-enhanced CT enema has proved to be accurate and has lowered the incidence of nontherapeutic laparotomies in centers in which it has been used.<sup>24</sup>

#### *Diagnostic Peritoneal Lavage—Blunt Trauma*

Diagnostic peritoneal lavage (DPL) as a complementary study to CT continues to be used to evaluate patients with blunt abdominal trauma and possible retroperitoneal hematomas.<sup>25</sup> Most commonly it has been used to rule out rapidly the presence of intraperitoneal injuries in patients with pelvic fractures. The incidence of such associated

injuries varies depending on the magnitude and type of the fracture. In Murr and Moore's series, the incidence was 16% overall and 40% in patients with Malgaigne fractures.<sup>26</sup> This latter figure is similar to the 36% reported for Malgaigne fractures in Peltier's review.<sup>27</sup> In a more recent review, Cryer et al.<sup>28</sup> noted a 45% incidence in patients with unstable, open-book, lateral compression, or vertical shear pelvic fractures.

The major problem with the standard infraumbilical technique has been the large number of false-positive examinations in patients with pelvic fractures and associated retroperitoneal hematomas.<sup>29-32</sup> In such patients, a careful open approach through the supraumbilical area or at the infraumbilical ring is recommended to avoid passing the lavage catheter through the anterior extension of a retroperitoneal hematoma or into the posterior retroperitoneal hematoma itself.<sup>1,33</sup> A tear in the posterior peritoneum will, of course, lead to a false-positive DPL in most patients.

In stable patients with pelvic fractures, CT would be the diagnostic test of choice rather than DPL in many modern trauma centers.<sup>23</sup> In unstable patients (not exsanguinating), many of whom will have a pneumatic antishock garment (PSAG) in place, the trauma center staffs at Denver General Hospital, the Mayo Clinic, and the University of Louisville will perform a supraumbilical DPL to rapidly determine the presence of intraperitoneal bleeding.<sup>1,34-36</sup> It is of interest that the DPL is performed in the operating room in Louisville.<sup>34</sup> A patient whose preliminary diagnostic peritoneal tap or lavage return is grossly bloody will then undergo emergent laparotomy to control presumed intraperitoneal hemorrhage. Pelvic fixation is also performed under this anesthetic, depending on the type of fracture, the hemodynamic status of the patient, and the progression of the pelvic retroperitoneal hematoma during the laparotomy. Continued progression of the hematoma or need for postlaparotomy transfusion would mandate pelvic arteriography with selective arterial embolization.<sup>1,34-36</sup>

A patient whose DPL is positive based on red blood cell count alone can undergo further studies or therapeutic maneuvers such as CT of the head, immediate pelvic fixation, or visceral arteriography. The Hermann Hospital in Houston has used visceral arteriography in reasonably stable patients with this DPL result to verify whether active visceral hemorrhage, which would mandate laparotomy, is occurring.<sup>37</sup> This is performed in association with standard pelvic arteriography and therapeutic embolization, as needed.

### Retroperitoneal Hematoma After Blunt Trauma

#### *Nonoperative Management of Selected Patients*

In patients with signs of significant intra-abdominal blood loss, overt peritonitis, or both after sustaining blunt

trauma, laparotomy is recommended. Other stable asymptomatic or mildly symptomatic patients will undergo general evaluation by the diagnostic studies previously discussed.<sup>16,20,21,24,31,32</sup> Many patients in this latter group may have documented intra-abdominal visceral injuries to the kidney, spleen, or liver, bony pelvic injuries, and associated or presumed retroperitoneal hematomas; however, laparotomy is not recommended.

#### *Patients with Perirenal Retroperitoneal Hematomas.*

The first group of patients in whom nonoperative management is usually chosen includes those with hematuria, limited renal injuries, and a perirenal retroperitoneal hematoma.<sup>38-41</sup> Approximately 95% of patients with blunt renal injuries fall in this group.<sup>42</sup> If radiologic evaluation with an IVP, nephrotomogram, ultrasound, CT, or renal arteriogram reveals only a renal contusion, there is uniform opinion that nonoperative management is indicated because all of these kidneys are normal on late follow-up.<sup>42,43</sup> The management of patients with more severe injuries such as superficial (cortical) lacerations, deep (medullary) lacerations, urinary extravasation, polar avulsion, or blunt rupture associated with a perirenal retroperitoneal hematoma remains controversial. While superficial lacerations are usually managed nonoperatively, persistent or late complications such as continuing hematuria or reduced parenchymal activity have been reported.<sup>42,43</sup> Cass et al.<sup>43</sup> noted that the delayed renal surgery rate has been 13% to 68% in the available literature during the past 20 years and was 53% in his own series when nonoperative management of the more severe degrees of renal injury was chosen. As a general rule, the patient with a deep (medullary) laceration, extensive urinary extravasation, polar avulsion with more than 20% of the kidney nonviable, rupture of the kidney, renovascular injury, and a perirenal retroperitoneal hematoma on preoperative radiologic screening should undergo renal exploration.<sup>21,41-43</sup>

*Patients with Pelvic Retroperitoneal Hematomas.* As previously noted pelvic retroperitoneal hematomas associated with pelvic fractures are caused by bleeding from a variety of sites, none of which is usually amenable to direct surgical control.<sup>44-46</sup> Hemorrhage from sites of fractures may be slowed or stopped by the application of a PASG<sup>1,47-50</sup> or early external skeletal fixation,<sup>51-53</sup> while venous hemorrhage from venous plexuses or smaller veins should be tamponaded by the intact retroperitoneum.<sup>1,48,54</sup> The rare patient with a deep pelvic arterial bleeder can be managed by therapeutic embolization.<sup>35-37,54-60</sup> Therefore stable patients or unstable (not exsanguinating) patients without evidence of intraperitoneal injuries on physical examination, DPL, arteriography, or CT can be managed nonoperatively when retroperitoneal hematomas from pelvic fractures are present.<sup>1,35-37,54</sup>

Exceptions to nonoperative management for pelvic

retroperitoneal hematomas include (1) patients with exsanguination secondary to the pelvic fractures or associated intra-abdominal injuries<sup>35,54</sup> (Fig. 4); (2) patients with rupture of the hematoma through open perineal wounds (open pelvic fractures)<sup>61-63</sup>; and (3) patients with known or suspected major vascular injuries within the retroperitoneal hematoma.<sup>64-67</sup> Rothenberger et al.<sup>66</sup> have suggested that hypotensive pedestrians with open pelvic fractures and a double break in the pelvic ring are at highest risk for major vascular injuries and should undergo early operation.

### Operative Management

Laparotomy is performed after blunt trauma in symptomatic patients and in asymptomatic or mildly symptomatic patients with DPL or radiologic evidence of major visceral or vascular injuries. Certain retroperitoneal hematomas discovered at laparotomy for blunt trauma should always be opened (Table 2). Other hematomas, such as the selected perirenal and pelvic hematomas previously discussed, should not be opened when the appearance at operation conforms to the preoperative clinical and radiologic evaluation (Fig. 5). Should the hematoma in either of these groups rapidly expand, become pulsatile, or rupture, it is usually opened; however not all surgeons would agree with this approach.

TABLE 2. Operative Management of Retroperitoneal Hematomas After Blunt Abdominal Trauma\*

Location	Approach at Operation
Midline supramesocolic	Open hematoma†
Midline inframesocolic	Open hematoma†
Lateral	
Perirenal	Do not open if preoperative IVP, ultrasound, or CT reveals reasonably intact kidney
Paraduodenal (bile staining, crepitus, etc.)	Open hematoma to rule out duodenal perforation
Pericolonic	Open hematoma to rule out colonic injury, if not associated with pelvic hematoma
Pelvic	Do not open if pelvic fracture present, rate of expansion is slow, arterial pulsations intact in groins, and urethrogram and cystogram are normal
Portal and retrohepatic	
Portal	Open hematoma to rule out injury to common bile duct or portal vein†
Retrohepatic	Controversial. Do not open in stable patient if no obvious active hemorrhage after hepatic injury treated

\* Modified from Feliciano DV. Abdominal trauma. In: Schwartz SI, Ellis H, eds. *Maingot's Abdominal Operations*. East Norwalk: Appleton & Lange, 1989 (publication pending).

† After obtaining proximal and, if possible, distal vascular control.

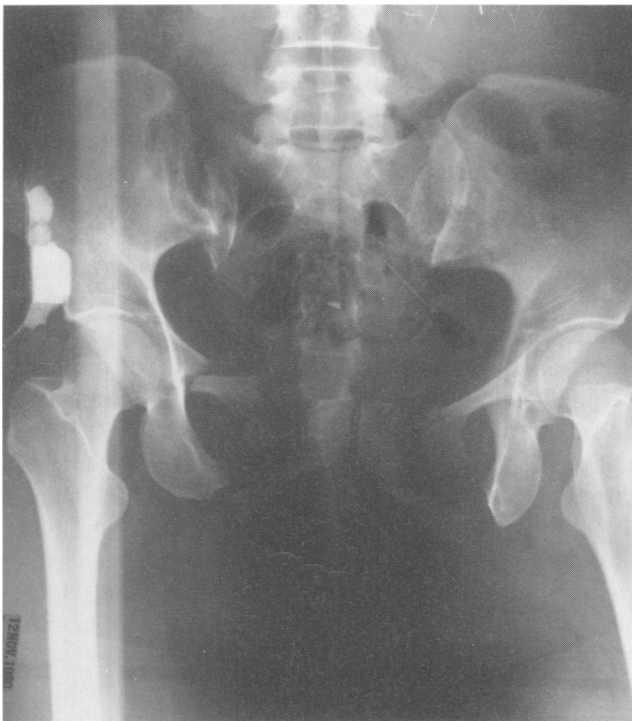

FIG. 4. Patient with multiple pelvic fractures after being run over by a bus required immediate operation because of exsanguinating hemorrhage.

**Midline Supramesocolic Retroperitoneal Hematoma.** This hematoma should be opened after obtaining proximal and, if possible, distal vascular control because a major vascular injury may be present.<sup>68-75</sup> While a major blunt injury to the suprarenal aorta (SRA) is extraordinarily rare,<sup>73,74</sup> avulsion of the superior mesenteric artery (SMA) from its origin has been reported from several trauma centers.<sup>68-72</sup> More commonly avulsion of small posterior branches of the SRA is present. Proximal control of the SRA and its branches is obtained with a medial mobilization of all left-sided intra-abdominal viscera, including the left colon, pancreas, spleen, left kidney, and fundus of the stomach (Fig. 6). The aorta is most easily exposed after this mobilization by making a left radial phrenotomy incision and dissecting the distal thoracic aorta or abdominal aorta in the hiatus superior to the celiac nerve plexus and surrounding lymphatics.<sup>3</sup> An alternative approach is to open the lesser omentum, pull the esophagus to the left, and come down directly on the aorta just inferior to its hiatus.<sup>76</sup> An aortic clamp is then applied to the supraceliac aorta before the supramesocolic retroperitoneal hematoma is opened. Dissection proceeds distally until the SRA, origin of the SMA, and origin of the left renal artery are inspected. If avulsion of the SMA is found, back-bleeding from the avulsed end can be con-

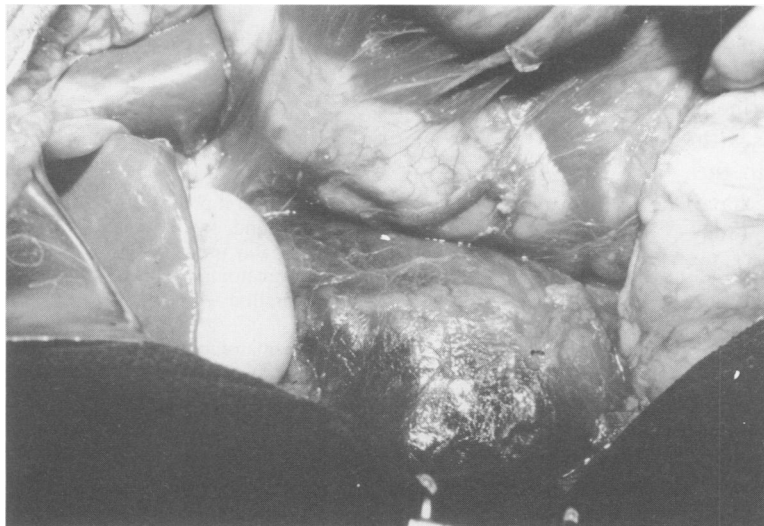


FIG. 5. Right perirenal hematoma was not opened at laparotomy after preoperative radiologic screening revealed that kidney was reasonably intact.

trolled by application of a vascular clamp or insertion of a Fogarty balloon catheter into the orifice. Options for repair of blunt avulsion of the SMA include reimplantation into the aorta, ligation with dependence on distal collateral flow, or bypass grafting from a more distal site on the abdominal aorta to the distal end of the SMA.<sup>68</sup>

A small supramesocolic hematoma or a retroperitoneal hematoma at the base of the transverse mesocolon may be the sole external manifestation of a blunt thrombosis of the renal artery secondary to an intimal tear. The decision to attempt revascularization depends primarily on the length of time elapsed since occlusion was thought to occur. In one review there was an 80% chance of restoring

some renal function after 12 hours of occlusion, but this decreased to 57% if the occlusion had been present for 18 hours.<sup>77</sup> Some surgeons have chosen to revascularize the ischemic kidney only when other intra-abdominal injuries mandate laparotomy and less than 12 hours have elapsed since injury.<sup>78</sup>

Blunt venous injuries that may cause a supramesocolic hematoma include avulsion of the left renal vein or of small peripancreatic branches of the portal vein. Avulsion of the left renal vein has most commonly occurred after a severe direct blow to the epigastrium. As proximal control would not ordinarily be obtained because of the rarity of this condition, control of hemorrhage may be difficult after the retroperitoneal hematoma is opened. Lateral venorrhaphy is performed if a partial avulsion is present, although ligation of the vein near the midline (with or without nephrectomy) may be required. Avulsed peripancreatic veins are ligated, and the pancreas is drained depending on the magnitude of the capsular injury.

A midline supramesocolic retroperitoneal hematoma in the lesser sac may contain a transected pancreas rather than a vascular injury. This injury has been missed on numerous occasions because of reluctance to mobilize the pancreas, open the hematoma under the thin mesothelial capsule of the pancreas, evacuate the clot, and visualize the transection<sup>79</sup> (Figs. 7 and 8). When present blunt transection is often to the right of the midline and much closer to the head of the pancreas than is commonly illustrated in textbooks. Surgical options, once a pancreatic transection has been confirmed, include distal pancreatectomy with or without splenectomy or a Roux-en-Y distal pancreateojejunostomy.<sup>79</sup>

*Midline Inframesocolic Retroperitoneal Hematoma.* Avulsion of posterior lumbar branches of the infrarenal abdominal aorta or inferior vena cava accounts for most hematomas in this location. Active hemorrhage is rare,

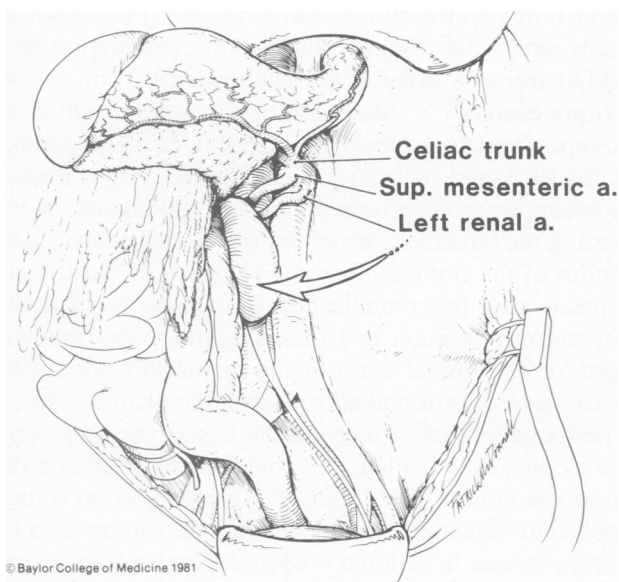


FIG. 6. Medial rotation of all left-sided intra-abdominal viscera allows visualization of the entire abdominal aorta, including the hiatal or diaphragmatic, suprarenal or visceral, and infrarenal portions.



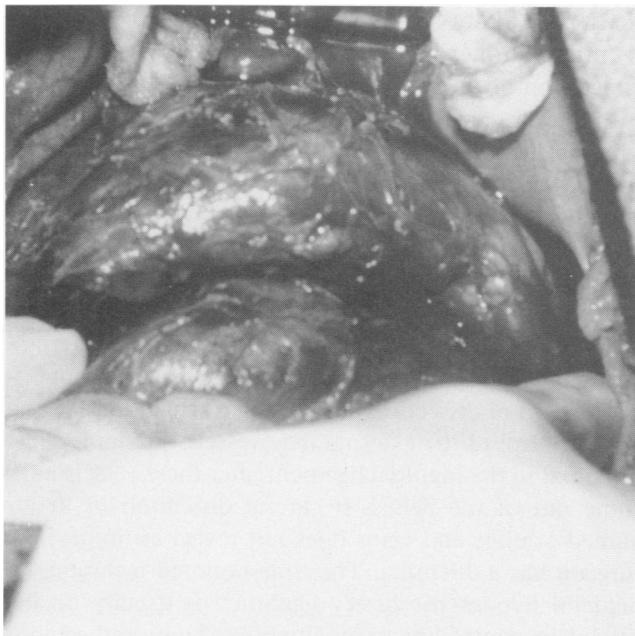


FIG. 7. Peripancreatic hematoma after blunt trauma (From Feliciano DV. In Schwartz SI, Ellis H, eds. *Maingot's Abdominal Operations*, ninth edition. East Norwalk, CT: Appleton & Lange, 1989; publication pending. Reprinted with permission.)

but exploration is mandatory to verify that a lumbar artery is not bleeding. The infrarenal abdominal aorta is exposed inferior to the base of the mesocolon to obtain proximal

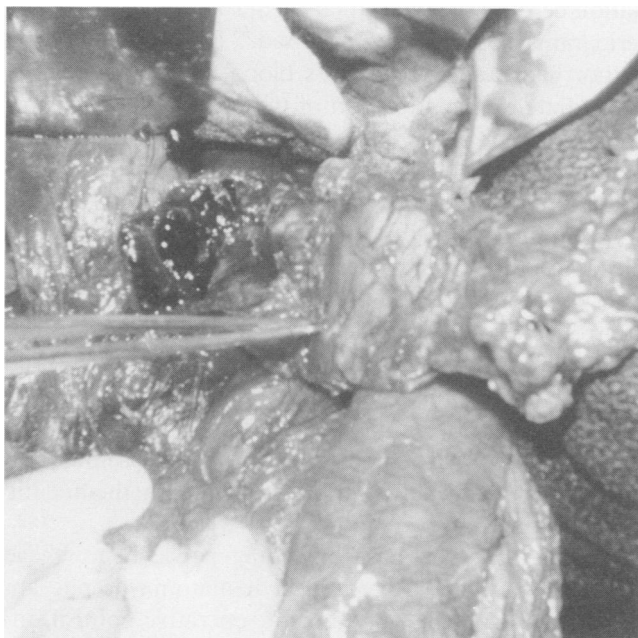


FIG. 8. Transection of the pancreas discovered when the hematoma seen in Figure 7 was opened. (From Feliciano DV. In Schwartz SI, Ellis H, eds. *Maingot's Abdominal Operations*, 9th ed. East Norwalk, CT: Appleton & Lange, 1989; publication pending. Reprinted with permission.)

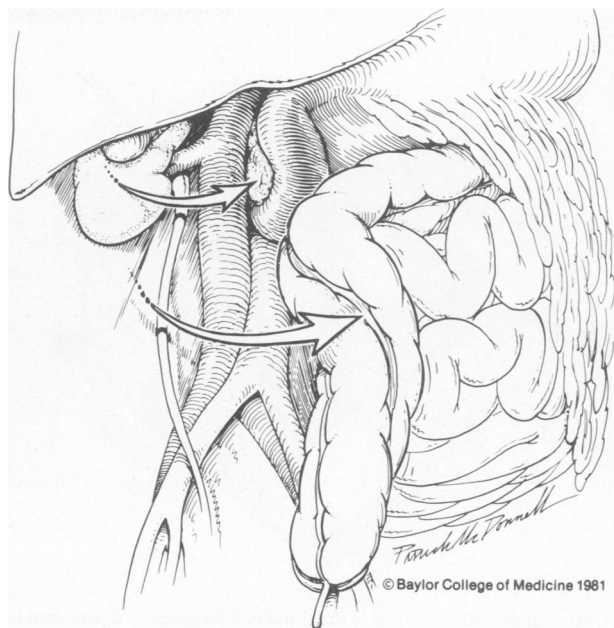


FIG. 9. Medial rotation of all right-sided intra-abdominal viscera except the right kidney allows visualization of the entire infrahepatic inferior vena cava.

control. The inferior vena cava may be exposed in this fashion also; however medial mobilization of all right-sided intra-abdominal viscera except the right kidney along with a Kocher maneuver will allow visualization of the entire infrahepatic inferior vena cava (Fig. 9).

**Lateral Perirenal Retroperitoneal Hematoma.** As previously noted exploration is favored by many urologists if preoperative radiologic staging indicates that a more severe degree of renal injury is present underneath the hematoma or if rapid expansion, a pulsatile nature, or free rupture of the hematoma is present.<sup>41-43,80,81</sup> A perirenal retroperitoneal hematoma is opened only after proximal renovascular control has been obtained at the midline for the left-sided vessels or at the midline and after a Kocher maneuver for the right-sided vessels<sup>81</sup> (Fig. 10).

On rare occasions a retroperitoneal hematoma in a location more superior to that of a standard perirenal hematoma may contain an avulsed right adrenal vein. This hematoma should also be opened if this injury is suspected, and the inferior vena cava should be repaired with 5-0 or 6-0 polypropylene sutures.

**Lateral Paraduodenal Retroperitoneal Hematoma.** Because of concern about the presence of a perforation or blowout of the second or third portion of the duodenum under a lateral paraduodenal retroperitoneal hematoma, this hematoma should be opened. In many patients palpable crepitus or visible bile staining under the hematoma will make the diagnosis obvious before the hematoma is opened. A small perforation is repaired in two layers in

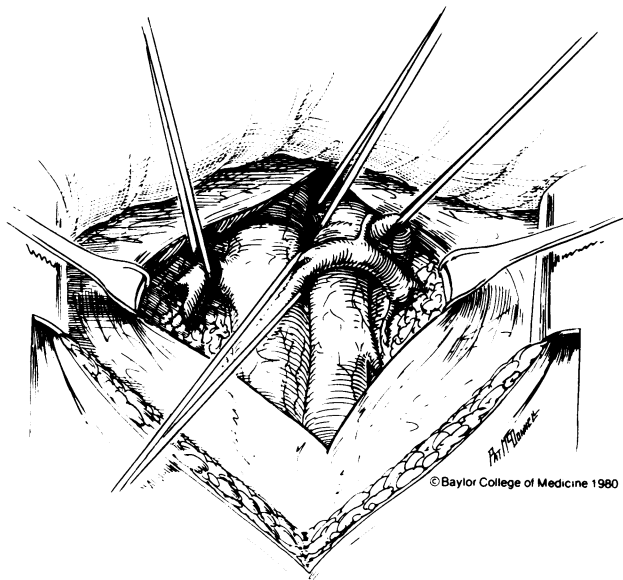


FIG. 10. Renovascular control is obtained before opening a perirenal hematoma.

a transverse direction, while more extensive blowouts or near transections are treated by debridement and an end-to-end anastomosis, Roux-en-Y (side) duodenojejunostomy, or conversion to a Roux-en-Y (proximal end) duodenojejunostomy with stapling or overviewing of the distal end of the duodenum.<sup>82,83</sup> Protective proximal diversion or decompression of the duodenal repair may be obtained by technical adjuncts such as duodenal diverticulization, pyloric exclusion with gastrojejunostomy, or insertion of triple tubes.<sup>84-87</sup>

**Lateral Pericolonic Retroperitoneal Hematoma.** Pelvic retroperitoneal hematomas frequently extend and involve the posterior aspect of the ascending and descending colons and gutters outside these structures. A pericolonic hematoma that is clearly an extension of a pelvic retroperitoneal hematoma is ordinarily not opened if the colon itself shows no signs of a direct injury. A completely separate pericolonic hematoma is more suggestive of direct blunt trauma to the colon, an admittedly rare injury, and should be opened to verify integrity of the colonic wall.<sup>88</sup>

**Pelvic Retroperitoneal Hematoma.** This blunt hematoma discovered at laparotomy (*i.e.*, was not an indication for laparotomy) is not opened in the presence of (1) pelvic fracture; (2) slow rate of expansion during laparotomy; (3) intact arterial pulsations in the groin; and (4) normal preoperative urethrogram and cystogram. Therefore exploration is indicated when one of the following is present: (1) ruptured hematoma (either into peritoneal cavity or perineal wound) or pulsatile (suggesting the presence of an arterial injury); (2) rapidly expanding hematoma with no other source of exsanguination (major vascular injury likely; no time for transfer to arteriography suite); (3) lack

of arterial pulsation in a groin (arterial injury present); or (4) intraperitoneal rupture of the bladder or rupture or transection of the male urethra.

In the presence of a ruptured, pulsatile, or rapidly expanding hematoma, proximal control of the infrarenal abdominal aorta and inferior vena cava should be obtained. The small bowel is pulled to the right, the sigmoid colon to the left, and the midline retroperitoneum is opened proximal to the sacral promontory. Vascular looping of these structures is not necessary in young trauma patients because the placement of an aortic cross-clamp or caval spongesticks is relatively easy once a modest amount of dissection has been performed. Distal vascular control of the external iliac vessels is obtained just proximal to the inguinal ligament after these vessels have come out of the pelvis. If careful dissection of major named arteries and veins does not reveal an injury, the surgeon has a dilemma. The time-honored technique of bilateral hypogastric artery ligation<sup>89</sup> is usually unsuccessful in controlling exsanguinating bony and venous hemorrhage directly associated with the pelvic fractures and is not selective enough to control the uncommon deep pelvic arterial bleeders.<sup>1,35,36,46,54,90-92</sup>

There are several options for the surgeon at this point. If the continuing hemorrhage appears to be venous or bony in origin, the pelvis is packed tightly with nonopaque gauze and the midline incision rapidly is closed. A towel clip closure of the skin only, which has been used in selected distended, shocky, or packed patients after abdominal trauma in recent years, is not appropriate in this situation because the interpretation of subsequent pelvic arteriograms would be compromised.<sup>93</sup> If the packing slows hemorrhage and the patient's blood pressure stabilizes, immediate external fixation of the pelvic fractures is indicated. When rapid continuing hemorrhage from the depths of the pelvis appears to be arterial in origin and cannot be controlled by packing, intraoperative arteriography through the hypogastric arteries is indicated. A bleeding point from a distal branch of one hypogastric artery demonstrated on the operative arteriogram can be controlled by proximal ligation and the passage of a Fogarty balloon catheter<sup>94,95</sup> into the offending vessel or by intraoperative embolization performed by the surgeon.<sup>96</sup> Finally a patient with only modest control of hemorrhage or expansion of the hematoma during packing should undergo immediate pelvic arteriography with therapeutic embolization.

The patient who has continuing pelvic hemorrhage from a ruptured retroperitoneal hematoma despite application of a PASG, attempts at operative control, insertion of pelvic packs, application of an external fixator, or attempted therapeutic embolization is theoretically a candidate for hemipelvectomy as a lifesaving maneuver.<sup>1,54,96</sup> In truth, this procedure has essentially been re-

served for patients whose original injury mandates that it be done.<sup>97,98</sup>

Thrombosis of the common or external iliac artery is a rare manifestation of crushing pelvic injuries.<sup>67,99</sup> Failure to recognize or treat this problem will result in a lower extremity amputation rate of at least 50%.<sup>100</sup> If profound hypovolemic shock, disruption of arterial collaterals by extensive soft-tissue injuries, and use of the PASG are also present, essentially all patients will require a major amputation of the ipsilateral lower extremity.<sup>67</sup> Options for repair include interposition grafting in the pelvic hematoma, bypass grafting (iliofemoral) around the point of occlusion, or insertion of an extra-anatomic femoro-femoral bypass using an 8-mm externally supported PTFE prosthesis.<sup>3</sup>

While extraperitoneal rupture of a bladder containing sterile urine is usually managed nonoperatively, intraperitoneal rupture mandates laparotomy. The anterior wall of the bladder is exposed through any extension of the pelvic retroperitoneal hematoma and is opened to expose the site of rupture.<sup>42</sup> A double layer closure of the intraperitoneal site of rupture with absorbable sutures is performed. This is coupled with seven to ten days of drainage through a cystostomy tube placed in the anterior wall of the bladder and will usually lead to a satisfactory repair.

Posterior rupture of the male urethra associated with a pelvic fracture is most commonly treated in a preliminary fashion by operative insertion of a suprapubic cystostomy tube that remains in place for 3 months.<sup>101</sup> At that time dilatation of a stricture or formal excision of the strictured area with reanastomosis can be performed with excellent results.

*Portal and Retrohepatic Retroperitoneal Hematomas.* A hematoma in the area of the porta hepatis should be opened because injury to either the common bile duct, common hepatic duct, or portal vein may be present. Blunt injuries to the extrahepatic biliary ductal system are thought to be due to sudden upward motion of the liver with secondary avulsion at the fixed points of the duct, specifically just above the head of the pancreas and at the bifurcation of the hepatic duct.<sup>102-104</sup> If this injury is not diagnosed, the chronic biliary leak will lead to jaundice, biliary ascites, inanition, and, eventually, death. A partial avulsion of a biliary duct may be repaired in a primary fashion, with the role of stents still controversial.<sup>103,105</sup> Complete transections from avulsing trauma are best repaired with a bilioenteric anastomosis using a Roux-Y limb.<sup>104,105</sup>

Blunt injuries to the portal vein are rare and most commonly represent avulsions of branches from the wall. The presence of a dark (nonbilious) hematoma in the porta should prompt the application of a proximal vascular clamp (Pringle maneuver) to all structures in the hepa-

toduodenal ligament before the hematoma is opened.<sup>106</sup> Repair of the injured portal vein is preferably accomplished by lateral venorrhaphy in a transverse direction using 5-0 or 6-0 polypropylene sutures; however even such simple repairs may be thrombosed on postoperative angiograms or ultrasound examinations.<sup>107</sup> More complex repairs such as end-to-end anastomoses, portacaval shunting, and venous shunts have been used with success on occasion, as has ligation.<sup>108-110</sup> If ligation is necessary, splanchnic hypervolemia will lead to a several-day period of peripheral hypovolemia. Stone and associates<sup>110</sup> have emphasized the need for vigorous fluid resuscitation in the early postoperative period in these patients.

A retrohepatic retroperitoneal hematoma should not be disturbed if no active hemorrhage occurs once an overlying hepatic injury is treated.<sup>93</sup> If moderate bleeding from the area of the hematoma occurs with manipulation of the overlying lobe and multiple intra-abdominal injuries are present, the insertion of perihepatic packs for a 24-to-48-hour period may be more efficacious than originally thought.<sup>111</sup> Exsanguinating hemorrhage from the area of the hematoma that increases with manipulation of the overlying hepatic lobe strongly suggests blunt injury to the hepatic veins or retrohepatic vena cava. Partial vascular control may be attained by insertion of a transcardiac atriocaval shunt using either a #36 chest tube or #8 endotracheal tube and application of a Pringle maneuver before attempting venous repair.<sup>112,113</sup>

### **Retroperitoneal Hematoma After Penetrating Trauma**

#### *Nonoperative Management of Selected Patients*

In patients with signs of significant intra-abdominal blood loss, overt peritonitis, significant evisceration, hematemesis, or proctorrhagia after sustaining penetrating trauma, laparotomy is recommended. Other stable asymptomatic or mildly symptomatic patients who have suffered stab wounds and even gunshot wounds with peritoneal penetration now undergo a variety of evaluations to avoid an unnecessary laparotomy. For example patients with anterior abdominal or flank stab wounds have been safely screened with either DPL or a period of observation in many trauma centers.<sup>114,115</sup> Similarly observation alone has been very successful in avoiding unnecessary laparotomy for patients with stab wounds and gunshot wounds of the back.<sup>116</sup> CT has been used to avoid laparotomy in patients with stab wounds or gunshot wounds to the flank or back, hematuria, and a known renal injury.<sup>81</sup> Finally the previously described contrast-enhanced CT enema has been used to screen patients with stab wounds or gunshot wounds of the pelvis or back.<sup>24</sup> All of these techniques are extremely accurate and, hence, successful in avoiding unnecessary laparotomies in patients who do not have gastrointestinal perforation, vascular perforation, con-

tinuing hemorrhage from solid organs, or have only limited renal injuries. Many of these patients have flank or retroperitoneal hematomas that will never be explored.

### Operative Management

The aphorism that all retroperitoneal hematomas associated with penetrating wounds must be opened is no longer completely true. Certain retroperitoneal hematomas discovered at laparotomy for penetrating trauma should still always be opened, but there is debate about some others, much as in patients with retroperitoneal hematomas from blunt trauma (Table 3). A comprehensive description of all the available repairs for vascular injuries in retroperitoneal hematomas associated with penetrating wounds is beyond the scope of this report, and the reader is referred to available publications.<sup>3,106,117</sup>

**Midline Supramesocolic Retroperitoneal Hematoma.** This hematoma should be opened after obtaining proximal and, if possible, distal vascular control. The left-sided medial mobilization maneuver and left phrenotomy at the aortic hiatus allow clamping of the supraceliac aorta under direct vision before opening the hematoma (Fig. 6). Dissection then proceeds distally until the surgeon determines if the injury is to the SRA, celiac axis, proximal SMA, or proximal renal artery.<sup>3,117</sup> Exposure for distal vascular control of an injury to the SRA is improved by ligation and division of the celiac axis. Options for repair

of the SRA include lateral aortorrhaphy, patch aortoplasty, resection with end-to-end anastomosis, or resection with interposition grafting with a 12-mm or 14-mm Dacron or PTFE prosthesis. Survival after penetrating wounds of the SRA is 36%, as previously noted, with the combination of injuries to the SRA and inferior vena cava yielding a 100% mortality rate in the recent review from the Ben Taub General Hospital.<sup>12</sup>

Proximal vascular control for a penetrating injury to the SMA is obtained through the lateral exposure previously described. Options for repair include lateral arteriorrhaphy, reimplantation, and bypass grafting, remembering the previous suggestion to place the proximal anastomosis of the bypass graft on the distal abdominal aorta away from the pancreas. Survival after wounds of the SMA is 58%; however, this decreases to 22% when any form of repair more complex than lateral arteriorrhaphy is necessary.<sup>68</sup>

Wounds of the proximal left renal artery are easily exposed by the left medial mobilization maneuver. On the right a midline inframesocolic approach with mobilization of the overlying left renal vein allows proximal clamping. Options for repair are discussed in the section on lateral perirenal retroperitoneal hematoma.

A large hematoma at the base of the transverse mesocolon may contain an injury to the superior mesenteric vein. On rare occasions penetrating injuries to this vessel beneath the pancreas may require division of the gland. A significant perforation or transection can be managed by reanastomosis, ligation and saphenous vein grafting to the portal vein, or ligation alone. As with ligation of the portal vein, vigorous infusion of fluids in the early postoperative period is necessary to reverse peripheral hypovolemia.<sup>110</sup> The survival rate after injuries to the superior mesenteric vein is approximately 72%.<sup>3</sup>

**Midline Inframesocolic Retroperitoneal Hematoma.** Proximal vascular control of the infrarenal abdominal aorta is obtained as previously described, and the repairs used are the same as for the SRA. The survival rate after wounds of the infrarenal aorta is 45%.<sup>117</sup>

Exposure of the infrahepatic inferior vena cava is most complete after the right medial mobilization and Kocher maneuvers illustrated in Figure 9. Vascular control is obtained by application of a partial occlusion clamp, compression with spongosticks proximal and distal to the perforation, or complete cross-clamping around the perforation. Hypotension associated with the latter maneuver may be partially alleviated by the simultaneous application of an infrarenal aortic cross-clamp. Options for repair include lateral venorrhaphy, patch cavoplasty with PTFE, end-to-end anastomosis, or interposition grafting with an externally supported PTFE prosthesis. The survival rate after penetrating wounds of the infrarenal inferior vena cava is 83%.<sup>118</sup> This decreases to 36% with injury to the

TABLE 3. Operative Management of Retroperitoneal Hematomas After Penetrating Abdominal Trauma\*

Location	Approach at Operation
Midline supramesocolic	Open hematoma†
Midline inframesocolic	Open hematoma†
Lateral	
Perirenal	Open hematoma†, unless preoperative CT allows for careful staging of renal parenchymal injury
Paraduodenal	Open hematoma†
Pericolonic	Controversial. No major structures located here, but steady bleeding from lumbar vessels or muscular branches has been a cause of reoperation
Pelvic	Open hematoma†
Portal and retrohepatic	Open hematoma†
Portal	
Retrohepatic	Controversial. Do not open in stable patient if no obvious active hemorrhage after hepatic injury treated

\* Modified from Feliciano DV. Abdominal trauma. In Schwartz SI, Ellis H, eds. *Maingot's Abdominal Operations*. East Norwalk, CT: Appleton & Lange, 1989 (publication pending).

† After obtaining proximal and, if possible, distal vascular control.

retrohepatic inferior vena cava, 53% with the suprarenal inferior vena cava, 49% at the level of the renal veins, and 49% at the confluence of the common iliac veins.<sup>118</sup>

*Lateral Perirenal Retroperitoneal Hematoma.* This should be opened unless preoperative staging by CT documents that a limited renal injury is present.<sup>42,81</sup> Proximal vascular control at the midline is mandatory before the hematoma and kidney are manipulated.<sup>81</sup>

Severely injured kidneys or renal arteries are treated by nephrectomy whenever the patient is hypotensive, has multiple injuries, and the contralateral kidney has a normal appearance on a preoperative or intraoperative IVP. Injuries of the renal vein are treated by lateral venorrhaphy or ligation, as previously noted.

*Lateral Paraduodenal Retroperitoneal Hematoma.* This hematoma is opened to rule out a perforating injury to the retroperitoneal duodenum, inferior vena cava, or right renal artery. A massive hematoma in this location strongly suggests injury to either the inferior vena cava or right renal artery and is approached by preliminary mobilization of the ascending colon and an extensive Kocher maneuver to expose either vessel. Techniques for repair of the injured duodenum, inferior vena cava, or right renal artery have been discussed previously.

*Lateral Pericolonic Retroperitoneal Hematomas.* While there are no viscera or major vascular structures here, exploration may be warranted to rule out occult retroperitoneal hemorrhage from a lumbar artery or other muscular branch. The insertion of small right-angle retractors into the tract of a missile through the retroperitoneal muscle should allow for selective clipping or ligation of any bleeding vessel.

*Lateral Pelvic Retroperitoneal Hematoma.* This hematoma should be opened after obtaining proximal and distal vascular control of the iliac vessels as previously described. An injury to the right common iliac vein may require division of the overlying right common iliac artery and mobilization of the aortic bifurcation to the left for complete exposure.<sup>119</sup> The internal iliac artery is best visualized by passing umbilical tapes or vessel loops around the common and external iliac arteries on one side of the pelvis and lifting them simultaneously. Either internal iliac artery may be ligated and divided to allow for better exposure of an injury to the underlying internal iliac vein.

The iliac arteries can be repaired with lateral arteriorrhaphy, transposition of the ipsilateral internal iliac artery, resection with end-to-end anastomosis, or interposition grafting with a saphenous vein or PTFE prosthesis. Extensive enteric or fecal contamination in the area of a major arterial injury should prompt proximal and distal ligation, ipsilateral four-compartment fasciotomy below the knee, and consideration of an extra-anatomic crossover femerofemoral graft.<sup>3</sup> Injuries to the iliac veins are treated with lateral venorrhaphy or ligation.

### *Portal and Retrohepatic Retroperitoneal Hematoma*

The approach to these hematomas is the same as that previously described for the same hematomas secondary to a blunt injury. A Pringle maneuver is applied and careful dissection is performed to precisely define which structures in the porta hepatis have been injured. Back-bleeding may be controlled by having an assistant compress all three structures with a forceps right next to the liver. Repair of the perforated portal vein is accomplished as described previously. Should a penetrating wound in the hepatoduodenal ligament injure the hepatic artery, options for treatment include lateral arteriorrhaphy and other such procedures; however ligation is well tolerated if the portal vein is intact.<sup>93</sup>

In conclusion the management of retroperitoneal hematomas is complex and continues to evolve. Nonoperative and operative approaches for blunt *versus* penetrating hematomas differ considerably in certain locations. The surgeon's approach is dictated by the mechanism of injury, location of the retroperitoneal hematoma, hemodynamic status of the patient, and the presence of associated injuries.

### Acknowledgments

The author is grateful to Drs. Peter A. Mucha, Jr. (Mayo Clinic) and Jack McAninch (University of California, San Francisco General Hospital) for their assistance in reviewing the sections on blunt pelvic and perirenal hematomas, respectively. The author acknowledges the technical assistance of Mariellen Blossom in the preparation of this manuscript.

### References

1. Moreno C, Moore EE, Rosenberger A, Cleveland HC. Hemorrhage associated with major pelvic fracture: a multispecialty challenge. *J Trauma* 1986; 26:987-94.
2. Weil PH. Management of retroperitoneal trauma. *Curr Prob Surg* 1983; 20:539-620.
3. Feliciano DV, Burch JM, Graham JM. Abdominal vascular injury. In Mattox KL, Moore EE, Feliciano DV, eds. *Trauma*. East Norwalk: Appleton & Lange, 1988. pp.519-536.
4. Grieco JG, Perry JF Jr. Retroperitoneal hematoma following trauma: its clinical significance. *J Trauma* 1980; 20:733-6.
5. Selivanov V, Chi HS, Alverdy JC, et al. Mortality in retroperitoneal hematoma. *J Trauma* 1984; 24:1022-7.
6. Henaio F, Aldrete JS. Retroperitoneal hematomas of traumatic origin. *Surg Gynecol Obstet* 1985; 161:106-16.
7. Allen RE, Eastman BA, Halter BL, Conolly WB. Retroperitoneal hemorrhage secondary to blunt trauma. *Am J Surg* 1969; 118:558-61.
8. Steichen FM, Dargan EL, Pearlman DM, Weil PH. The management of retroperitoneal hematoma secondary to penetrating injuries. *Surg Gynecol Obstet* 1966; 123:581-91.
9. Feliciano DV, Bitondo CG, Mattox KL, et al. Civilian trauma in the 1980s. A 1-year experience with 456 vascular and cardiac injuries. *Ann Surg* 1984; 199:717-24.
10. Feliciano DV, Burch JM, Spjut-Patrinely V, et al. Abdominal gunshot wounds. An urban trauma center's experience with 300 consecutive patients. *Ann Surg* 1988; 208:362-70.
11. Feliciano DV. Patterns of injury. In Mattox KL, Moore EE, Feliciano DV, eds. *Trauma*. East Norwalk: Appleton & Lange, 1988. pp.91-103.
12. Accola KD, Feliciano DV, Mattox KL, et al. Management of injuries to the suprarenal aorta. *Am J Surg* 1987; 154:613-8.

13. Shaftan GW. Retroperitoneal trauma. *Contemporary Surgery* 1980; 16:25-35.
14. Kudsk KA, Sheldon GF. Retroperitoneal hematoma. In Blaisdell FW, Trunkey DD, eds. *Abdominal trauma*. New York: Thieme-Stratton, 1982. pp.279-93.
15. Olsen WR. The serum amylase in blunt abdominal trauma. *J Trauma* 1973; 13:200-4.
16. Jeffrey RB Jr, Federle MP, Crass RA. Computed tomography of pancreatic trauma. *Radiology* 1983; 147:491-4.
17. Gougeon FW, Legros G, Archambault A, et al. Pancreatic trauma: a new diagnostic approach. *Am J Surg* 1976; 132:400-2.
18. Taxier M, Sivak MV Jr, Cooperman AM, Sullivan BH Jr. Endoscopic retrograde pancreatography in the evaluation of trauma to the pancreas. *Surg Gynecol Obstet* 1980; 150:65-8.
19. Bozymski EM, Orlando RC, Holt JW. Traumatic disruption of the pancreatic duct demonstrated by endoscopic retrograde pancreatography. *J Trauma* 1981; 21:244-5.
20. Klein S, John S, Fujitani R, State D. Hematuria following blunt abdominal trauma. The utility of intravenous pyelography. *Arch Surg* 1988; 123:1173-7.
21. McAninch JW, Federle MP. Evaluation of renal injuries with computerized tomography. *J Urol* 1982; 128:456-60.
22. Griffen WO Jr, Belin RP, Ernst CB, et al. Intravenous pyelography in abdominal trauma. *J Trauma* 1978; 18:387-92.
23. Dunn EL, Berry PH, Connally JD. Computed tomography of the pelvis in patients with multiple injuries. *J Trauma* 1983; 23:378-83.
24. Phillips T, Sclafani SJA, Goldstein A, et al. Use of the contrast-enhanced CT enema in the management of penetrating trauma to the flank and back. *J Trauma* 1986; 26:593-601.
25. Kearney PA Jr, Vahey T, Burney RE, Glazer G. Computed tomography and diagnostic peritoneal lavage in blunt abdominal trauma. Their combined role. *Arch Surg* 1989; 124:344-7.
26. Murr PC, Moore EE, Lipscomb R, Johnston RM. Abdominal trauma associated with pelvic fracture. *J Trauma* 1980; 20:919-23.
27. Peltier LF. Complications associated with fracture of the pelvis. *J Bone Joint Surg* 1965; 47-A:1060-9.
28. Cryer HM, Miller FB, Evers BM, Rouben LR, Seligson DL. Pelvic fracture classification: correlation with hemorrhage. *J Trauma* 1988; 28:973-80.
29. Baylis SM, Lansing EH, Glas WW. Traumatic retroperitoneal hematoma. *Am J Surg* 1962; 103:477-80.
30. Hawkins L, Pomerantz M, Eisman B. Laparotomy at the time of pelvic fracture. *J Trauma* 1970; 10:619-23.
31. Trunkey DD, Chapman MW, Lim RC, Dunphy JE. Management of pelvic fractures in blunt trauma injury. *J Trauma* 1974; 14: 912-23.
32. Hubbard SG, Bivins BA, Sachatello CR, Griffen WO. Diagnostic errors with peritoneal lavage in patients with pelvic fractures. *Arch Surg* 1979; 114:844-6.
33. Powell DC, Bivins BA, Bell RM. Diagnostic peritoneal lavage. *Surg Gynecol Obstet* 1982; 155:257-64.
34. Evers BM, Cryer HM, Miller FB. Pelvic fracture hemorrhage. Priorities in management. *Arch Surg* 1989; 124:422-4.
35. Mucha P Jr, Farnell MB. Analysis of pelvic fracture management. *J Trauma* 1984; 24:379-86.
36. Mucha P Jr. Recognizing and avoiding complications with pelvic fractures. *Infections in Surgery* 1985; 4:53-55,58.
37. Gilliland MG, Ward RE, Flynn TC, et al. Peritoneal lavage and angiography in the management of patients with pelvic fractures. *Am J Surg* 1982; 144:744-7.
38. Vermillion CD, McLaughlin AP, Pfister RC. Management of blunt renal trauma. *J Urol* 1971; 106:478-84.
39. Peterson NE. Intermediate degree blunt renal trauma. *J Trauma* 1977; 17:425-35.
40. Morgensen P, Agger P, Ostergaard AH. A conservative approach to the management of blunt renal trauma. *Br J Urol* 1980; 52: 338-41.
41. Cass AS, Cass BP. Immediate surgical management of severe renal injuries in multiple injured patients. *Urology* 1983; 21:140-5.
42. McAninch JW. Genitourinary trauma. In Mattox KL, Moore EE, Feliciano DV, eds. *Trauma*. East Norwalk: Appleton & Lange, 1988. pp.537-52.
43. Cass AS, Bubrick M, Luxenberg M, et al. Renal trauma found during laparotomy for intra-abdominal injury. *J Trauma* 1985; 25:997-1000.
44. Huttinen VM, Slatis P. Postmortem angiography and dissection of the hypogastric artery in pelvic fractures. *Surgery* 1973; 73: 454-62.
45. Reynolds BM, Balsano NA. Venography in pelvic fractures: a clinical evaluation. *Ann Surg* 1971; 173:104-6.
46. Brotman S, Soderstrom CA, Oster-Granite M, et al. Management of severe bleeding in fractures of the pelvis. *Surg Gynecol Obstet* 1981; 153:823-6.
47. Batalden DJ, Wickstrom PH, Ruiz E, Gustilo RB. Value of the G-suit in patient with severe pelvic fracture. *Arch Surg* 1974; 109: 326-8.
48. Flint LM Jr, Brown A, Richardson JD, Polk HC. Definitive control of bleeding from severe pelvic fractures. *Ann Surg* 1979; 189: 709-16.
49. Yap SNL. The management of traumatic pelvic retroperitoneal hemorrhage. *Surgical Rounds* 1980; 3:34-42.
50. Dove AF, Poon WS, Weston PAM. Hemorrhage from pelvic fractures: dangers and treatment. *Injury* 1982; 13:375-81.
51. Mears DC, Fu FH. Modern concept of external skeletal fixation of the pelvis. *Clin Orthop* 1980; 151:65-72.
52. Wild JJ, Hanson GW, Tullos HS. Unstable fractures of the pelvis treated by external fixation. *J Bone Joint Surg* 1982; 64A:1010-20.
53. Gylling SF, Ward RE, Holcroft JW, et al. Immediate external fixation of unstable pelvic fractures. *Am J Surg* 1985; 150:721-4.
54. Mucha P Jr. Pelvic fractures. In Mattox FH, Moore EE, Feliciano DV, eds. *Trauma*. East Norwalk: Appleton & Lange, 1988. pp.505-18.
55. Margolies MN, Ring EJ, Waltman AC, et al. Arteriography in the management of hemorrhage from pelvic fractures. *N Engl J Med* 1972; 287:317-21.
56. Ring EJ, Athanasoulis C, Waltman AC, et al. Arteriographic management of hemorrhage following pelvic fracture. *Radiology* 1973; 109:65-70.
57. Ring EJ, Waltman AC, Athanasoulis C, et al. Angiography in pelvic trauma. *Surg Gynecol Obstet* 1974; 139:375-80.
58. Ben-Menachem Y, Handel SF, Thaggard A III, et al. Therapeutic arterial embolization in trauma. *J Trauma* 1979; 19:944-52.
59. Yellin AE, Lundell CJ, Finck EJ. Diagnosis and control of post-traumatic pelvic hemorrhage. Transcatheter angiographic embolization techniques. *Arch Surg* 1983; 118:1378-83.
60. Panetta T, Sclafani SJA, Goldstein AS, et al. Percutaneous transcatheter embolization for massive bleeding from pelvic fractures. *J Trauma* 1985; 25:1021-9.
61. Maull KI, Sachatello CR, Ernst CB. The deep perineal laceration—an injury frequently associated with open pelvic fractures: a need for aggressive, surgical management. A report of 12 cases and review of the literature. *J Trauma* 1977; 17:685-96.
62. Rothenberger D, Velasco R, Strate R, et al. Open pelvic fracture: a lethal injury. *J Trauma* 1978; 18:184-7.
63. Richardson JD, Harty J, Amin M, Flint LM. Open pelvic fractures. *J Trauma* 1982; 22:533-8.
64. Motsay GJ, Manlove C, Perry JF. Major venous injury with pelvic fracture. *J Trauma* 1969; 9:343-6.
65. Fleming WH, Bowen JC III. Control of hemorrhage in pelvic crush injuries. *J Trauma* 1973; 13:567-70.
66. Rothenberger DA, Fischer RP, Perry JF Jr. Major vascular injuries secondary to pelvic fractures: an unsolved clinical problem. *Am J Surg* 1978; 136:660-2.
67. Smejkal R, Izant T, Born C, et al. Pelvic crush injuries with occlusion of the iliac artery. *J Trauma* 1988; 28:1479-82.
68. Accola KD, Feliciano DV, Mattox KL, et al. Management of injuries to the superior mesenteric artery. *J Trauma* 1986; 26: 313-9.
69. Courcy PA, Brotman S, Oster-Granite ML, et al. Superior mesenteric artery and vein injuries from blunt abdominal trauma. *J Trauma* 1984; 24:843-5.

70. Killen DA. Injuries of the superior mesenteric vessels secondary to nonpenetrating abdominal trauma. *Am Surg* 1964; 30:306-11.
71. Pezzella AT, Griffen WO, Ernst CB. Superior mesenteric artery injury following blunt abdominal trauma: case report with successful primary repair. *J Trauma* 1978; 18:472-4.
72. Ulvestad LE. Repair of laceration of superior mesenteric artery acquired by non-penetrating injury to the abdomen. *Ann Surg* 1954; 140:752-4.
73. Accola KD, Feliciano DV, Mattox KL, et al. Management of injuries to the suprarenal aorta. *Am J Surg* 1987; 154:613-8.
74. Lassonde J, Laurendeau F. Blunt injury of the abdominal aorta. *Ann Surg* 1981; 194:745-8.
75. Matsubara J, Seko T, Ohta T, et al. Traumatic aneurysm of the abdominal aorta with acute thrombosis of bilateral iliac arteries. *Arch Surg* 1983; 118:1337-9.
76. Veith FJ, Gupta S, Daly V. Technique for occluding the supraceliac aorta through the abdomen. *Surg Gynecol Obstet* 1980; 151:426-8.
77. Maggio AF Jr, Brosman S. Renal artery trauma. *Urology* 1978; 11:125-30.
78. Spirnak JP, Resnick MI. Revascularization of traumatic thrombosis of the renal artery. *Surg Gynecol Obstet* 1987; 164:22-6.
79. Feliciano DV. Abdominal trauma. In Schwartz SI, Ellis H, eds. *Maingot's Abdominal Operations*. East Norwalk: Appleton & Lange, (publication pending).
80. Holcroft JW, Trunkey DD, Minagi H, et al. Renal trauma and retroperitoneal hematomas—indications for exploration. *J Trauma* 1975; 15:1045-52.
81. McAninch JW, Carroll PR. Renal trauma: kidney preservation through improved vascular control. *J Trauma* 1982; 22:285-90.
82. Martin TD, Feliciano DV, Mattox KL, Jordan GL Jr. Severe duodenal injuries. Treatment with pyloric exclusion and gastrojejunostomy. *Arch Surg* 1983; 118:631-5.
83. Ivatury RR, Nallathambi M, Gaudino J, et al. Penetrating duodenal injuries. Analysis of 100 consecutive cases. *Ann Surg* 1985; 202:153-8.
84. Berne CJ, Donovan AJ, White EJ, Yellin AE. Duodenal "diverticulization" for duodenal and pancreatic injury. *Am J Surg* 1974; 127:503-7.
85. Vaughan GD III, Frazier OH, Graham DY, et al. The use of pyloric exclusion in the management of severe duodenal injuries. *Am J Surg* 1977; 134:785-90.
86. Feliciano DV, Martin TD, Cruse PA, et al. Management of combined pancreatoduodenal injuries. *Ann Surg* 1987; 205:673-80.
87. Stone HH, Fabian TC. Management of duodenal wounds. *J Trauma* 1979; 19:334-9.
88. Burch JM, Brock JC, Gevirtzman L, et al. The injured colon. *Ann Surg* 1986; 203:701-11.
89. Seavers R, Lynch J, Ballard R, Jernigan S, Johnson J. Hypogastric artery ligation for uncontrollable hemorrhage in acute pelvic trauma. *Surgery* 1964; 55:516-9.
90. Ravitch MM. Hypogastric artery ligation in acute pelvic trauma. *Surgery* 1974; 56:601-2.
91. Hauser CW, Perry JF. Control of massive hemorrhage from pelvic fractures by hypogastric artery ligation. *Surg Gynecol Obstet* 1965; 121:313-5.
92. Flint L, Seligson D. Pelvic fracture: overview, assessment and initial management. In Champion HR, Robbs JV, Trunkey DD, eds. *Trauma Surgery, Part 1 (Operative Surgery series)*. London: Butterworths, 1989. pp.492-504.
93. Feliciano DV, Pachter HL. Hepatic trauma revisited. *Curr Prob Surg* 1989; 26:453-524.
94. Paster SB, VanHouten FX, Adams DF. Percutaneous balloon catheterization. A technique for the control of arterial hemorrhage caused by pelvic trauma. *JAMA* 1974; 230:573-5.
95. Sheldon GF, Winestock DP. Hemorrhage from open pelvic fracture controlled intraoperatively with balloon catheter. *J Trauma* 1978; 18:68-70.
96. Saueracker AJ, McCroskey BL, Moore EE, Moore FA. Intraoperative hypogastric artery embolization for life-threatening pelvic hemorrhage: a preliminary report. *J Trauma* 1987; 27:1127-9.
97. Morales GR, Phillips T, Conn AK, Cox EF. Traumatic hemipelvectomy: report of two survivors and review. *J Trauma* 1983; 23:615-20.
98. Beal SH, Blaisdell FW. Traumatic hemipelvectomy: a catastrophic injury. *J Trauma* (publication pending).
99. Brown JJ, Greene FL, McMillin RD. Vascular injuries associated with pelvic fractures. *Am Surg* 1984; 50:150-4.
100. DeBaKey ME, Simeone FA. Battle injuries of the arteries in World War II. An analysis of 2,471 cases. *Ann Surg* 1946; 123:534-79.
101. McAninch JW. Traumatic injuries to the urethra. *J Trauma* 1981; 21:291-7.
102. Maier WP, Lightfoot WP, Rosemond GP. Extrahepatic biliary ductal injury in closed trauma. *Am J Surg* 1968; 116:103-8.
103. Zollinger RM Jr, Keller RT, Hubay CA. Traumatic rupture of the right and left hepatic ducts. *J. Trauma* 1972; 12:563-9.
104. Feliciano DV, Bitondo CG, Burch JM, et al. Management of traumatic injuries to the extrahepatic biliary ducts. *Am J Surg* 1985; 150:705-9.
105. Busuttill RW, Kitahama A, Cerise E, McFadden M, Lo R, Longmire WP Jr. Management of blunt and penetrating injuries to the porta hepatis. *Ann Surg* 1980; 191:641-8.
106. Feliciano DV. Approach to major abdominal vascular injury. *Surgery* 1988; 7:730-6;743-8.
107. Ivatury RR, Nallathambi M, Lankin DH, Wapnir I, Rohman M, Stahl WM. Portal vein injuries. Noninvasive follow-up of venorrhaphy. *Ann Surg* 1987; 206:733-7.
108. Graham JM, Mattox KL, Beall AC Jr. Portal venous system injuries. *J. Trauma* 1978; 18:419-22.
109. Pachter HL, Drager S, Godfrey N, LeFleur R. Traumatic injuries of the portal vein. The role of acute ligation. *Ann Surg* 1979; 189:383-5.
110. Stone HH, Fabian TC, Turkelson ML. Wounds of the portal venous system. *World J Surg* 1982; 6:335-41.
111. Feliciano DV, Mattox KL, Burch JM, et al. Packing for control of hepatic hemorrhage. *J Trauma* 1986; 26:738-43.
112. Rovito PF. Atrial caval shunting in blunt hepatic vascular injury. *Ann Surg* 1987; 205:318-21.
113. Burch JM, Feliciano DV, Mattox KL. The atriocaval shunt. Facts and fiction. *Ann Surg* 1988; 207:555-68.
114. Feliciano DV, Bitondo CG, Steed G, et al. Five hundred open taps or lavages in patients with abdominal stab wounds. *Am J Surg* 1984; 148:772-7.
115. Shorr RM, Gottlieb MM, Webb K, et al. Selective management of abdominal stab wounds. Importance of the physical examination. *Arch Surg* 1988; 123:1141-5.
116. Demetriades D, Rabinowitz B, Sofianos C, et al. The management of penetrating injuries of the back. *Ann Surg* 1988; 207:72-7.
117. Feliciano DV. Abdominal vascular injuries. *Surg Clin North Am* 1988; 68:741-55.
118. Burch JM, Feliciano DV, Mattox KL, Edelman M. Injuries of the inferior vena cava. *Am J Surg* 1988; 156:548-52.
119. Salam AA, Stewart MT. New approach to wounds of the aortic bifurcation and inferior vena cava. *Surgery* 1985; 98:105-8.