
Duplex Scanning of Central Vascular Access Sites in Burn Patients

MICHAEL WAIT, M.D., JOHN L. HUNT, M.D., and GARY F. PURDUE, M.D.

Seventy-one burned patients requiring intensive care unit management underwent 570 central venous and 167 femoral arterial catheterizations. These patients were surveyed by repeated physical examinations and duplex scans for vascular-related complications. Catheter sites were rotated every 3 days. No arterial thrombi or occlusions were noted. Fourteen patients (19.6%) had 19 positive venous duplex scans. Five patients (7%) had symptomatic deep venous thrombosis (DVT) and nine (12.6%) had asymptomatic DVT. Mean number of venous cannulations before a positive scan was 4.3 (range 1 to 17). All five symptomatic patients had DVT that originated in the lower extremities. No patient had clinical evidence of a pulmonary embolus, or limb morbidity resulting from the DVT. Follow-up duplex scans in the five asymptomatic and three symptomatic patients showed complete resolution in each case. This study demonstrates the high incidence and natural history of central DVT in a group of critically ill burn patients.

THE INCIDENCE OF lower-extremity deep venous thrombosis (DVT) in the postoperative period is estimated to be between 25% and 40%.¹ This includes both peripheral and central sites. Upper-extremity DVT is reported to occur in from 1.3% to 9% of axillary and subclavian veins.²⁻⁴

Short- and long-term vascular access in the patient with a large burn not only represents a difficult technical problem but more importantly may be the cause of significant local and systemic morbidity. The technical complications reported in the literature are legion and include thromboembolism, sepsis, pneumothorax, and particularly DVT.⁵⁻¹¹ The latter is especially dangerous because of the association with fatal and nonfatal pulmonary emboli.¹² A previous prospective clinical study in burn patients demonstrated only six complications in more than 2190

From the Parkland Memorial Hospital and University of Texas Southwestern Medical School, Dallas, Texas

femoral arterial and venous cannulations performed during a 3.5-year period.¹³

The clinical diagnosis of DVT based on the history and physical examination may be erroneous in as many as 50% of the cases, and nearly 50% of all cases are silent.¹⁴ The burned lower extremity may be associated with a number of factors not found in other patient populations that decrease the accuracy of the physical examination. These include pain, edema, and tenderness associated with the burn, escharotomies, fasciotomies, a grafted wound bed and donor sites.

Until now venography had been considered the diagnostic gold standard for DVT and, until recently, was the most frequently used and most accurate of all tests.¹⁵ Now the ideal noninvasive method of detecting DVT is with real-time B-mode venous ultrasound (duplex scanning). This test not only provides anatomic information but also physiologic data relevant to flow in the vessel. The duplex scan is as accurate as either venography or arteriography but does not cause the complications found with an invasive procedure.¹⁶⁻²⁰ It is superior to Doppler ultrasound for the diagnosis of femoral DVT when the clot is non-occlusive.²¹ The sensitivity of the duplex scan is reported to be between 89% and 100% and the specificity is between 94% and 100% when compared to venography.^{21,22}

A study was undertaken using duplex scanning to identify both the incidence and natural history of central DVT and accumulate additional data on the safety of femoral arterial cannulation in critically ill burn patients.

Materials and Methods

Two hundred thirty-eight patients were admitted to the Parkland Memorial Hospital burn Intensive Care Unit

Address reprint requests to John L. Hunt, M.D., UT Southwestern Medical Center, 5323 Harry Hines Blvd., Dallas, TX 75235-9031.

Presented at The American Burn Association, Twenty-First Annual Meeting, March 29 to April 1, 1989, New Orleans, Louisiana.

Accepted for publication July 27, 1989.

during an 18-month period. Seventy-one patients requiring central vascular access were studied serially for the development of DVT. The mean age was 31.8 years, with a range from 15 months to 68 years. The mean total burn surface area (TBSA) was 55.6% (range 15% to 97%). There were 167 common femoral artery and 570 central venous cannulations, as well as an unknown number of single punctures for the purpose of obtaining blood chemistries. The venous access sites included internal jugular-42, subclavian-30, and common femoral-498. Catheter sites were routinely changed every 3 days.

The following data were collected on all study patients: catheter type, size, number of lumens, location of access, ease of insertion, indications for insertions, and complications. Catheterizations were performed by the percutaneous Seldinger technique. A variety of catheter-type material was used. Single lumen intravenous catheters were used in 80% of the cases. The largest-gauge catheter used for central access in adults and children was 19 and 22, respectively. Femoral artery catheterization was avoided during acute burn resuscitation. No patient had a past history of central venous access, pulmonary emboli, or DVT. Prophylactic low-dose subcutaneous heparin, compressive leg wrapping, or pneumatic calf compression were not used in these patients.

Venous and arterial duplex scanning was performed by the same technician with a Diasonics Duplex Scanner (model DRF 400, Barber Lane, Milpitas, CA), using a 7.5-megaHertz ultrasonographic real-time imager and a 4.5-megaHertz scanner for Doppler spectral analysis. Duplex examinations of bilateral venous and arterial sites in the groin and the neck, including the subclavian veins, were performed each time.

The presence of any of the following criteria indicated DVT: (1) visualization of intravascular thrombus; (2) noncollapsible, noncompressible vessel wall; (3) inability to augment or demonstrate a doppler flow signal; and (4) inability to visualize motion, valves, or blood flow. All patients with DVT were restudied every 7 to 10 days until discharge and then scanned periodically as outpatients until the duplex scan was normal.

Results

There were no instances of intimal injury or arterial thrombosis detected by Duplex scanning. Of the 71 patients, 14 (19.7%) developed 19 instances of DVT in central veins. The venous sites included 4 subclavian after 6 cannulations, 4 internal jugular after 19 cannulations, and 11 femoral after 158 cannulations. There were 12 partial and seven complete venous thrombi. Nine patients with DVT were asymptomatic and five were symptomatic. Each of the latter patients presented with the sudden development of unilateral leg edema. There was no significant difference between the patients with symptomatic

and asymptomatic DVT regarding burn size, age, post-burn day of diagnosis of DVT, number of operations, or length of hospitalization. The mean postburn day that DVT was diagnosed was 45, with a range of days 10 to 110. The mean number of venous cannulations before a positive scan was 4.3 (range, 1 to 17). Seven instances of DVT developed after one cannulation (Table 1). No patient with either subclavian or jugular DVT was symptomatic (Figures 1A and B). Seven of the eight subclavian and internal jugular DVT sites were in two patients. Patients without evidence of DVT had significantly fewer overall venous cannulations than patients who developed DVT.

Three of the seventy-one patients were scanned within 1 week of burn and each had a normal scan. Scans were repeated every 7 to 10 days. Asymptomatic femoral DVT was detected on days 30, 44, and 97, respectively, after a normal scan. The number of cannulations of each vessel before DVT was 4, 12, and 16, respectively.

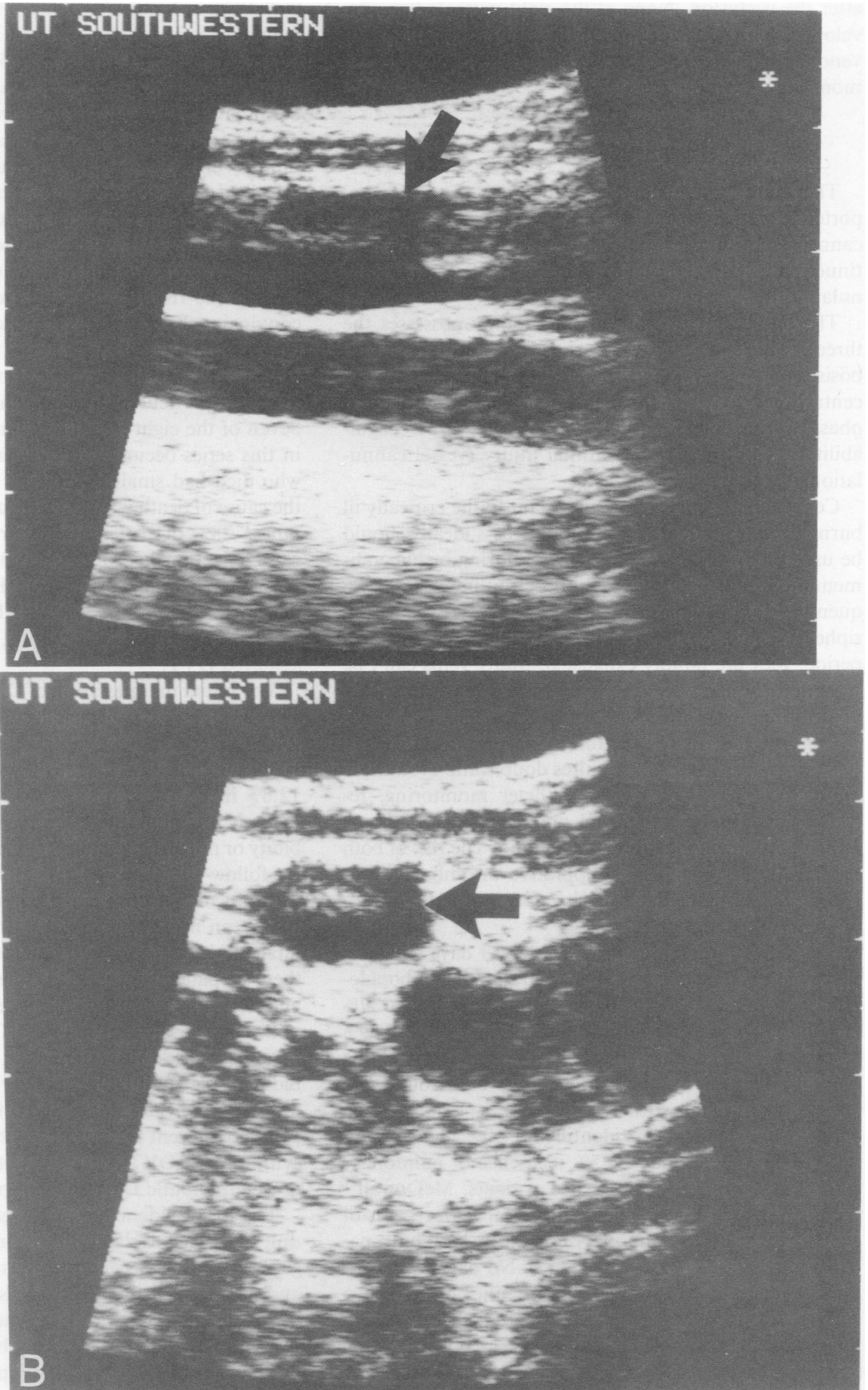
Six of the fourteen patients with DVT died in the hospital, two from a stroke, three from sepsis, and one from inadvertent airway extubation. Two patients with symptomatic DVT died, one with an 86% TBSA burn from sepsis, and the other from a cerebral vascular accident. No autopsies were performed. Comparison by chi square univariate analysis between patients with and without DVT revealed the following to be statistically significant: need for Swan-Ganz catheter monitoring ($p < 0.05$), sepsis ($p < 0.001$), ARDS ($p < 0.05$), stroke ($p < 0.001$), and death ($p < 0.001$). None of the patients with asymptomatic DVT received heparin, coumadin, or an inferior vena cava filter. Only one patient with symptomatic DVT was anticoagulated because of phlegmasia cerulea dolens.

The eight surviving asymptomatic patients were scanned every 2 weeks after discharge. The five asymptomatic patients had complete resolution of the DVT. The mean day of resolution was 32, with a range of 24 to 60 days. The three symptomatic patients had complete resolution of the DVT on days 31, 38, and 42, respectively,

TABLE 1. Number of Catheterizations Per Patient

Number of Catheter Insertions	Group A (n = 14)	Group B (n = 57)	p value
1-5	1	30	0.0014
6-10	6	7	0.008
11-20	4	11	NS
21-30	1	6	NS
31-40	1	3	NS
41-50	1	0	NS
Total 570	14	57	

A comparison of the number of central venous catheterizations in patients with subsequent DVT (group A) and those patients without DVT (group B).



FIGS. 1A AND B. (A) Longitudinal view with B-mode duplex scan of internal jugular vein. Arrow denotes partially occlusive thrombus adherent to anterior wall. (B) Cross-sectional duplex scan of jugular vein with near-occlusive thrombus (arrow).

after the occlusion. None of the eight patients have developed signs or symptoms of a pulmonary embolus or venous insufficiency. The follow-up ranges from 14 to 31 months.

Discussion

This study updates and reaffirms data previously reported from this burn unit; complications associated with cannulation of the femoral artery are minimal. This continues to be a practical and safe route for arterial cannulation in burn patients.

The critically ill burn patient certainly possesses the three predisposing factors associated with venous thrombosis proposed by Virchow: (1) stasis of blood (hemoconcentration and hypotension in the acute resuscitation phase and prolonged immobilization), (2) hypercoagulability,²³ and (3) vascular intimal injury (vessel cannulation).

Central vascular access is important in the critically ill burn patient. While central venous access ideally should be used only for hemodynamic monitoring or hyperalimentation, and not resuscitation or routine access, frequently this is not practical in burn patients. Because peripheral sites are preferentially used in the early postburn period, they are rapidly exhausted. Many veins can't be used because they are destroyed by the overlying cutaneous injury or excised with the burn eschar.

Prolonged intensive care unit management of large cutaneous burns frequently requires double and even triple lumen catheters, Swan-Ganz catheter monitoring, repeated access in the same vessel, and the use of hypertonic intravenous fluids for hyperalimentation. The risk of both systemic sepsis and local suppurative thrombophlebitis represent additional predisposing factors for the development of DVT.

Rotation of intravascular sites every 3 days has been shown to decrease the risk of suppurative thrombophlebitis.²⁴ In a study of 139 burn deaths there was a 37% incidence of venous thrombosis found at autopsy and 39% of these were infected.²⁵ The standard practice in treating burned patients with central lines is to both rotate and change the catheters sites every 3 days.

Sevitt and Gallagher²⁶ identified a 60% incidence of venous thrombosis and a 5.5% incidence of pulmonary emboli at necropsy in 33 burned patients. McDowall²⁷ reviewed the clinical records and postmortem reports of deaths attributed to pulmonary emboli in 2250 burn patients and found a 0.04% incidence. No data was given on the incidence of central DVT in either of these two studies. Mayou et al.²⁸ prospectively studied 15 burn patients with I¹²⁵ fibrinogen. Nine scans were positive (60%) and eight were confirmed with venography. There were

two cases of femoral thrombi and one pulmonary embolus.

Clagett²⁹ pooled data from 54 previously published studies during a 10-year period evaluating different methods of prophylaxis for DVT and reported a 25% incidence of DVT in general surgical patients. The incidence of pulmonary emboli in the same group of pooled studies approached 1.6%. However the diagnosis of DVT was largely made using I¹²⁵ fibrinogen uptake scanning and many series did not specify if central vascular sites were involved. There appears to be little argument that low-dose heparin reduces the risk of postoperative DVT, but data is less convincing that it reduces the risk of fatal pulmonary emboli.

Central DVT in the jugular or subclavian veins represents a particularly difficult therapeutic challenge.^{30,31} Seven of the eight subclavian and internal jugular DVT in this series occurred in two patients. The one patient who died had small pulmonary emboli at autopsy, but the cause of death was sepsis. In a study reported by Horratas,³ 28% of patients with previous subclavian vein catheterization had a 28% incidence of DVT and 12% developed pulmonary emboli. Harley et al.² identified pulmonary emboli in 35.7% of 14 patients with axillary and subclavian vein thrombosis, but none had hospital-acquired DVT.

The initial manifestation of DVT may be a pulmonary embolus. More than 80% of pulmonary emboli originate in the deep veins of the leg, and the majority originate when the thrombus extends above the knee.³² While the 12.6% incidence of asymptomatic DVT in these 71 patients is alarming, there has been no chronic limb morbidity or pulmonary emboli in the surviving patients, with the follow-up exceeding 2.5 years. During the last 8 years in more than 3200 admissions to this burn unit, there have been no fatal pulmonary emboli and only six non-fatal, clinically diagnosed pulmonary emboli.³³ Three of these six patients received low-dose subcutaneous heparin and none had lower-extremity central venous access.

Because lower-extremity DVT is common in surgical patients and results in significant acute and chronic morbidity and even fatal pulmonary emboli, early diagnosis and treatment are paramount. Prophylactic and therapeutic treatment regimens have become standardized for symptomatic DVT.^{34,35} On the other hand, the treatment of asymptomatic DVT in burn patients is uncharted.

The low incidence of pulmonary emboli in this burn unit does not correlate with reported series of general surgical patients.³² Because this was not a prospective study and the number of patients was small, the true incidence of central DVT and the exact time of thrombus formation in asymptomatic cases could not be determined. Therefore none of the patients with asymptomatic DVT were an-

ticoagulated or had insertion of a inferior vena cava filter. Four of the five symptomatic patients were not anticoagulated because each had a large open burn wound, which was considered a contraindication to anticoagulation.

The present study is the first to provide data about the incidence and natural history of central DVT in burn patients. This represents a unique subset of intensive care unit patients and therefore care must be exercised in interpreting this data and how the patients were treated. It is hoped that investigators in other burn units will accumulate data on both the incidence of central DVT and pulmonary emboli so that safe and effective treatment regimens can be formulated and, more importantly, better preventive measures can be developed.

This study raises more questions than answers. Should all burn patients with central lines be treated with prophylactic low-dose subcutaneous heparin because of the high incidence of symptomatic and asymptomatic DVT? If anticoagulation is believed to be contraindicated in a burn patient with either symptomatic or asymptomatic DVT, should caval interruption be instituted? Should a vena cava filter be inserted in the septic burn patient when anticoagulation is contraindicated? If the low incidence of pulmonary emboli found in this unit is confirmed by others, is any therapy warranted for asymptomatic DVT? Should routine serial Duplex scanning be performed in burn patients with central venous access to identify DVT?

Acknowledgment

The authors thank Candy Alway, R.D.M.S, for her invaluable assistance in obtaining data for this manuscript.

References

- Diserio FJ, Sasahara AA. United States trial of dihydroergotamine and heparin prophylaxis of deep vein thrombosis. *Am J Surg* 1985; 150:25-32.
- Harley DP, White RA, Nelson RJ, Hehringer CM. Pulmonary embolism secondary to venous thrombosis of the arm. *Am J Surg* 1984; 147:221-224.
- Horattas MC, Wright DJ, Fenton AH, et al. Changing concepts of deep venous thrombosis of the upper extremity; report of a series and review of the literature. *Surgery* 1988; 104:561-564.
- Dye LE, et al. Deep venous thrombosis of the upper extremity associated with the use of the swan ganz catheter. *Chest* 1978; 73: 673-675.
- Chartre J, Cornud F, Abderrezak B. Thrombosis as a complication of pulmonary artery catheterization via the internal jugular vein. *N Engl J Med* 1982; 306:278-281.
- Elliott CG, Zimmerman GA, Terry CP, et al. Complications of pulmonary artery catheterization in the care of critically ill patients. *Chest* 1979; 76(6):647-652.
- Malatinsky J, Faybik M, Samel M. Surgical infections and thromboembolic complications of central venous catheterizations. *Resuscitation* 1983; 10:271-281.
- Ahmed N, Payne RF. Thrombosis after central venous catheterization. *Med J Aust* 1976; 1:217-220.
- Ryan JA, Abel RM, Abbott WM, et al. Catheter complications in total parenteral nutrition: a prospective study of 200 consecutive patients. *N Engl J Med* 1974; 290:757-761.
- Lynn KL, Maling TM. A major pulmonary embolus as a complication of femoral vein catheterization. *Br J Radiol* 1977; 50:667-668.
- Wheeler HB. Diagnosis of deep vein thrombosis. *Am J Surg* 1985; 150:7-13.
- Comerota AJ, White JV, Katz ML. Diagnostic methods for deep vein thrombosis: venous doppler examination, phlebography, iodine-125 fibrinogen uptake, and phlebography. *Am J Surg* 1985; 4A:14-24.
- Purdue GF, Hunt JL. Vascular access through the femoral vessels: indications and complications. *JBCR* 1986; 7:498-500.
- Maurer AH, Hill SL, Martin D, McDannald ER. Radionuclide-nography in subclavian vein thrombosis complicating parenteral nutrition. *Clin Nucl Med* 1984; 9:397-399.
- Hill SL, Martin D, McDannald ER, Donato AT. Early diagnosis of iliofemoral venous thrombosis by doppler examination. *Am J Surg* 1988; 156:11-20.
- Rollins DL, Semrow CM, Friedell ML, et al. Progress in the diagnosis of deep venous thrombosis: the efficacy of real-time B-mode ultrasonic imaging. *J Vasc Surg* 1988; 638-641.
- Szendro G, Nicolaides AN, Zukowski AJ, et al. Duplex scanning in the assessment of deep venous incompetence. *J Vasc Surg* 1988; 4:237-242.
- Borozan PG, Zukowski A, Thorpe L, et al. Noninvasive imaging for deep venous thrombosis. *Am J Surg* 1988; 156:474-476.
- Dauzat M, Laroche JP, Charras C, Blin B. Real-time b-mode ultrasonography for better specificity in the noninvasive diagnosis of deep venous thrombosis. *J Ultrasound Med* 1986; 5:625-631.
- Sullivan ED, Peter DJ, Cranley JJ. Real-time b-mode venous ultrasound. *J Ultrasound* 1984; 1:465-471.
- Langesfeld M, Hershey Falls B, Thorpe L, et al. Duplex b-mode imaging for the diagnoses of deep venous thrombosis. *Arch Surg* 1987; 122:587-591.
- Lensing WA, Prandoni P, Brandjes D, et al. Detection of deep vein thrombosis by real-time b-mode ultrasonography. *New Engl J Med* 1988; 320:342-345.
- Curreri PW, Katz AI, Dotin LN, et al. Coagulation abnormalities in the thermally injured patient. *Dur Topics Surg Res* 1970; 2: 401-411.
- Warden GA, Wilmore DW, Pruitt BA. Central venous thrombosis: a hazard of medical progress. *J Trauma* 1983; 13:620-626.
- Pruitt BA, McManus WF, Kim SH, Treat RC. Diagnosis and treatment of cannula-related intravenous sepsis in burn patients. *Ann Surg* 1980; 191:546-554.
- Sevitt S, Gallagher N. Venous thrombosis and pulmonary embolism: a clinico-pathological study in injured and burned patients. *Br J Surg* 1961; 48:475-489.
- McDowall RAW. Pulmonary embolism and deep vein thrombosis in burned patients. *Br J. Plas Surg* 1973; 26:176-177.
- Mayou BJ, Wee J, Girling M. Deep vein thrombosis in burns. *Ann Surg* 1980; 191:546-554.
- Clagett G, Patrick, Reisch JS. Prevention of venous thromboembolism in general surgical patients. *Ann Surg* 1988; 208:227-240.
- Fishman EK, Pakter EL, Gayler, BW, et al. Jugular venous thrombosis: diagnosis by computed tomography. *J CAT* 1984; 8:963-968.
- Moser KM, LeMoine JR. Deep venous thrombosis and pulmonary embolism. *JAMA* 1981; 246:1422-1424.
- Dalen JE, Paraskos JA, Ockene IS, et al. Venous thromboembolism. Scope of the problem. *Chest* 1986; (Suppl):370S-373S.
- Purdue GF, Hunt JL. Pulmonary emboli in burned patients. *J Trauma* 1988; 25:218-220.
- Hull RD, Raskob GE, Hirsh J. Prophylaxis of venous thromboembolism. An overview. *Chest* 1986; 89(Suppl):374S-383S.
- Crandon AJ, Peel KR, et al. Prophylaxis of postoperative deep vein thrombosis: selective use of low-dose heparin in high-risk patients. *Br Med J* 1980; 345-347