

ROTATORY NYSTAGMUS SYNCHRONOUS WITH HEARTBEAT: A TREATABLE FORM OF NYSTAGMUS

BY **Brian R. Younge MD**,* Nissim Khabie MD, Robert H. Brey PhD, AND Colin L.W. Driscoll MD

ABSTRACT

Purpose: To describe a treatable form of nystagmus.

Methods: Two patients recently evaluated at the Mayo Clinic had experienced various forms of oscillopsia, imbalance, and worsening symptoms with a Valsalva maneuver. Close inspection of the eye revealed a subtle rotatory nystagmus that was synchronous with the heartbeat.

Results: The two patients had surgical treatment for dehiscence of the superior semicircular canal; postoperatively, their symptoms completely resolved. This is a relatively newly discovered condition that has not been described on either slit-lamp or ophthalmoscopic examination. The cause is related to a dehiscence of the superior semicircular canal that permits communication of variable pressures between the intracranial cavity and the perilymphatic spaces of the semicircular canal.

Conclusion: Being aware of this unusual form of nystagmus may permit physicians to diagnose it—one of the few treatable forms of nystagmus.

Trans Am Ophthalmol Soc 2003;101:113-118

INTRODUCTION

Most forms of nystagmus, whether congenital or acquired, respond poorly to treatment, although some progress has been made with surgical management of congenital nystagmus. Of the acquired types due to peripheral or vestibular causes, treatment of the primary condition may be helpful if the condition is treatable. We describe for the first time the ophthalmoscopic and slit-lamp appearance of a rotatory nystagmus that sometimes is associated with oscillopsia and is synchronous with the heartbeat, implying a connection between the intracranial space and the inner ear. The cause of this disturbance of the physiology of the inner ear mechanism is dehiscence of the superior semicircular canal.

This condition was described initially by Minor and associates¹ in 1998. The nystagmus has been described by Cremer and colleagues² as having upward torsional slow phases, characteristic of superior canal activation, due either to a loud sound or a Valsalva maneuver. This condition is also known as the Tullio phenomenon (a phenom-

enon of combined vertigo and abnormal eye movements induced by high-intensity sound). Canal occlusion or repair has been performed with considerable success in several patients.

METHODS

Recently, two patients evaluated at the Mayo Clinic were discovered to have dehiscence of the superior semicircular canals and had surgical repair. They are the subjects of this report.

The first patient, referred for neuro-ophthalmic examination because of a peculiar story, was seen initially by Dr Dennis Robertson of Mayo Clinic. The patient was a 56-year-old man and an avid cyclist. Over the past 2 years, he had experienced a subtle imbalance, which he particularly noted when he moved his head quickly, for example, when looking back and forth for traffic while riding his bike. About 2.5 years ago, he fell and cracked his helmet but had no injury. He also found that straining would exaggerate his symptoms of oscillopsia and imbalance.

The patient's relevant past medical history included a long-standing stable hearing loss, for which he wore hearing aids. A vestibular assessment 1.5 years previously uncovered a 56% reduction in the caloric response on the left. On eye examination, the only positive finding was a subtle rotatory nystagmus seen during direct ophthal-

From the Department of Ophthalmology (Dr Younge), the Vestibular/Balance Laboratory (Dr Brey), and the Department of Otorhinolaryngology (Drs Driscoll and Khabie), Mayo Clinic, Rochester, Minnesota. Supported in part by a departmental unrestricted grant from Research to Prevent Blindness.

*Presenter.

Bold type indicates AOS member.

moscopy. On close questioning, and after some hesitancy, the patient admitted that his vision appeared to oscillate very slightly, more so with exercise. The frequency of the oscillation was synchronous with his pulse and increased with mild exercise (the examiner and patient climbed stairs together). With careful slit-lamp examination, the same subtle movement was seen and captured on video. The movement had no rapid component in either direction, just a slow torsion. Later, Dr Robertson witnessed a torsion movement of the whole eye during indirect ophthalmoscopy while the patient performed a strong Valsalva maneuver. This, too, was captured on video. Subsequent vestibular testing that included posturography implicated the left semicircular canal system. The results of magnetic resonance imaging (MRI) of the head were unremarkable, but computed tomography (CT), using high-resolution techniques to see the temporal bones, showed a dehiscence of the left superior semicircular canal (Figure 1). At surgery, this canal was found to be covered with only a thin membrane, and temporalis fascia and a bone graft were placed over the dehiscence to seal it.

The second patient was a 62-year-old man who was a neuroradiologist (in fact, trained at Mayo Clinic). He had problems with balance dating to 1992, when he had short episodes of vertigo when picking up a golf ball. Evaluation included two MRI studies, both of which were normal. In the last year, his symptoms have become worse, notably acute vertigo with any sort of sneeze, cough, or Valsalva maneuver or with just bending over. He has been evaluated at Mayo Clinic over the years for various problems, including an old resolved history of Guillain-Barré syndrome and an ongoing chronic inflammatory demyelinating polyneuropathy. Two years earlier, an ear, nose, and throat examination was performed for tinnitus, fullness, and hyperacusis in the left ear. The results of an eye examination were normal, except for a very noticeable torsional nystagmus with a Valsalva maneuver. The rapid component had a clockwise vector (as seen looking at the patient). A fine rotatory nystagmus was noted during both the slit-lamp and ophthalmoscopic examinations. Of anecdotal interest, a high-resolution CT scan had been interpreted as “negative,” but in the office, he was invited to scrutinize this scan on the computer display and found abnormalities on *both* sides, namely, bilateral superior semicircular canal dehiscences (Figure 2).

The left superior semicircular canal was explored through a middle cranial fossa approach. The superior semicircular canal was clearly dehiscence (Figure 3). To prevent loss of inner ear fluid and an almost certain hearing loss, the canal was immediately occluded with bone wax. The dehiscence area was then covered with a bone

graft. Brainstem auditory evoked potentials were monitored intraoperatively, and, of interest, the waveform corresponding to cochlear function improved as the dehiscence was sealed (Figure 4). His symptoms have almost cleared. He is considering having the procedure performed on the opposite side.

DISCUSSION

The superior canal dehiscence syndrome was first described in 1998 in 8 patients with vertigo or disequilibrium related to sound or pressure stimuli.¹ All the patients were found to have dehiscence of the bone overlying the superior semicircular canal. The symptoms included sound- or pressure-induced vertigo, oscillopsia, or imbalance, which may be constant or episodic. Typically, the patient has no history of otologic disease, and hearing is normal or loss is minimal. Sometimes, hyperacusis is reported.

Examination discloses vertical-torsional nystagmus induced by sound or pressure delivered to the middle ear, with the Weber test lateralizing to the affected ear. Valsalva-induced nystagmus is prominent. CT demonstrates dehiscence of the superior semicircular canal.

The pathophysiologic mechanism is dehiscence over the superior semicircular canal. This represents a “third mobile window” that allows pressure to be dissipated into the dehiscence area. Positive pressure in the middle ear causes endolymph to flow away from the ampulla of the superior semicircular canal, resulting in excitation of the hair cell receptors and, thus, the vestibular nerve. Carey and associates³ examined 1,000 temporal bones from 596 adults and found dehiscence in 5 bone specimens (0.5% [0.7% of the adults]). In 1.4%, the bone was thin (<0.1 mm); they reported that the bone is uniformly thin in infants until age 3. The location of this phenomenon is in the arcuate eminence or superior petrosal sinus, and it is often bilateral. There were no erosive processes (gummas or arachnoid granulations). Carey and associates³ concluded that this dehiscence is most likely a developmental problem, often bilateral, with no evidence of erosion. A secondary event such as trauma may cause symptoms. The dehiscence is shown in Figure 5.

Eye movements in the superior canal dehiscence syndrome were first described by Cremer and colleagues,² who used scleral search coils for 3-dimensional representation of eye movements. They demonstrated that the slow phase of the nystagmus was parallel to the axis of the superior semicircular canal: up and counterclockwise rotation with stimulation of the right ear, clockwise with stimulation of the left ear. The release of Valsalva pressure leads to a “stimulatory” pattern of nystagmus. Visual fixation, using a light-emitting diode target, led to

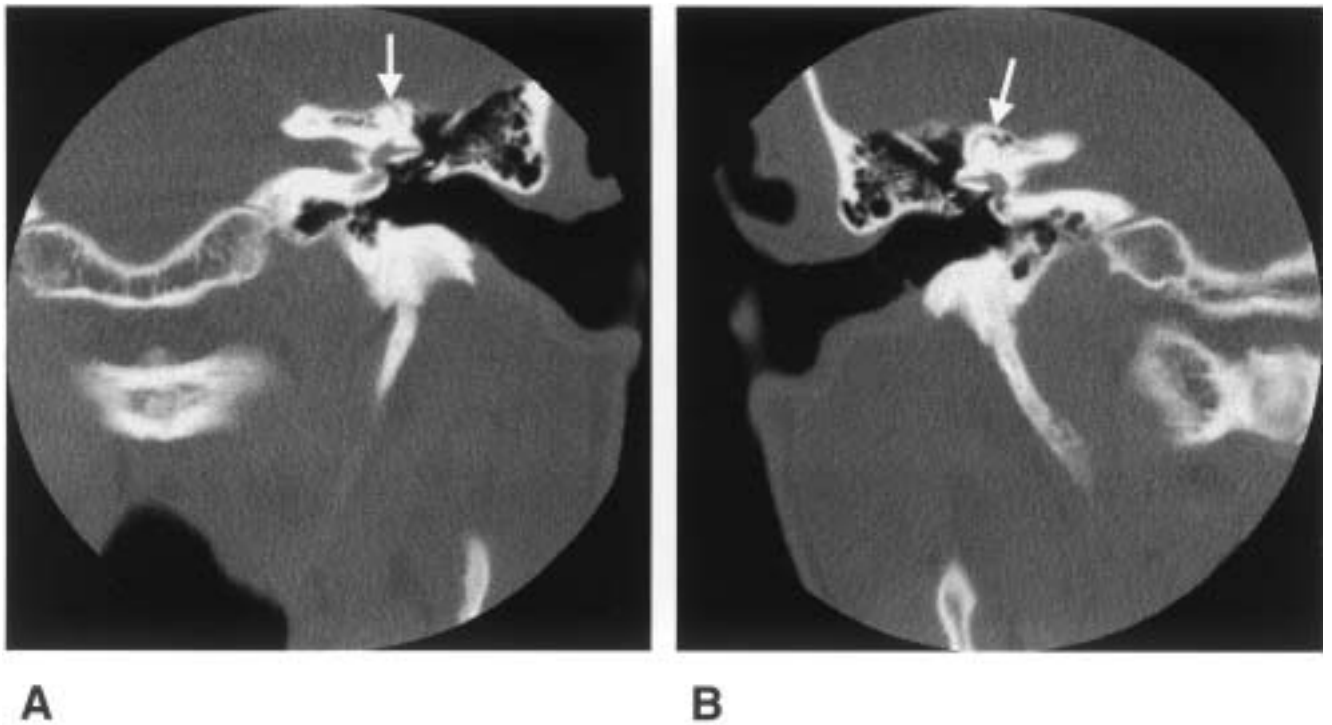


FIGURE 1

Patient 1. A, Left temporal bone seen on high-resolution computed tomogram showing dehiscence (arrow) in superior semicircular canal. B, Note the bone (arrow) overlying the canal.

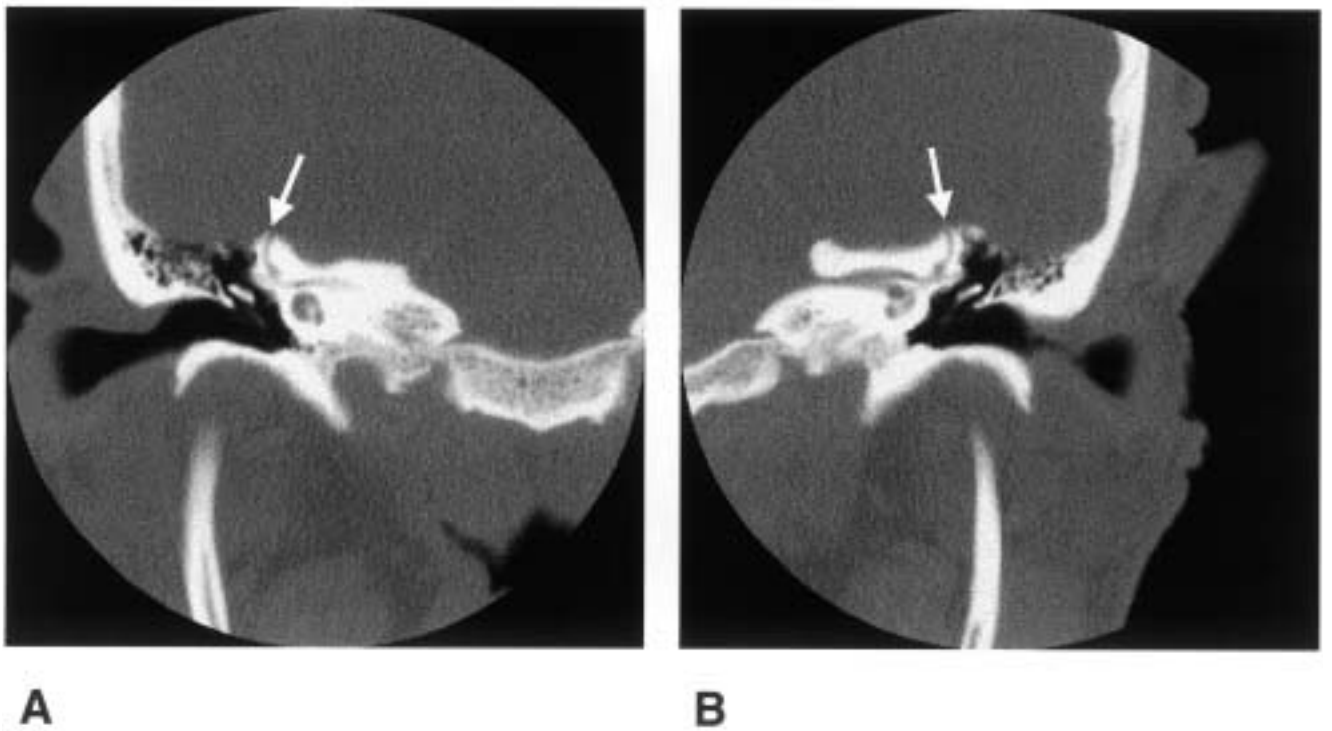


FIGURE 2

Patient 2. A and B, Bilateral dehiscences (arrows) in the superior semicircular canals.

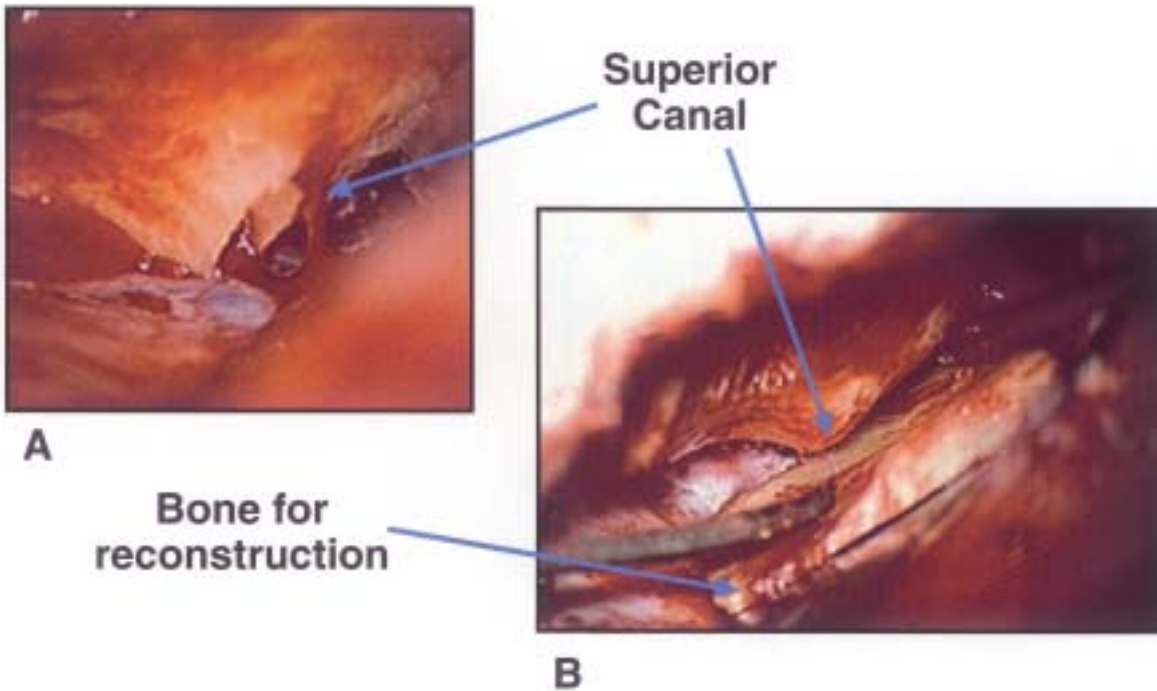


FIGURE 3

Patient 2. A, Operative field of dehiscence. Note that the inside of the superior semicircular canal is widely exposed (arrow). B, A bone graft about to be placed over the opening (arrow) in the canal.

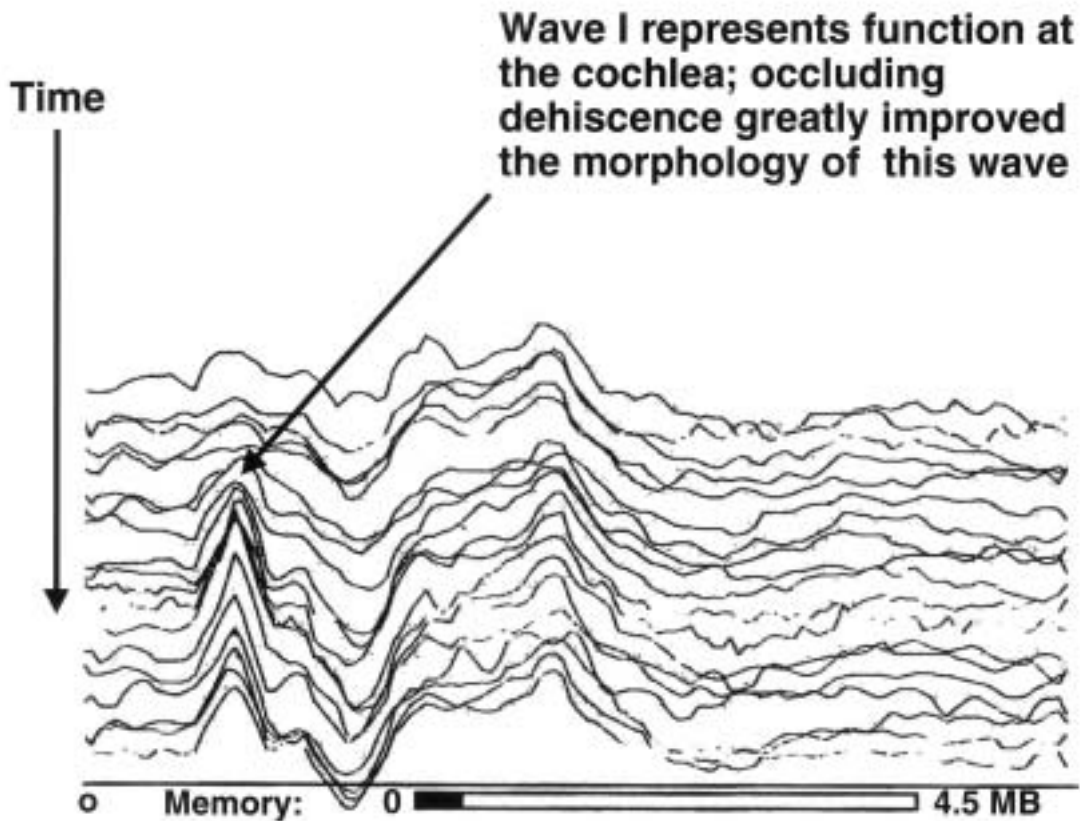


FIGURE 4

Patient 2. Intraoperative brainstem auditory potential tracings showing improvement in the form of wave I, corresponding to the cochlea, as dehiscence is covered.

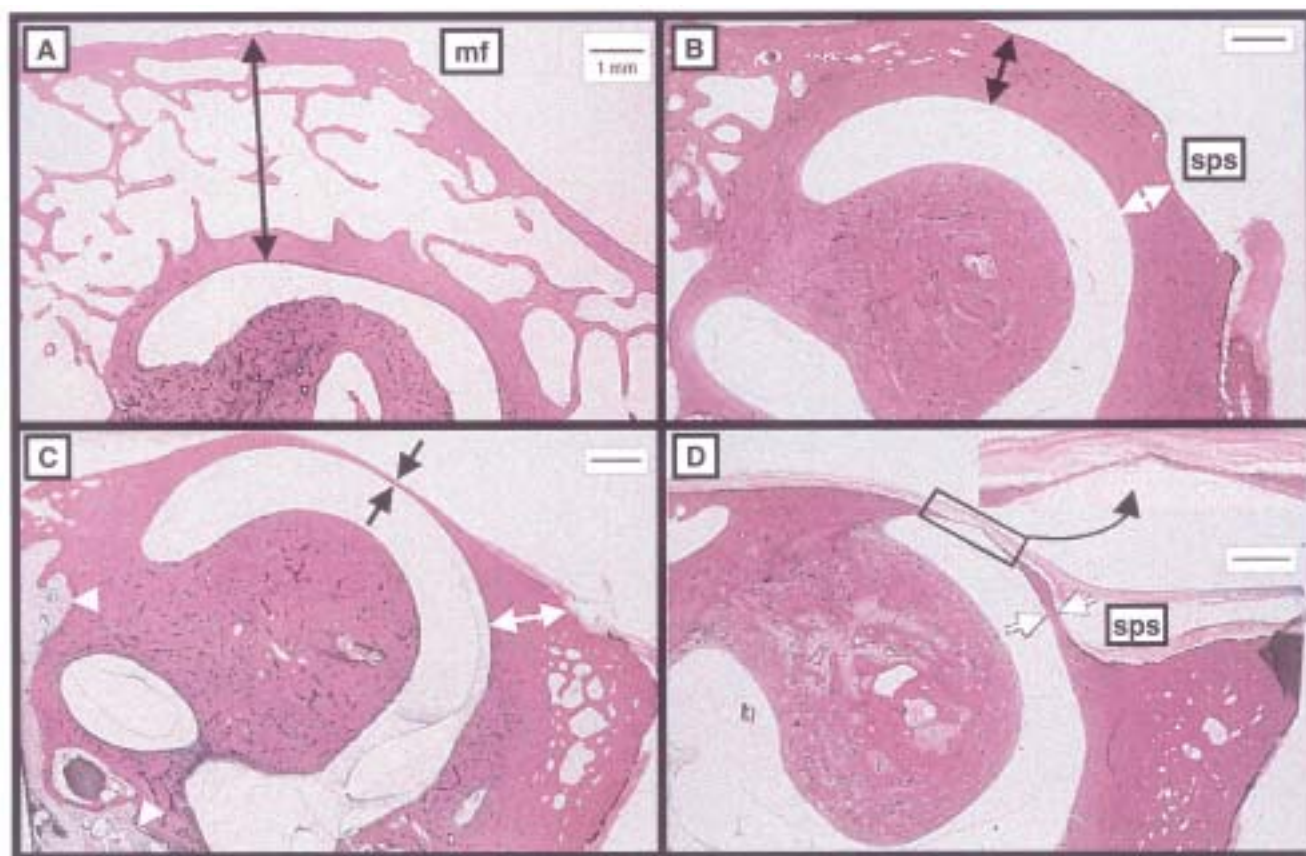


FIGURE 5

A through D, The varying thickness of bone (indicated by arrows) overlying the superior canals. Inset in D shows a very thin or perhaps fractured canal. mf, middle cranial fossa; sps, superior petrosal sinus. (Reprinted with permission from *Arch Otolaryngol Head Neck Surg*. Copyright 2000, American Medical Association.)

sustained torsional deviation of the eyes away from the stimulated ear, but suppression of horizontal and vertical nystagmus. There was no skew deviation (which is seen with stimulation of the utricle).

For most patients, treatment has been conservative, with most patients electing to watch the situation and avoid stimuli that cause vertigo.² Seven patients at two institutions have been reported to have undergone treatment, with either a middle fossa or transmastoid approach being used. The vestibular symptoms of all the patients have improved, but neurosensory hearing loss developed postoperatively in two.

CONCLUSIONS

Dehiscence of the superior semicircular canal is a newly described phenomenon in which vertigo is caused by pressure or sound changes. Heretofore, it has been misdiagnosed as perilymph fistula or Tullio phenomenon. The syndrome has specific eye movement findings on vestibular testing, and high-resolution CT confirms the diagnosis of dehiscence of the superior semicircular canal.

This is a treatable cause of nystagmus and vertigo. During an ophthalmoscopic or slit-lamp examination, finding of a subtle rotary nystagmus that is synchronous with the pulse can lead the examiner to the diagnosis.

REFERENCES

1. Minor LB, Solomon D, Zinreich JS, et al. Sound- and/or pressure-induced vertigo due to bone dehiscence of the superior semicircular canal. *Arch Otolaryngol Head Neck Surg* 1998;124:249-258.
2. Cremer PD, Migliaccio AA, Pohl DV, et al. Posterior semicircular canal nystagmus is conjugate and its axis is parallel to that of the canal. *Neurology* 2000;54:2016-2020.
3. Carey JP, Minor LB, Nager GT. Dehiscence or thinning of bone overlying the superior semicircular canal in a temporal bone survey. *Arch Otolaryngol Head Neck Surg* 2000;126:137-147.

DISCUSSION

DR JONATHAN D. WIRTSCHAFTER. It has been said that most of the questions asked of candidates for the exami-

nations of the American Board of Ophthalmology have remained the same over the years. Fortunately, the answers to the old questions continue to change. It has also been said that, in medicine and science, what is accepted as a fact is simply what cannot be disproven at present. Rotary nystagmus, vertigo and disequilibrium have been known to occur with several forms of pressure on the vestibular system. These include heartbeat-induced fluctuation of intracranial venous pressure or Valsalva maneuver, increased external auditory canal pressure (finger movement within the external auditory canal-Hennebert's sign), increased middle ear pressure transmitted by the eustachian tube (yawning), and sound pressure. The phenomenon of nystagmus induced by loud sound is known as Tullio's phenomenon. The accepted explanation of most of these pressure-induced nystagmus cases was a perilymph fistula (an abnormal connection between the inner and middle ears that allows the escape of perilymph fluid into the middle ear compartment). Ruptures of the round and oval windows are a treatable cause of symptoms.

Advances in neuroimaging and studies of bone bank material have shown that the bone overlying the superior semicircular canal is very thin in infants, so that the dura and membranous canal are initially in direct contact and only later are separated by bone. In 1998 Minor and associates reported probable dehiscence of the superior semicircular canal in eight patients with Tullio's phenomenon, Hennebert's sign or similar symptoms. The dehiscence constituted a so-called third mobile window into the inner ear that allowed the fluid in the semi-circular canal to be responsive to sound and pressure changes. In this way the CSF pulse can be transmitted to the vestibular system. In two of these cases the affected canal was surgically sealed via craniotomy with beneficial results. More significantly, the same group performed a study of a thousand temporal bones that had wisely been collected in the middle of the previous century and this collection had not been discarded to reclaim space at the beginning of this century. Their study showed that 0.5% of temporal bone specimens and 0.7% of the individuals had dehiscence in the semicircular canal and that additional patients had intrusion on the canal from the adjacent superior petrosal sinus. Younge and his associates have called to our attention today that a previously unrecognizable condition has a rational explanation and a possible surgical treatment for the most disabled cases. However we must be cautious in assuming that we understand the pathogenesis of pressure-induced nystagmus for all patients, as there are patients who may have local erosive processes such as a vestibular schwannoma or infectious disorders such as syphilis or Lyme disease who may acquire the same symptomatology due to other mechanisms. All patients with

vestibular symptoms should be questioned concerning barotrauma and head injury, as these are predisposing events. Classical perilymph fistulas must still be identified and the diagnosis may be elusive. The authors are to be commended for sharing with us a new answer to an old question and in demonstrating that the new answer provides a potential opportunity for effective surgical treatment.

DR JONATHAN C. HORTON. In this condition, what is dehiscing from what? At one point you call this a superior, semi-circular canal dehiscence and at another point you call it a bony dehiscence. Isn't this really an erosion of the bone encasing the canal rather than a dehiscence?

The dehiscence itself is a defect in the bone, and there may be a membrane still present. There is not a fluid communication with the central nervous system. It is like a diaphragm that will move and that movement will set up the transmission of the pulse from within the head, whether it's just from the heartbeat, or from a sneeze, or from a Valsalva movement. The increase in pressure is transmitted through that membrane which isn't necessarily a complete dehiscence but rather a membranous dehiscence of bone that allows the transmission of the pulse wave into the semi-circular canal. What causes this is unknown. It may be some minor trauma, or it may just be a spontaneous event that happens at some time in life.