

# Natural course of Crohn's disease after ileocolic resection: endoscopically visualised ileal ulcers preceding symptoms

G Olaison, K Smedh, R Sjö Dahl

## Abstract

Forty two Crohn's disease patients were followed up after ileocolic resection with regard to symptoms and endoscopic appearance of the ileocolic anastomosis. Twenty eight patients resected because of colonic neoplasm served as controls. In all the Crohn's disease patients the ileal resection margin was disease free macroscopically at operation. In addition, intraoperative ileoscopy was performed in 13 and no sign of residual inflammation in the neoterminal ileum was seen. Endoscopy soon after surgery often showed preanastomotic ileal ulceration before symptoms appeared, whereas no anastomotic lesions were observed in the controls. Thus, 22 of 30 Crohn's disease patients examined had ulceration of the anastomotic area after three months, but only 10 had developed symptoms indicating relapse (73 v 33%). Corresponding figures in the 30 patients examined after one year were 93 v 37%, and in 14 patients after three years they were 100 and 86% respectively. The inflammatory lesions in all cases were preanastomotic, in the neoterminal ileum, and showed time related progression from aphthae to larger ulcers and stricture. The study suggests that endoscopically observed inflammatory lesions that appear soon after ileocolic resection for Crohn's disease signify new inflammation and not residual, persistent disease or incomplete anastomotic healing. The data further suggest that despite clinical remission after apparently radical intestinal resection, the bowel is permanently inflamed in Crohn's disease.

Crohn's disease generally leads inevitably to severe intestinal inflammation and stricture. Resection of the diseased gut remains the standard option for the severely ill patient with defined segmental inflammation. Recurrence, however, is distressingly common, and it is now clearly established that surgery, even though apparently radical, offers no cure. The effect of surgery on the natural course of the disease is still controversial, and recurrence rates of 16-94% have been reported.<sup>1-11</sup> This difference is not surprising, as the diagnostic criteria for recurrence are highly variable, ranging from clinical manifestations through radiological or histological evidence of disease to need for surgical intervention.

Recurrent lesions after ileocaecal resection for ileal disease or colectomy with ileorectal anastomosis for colitis tend to be localised to the region of the anastomosis.<sup>4,12,13</sup> Moreover, the overall postoperative recurrence rate was

reported to be higher after colectomy and ileorectal anastomosis.<sup>9,14-16</sup> Colonoileoscopy provides unique opportunities for studying the early development of intestinal inflammation in this area.<sup>17</sup> In previous studies,<sup>18,19</sup> a recurrence rate of 72-73% was found within a year of operation, and after three years it was 87%.<sup>19</sup> Other authors<sup>20,21</sup> have described endoscopic lesions in the ileocolic anastomosis within two to six months in 70% of their patients, and postulated that these early lesions are not true recurrences, but merely recrudescing foci not removed at the time of resection.

This study examined the endoscopic appearance of the anastomotic area and its relation to symptoms after ileocolic resection or colectomy for Crohn's disease. Because we wished to clarify whether lesions seen at endoscopy were true recurrences or simply non-resected, residual disease, only patients without grossly visible residual intraoperative inflammation were admitted to the study. In order to elucidate whether early anastomotic lesions represent changes specific for Crohn's disease, patients who had undergone ileocolic resection and anastomosis because of colonic neoplasm served as controls.

## Patients and methods

### CROHN'S DISEASE PATIENTS

During the six year period 1984-90, 55 patients with Crohn's disease under surveillance at our hospital were treated with ileocolic resection. Forty two of these patients agreed to participate in the study. The male:female ratio was 26:16 and the age range was 11-75 (mean 39) years. The diagnosis was based on the Morson morphological criteria of resected tissue.<sup>22</sup> Thirty four patients had primarily ileal disease. The operations comprised ileocaecal resection in 26 and anastomotic resection after primary ileocaecal resection in eight others. Eight patients had primarily Crohn's colitis, six of whom had no ileal involvement. Subtotal colectomy with ileocolic anastomosis was performed in three, and anastomotic resection because of ileal recurrence after colectomy was undertaken in another three. One patient required a left hemicolectomy with ileorectal anastomosis after right hemicolectomy and another a right sided hemicolectomy because of colitis and ileitis.

### CONTROL SUBJECTS

Twenty eight patients who had undergone right sided hemicolectomy or ileocaecal resection

Gastrointestinal Unit,  
Department of Surgery,  
University Hospital,  
Linköping, Sweden  
G Olaison  
K Smedh  
R Sjö Dahl

Correspondence to:  
Dr G Olaison, Department of  
Surgery, University Hospital,  
S-581 85 Linköping, Sweden.

Accepted for publication  
3 June 1991

(one) because of colonic carcinoma or large villous adenoma (two) served as controls. Their ages ranged from 30–79 years (mean 63 years).

#### INTRAOPERATIVE PROCEDURE

During operation the entire small and large bowel were carefully scrutinised for inflammatory lesions. To ascertain freedom from macroscopic inflammation at the resected margins, both the remaining intestine and the resected specimen were inspected. Intraoperative ileoscopy (Olympus CF-IBW or CF-10L colonoscope) of at least 30 cm of the residual neoterminal ileum was performed in the last 13 Crohn's disease patients, in all of whom the ileal mucosa was seen to be normal. The ileoscopy was performed in a retrograde fashion, and the ileum was distended with air as the bowel proximal to the endoscope was gently compressed. This technique allowed an excellent view of the distended bowel. All resected tissue was examined histologically, with special emphasis on the presence of inflammation at the margins. Six patients showed microscopic inflammation at the ileal resection margin, and one of 13 patients who underwent perioperative ileoscopy showed marginal ileal inflammation.

In both groups the anastomosis was constructed as a conventional end to end anastomosis. A one or two layer closure with 3–0 or 4–0 polyglycolic acid (Dexon) was used.

#### FOLLOW UP

Crohn's disease patients were followed up with colonoileoscopy and evaluation of symptoms after 3 (range 1.5–4.5) months, 12 (range 7–15) months, 24 (range 21–27) months, and 36 (range 35–39) months. Twelve patients were unwilling to undergo endoscopy after only three months, and were studied first after one year. Colonoileoscopy occasionally failed to show the anastomosis (after one year in two cases, after two years in two cases, and three years in two cases) and data from these examinations are not included in the report. During follow up two patients underwent further operation – one resection of the ileocolic anastomosis at 20 months and one left sided hemicolectomy at 52 months.

Control patients were investigated with colonoileoscopy after 6 (range 3–8) months in 12 cases, 12 (9–13 months) in 14 cases, and nine patients had an examination after 24 (22–26) months.

The endoscopic investigations were performed by two of the authors (GO and KS), using an Olympus CF-10L or CF-IBW colonoscope. To confirm that the site of anastomosis had been adequately visualised, tissue for light microscopy was sampled immediately above and below the join. Intestinal inflammation was staged as in Table I.

In assessing the width of the anastomosis and the size of ulcers open biopsy forceps (width 8 mm:s) were used for comparison. Symptoms were assessed according to the Harvey-Bradshaw activity index.<sup>23</sup> Scores of  $\geq 4$  were classified as relapse.

#### STATISTICS

The two tailed Wilcoxon test corrected for ties, paired two tailed Wilcoxon test, and multiple regression were used for statistical analysis, with  $p < 0.05$  considered significant. Survival rates without anastomotic inflammation and symptomatic relapse are shown in the Figure, values of missing observations have been imputed using estimated transition probabilities for guidance.

#### Results

Inflammatory lesions were visualised endoscopically in the region of the anastomosis in all 42 Crohn's disease patients but in no control subjects ( $p < 0.01$ ). The endoscopic findings and the symptoms in Crohn's disease patients three months and one, two, and three years after operation are summarised in Table I. Inflammatory lesions appeared regularly above the anastomosis in the neoterminal ileum, and in patients without concomitant colitis the lesions were strictly confined to the neoterminal ileum. In no case did the inflammation overbridge the mucosal join. In patients with concomitant colitis, the inflammation was more pronounced above than below the anastomosis, where the inflammation was a part of the colitis in the remaining colon. After three months, 73% of the patients examined had ileal inflammation above the anastomosis, but only 33% had developed symptoms indicating relapse. After one year the corresponding figures were 93% and 37%, and after two years they were 94% and 82%. All of the 14 patients examined after three years showed ileal inflammation above the anastomosis and all but two had developed clinical relapse (86%). Thirteen patients operated on during the same period, but not participating in the study, have been followed up with regard to symptoms. This group showed no difference ( $p > 0.05$ ) in the rate of symptomatic relapse after three months 38% (5/13), one year 62% (8/13), two years 62% (8/13), and three years 69% (9/13).

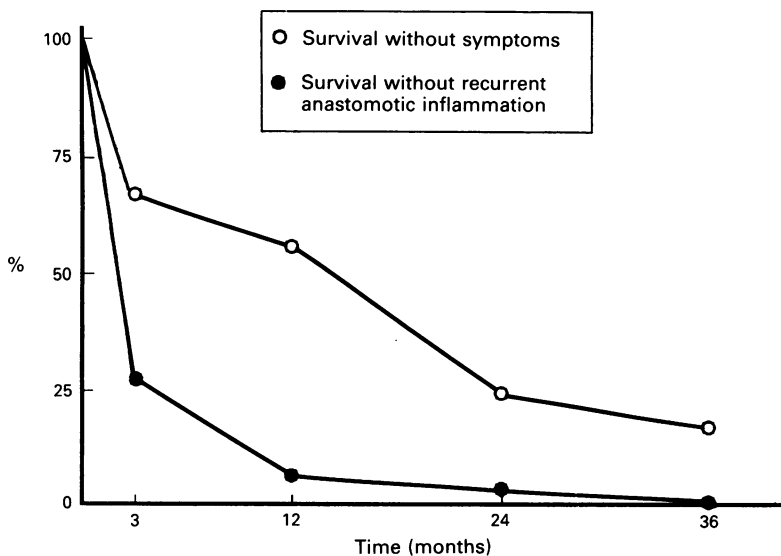
Endoscopic findings at one year follow up after grouping according to colitis, microscopic inflammation at the ileal resection margin, primary *v* further resection, short *v* long duration of disease (more or less than seven years), and perforating *v* non-perforating disease (according to Greenstein *et al*)<sup>24</sup> are shown in Table II. All of the six patients originally operated on for Crohn's colitis without ileal involvement developed ileal inflammation above the

TABLE I Endoscopic preanastomotic findings in the neoterminal ileum and cumulative symptomatic relapse at follow up after intestinal resection for Crohn's disease\*

	Interval to follow up endoscopy			
	3 mths (n=30)	1 yr (n=30)	2 yrs (n=17)	3 yrs (n=14)
Stage of inflammation:				
0 None visible	27% (8)	7% (2)	6% (1)	0
1 Aphthous ulcers	13% (4)	37% (11)	17% (3)	14% (2)
2 Ulcers <4 mm	33% (10)	27% (8)	41% (7)	0
3 Ulcers 4–8 mm	7% (2)	10% (3)	12% (2)	36% (5)
4 Ulcers >8 mm	20% (6)	17% (5)	12% (2)	43% (6)
5 Fibrotic stricture, diam 4–8 mm	–	3% (1)	12% (2)	7% (1)
6 Fibrotic stricture, diam <4 mm	–	–	–	–
Symptomatic relapse:†	33% (10)	37% (11)	82% (14)	86% (12)

\* Figures in brackets denote no of patients.

† Harvey-Bradshaw disease activity index  $\geq 4$ .



Survival without endoscopic anastomotic inflammation and symptomatic relapse in 42 patients with Crohn's disease followed up after ileocolic resection. The figure shows that anastomotic inflammation develops rapidly, is seen in all patients after three years, and precedes symptomatic relapse.

anastomosis. No differences were observed when considering each factor separately or when making comparisons that were adjusted for possible confounding of the variables under study by multiple regression ( $p > 0.05$ ). Of 13 cases with intraoperative ileoscopy, 11 were investigated after three months and all showed ileal inflammation above the anastomosis (stage 2 in five, stage 3 in one, and stage 4 in five cases).

Thirty patients had repeated investigations, and a time related progression to more severe intestinal inflammation was observed ( $p < 0.05$ ). Some 73% (22) showed evolution to a more severe stage, 20% remained unchanged, (6) and in 7% (2) the inflammatory stage became less severe between the first and last investigations. Between three months and one year, 60% (12/20) showed progression to more severe inflammation, 25% (5) were unchanged, and 15% (3) had less severe inflammation.

To date, seven patients have been investigated at all four follow up intervals. The individual course of ileal inflammation in these patients is given in Table III. There was progressive severity of the inflammation, from aphthous to larger ulcerations and to stricture.

### Discussion

In this study apparently radical resection for Crohn's disease was often followed soon afterwards by development of endoscopically visible inflammation at the site of the anastomosis. Three months after operation most patients with this inflammation were still in clinical remission but after 12 months, when anastomotic ulcerations were observed in 93% of the patients, 37% had developed symptomatic relapse. A time related progression from aphthae to larger ulcers and stricture was observed. This observed progression suggests that the staging proposed by us (Table I) that describes the sequential development of recurrent anastomotic inflammation may be useful for evaluating the severity of the intestinal inflammation.

The findings suggest that clinically evaluable

TABLE II Mean endoscopic stage\* of preanastomotic ileal inflammation one year after ileocolic resection in patients grouped according to variables

Variable	Mean endoscopic stage†
Colitis	1.9 (7)
No colitis	2.1 (23)
Microscopic inflammation at ileal margin	2.0 (5)
No marginal inflammation	2.0 (25)
Primary resection	2.2 (18)
Re-resection	1.8 (12)
Perforating disease	2.5 (6)
Non-perforating disease	1.9 (24)
Short disease duration‡	2.1 (15)
Long disease duration	2.0 (15)

\* See Table I; † (no of patients); ‡ less than seven years.

symptoms may not appear until the intestinal inflammation is fairly advanced. In Crohn's disease there may be an individual inflammatory burden, clinical evidence of which occurs only when a certain stage has been reached. Our rate of symptomatic relapse after surgery is higher than previously reported,<sup>1-16,19</sup> but the figures are not biased by the group of patients unwilling to participate as their rate did not differ from the investigated group. This is, however, the first study in which patients followed up after surgery were evaluated prospectively by a Crohn's disease activity index, and studies that do not use a formal activity index may underscore the symptoms. Our figures are more similar to those in other prospective studies in patients with apparently quiescent disease at entry, where a Crohn's disease activity index of more than 150 was considered to indicate relapse, a figure equivalent to the  $\geq 4$  Harvey-Bradshaw index in the present study.<sup>23</sup> Relapse rates after one and two years were reported as 28 and 45%<sup>25</sup> and 51 and 66%<sup>26</sup> respectively in these studies, while we found rates of 37 and 82%.

In our patients the incidence of anastomotic inflammation three months after operation was similar to previous reports,<sup>20,21</sup> but at subsequent endoscopies it was higher than in earlier studies (93-100 v 72-79%).<sup>18,19,27</sup> In early inflammation the lesions are often discrete and recognisable only to the trained eye. Our figures may reflect substantial experience in performing endoscopy in Crohn's disease patients, resulting in the larger number of endoscopically detected lesions.

Our data do not support the view that recurrence of inflammation should be more common in Crohn's colitis than in ileal disease. In previous studies recurrence was commonly defined as a need for further resection<sup>1,2,7,10,11,13,14</sup> and the high rates reported may be explained by exacerbation of inflammation in the remaining

TABLE III Individual course of preanastomotic ileal inflammation in seven patients endoscopically examined at all intervals after ileocolic resection

Case no	Endoscopic stage*			
	At 3 mths	At 1 yr	At 2 yrs	At 3 yrs
1	1	2	5	5
2	0	2	4	4
3	0	1	1	3
4	0	1	1	1
5	1	1	2	4
6	0	2	1	4
7	0	1	2	3

\* See Table I.

colon or rectum. Nor could we confirm previous data on higher recurrence rates after further resection than after primary resection.<sup>3,9-11</sup> Likewise, disease duration or a history of perforating disease had no influence on the postoperative evolution of inflammatory lesions.

We were not able to visualise any anastomotic lesions in the patients resected because of colonic neoplasm, and in these patients we found complete healing of the anastomosis. They were followed up at a mean of six months, but some were seen after three months. All Crohn's disease patients retained their early ileal ulcers between three months and one year, and most showed progression. It is, thus, unlikely that early ulceration at the site of the anastomosis is a sign of incomplete healing or a reaction to sutures in the anastomosis, it probably represents lesions specific for Crohn's disease.

In the patients with Crohn's disease, recurrent anastomotic inflammation was always observed at the ileal side of the join, and in patients without concomitant colitis recurrent inflammation was confined to the neoterminal ileum. It is noteworthy that recurrence of inflammation above the anastomosis also developed in colitis patients without primary ileal involvement. Moreover, inflammation above the anastomosis was observed regardless of the operative procedure (ileocaecal resection, colectomy, or anastomotic resection). In addition, most patients followed showed progression to more severe ileal inflammation. These results, and the finding that the distal ileum is the preferred site for primary involvement in Crohn's disease,<sup>2,28</sup> suggest that proximity to the colon may be harmful to the small intestine in this condition, and that colonic factors may contribute to small bowel inflammation. The low recurrence rate after colectomy with ileostomy,<sup>9,13</sup> as well as previous findings that glucocorticoid treatment improves endoscopic colonic inflammation but not ileal inflammation above the anastomosis, as recently reported by us,<sup>29</sup> underline the notion of inflammatory factors in the anastomotic area essentially affecting the distal ileum.

It has been suggested that inflammatory lesions found soon after intestinal resection represent residual inflammation not removed at surgery.<sup>21</sup> Our series, however, comprised only patients in whom ileal resection had been performed in tissue free from macroscopic disease. In the last 13 patients intraoperative ileoscopy further confirmed the absence of inflammation in the neoterminal ileum anastomosed to the colon. We had no problem scrutinising the distal ileum at either intraoperative endoscopy or when inspecting the resection margin. Our high frequency of postoperative lesions indicates a high sensitivity in detecting minor lesions and may to some extent validate the intraoperative investigation – minor lesions were not easily overlooked. Our findings agree with two previous studies. In one the patients had their distal ileum everted and inspected at the time of resection, and after six months 21 of 22 developed ileal ulcerations.<sup>19</sup> In another, intraoperative ileoscopy was performed to confirm that 40 cm of the distal ileum was free from inflammatory lesions, and when followed

28 of 34 investigated patients had developed anastomotic lesions.<sup>30</sup> It is arguable that early ulceration could develop from residual microscopic ileal lesions. Although microscopy showed inflammation at the ileal resection margin in a few cases in our series, this did not seem to be an important factor, as early endoscopic lesions could develop independently of these findings (Table II). Several earlier studies also indicated that residual microscopic inflammation at surgery did not influence the outcome.<sup>31,32</sup> The inflammatory lesions found in our patients as early as three months postoperatively are more likely to represent true fresh inflammation.

The question of recrudescence or recurrence is, in our view, a matter of semantics. Although the intestinal inflammation most often seems to be regional, several studies indicate that Crohn's disease is a panenteric disease, with morphological and biochemical abnormalities in non-inflamed mucosa also.<sup>33-36</sup> A recent study also showed that a diffuse small intestinal inflammation was commonly encountered when endoscopy of the whole of the small bowel was performed intraoperatively.<sup>37</sup> The anastomotic inflammatory lesions occurring soon after apparently radical ileocolic resection may be regarded as fresh inflammation or as recrudescence of a diseased mucosa prone to develop intestinal inflammation, or both.

The concept of 'recurrence after surgery' requires re-evaluation in Crohn's disease. On the one hand, our data favour the concept that early anastomotic ileal inflammation is new (true recurrent) inflammation, but on the other such inflammation seems to be initiated almost immediately in most cases, and in most patients intestinal inflammation is present chronically. 'Clinical recurrence' may be used to denote overt disease, but 'recurrence' in the conventional sense of newly developed disease after an interval of health is inappropriate in the light of current data.

In summary, we found that ileal inflammation above the anastomosis is endoscopically detectable in many patients soon after resection for Crohn's disease, and that these lesions progress from aphthae to larger ulcers and stricture. Ulceration precedes symptoms, which do not occur until the intestinal inflammation has reached a certain stage. Anastomotic lesions occurring soon after intestinal resection represent new inflammation specific for Crohn's disease and not incomplete anastomotic healing or residual disease. Despite apparently radical resection with initial clinical remission, Crohn's disease is an ongoing process in which intestinal inflammation is permanently present.

This study was supported by grants from Östergötlands County Council, Swedish Society of Medicine, and Swedish Society for Medical Research.

- 1 Barber KW, Waugh JM, Beahrs OH, Sauer WG. Indications for and the results of the surgical treatment of regional enteritis. *Ann Surg* 1962; 156: 472-82.
- 2 Farmer RG, Hawk WA, Turnbull RB. Clinical patterns in Crohn's disease: a statistical study of 615 cases. *Gastroenterology* 1975; 68: 627-35.
- 3 Lennard-Jones JE, Stadler GE. Prognosis after resection of chronic regional ileitis. *Gut* 1967; 8: 332-6.
- 4 De Dombal FT, Burton I, Goligher JC. Recurrence of Crohn's disease after primary excisional surgery. *Gut* 1971; 12: 519-27.

- 5 Lindhagen T, Ekelund G, Leandroer L, Hildell J, Lindström C, Wenckert A. Crohn's disease in a defined population. Course and results of surgical treatment. 1 Small bowel disease. *Acta Chir Scand* 1983; **149**: 407-13.
- 6 Hellberg G, Hulten L, Rosengren C, Ahren C. The recurrence rate after primary excisional surgery for Crohn's disease. *Acta Chir Scand* 1980; **146**: 435-43.
- 7 Whelan G, Farmer RG, Fazio VW, Goormastic M. Recurrence after surgery in Crohn's disease. Relationship to location of disease (clinical pattern) and surgical indication. *Gastroenterology* 1985; **88**: 1826-33.
- 8 Sachar DB, Wolfson DM, Greenstein AJ, Goldberg J, Styczynski R, Janowitz HD. Risk factors for postoperative recurrence of Crohn's disease. *Gastroenterology* 1983; **85**: 917-21.
- 9 Hellers G. Crohn's disease in Stockholm County 1955-1974. A study of epidemiology results of surgical treatment and longterm prognosis. *Acta Chir Scand* 1979; **145**: (suppl 490) 1-84.
- 10 Mekhjian HS, Switz DM, Watts HD, Deren JJ, Katon RM, Beman FM. National Cooperative Crohn's disease study: factors determining recurrence of Crohn's disease after surgery. *Gastroenterology* 1979; **77**: 907-13.
- 11 Greenstein AJ, Sachar DB, Pasternack BS, Janowitz HD. Reoperation and recurrence in Crohn's colitis and ileocolitis. Crude and cumulative rates. *N Engl J Med* 1975; **293**: 685-90.
- 12 Chardavoyne R, Flint GW, Pollack S, Wise L. Factors affecting recurrence following resection for Crohn's disease. *Dis Colon Rectum* 1986; **29**: 495-502.
- 13 Kirsner JB. The local and systemic complications of inflammatory bowel disease. *JAMA* 1979; **242**: 1177-83.
- 14 Fasth S, Hellberg R, Hulten L, Åhren C. Site of recurrence, extent of ileal disease and magnitude of resection in primary and recurrent Crohn's disease. *Acta Chir Scand* 1981; **147**: 569-76.
- 15 Himel HS, Belliveau P. Prognosis after surgical treatment for granulomatous enteritis and colitis. *Am J Surg Gastroenterol* 1981; **142**: 347-9.
- 16 Frikker MJ, Segall MM. The resectional reoperation rate for Crohn's disease in a general community hospital. *Dis Colon Rectum* 1983; **26**: 305-9.
- 17 Clavdetscher P, Deyhle P. Diagnosis of Crohn's recurrence after surgery. *Endoscopy* 1975; **7**: 27-9.
- 18 Rutgeerts P, Geboes K, Vantrappen G, Kerremans R, Coenegrachts JL, Coremans G. Natural history of recurrent Crohn's disease at the ileocolonic anastomoses after curative surgery. *Gut* 1984; **25**: 665-72.
- 19 Rutgeerts P, Geboes K, Vantrappen G, Beyls J, Kerremans R, Hiele M. Predictability of the postoperative course of Crohn's disease. *Gastroenterology* 1990; **99**: 956-62.
- 20 Tytgat GNJ, Nio CY, Mulder CJJ. Le rôle de la coloscopie dans l'évaluation post-opératoire de la maladie de Crohn. *Acta Endosc* 1987; **17**: 121-7.
- 21 Tytgat GNJ, Mulder CJJ, Brummelkamp WH. Endoscopic lesions in Crohn's disease early after ileocecal resection. *Endoscopy* 1988; **20**: 260-2.
- 22 Morson BC. Histopathology of Crohn's disease. *Proc R Soc Med* 1968; **61**: 79-81.
- 23 Harvey RF, Bradshaw JM. A simple index of Crohn's disease activity. *Lancet*; 514.
- 24 Greenstein AJ, Lachman P, Sachar DB, Springhorn J, Heimann T, Janowitz HD, et al. Perforating and non-perforating indications for repeated operations in Crohn's disease: Evidence for clinical forms. *Gut* 1988; **29**: 588-592.
- 25 Summers RW, Switz DM, Sessions J Jr, Becketl JM, Best WR, Kern F Jr, et al. National Cooperative Crohn's Disease Study: results of drug treatment. *Gastroenterology* 1979; **77**: 847-69.
- 26 Malchow H, Ewe K, Brandes JW, Goebell H, Ehms H, Sommer H, et al. European Cooperative Crohn's Disease Study (ECCDS): results of drug treatment. *Gastroenterology* 1984; **86**: 249-66.
- 27 Gabbert HE, Ewe K, Singe CC, Junginger T, Gerharz CD, Köther K. Frührezidiv des Morbus Crohn nach "kurativer" Ileocaecalresektion. *Dtsch Med Wochenschr* 1990; **115**: 447-51.
- 28 Mekhjian HS, Switz DM, Melnyk CS, Rankin GB, Brooks RK. Clinical features and natural history of Crohn's disease. *Gastroenterology* 1979; **77**: 898-906.
- 29 Olaison G, Sjö Dahl R, Tagesson C. Glucocorticoid treatment in ileal Crohn's disease: relief of symptoms but not of endoscopically viewed inflammation. *Gut* 1990; **31**: 325-8.
- 30 Lescut D, Vanco D, Colombel JF, Bonnière P, Quandalle P, Lecomte-Houcke M, et al. Influence des lésions endoscopiques d'amont sur les récurrences endoscopiques anastomotiques (rea) au cours de la maladie de Crohn (MC). *Gastroenterol Clin Biol* 1990; **14**: A20.
- 31 Pennington L, Hamilton S, Bayless TM, Cameron JL. Surgical management of Crohn's disease - Influence of disease at margin of resection. *Ann Surg* 1980; **192**: 311-8.
- 32 Heuman R, Boeryd B, Bolin T, Sjö Dahl R. The influence of disease at the margin of resection on the outcome of Crohn's disease. *Br J Surg* 1983; **70**: 519-21.
- 33 Cooper BT, Lucas ML, Lei FH, Blair JA, Cooke WT. Abnormal jejunal surface pH in Crohn's disease-new evidence that Crohn's disease is a diffuse lesion of the gastrointestinal tract. *Gut* 1977; **18**: A423.
- 34 Dunne WT, Cooke WT, Allan RN. Enzymatic and morphometric evidence for Crohn's disease as a diffuse lesion of the gastrointestinal tract. *Gut* 1977; **18**: 290-4.
- 35 Olaison G, Sjö Dahl R, Tagesson C. Decreased gastrointestinal absorption of peroral polyethyleneglycol (PEG 1000) in Crohn's disease-A sign of jejunal abnormality. *Acta Chir Scand* 1987; **153**: 373-7.
- 36 Rickert RR, Carter HW. The early ulcerative lesions of Crohn's disease: correlative light-and scanning electron-microscopic studies. *J Clin Gastroenterol* 1980; **2**: 11-9.
- 37 Lescut D, Colombel JF, Cortot A, Vanco D, Bonnière P, Quandalle P, et al. Peroperative small bowel endoscopy in Crohn's disease. *Eur J Gastroenterol Hepatol* 1990; **2** (suppl 1): S59.