

Expression of mutant p53 protein in hepatocellular carcinoma

J D Collier, M Carpenter, A D Burt, M F Bassendine

Abstract

p53 mutations are a common genetic finding in hepatocellular carcinoma from areas of high aflatoxin exposure. Recent small studies have shown that p53 gene mutations may be less common in areas with a low prevalence of hepatocellular carcinoma such as Great Britain. The protein product of mutant p53 can be detected immunohistochemically because of its longer half life in comparison with native protein. This study used a novel monoclonal antibody DO-7, raised against recombinant p53 and effective in routinely processed biopsy specimen tissue, to detect the mutant protein in a series of 45 cases of hepatocellular carcinoma occurring in white subjects resident in the United Kingdom. Focal nuclear labelling was seen in four cases (9%); surrounding cirrhotic tissue in one of these was negative for p53 expression. This study shows that p53 mutations are a rare event in hepatocarcinogenesis in Great Britain, an area of low aflatoxin exposure, and supports the concept of geographical variations in the cause and pathogenesis of hepatocellular carcinoma.

(Gut 1994; 35: 98-100)

The tumour suppressor gene p53 is located on the short arm of chromosome 17.¹ It encodes a 53 kD nuclear phosphoprotein, which is expressed in low values in normal cells and has the ability to complex with viral and cellular antigens.² Its precise function remains to be fully elucidated but it probably participates in controlling cell proliferation as values are influenced by the cell cycle and microinjection of antibodies to p53 prevent cells entering S phase.^{3,4}

Initial reports suggested that p53 values were raised in many human tumour derived cell lines in contrast with normal cells, but further work showed the protein to be a mutant form.^{2,5} The ability to detect mutant p53 in malignant cells is now related to its established increased half life, as a result of changed conformation.^{6,7} Mutant p53 has changed cell regulatory properties; it can transform cells in culture in the presence of low values of wild type p53 possibly by binding to and inhibiting the native (wild type) protein, and in the absence of wild type p53, it has been shown to stimulate cell growth.⁸

The genetic basis for mutant protein has received intense investigation and mutations of the p53 gene have been discovered to be a common change found in human cancer.¹ In hepatocellular carcinoma a mutational hot spot at codon 249 has been reported in a substantial proportion of tumours from areas of aflatoxin

exposure, and this contrasts with the less specific pattern of mutations reported in other tumours.^{1,9} These mutations are G to T transversions and it is postulated that they are related to aflatoxin damage as this carcinogen is known to bind to guanine in DNA causing G to T mutations.¹⁰ This contrasts with the infrequent finding of p53 mutations in hepatocellular carcinoma from areas of low prevalence; these mutations are neither confined to codon 249 nor to GT transversions.^{11,12}

The biological significance of these various point mutations is, however, far from clear. Not all point mutations have the same functional effect on p53 and this includes the inability of some mutations to stabilise the protein.¹³ As it is the mutant protein that ultimately affects cell regulation and thus the malignant phenotype it is important that the presence of mutant protein is assessed together with genetic changes in the p53 gene.

We have therefore examined a series of cases of hepatocellular carcinoma in Great Britain immunohistochemically for the presence of mutant p53 protein.

Patients and methods

PATIENTS

Formalin fixed paraffin wax embedded archival material was available for study from 45 cases of hepatocellular carcinoma seen at the Freeman Hospital. Clinical details were available from the medical records on all patients and survival data in 39 cases. The mean age of the patients was 70 (range 43-84) with a male:female ratio of 2:1. Seventy seven per cent of patients had biopsy proved cirrhosis and serological markers of hepatitis B infection were present in 12 (27%) cases, three patients had HBsAg and in nine cases HBcAb alone was present.

METHODS

Sections of 3 µm were cut from paraffin blocks and endogenous peroxidase was blocked with 0.5% hydrogen peroxide in methanol. p53 was identified with two primary antibodies raised against recombinant p53 protein CM-1, and DO-7. CM-1 is a rabbit polyclonal antibody, raised against human wild type p53 produced in a bacterial expression system using a full length p53 cDNA, and used at a dilution of 1/1000.¹⁴ The monoclonal antibody DO-7, used at a dilution of 1/100, is also raised against recombinant human wild type p53 and has been shown to be specific for the denaturation resistant epitope at the N terminus of the protein.¹⁵ Incubation with primary antibody was performed overnight at

Departments of Medicine
J D Collier
M F Bassendine

and Pathology,
University of Newcastle
upon Tyne
M Carpenter
A D Burt

Correspondence to:
Dr M F Bassendine,
Department of Medicine, The
Medical School, Framlington
Place, Newcastle upon Tyne
NE2 4HH.

Accepted for publication
12 May 1993

Figure 1A: intense staining with monoclonal antibody DO-7 within nuclei of a well differentiated hepatocellular carcinoma; B: positive nuclear staining with anti-p53 polyclonal antibody CM-1 in malignant cells; note greater background cytoplasmic immunoreactivity with this antibody compared with DO-7.

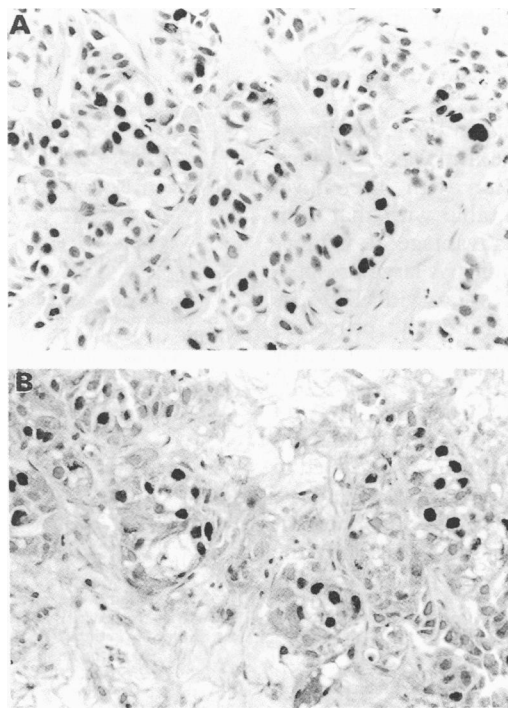
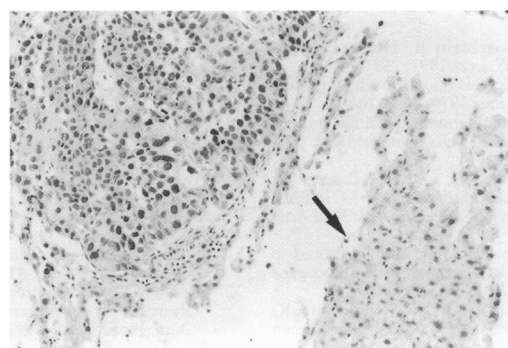


Figure 2: Expression of mutant p53 in malignant hepatocytes as shown by nuclear immunoreactivity with monoclonal antibody DO-7 but not in hepatocytes of adjacent cirrhotic tissue (arrowed).



4°C. Immunostaining was detected with an avidin-peroxidase system; 3'3 diaminobenzidine was used as the chromagen.

A malignant fibrohistiosarcoma of the liver, shown to have a mutation at codon 248 of the p53 gene, was used as a positive control (data not shown). Negative controls consisted of replacement of the primary antibody by buffer alone.

Results

With the monoclonal antibody DO-7 immunolabelling was detected in 4/45 (9%) tumours (Fig 1A). The staining was focal, affecting less than 10% of the malignant cells, but of uniform intensity and was confined to the nucleus except in those cells undergoing mitosis. Immunostaining with the polyclonal antibody CM-1 was also only seen in the four DO-7 positive tumours with a similar focal nuclear distribution. Back-

ground staining was higher, however, using CM-1 compared with DO-7 (Fig 1B). In the four positive hepatocellular carcinoma tissue blocks surrounding cirrhotic tissue was present in one and was negative for p53 (Fig 2). In 10 p53 negative tumours surrounding cirrhotic tissue was also negative.

The Table shows the clinical features of the four cases expressing mutant p53. The median survival of these cases was six weeks (range 1-60), which compares with a median survival of 10 weeks (range 1-96) for those patients whose tumours did not express mutant p53.

Discussion

Although the frequency of p53 gene mutations in hepatocellular carcinoma varies geographically, from 10% in low incidence areas to 50% in high incidence areas, it is still unknown whether this variation is also reflected in differences in expression of mutant protein and cell growth.^{9 11 12 16-19} Native (wild type) p53 protein cannot normally be detected immunohistochemically because of its short half life.^{7 20} Many p53 gene mutations result in expression of protein with a prolonged half life and resulting cellular accumulation.²¹ The ability to detect p53 expression immunohistochemically thus usually occurs when the protein is mutant, but also has been shown to sometimes reflect stabilisation of native protein by interaction with cellular and viral (for example SV40) proteins.^{2 22 23} More recently abnormal expression of wild type p53 protein has been found in normal cells of a cancer family patient, implying impaired degradation.²⁴

In this study expression of p53 was shown in 9% of tumours. Other studies have shown there is overall a good correlation between p53 gene mutations and detectable protein immunohistochemically.²⁵⁻²⁸ In a previous study we reported 19 cases of hepatocellular carcinoma, two of which (16%) had p53 gene mutations, one of which was detected immunohistochemically with the polyclonal antibody CM-1.¹¹ Combining our two studies five out of 64 (8%) of cases of hepatocellular carcinoma in Great Britain express mutant p53 protein.

Not only was expression of mutant protein uncommon in our series but in those cases where it did occur the distribution was focal. Values of native p53 protein are known to vary throughout the cell cycle, accumulating during G₁ and falling after cell division.²⁹ Mutant p53 protein may also be regulated by the cell cycle and focal distribution may reflect this. A heterogenous pattern of p53 gene mutations, however, has also been shown in nodules from multiple hepatocellular carcinoma in Japanese patients, suggesting a multifocal rather than clonal origin for the tumour in most patients.³⁰ The absence of staining in cirrhotic tissue adjacent to tumour expressing mutant p53 is consistent with a role for the protein in hepatocarcinogenesis. It is of interest that in gastric cancer expression of p53 mutant protein has been considered to be a poor prognostic indicator.³¹ In this retrospective study it was not possible to evaluate the prognostic significance of p53 expression in hepatocellular carcinoma but preliminary evidence

Clinical features of patients with hepatocellular carcinoma expressing immunoreactive p53

Age	60	76	77	44
Sex	M	M	M	F
Aetiology	Cryptogenic cirrhosis	No cirrhosis	Cryptogenic cirrhosis	Hepatitis B cirrhosis
HBsAg	Negative	Negative	Negative	Positive
αFP (IU/l)	<10	670	90 000	92 000
Survival (weeks)	60	1	6	?

HBsAg=hepatitis B antigen, αFP=α fetoprotein.

suggests that it may contribute to an aggressive tumour phenotype.³² A prospective study is now necessary to investigate the value of p53 expression as a prognostic indicator.

In this study we have shown the feasibility of detecting mutant p53 in paraffin wax embedded material. Immunoreactivity with the novel reagent DO-7 was comparable with that seen with CM-1 but with the advantage of significantly less background staining. A large prospective analysis of p53 expression with DO-7 is therefore possible with routinely processed paraffin wax embedded biopsy material rather than frozen tissue.³²

This study has confirmed that the low frequency of p53 gene mutations seen in hepatocellular carcinoma in Great Britain is reflected in a similar frequency of mutant protein expression. The geographical difference in aberrant p53 expression suggest differences in the molecular mechanisms of hepatocarcinogenesis with p53 being less important in low incidence areas such as Great Britain.

Dr J D Collier is supported by the North of England Cancer Research Campaign.

The data described in this paper have previously been published in abstract form in *J Hepatol* 1992; 16 (suppl 1): S28.

- 1 Hollstein M, Sidransky D, Vogelstein B, Harris CC. p53 mutations in human cancers. *Science* 1991; 253: 49-53.
- 2 Lane DP, Crawford LV. T antigen is bound to a host protein in SV40 transformed cells. *Nature* 1979; 278: 261-3.
- 3 Reich NC, Levine AJ. Growth regulation of a cellular tumour antigen, p53, in nontransformed cells. *Nature* 1984; 308: 199-201.
- 4 Mercer WE, Nelson D, DeLeo AB, Old LJ, Baserga R. Microinjection of monoclonal antibody to p53 inhibits serum-induced DNA synthesis in 3T3 cells. *Proc Natl Acad Sci USA* 1982; 79: 6309-12.
- 5 Hinds PW, Finlay CA, Levine AJ. Mutation is required to activate the p53 gene for cooperation with the ras oncogene and transformation. *J Virol* 1989; 63: 739-46.
- 6 Hinds PW, Finlay CA, Quarbin RS, Baker SJ, Fearon GR, Vogelstein B *et al*. Mutant p53 DNA clones from human colon carcinomas cooperate with ras in transforming primary rat cells: a comparison of the 'hot spot' mutant phenotypes. *Cell Growth Differ* 1990; 1: 571-80.
- 7 Gannon JV, Greaves R, Iggo R, Lane DP. Activating mutations in p53 produce a common conformational effect. A monoclonal antibody specific for the mutant form. *EMBO J* 1990; 9: 1595-602.
- 8 Levine AJ, Momand J, Finlay CA. The p53 tumour suppressor gene. *Nature* 1991; 351: 453-6.
- 9 Ozturk M, Bressac B, Puisieux A, Kew M, Volkmann M, Bozcail S, *et al*. p53 mutation in hepatocellular carcinoma after aflatoxin exposure. *Lancet* 1991; 338: 1356-9.
- 10 Foster PL, Eisenstadt E, Miller JH. Base substitution mutations induced by metabolically activated aflatoxin B1. *Proc Natl Acad Sci USA* 1983; 80: 2695-8.
- 11 Challen C, Lunec J, Warren W, Collier J, Bassendine MF. Analysis of the p53 tumour suppressor gene in human hepatocellular carcinomas from Britain. *Hepatology* 1992; 12: 1362-6.
- 12 Kress S, Jahn U-R, Buchmann A, Bannasch P, Schwarz M. p53 mutations in human hepatocellular carcinomas from Germany. *Cancer Res* 1992; 52: 3220-3.
- 13 Malkin D, Li FP, Strong LC, Fraumeni JF, Nelson CE, Kim D, *et al*. Germ line p53 mutations in a familial syndrome of breast cancer, sarcomas and other neoplasms. *Science* 1990; 250: 1233-8.
- 14 Bartek J, Bartkova J, Vojtesek B, Staskova Z, Lukas J, Rejthar A, *et al*. Aberrant expression of the p53 oncoprotein is a common feature of a wide spectrum of human malignancies. *Oncogene* 1991; 6: 1699-703.
- 15 Vojtesek B, Bartek J, Midgley CA, Lane DP. An immunohistochemical analysis of human p53: new monoclonal antibodies and epitope mapping using recombinant p53. *J Immunol Methods* 1992; 151: 237-44.
- 16 Bressac B, Kew M, Wands J, Ozturk M. Selective G to T mutations of p53 gene in hepatocellular carcinoma from southern Africa. *Nature* 1991; 350: 429-31.
- 17 Hsu IC, Metcalf RA, Sun T, Welch JA, Wang NJ, Harris CC. Mutational hotspot in the p53 gene in human hepatocellular carcinomas. *Nature* 1991; 350: 427-8.
- 18 Hosono S, Lee C-S, Chou M-J, Yang C-S, Shih C. Molecular analysis of the p53 alleles in primary hepatocellular carcinomas and cell lines. *Oncogene* 1991; 6: 237-43.
- 19 Scorsone KA, Zhou Y-Z, Butel JS, Slagle BL. p53 mutations cluster at codon 249 in Hepatitis B virus-positive hepatocellular carcinomas from China. *Cancer Res* 1992; 52: 1635-8.
- 20 Oren M, Maltzman W, Levine AJ. Post translocational regulation of the 54K cellular tumour antigen in normal and transformed cells. *Mol Cell Biol*; 1: 101-10.
- 21 Finlay CA, Hinds PW, Tan T-H, Eliyahu D, Oren M, Levine AJ. Activating mutations for transformation by p53 produce a gene product that forms a hsc 70 - p53 complex with an altered half life. *Mol Cell Biol* 1988; 8: 531-9.
- 22 Werness BA, Levine AJ, Howley PM. Association of human papilloma virus types 16 and 18 E6 proteins with p53. *Science* 1990; 248: 76-9.
- 23 Lehman TA, Bennett WP, Metcalf RA, Welsh JA, Ecker J, Modali RV *et al*. p53 mutations, ras mutations, and p53-heat shock 70 protein complexes in human lung carcinoma cell lines. *Cancer Res* 1991; 51: 4090-6.
- 24 Barnes DM, Hanby AM, Gillett CE, Mohammed S, Hodgson S, Bobrow LG, *et al*. Abnormal expression of wild type p53 protein in normal cells of a cancer family patient. *Lancet* 1992; 340: 259-63.
- 25 Bartek J, Iggo R, Gannon J, Lane DP. Genetic and immunohistochemical analysis of mutant p53 in human breast cancer cell lines. *Oncogene* 1990; 5: 893-9.
- 26 Iggo R, Gatter K, Bartek J, Lane D, Harris AL. Increased expression of mutant forms of p53 oncogene in primary lung cancer. *Lancet* 1990; 335: 675-9.
- 27 Davidoff AM, Humphrey PA, Iglehart JD, Marks JR. Genetic basis for p53 overexpression in human breast cancer. *Proc Natl Acad Sci USA* 1991; 88: 5006-10.
- 28 Rodrigues NR, Rowan A, Smith MEF, Kerr IB, Bodmer WF, Gannon JV, *et al*. p53 mutations in colorectal cancer. *Proc Natl Acad Sci USA* 1990; 87: 7555-9.
- 29 Bischoff JR, Friedman PN, Marshak DR, Prives C, Beach D. Human p53 is phosphorylated by p60-cdc2 and cyclin B-cdc2. *Proc Natl Acad Sci USA* 1990; 87: 4766-70.
- 30 Oda T, Tsuda H, Scarpa A, Sakamoto M, Hirohashi S. Mutation pattern of the p53 gene as a diagnostic marker for multiple hepatocellular carcinoma. *Cancer Res* 1992; 52: 3674-8.
- 31 Martin HM, Filipe MI, Morris RW, Lane DP, Silvestre F. p53 expression and prognosis in gastric carcinoma. *Int J Cancer* 1992; 50: 859-86.
- 32 Laurent-Puig P, Flejou J-F, Fabre M, Bedossa P, Belghiti J, Gayral F *et al*. Overexpression of p53: a rare event in a large series of white patients with hepatocellular carcinoma. *Hepatology* 1992; 16: 1171-5.