

Gut

Leading article – Hepatology series

Liver cell death: patterns and mechanisms

This review discusses the causes and mechanisms of hepatocyte cell death in normal and diseased states, and briefly describes the responses of the liver to the inflicted damage. In tissues such as the epidermis and gastrointestinal mucosa, cells proliferate, differentiate, and die in a highly ordered and predictable fashion.¹ In these tissues, cells destined for terminal differentiation proceed through a short series of cell divisions to amplify their numbers, before permanently decycling from the proliferative cell cycle and migrating into an anatomically distinct differentiated compartment, which heralds their imminent demise. Such a tissue hierarchy is a feature of the so called continually renewing tissues such as gut, epidermis, and bone marrow, while liver with its almost negligible rate of cell proliferation has traditionally been classified as a conditionally renewing population – a population of essentially proliferatively quiescent cells, which nevertheless retains the ability to re-enter the proliferative cell cycle after a stimulus such as cell damage. The wisdom, however, of placing the liver in the conditionally renewal category has recently been challenged by Zajicek *et al.*² Though the proportion of rat hepatocytes labelled at one hour after a single injection of tritiated thymidine will be small (<1%), they could plot the distribution of these labelled cells as a function of the distance between the edge of the portal space and the terminal hepatic venous radicles. At one hour after injection, labelled hepatocytes were situated, on average, 266 µm downstream from a terminal portal tract, but if rats were left for five weeks after injection it was claimed that the labelled cells were now on average 313 µm away from a terminal portal tract. Thus it was concluded that liver cells streamed, travelling at a speed of about 1 cell position/5 weeks as they migrated from the periportal area towards the terminal hepatic veins. At the end of their travels it was envisaged that senescent (terminally differentiated) hepatocytes undergo apoptosis and are phagocytosed by neighbouring cells: a failure of this process to keep pace with anabolic steroid induced hyperplasia has been invoked to explain the accumulation of hepatocytes between the endothelium and supporting collagen fibres of the hepatic veins.³ Hard evidence for the apoptosis of perivenular hepatocytes as a crucial component in the maintenance of the steady state in a hepatic renewal system is still lacking, and the depiction of such a renewal system as being like ‘the spokes of a wheel’ (the hepatic plates) down which hepatocytes migrate is something of an oversimplification given the honeycomb arrangement of the hepatic muralium.⁴

If in normal adulthood hepatic cell death is not a prominent feature, then likewise it is not a significant factor in

human liver morphogenesis. Substantial cell death is part and parcel of normal embryonic development,⁵ yet the human liver arising as an outgrowth of endodermal epithelium from the primitive foregut, is conspicuous for its lack of overt cell death during morphogenesis.

Cell death: necrosis and apoptosis

In 1980, Wyllie *et al.*⁶ proposed a new classification of cell death based on morphological criteria, which separated the degradative reactions that occur after cell death resulting from generally severe perturbations (necrosis), from a gene directed programme of cell death (apoptosis) caused by both physiological and pathological conditions. Generally speaking, necrosis follows from severe environmental trauma, which either directly damages the plasma membrane (complement induced cytolysis) or interferes with the generation of energy by blocking the synthesis of ATP (anoxia, ischaemia). As a consequence, energy dependent ion pumping mechanisms are impaired causing various ions to move down their concentration gradients across the plasma membrane; notably an entry of sodium and calcium and a loss of potassium. These ion movements result in a loss of plasma membrane volume control, causing an influx of water into the cell (cell and organelle oedema, formerly called hydropic degeneration), manifest as acute cell swelling or ‘cell ballooning’ (Fig 1). Initially such changes are reversible, but prevailing adverse conditions send the cell on a downward spiral particularly with the sustained increased concentrations of cytosolic calcium causing disruption of the cytoskeleton and activating membrane located degradative phospholipases and proteases.⁷ Together with a switch to anaerobic glycolysis, a decrease in intracellular pH, and a reduction of macromolecular synthesis, the affected cell dies with the accompanying rupture of organelles and the plasma membrane, manifest by light microscopy as coagulative necrosis (Fig 2). On the other hand, apoptosis (apo^o-pto^o-sis: Greek ‘dropping off’, as leaves from trees),⁸ is not a passive phenomenon but is gene directed, usually requiring ongoing protein synthesis. Apoptosis is not new to liver pathology, but terms such as ‘shrinkage necrosis’, ‘acidophil bodies’, and ‘Councilman bodies’ have undoubtedly been used to describe what the modern histopathologist would regard as apoptotic hepatocytes. The apoptotic cell death pathway has been conserved through much of evolution,⁹ and though the activation of a non-lysosomal endonuclease, which cleaves double stranded DNA into oligonucleosome length fragments is considered a key event in many apoptotic cells,¹⁰

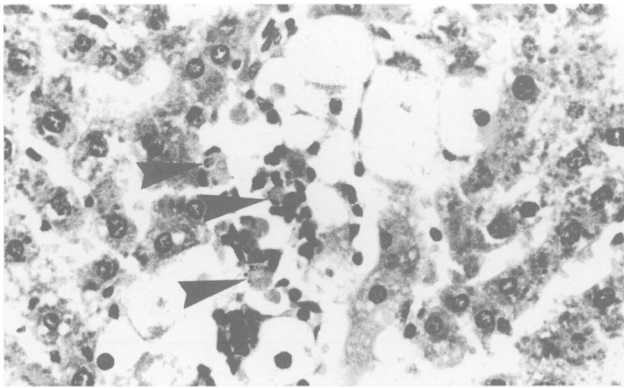


Figure 1: An admixture of ballooning and small acidophilic (apoptotic) (arrows) hepatocytes in the perivenular area caused by paracetamol.

degradation of chromatin at a higher level of organisation may be a more proximate event.¹¹

Viewed by light microscopy, the difference between apoptotic cell death and necrosis is not always apparent. The large lakes of centrilobular necrosis caused by the archetypal hepatotoxin carbon tetrachloride (CCl₄) present no problem in recognition (Fig 2), but when cell death occurs discretely, affecting single cells (Fig 1), how do we know if it is single cell necrosis or apoptosis? In the classic *in vitro* model of apoptosis in which thymocytes from young rats are exposed to glucocorticoids, large numbers of apoptotic cells can be harvested, and the 'ladder pattern' of degraded DNA products can be readily shown.¹⁰ To isolate apoptotic hepatocytes from an intact liver, and in sufficient numbers for DNA analysis would be a difficult task. The most practicable and reliable way of unequivocally distinguishing between apoptosis and necrosis is by transmission electron microscopy. Cell blebbing and organelle disruption are features of

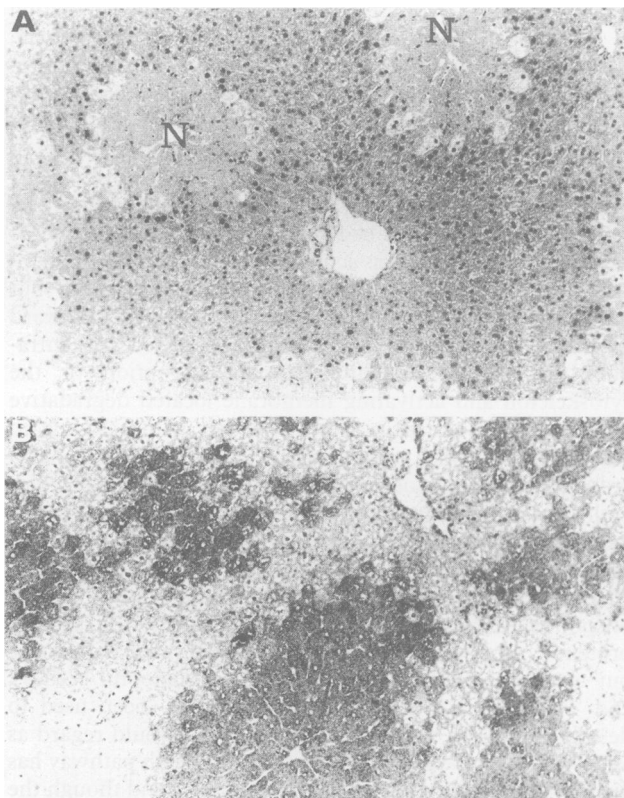


Figure 2: Centrilobular coagulative necrosis (N) surrounded by a cuff of ballooned hepatocytes (A) and (B) cytochrome P450 immunoreactivity located in the same area.

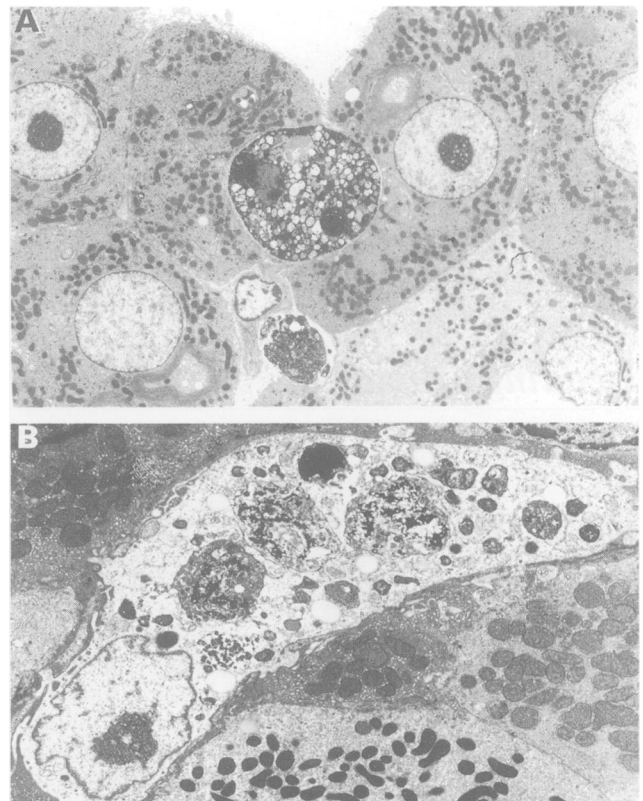


Figure 3: Electron micrographs illustrating how apoptotic bodies can be phagocytosed by both hepatocytes (A) and (B) Kupffer cells after cyproterone acetate treatment had finished.

necrotic cells,¹² while cell condensation and fragmentation into a number of membrane bound, 'apoptotic bodies', initially containing well preserved organelles and often, condensed chromatin, are hallmarks of apoptotic cell death (Fig 3). A not uncommon finding is the apparent coincidence of cell ballooning and shrunken dead cells, which, if the latter were found alone, we would assume to be apoptotic hepatocytes (Fig 1). Cell ballooning is a forerunner of necrosis, so in response to the same stimulus do some cells succumb to necrosis while others choose an apoptotic cell death? Much effort is being spent on developing a histological 'marker' of apoptosis, and Fesus *et al*^{13,14} describe how tissue transglutaminase activity is enhanced in hepatocytes *in vitro*, such activity can be detected immunohistochemically using an antihuman tissue transglutaminase antibody.

Very recently the task of identifying isolated apoptotic cells has been made easier by the development of a technique in which tissue sections are incubated with an appropriately labelled nucleotide triphosphate in the presence of DNA

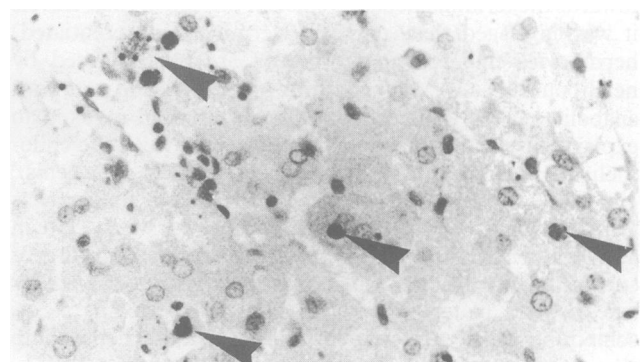


Figure 4: Widespread diffuse apoptosis caused by galactosamine, which can be readily visualised by *in situ* end labelling (arrows).

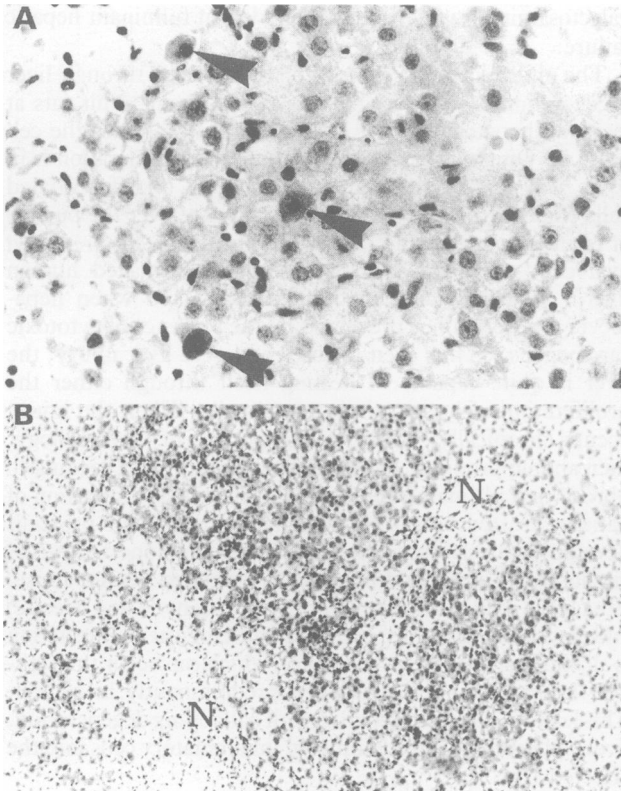


Figure 5: Viral hepatitis can cause both apoptosis (arrows) (A) and (B) centrilobular confluent coagulative necrosis (N).

polymerase in situ end labelling.^{15 16} The technique relies on the presence of DNA strand breaks in apoptotic cells, and the labelled DNA is identified immunohistochemically (Fig 4). Staining, however, is not limited to apoptotic cells, as necrotic cells may have DNA fragmented by lysosomal enzymes, but the value of the technique lies in the ease of spotting single apoptotic cells. Of course, despite advances in our knowledge of cell death, certain pathological phenomena will still be couched in archaic terminology. Thus, the piecemeal necrosis characteristic of chronic active hepatitis will still be called necrosis despite the fact that hepatocyte apoptosis is actually what is being induced by lymphocyte attack.

Immunologically mediated hepatocyte injury

This type of injury results from cytotoxic lymphocytes attacking antigens exposed on the surface of cells in the liver, and would include diseases such as acute hepatitis (viral and

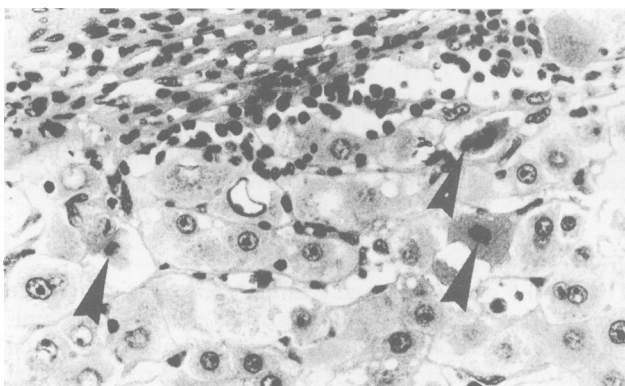

Figure 6: Piecemeal necrosis in a case of chronic active hepatitis in which lymphocytes are seen in close association with hepatocytes and individual cells die by apoptosis (arrows).

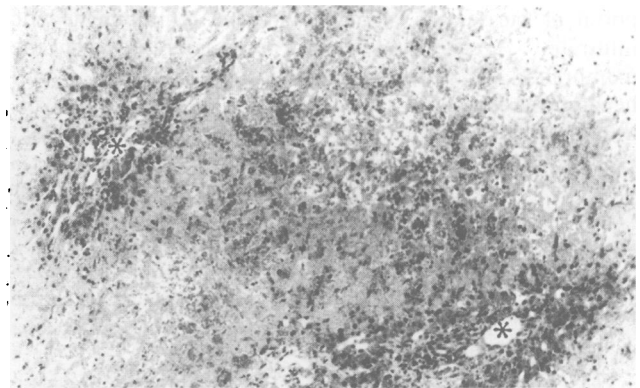


Figure 7: Periportal survival (asterisk) and centrilobular/mid zonal necrosis and congestion are pathognomonic of veno-occlusive disease.

drug induced), chronic active hepatitis, primary biliary cirrhosis, and possibly alcoholic liver disease.¹⁷⁻¹⁹ Viral infections of the liver may result from hepatotropic viruses (the hepatitis viruses) or to viruses that affect many organs including the liver. The fundamental lesion of acute viral hepatitis is so called spotty (focal) necrosis whereby the affected hepatocytes show increased acidophilia and become shrunken and fragmented (Fig 5A). These, the Councilman bodies first described in yellow fever are undoubtedly apoptotic hepatocytes. Cell ballooning can also occur leading to necrosis, which can affect groups of hepatocytes to form areas of confluent necrosis often perivenular in location (Fig 5B). Confluent necrosis, which links vascular structures is known as bridging necrosis.¹⁸ Bridging at the periphery of complex acini links terminal hepatic venules to each other ('central-central' bridging), while necrosis linking terminal hepatic venules to portal tracts ('central-portal' bridging) can be thought of as necrosis of Rappaport zone 3 of the simple acinus. Examination of the reticulin pattern will show areas of lobular architecture collapse, a good indicator of the extent of uncompensated hepatocyte necrosis.

Though virally induced acidophilic hepatocytes are distinctly smaller than ballooned hepatocytes, some may be larger than normal hepatocytes, a finding that has led Scheuer²⁰ to suggest that in this instance the ballooned hepatocyte is a forerunner of the apoptotic hepatocyte. This is, of course, somewhat contradictory to the accepted dogma that significant cell swelling precedes necrosis! Chronic active (aggressive) hepatitis can result from a number of causes, but commonly there is portal and periportal inflammation with erosion of the limiting plate by piecemeal necrosis. This may be defined as a chronic inflammatory destruction of single or small groups of liver cells (hence piecemeal) at a mesenchymal/parenchymal interface (peri-

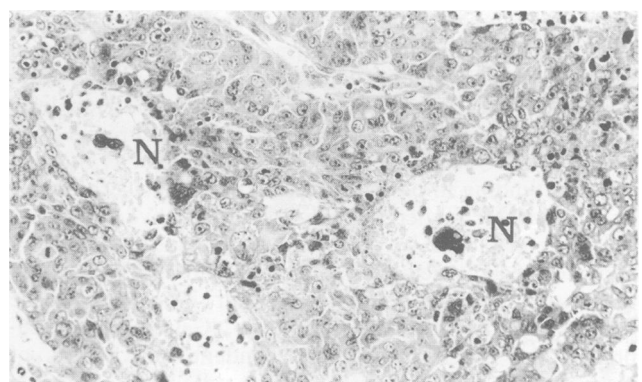


Figure 8: Foci of coagulative necrosis (N) are commonly seen in the thick trabeculae of hepatocellular carcinoma.

portal or periseptal), associated with a lymphohistiocytic infiltrate.¹⁸ A close association (peripoliosis) between the membranes of clustered lymphocytes/macrophages and hepatocytes (Fig 6) is the hallmark of piecemeal necrosis, though the degenerative hepatocytes are probably apoptotic. Not necessarily all virally induced hepatocyte injury is immune mediated, viruses may be intrinsically cytotoxic, for example, hepatitis D virus.²¹ Virally infected hepatocytes may also be very sensitive to the lethal effects of inflammatory cytokines.²² Many non-hepatitis viruses can cause an admixture of confluent necrosis and apoptosis and include herpes viruses, yellow fever (arbovirus), Lassa fever (arena virus), and Marburg virus disease.

Certain drugs can also lead to a liver picture mimicking viral hepatitis, often with an intermediate metabolite acting as a hapten, combining with a normal membrane antigen, rendering it antigenic. Sensitised lymphocytes are produced and, on re-exposure a delayed hypersensitivity reaction ensues and hepatocyte necrosis occurs. Drugs in this category include probably phenytoin, chlorpromazine, and β -aminosalicylic acid. The anaesthetic drug halothane produces liver damage rarely and unpredictably, but it is more common in subjects who have had multiple exposures, and the damage can be very severe with perivenular and mid zonal necrosis. Halothane is bioactivated by the cytochrome P450 mono-oxygenase system, and antibodies against trifluoroacetylated liver membranes are found in patients with severe halothane associated hepatitis.

Direct liver injury

Many hepatotoxic chemicals can be classified as either type I (their effects are predictable, dose dependent, occur in most subjects, readily reproducible in animals), or type II, where the reactions are not predictable, only seen after extensive screening, and can rarely if at all be reproduced in experimental animals.²³ Hepatotoxic compounds can be further divided into direct hepatotoxins (for example, CCl_4), which primarily injure the structural basis of hepatic metabolism, and indirect hepatotoxins (for example, paracetamol and galactosamine), which interfere with a specific metabolic pathway; thus structural injury is secondary to the metabolic lesion. Furthermore most intrinsic hepatotoxins cause zonal cell death, most commonly in zone 3 where this reflects the concentration of the enzyme system responsible for the conversion of the agent to its hepatotoxic metabolite. For example, CCl_4 is a well known hepatotoxic solvent whose toxicity crucially depends on a cytochrome P450 dependent mono-oxygenase, which is located in the smooth endoplasmic reticulum of perivenular hepatocytes (Fig 2B). A free radical (CCl_3^\bullet) may be responsible for the peroxidation of microsomal lipids leading to structural damage, though this may be secondary to the cells suffering from 'oxidative stress' whereby glutathione is overwhelmingly oxidised to its disulphide and glutathione is not available to act as a reductant in the metabolism of free radicals.^{7,24} Paracetamol is a widely used analgesic, which is hepatotoxic at high dose, again producing centrilobular necrosis because it is oxidised to its toxic metabolite NABQI by the cytochrome P450 system; NABQI may exert much of its cytotoxicity through covalent binding to proteins.²⁴ Zonal necrosis is also caused by allyl alcohol, but here a highly reactive aldehyde (acrolein) is largely produced by periportal hepatocytes resulting in their death. Thioacetamide causes centrilobular necrosis in the rat liver²⁵ but very acutely (within three hours) some hepatocytes may undergo apoptosis. Galactosamine depresses the uracil nucleotide-dependent biosynthesis of macromolecules, and causes diffuse cell death (probably apoptosis, see Fig 4) throughout the liver parenchyma. The degree of injury is very much dose dependent, and so

galactosamine is widely used in models of fulminant hepatic failure.

The ability of the liver to replace lost cells through liver regeneration is well recognised, and in young adult rats at least, all hepatocytes have the potential to re-enter the cell cycle.^{26,27} On the other hand, if hepatocyte regeneration is in some way impaired, then comparatively undifferentiated cells emerge from the portal space and take over the burden of regenerative growth. These potential stem cells are called oval cells²⁸ and are seen in chronically damaged human liver,²⁹ in galactosamine poisoned rats,³⁰ and when hepatocyte regeneration is prevented by the presence of cytotoxic carcinogens.³¹ Thus even in cases of severe liver injury, the liver is quite capable of healing itself through either the proliferation of hepatocytes or oval cells. When the injury occurs chronically, however, irrespective of the aetiology, then an inappropriate healing response may occur leading to fibrosis and ultimately cirrhosis. A substantial proportion of patients treated long term with methotrexate for psoriasis develop cirrhosis³² but, of course, the commonest cause of cirrhosis in Europe and the USA is longterm alcohol abuse. Ethanol is oxidised in the liver to acetaldehyde and acetate, and the earliest and most common pathological manifestation is alcoholic steatosis (fatty change), which can occur throughout the liver but which is often predominantly in zone 3. This leads to alcoholic hepatitis with ballooning degeneration, liver cell necrosis, and an influx of inflammatory cells into the affected area.

Reversal of hyperplasia

A wide range of drugs and environmental pollutants induce hyperplasia or hypertrophy of hepatocytes, or both, at least in rats. This growth can be purely 'additive' in that it is not preceded (initiated) by a necrogenic event. Once the stimulus for hyperplasia has been removed, however, the liver rapidly reverts to its normal size. In almost all cases this is achieved by an increased incidence of apoptosis, and this occurs in rat livers after lead nitrate injection³³ or cyproterone acetate treatment.³⁴ In the second case, cells that do not participate in the induced hyperplasia seem to be selectively deleted,³⁵ and transforming growth factor is believed to have a role in the elimination process.³⁶ The apoptotic cells can be phagocytosed by neighbouring hepatocytes or Kupffer cells (Fig 3). Apoptosis also occurs in livers deprived of portal blood.³⁷

Vascular causes

The hepatic venous occlusion in Budd-Chiari's syndrome usually affects the large hepatic veins or the intrahepatic portion of the inferior vena cava. In contrast, veno-occlusive disease affects small terminal hepatic venules, but the appearance of the affected area is similar with centrilobular and mid zonal necrosis and congestion, with hepatocyte survival restricted to the area immediately adjacent to the portal rim (Fig 7). In some cases veno-occlusive disease has an iatrogenic aetiology (irradiation, azathioprine, 6-thioguanine). Infarction is rare, presumably because of the dual blood supply, but circulatory shock leads to perivenular necrosis (so called hypoperfusion lesion).

Preneoplastic lesions and liver tumours

There is no doubt that many carcinogens, particularly the nitrosamines, cause both apoptosis and necrosis, predominantly in the centrilobular region.^{38,39} In some experimental models of liver carcinogenesis this induced necrosis is pivotal to the generation of dysplastic foci, as regeneration is initiated at the time of carcinogen exposure.⁴⁰ Increased rates of apoptosis are often found in these foci,⁴¹ and indeed some

tumour promoters seem to stimulate the growth of these foci by preventing apoptosis.⁴² As in other carcinomas, one can find apoptosis and necrosis in hepatocellular carcinomas and cholangiocarcinomas, often finding small lakes of necrosis in thick trabeculae (Fig 8).

M R ALISON
C E SARRAF

Department of Histopathology,
Royal Postgraduate Medical School,
Du Cane Road,
London W12 0NN

- 1 Wright NA, Alison MR. The biology of epithelial cell populations. Vol 1. Oxford: Clarendon Press, 1984.
- 2 Zajicek G, Oren R, Weinreb JR. The streaming liver. *Liver* 1985; 5: 293-300.
- 3 Paradinis FJ, Bull TB, Westaby D, Murray-Lyon IM. Hyperplasia and prolapse of hepatic veins during longterm methyltestosterone therapy: possible relationships of these changes to the development of peliosis hepatitis and liver tumours. *Histopathology* 1977; 1: 225-46.
- 4 Sigal SH, Brill S, Fiorino A, Reid LM. The liver as a stem cell and lineage system. *Am J Physiol* 1992; 263: G139-49.
- 5 Alison MR, Sarraf CE. Apoptosis: A gene-directed programme of cell death. *J R Coll Physicians Lond* 1992; 26: 25-35.
- 6 Wyllie AH, Kerr JFR, Currie AR. Cell death: the significance of apoptosis. *Int Rev Cytol* 1980; 68: 251-306.
- 7 Fawthrop DJ, Boobis AR, Davies DS. Mechanisms of cell death. *Arch Toxicol* 1991; 65: 437-44.
- 8 Kerr JFR, Wyllie AH, Currie AR. Apoptosis: a basic biological phenomenon with wide-ranging implications in tissue kinetics. *Br J Cancer* 1972; 68: 239-57.
- 9 Vaux DL. Toward an understanding of the molecular mechanisms of physiological cell death. *Proc Natl Acad Sci* 1993; 90: 786-9.
- 10 Arends MJ, Morris RG, Wyllie AH. Apoptosis. The role of the endonuclease. *Am J Pathol* 1990; 136: 593-608.
- 11 Tomei LD, Shapiro JP, Cope FO. Apoptosis in C3H/10½ mouse embryonic cells: evidence for internucleosomal DNA modification in the absence of double-strand DNA cleavage. *Proc Natl Acad Sci* 1993; 90: 853-7.
- 12 Allen TD. Ultrastructural aspects of cell death. In: Potten CS, ed. *Perspectives on cell death*. Oxford: Oxford University, 1987: 39-65.
- 13 Piacentini M, Autuori F, Dini L, et al. 'Tissue' transglutaminase is specifically expressed in neonatal rat liver cells undergoing apoptosis upon epidermal growth factor stimulation. *Cell Tissue Res* 1991; 263: 227-35.
- 14 Fesus L, Davies JA, Piacentini M. Apoptosis: molecular mechanisms in programmed cell death. *Eur J Cell Biol* 1991; 56: 170-7.
- 15 Wijsman JH, Jonker RR, Keijzer R, Van de Velde CJH, Cornilisse CJ, Van Dierendonck JH. A new method to detect apoptosis in paraffin sections: in situ end-labelling of fragmented DNA. *J Histochem Cytochem* 1993; 41: 7-12.
- 16 Ansari B, Coates PJ, Greenstein BD, Hall PA. In situ end-labelling detects DNA strand breaks in apoptosis and other physiological and pathological states. *J Pathol* 1993; 170: 1-8.
- 17 Popper H. Hepatocellular degeneration and death. In: Arias I, Popper H, Schachter D, Shafritz DA, eds. *The liver: biology and pathobiology*. New York: Raven Press, 1982: 771-84.
- 18 Bianchi L. Liver biopsy interpretation in hepatitis. *Pathol Res Pract* 1983; 178: 2-19.
- 19 Sherlock S. Patterns of hepatic injury in man. In: Brunner H, Thaler H, eds. *Hepatology. A Festschrift for Hans Popper*. New York: Raven Press, 1985: 51-9.
- 20 Scheuer PJ. Viral hepatitis. In: MacSween RMN, Antony PP, Scheuer P, eds. *Pathology of the liver*. 2nd ed. Edinburgh: Churchill Livingstone, 1987: 202-23.
- 21 Cole SM, Gowans EJ, Macnaughton TB, Hall PD, Burrell CJ. Direct evidence for cytotoxicity associated with expression of hepatitis delta virus antigen. *Hepatology* 1991; 13: 845-51.
- 22 Gilles PN, Guerrette DL, Ulevitch RJ, Schreiber RD, Chisari FV. HBsAg retention sensitizes the hepatocyte to injury by physiological concentrations of interferon-gamma. *Hepatology* 1992; 16: 655-63.
- 23 Plaa GL. Toxic responses of the liver. In: Amdur MO, Doull J, Klassen CD, eds. *Casarett and Doull's toxicology*. 4th ed. Oxford: Pergamon Press, 1991: 334-53.
- 24 Boobis AR, Fawthrop DJ, Davies DS. Mechanisms of cell injury. In: McGee JOD, Isaacson PG, Wright NA, eds. *Oxford textbook of pathology*. Vol 1. Oxford: Oxford University Press, 1992: 181-93.
- 25 Ledda-Columbano GM, Coni P, Curto M, et al. Induction of two different modes of cell death, apoptosis and necrosis, in rat liver after a single dose of thioacetamide. *Am J Pathol* 1991; 139: 1099-109.
- 26 Alison MR. Regulation of hepatic growth. *Physiol Rev* 1986; 66: 499-541.
- 27 Wright NA, Alison MR. The biology of epithelial cell populations. Vol 2. Oxford: Clarendon Press, 1984.
- 28 Sell S. Is there a liver stem cell? *Cancer Res* 1990; 50: 3811-5.
- 29 De Vos R, Desmet V. Ultrastructural characteristics of novel epithelial cell types identified in human pathologic liver specimens with chronic ductular reaction. *Am J Pathol* 1992; 140: 1441-50.
- 30 Lemire JM, Shiojiri N, Fausto N. Oval cell proliferation and the origin of small hepatocytes in liver injury induced by D-galactosamine. *Am J Pathol* 1991; 139: 535-52.
- 31 Alison MR, Nasim MM, Anilkumar TV, Sarraf CE. Transforming growth factor- α immunoreactivity in a variety of epithelial tissues. *Cell Prolif* 1993; 26: 449-60.
- 32 Ashton RE, Millward-Sadler GH, White JE. Complications in methotrexate treatment of psoriasis with particular reference to liver fibrosis. *J Invest Dermatol* 1982; 79: 229-32.
- 33 Columbano A, Ledda-Columbano GM, Coni PP, et al. Occurrence of cell death (apoptosis) during the involution of rat liver hyperplasia. *Lab Invest* 1985; 52: 670-3.
- 34 Alison MR, Wilkins MJE, Walker SM, Hully JR. Cell population size control in the rat liver: the response of hepatocytes in various proliferative states to a mitogenic stimulus. *Epithelia* 1987; 1: 53-64.
- 35 Bursch W, Taper HS, Lauer B, Schulte-Hermann R. Quantitative histological and histochemical studies on the occurrence and stages of controlled cell death (apoptosis) during regression of rat liver hyperplasia. *Virchows Arch B Cell Pathol* 1985; 50: 153-66.
- 36 Bursch W, Oberhammer F, Jirtle RL, et al. Transforming growth factor- β 1 as a signal for induction of cell death by apoptosis. *Br J Cancer* 1993; 67: 531-6.
- 37 Searle J, Harmon BV, Bishop C, Kerr JFR. The significance of cell death by apoptosis in hepatobiliary disease. *J Gastroenterol Hepatol* 1987; 2: 77-96.
- 38 Pritchard DJ, Butler WH. Apoptosis- the mechanism of cell death in dimethylnitrosamine-induced hepatotoxicity. *J Pathol* 1989; 158: 253-60.
- 39 Ray SD, Sorge CL, Kamendulis LM, Corcoran GB. Ca²⁺ activated DNA fragmentation and dimethylnitrosamine-induced hepatic necrosis: effects of Ca²⁺ endonuclease and poly (ADP-ribose) polymerase inhibitors in mice. *J Pharmacol Exp Ther* 1992; 263: 387-94.
- 40 Alison MR, Hully JR. Stimulus dependent phenotypic diversity in the resistant hepatocyte model. In: Columbano A, Feo F, Pascale R, Pani P, eds. *Chemical carcinogenesis 2. Modulating factors*. New York: Plenum, 1991: 563-77.
- 41 Columbano A, Ledda-Columbano GM, Rao PM, Rajalakshmi S, Sarma DSR. Occurrence of cell death (apoptosis) in preneoplastic and neoplastic liver cells. *Am J Pathol* 1984; 116: 441-6.
- 42 Gerbracht U, Bursch W, Kraus P, et al. Effects of hypolipidaemic drugs nafenopin and clofibrate on phenotypic expression and cell death (apoptosis) in altered foci of rat liver. *Carcinogenesis* 1990; 11: 617-24.