

Expression of p53 in early (T1) gastric carcinoma and precancerous adjacent mucosa

M J Brito, G T Williams, H Thompson, M I Filipe

Abstract

Abnormalities of the tumour suppressor gene p53 have been shown in approximately 60% of advanced gastric adenocarcinomas and it has been suggested that the immunohistochemical finding of increased p53 expression is a prognostic marker in gastric cancer. No studies of early (T1) tumours have been reported. Over expression of p53 protein in 95 early gastric carcinomas and in adjacent mucosa was investigated using immunohistochemistry with antibody CM1. Thirty five per cent of the tumours were positive. The frequency of p53 positivity in tumours of tubular histological type (46%) was significantly higher than that in signet ring tumours (10%) ($p=0.006$), and neoplasms that invaded deeply into the submucosa were more frequently positive (45%) than others (30%). Five of eight (62%) T1 tumours with lymph node metastases showed immunoreactive p53. In signet ring tumours, immunopositivity correlated with the frequency of DNA aneuploidy. p53 Over expression was also found in 15% of 26 examples of high grade dysplasia in mucosa adjacent to invasive tumours. No positivity was found in intestinal metaplasia or in normal mucosa. The findings show that immunocytochemically demonstrable over expression of p53 correlates with other morphological markers of aggressiveness in T1 gastric adenocarcinoma. The increasing frequency of p53 immunoreactivity in the sequence of high grade dysplasia→early gastric cancer→advanced gastric cancer supports the view that abnormalities of p53 are related to tumour progression in gastric carcinogenesis.

(Gut 1994; 35: 1697-1700)

A number of molecular events are being recognised as playing a part in gastric carcinogenesis.¹ Among these, mutation of the tumour suppressor gene p53 is well described in gastric adenocarcinomas² as is loss of

heterozygosity on chromosome 17p, the locus of p53.³ Immunohistochemically demonstrable over expression of p53 has been found in approximately 60% of advanced gastric cancers.^{4,5} There is much evidence from a range of human tumours to show that this is the result of p53 mutation which leads to the accumulation of a stable mutant p53 protein in the cell nucleus which can be visualised by immunohistochemistry,^{6,7} although non-mutational stabilisation of wild type p53 may be responsible in some cases.⁸

p53 Is a protein implicated in growth regulation. The wild type acts functionally as a tumour suppressor gene,⁹ while the mutated form acts as a dominant oncogene cooperating with *ras* to transform many different cell lines.¹⁰ Wild type p53 may also have a role in preventing replication of damaged DNA¹¹ while failure of this function in mutant p53 may lead to destabilisation of the genome and predisposition to the development of aneuploidy.¹²

We have previously found that 57% of advanced gastric carcinomas (invading into or beyond the muscularis propria) show p53 positivity on immunohistochemistry and that there is a significant association between the p53 status and survival time after diagnosis.⁴ A similar frequency of p53 positivity in advanced tumours has been reported by Joypaul *et al*,⁵ who also found positive staining in a low proportion (16%) of cases of high grade gastric dysplasia. No studies of p53 in early (T1) gastric cancer – that is, gastric adenocarcinoma confined to the mucosa or submucosa – have been reported. Since T1 gastric cancer might be regarded as an intermediate stage between high grade dysplasia and advanced gastric cancer, we have investigated the possible role of p53 expression in tumour progression in gastric carcinogenesis using p53 immunohistochemistry in 95 examples of T1 tumours and 26 examples of high grade dysplasia and compared the results with our previous study of advanced cases.⁴ We used the polyclonal antibody CM1, which is effective in paraffin sections and reacts with both wild type and stabilised mutant forms of p53. We have also correlated p53 staining with the various subtypes of T1 gastric cancer, some of which may reflect tumours of differing aggression.¹³

Departments of
Histopathology,
UMDS Guy's Hospital,
London
M J Brito
M I Filipe

University of Wales
College of Medicine,
Cardiff, Wales
G T Williams

The General Hospital,
Birmingham
H Thompson

Correspondence to:
Dr M I Filipe, UMDS,
Division of Histopathology,
Guy's Hospital, London
Bridge, London SE1 9RT.

Accepted for publication
23 March 1994

TABLE 1 p53 Immunostaining according to macroscopic type of tumours (Murakami¹⁴)

p53 Staining	Macroscopic type					Total
	Protruded (I)	Elevated (IIa)	Flat (IIb)	Depressed (IIc)	Excavated (III)	
Positive	10	5	4	10	4	33
Negative	15	5	5	27	10	62
Total	25	10	9	37	14	95
% Positive	40	50	44	27	28	35

Methods

Histological sections from 95 resection specimens for early (T1) gastric carcinoma from four different centres (Santa Marta Hospital, Lisbon (n=39); University Hospital

TABLE II *p53* Immunostaining according to histological type of tumours (WHO¹⁵)

<i>p53</i> Staining	Histological type					Total
	Tubular	Signet ring	Papillary	Mucinous	Undifferentiated	
Positive	26	2	3	1	1	33
Negative	30	18	6	4	4	62
Total	56	20	9	5	5	95
% Positive	46*	10*	33	20	20	35

*Significance difference. χ^2 test $p=0.006$.

of Wales, Cardiff (n=30); Guy's Hospital, London (n=14); General Hospital, Birmingham (n=14) were analysed. The tumours were classified according to: (i) macroscopic type (protruded, elevated, flat, depressed, and excavated) according to Murakami¹⁴; (ii) histologic type (tubular, signet ring, papillary, mucinous, undifferentiated) as defined by the WHO International Classification¹⁵; (iii) growth pattern (small mucosal (S), superficial spreading (SS), and penetrating (Pen) types A and B) according to Kodama *et al.*¹⁶ and (iv) lymph node status. Nearby mucosa showing high grade dysplasia¹⁷ (n=26) or intestinal metaplasia (complete type=45, incomplete type=5)¹⁸ was also studied. Care was taken to choose fields of dysplasia that were not obviously in direct continuity with the carcinoma.

The pathological material had been fixed in 10% buffered formalin for 24 hours and blocks (1–2 cm) were routinely processed and embedded in paraffin. Adjacent sections (3 μ m) were stained with haematoxylin and eosin and CM1, a polyclonal antibody that recognises both wild type and mutant *p53*^{19, 20} by a three layered immunoperoxidase method. All procedures were carried out at room temperature.

The sections destined for *p53* staining had been mounted on poly-L-lysine coated glass slides and air dried overnight. They were dewaxed in xylene, rehydrated through alcohol, and immersed in 1% hydrogen peroxide in methanol for 30 minutes to block endogenous peroxidase. After washing in phosphate buffered saline (PBS) and exposure to 4% normal swine serum for 20 minutes to reduce non-specific binding, antibody CM1 (diluted 1:1500 in PBS) was applied for 60 minutes. Further washing with PBS was followed by incubation for 60 minutes with biotinylated swine anti-rabbit immunoglobulin (Dakopatts, Copenhagen, Denmark), diluted 1:300 in 15% fetal calf serum/3% normal human serum. After further PBS washing, a streptavidin-horseradish complex (Bio-Sciences, Cambridge, UK) diluted 1:100

TABLE III *p53* Immunostaining according to growth pattern of the tumour (Kodama *et al.*¹⁶)

<i>p53</i> Staining	Growth pattern						Total
	Small mucosal M	Small mucosal SM	Superficial M	Superficial SM	Pen A	Pen B	
Positive	6	3	4	6	3	11	33
Negative	15	12	8	10	6	11	62
Total	21	15	12	16	9	22	95
% Positive	29	20	33	37	33	50	35

Pen=penetrating.

in PBS was applied for 15 minutes. Peroxidase activity was demonstrated by the addition of chromogen made up from 25 mg diaminobenzidine in 50 ml PBS, 1.25 ml of 1% cobalt chloride, 1 ml of nickel ammonium sulphate, and four drops of hydrogen peroxide which had been left to stand for three minutes. Nuclear fast red was applied for 30 seconds as a counterstain. Finally, the sections were dehydrated in alcohol, cleared in xylene, and mounted in DPX.

The specificity of *p53* staining was confirmed using parallel negative control sections which were processed immunohistochemically after replacing the primary antibody with PBS and positive control sections from a colonic adenocarcinoma previously shown to express high levels of *p53* by immunocytochemistry with CM1. Previous studies had also shown the abolition of nuclear staining of colonic carcinoma after preabsorption of antibody CM1 with *p53* protein.

Staining for *p53* was assessed by two independent observers. Only nuclear staining was considered a positive reaction.

Associations between *p53* positivity and other variables were investigated statistically using a χ^2 test. Where frequencies in various cells of a contingency table were small, Fisher's exact test was used instead.

Results

All control sections gave appropriate results. Concordance between the two independent observers was complete.

Thirty three of the 95 (35%) early (T1) gastric carcinomas showed immunopositivity for *p53*. Although the extent of staining was variable, more than 25% of tumour nuclei were stained in all positive cases. The intensity of nuclear staining varied little either within or between cases. The distribution of *p53* staining according to the various subtypes is shown in the Tables I–III.

MACROSCOPIC TYPE (TABLE I)

Tumours of protruded, elevated, and flat types showed a higher frequency of *p53* expression than depressed and excavated types, although this did not reach statistical significance.

HISTOLOGICAL TYPE (TABLE II)

Tumours of tubular type were more frequently *p53* positive (46%) (Fig 1) while those of signet ring type were only infrequently stained (10%). This difference is statistically significant (χ^2 test, $p=0.006$). The number of tumours of other types was too small for useful comparison.

GROWTH PATTERN (TABLE III)

Although not statistically significant, differences in *p53* immunopositivity between the various growth patterns were observed, with tumours invading the submucosa tending to show a higher frequency of staining than

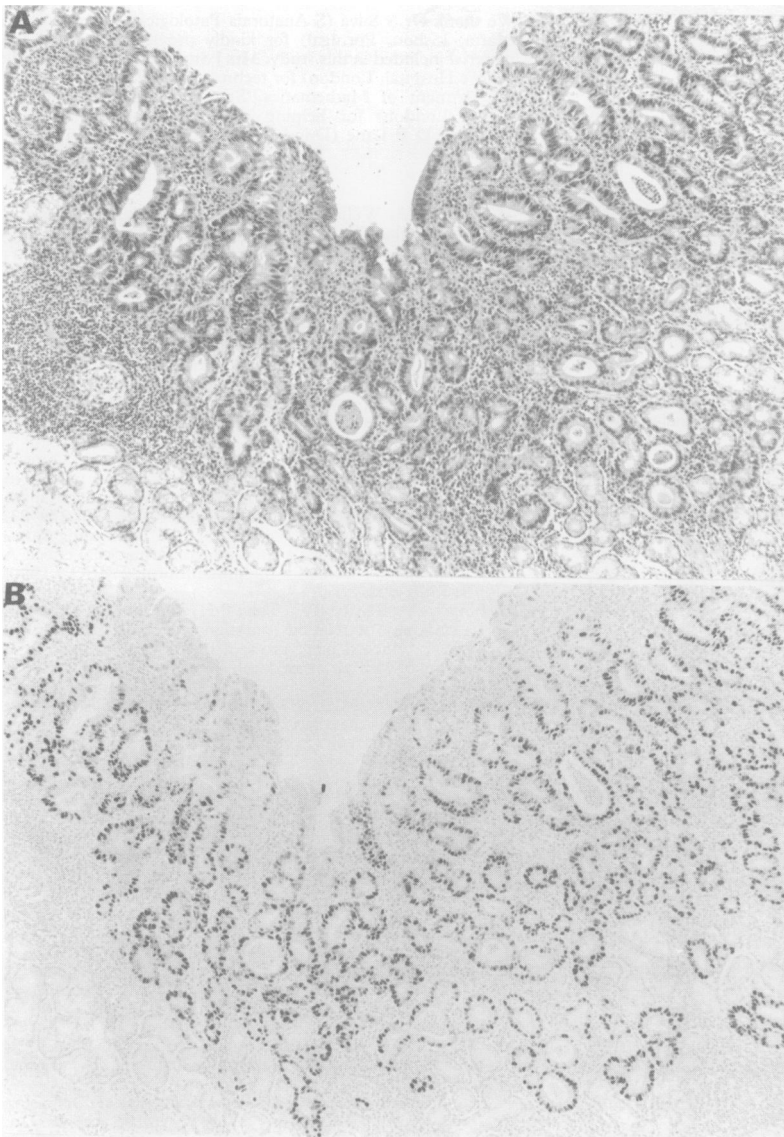


Figure 1: Tubular, well differentiated adenocarcinoma (T1) (A) stained with haematoxylin and eosin and (B) showing extensive nuclear staining for p53 (original magnification $\times 50$).

mucosal tumours. This was particularly true for Pen A and Pen B tumours which invade deeply into the submucosa (45% p53 positive *v* 30% in other types).

LYMPH NODE STATUS

Eight cases had lymph node metastasis. In five of these (62%) the primary gastric tumour was positive for p53.

DYSPLASIA AND INTESTINAL METAPLASIA

Four of 26 areas of high grade dysplasia (15%) were positive for p53 (Fig 2). None of the 50 examples of intestinal metaplasia showed p53 staining.

Discussion

Our study has found that expression of p53 in early (T1) gastric carcinomas is lower than in our previously reported series of advanced cases (35 *v* 57%),⁸ and that tumours confined to the mucosa show a lower frequency of p53 immunoreactivity than those penetrating

deeply into the submucosa. Tumours with lymph node metastases showed the highest frequency of p53 staining (62%). We also found immunopositivity for p53 in 15% of high grade dysplasia lesions, and this agrees with a recent publication.⁵ These observations support the suggestion that over expression of p53 is associated with tumour progression in gastric carcinogenesis and may be related to prognosis.

Broadly speaking, p53 staining also correlated with previously recognised phenotypic markers of prognosis in early gastric cancer. Over expression of p53 occurred much more frequently in tumours of tubular histological type than signet ring type (43% *v* 10%) and this correlates with the clinical behaviour of these subtypes. Complete resection of signet ring early gastric cancers (as opposed to advanced tumours) almost always cures the patient while intestinal early gastric cancers (which are mostly of tubular type) occasionally give rise to distant metastases.¹³ Interestingly, a previous study of advanced gastric cancers showed a higher frequency of allele loss on chromosome 17p in intestinal tumours compared with 'diffuse' and 'poorly differentiated' carcinomas (which often include signet ring forms).^{1,3} Early gastric cancers of elevated and protruded macroscopic types also have a worse prognosis than tumours of depressed or ulcerated type, and this also correlates with our results of p53 expression.

In this study we did not classify tumours into intestinal and diffuse types according to Lauren,²¹ preferring the WHO classification because of its better observer reproducibility. Generally speaking, however, the tubular, papillary and mucinous types of the WHO classification correspond to 'intestinal' tumours and the signet ring and undifferentiated types to 'diffuse' tumours. Over expression of p53 can therefore be said to occur in approximately 43% (30 of 70) of early gastric cancers of intestinal type and 12% (three of 25) of diffuse early gastric cancers.

Immunohistochemical demonstration of p53 protein may not always correspond to p53 mutation and absence of staining does not exclude mutation. 'False negatives' have been reported in a range of tumours when mutation results in a truncated protein or a weakly stabilised product which is not detected by immunohistochemistry.^{1,8} 'False positives' may occur if there is non-mutational stabilisation of wild type p53, perhaps because of interruption of the normal degradative pathway of p53⁸ or increased transcription in rapidly proliferating cells.¹ This appears to occur with some frequency in breast carcinomas,²² but not in colorectal cancer.²³ The situation in gastric adenocarcinoma is unknown and future studies should address this issue.

Mechanisms whereby increased expression of p53 might contribute to the malignant phenotype are poorly understood, but a recent study of colorectal cancer indicated a correlation between p53 immunoreactivity and aneuploidy, suggesting that wild type p53 may be involved in protecting the cell from

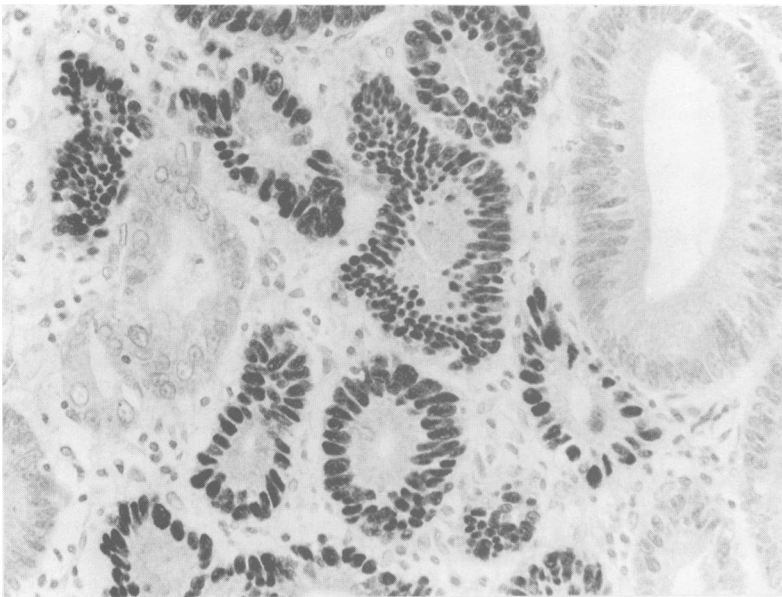


Figure 2: Dysplastic glands showing p53 positive nuclear staining.

aneuploidy.²⁴ It is therefore pertinent to compare the results of p53 expression in this study with our previous study of DNA ploidy in T1 gastric cancer.²⁵ Signet ring type tumours showed a significantly lower frequency of aneuploidy than tubular type tumours, and this mirrors our finding with p53 immunostaining. On the other hand, in early gastric cancers of non-signet ring cell type there is no clear relationship between p53 staining and ploidy in individual cases. This indicates that the role of p53 over expression in gastric carcinogenesis is not confined to facilitating the emergence of aneuploid clones, and that there are other mechanisms in malignant transformation.

In summary, our study adds further information on two important aspects of gastric carcinogenesis. Firstly, the progressive increase in the frequency of p53 immunopositivity in the sequence of high grade dysplasia → early gastric cancer → advanced gastric cancer supports the view that abnormalities of p53 are associated with tumour progression. Secondly, in early gastric cancer, tumours that are depressed or ulcerated and of signet ring morphology represent a subgroup of relatively indolent tumours which have low metastatic potential while elevated tumours of tubular or papillary type, especially when invading the submucosa over a broad front, are more aggressive. This has implications for endoscopic screening and patient management.

Although our study supports the notion that p53 immunopositivity is related to the aggressiveness of both early and advanced gastric cancer, it is premature to recommend its use as a prognostic marker for routine clinical use. However, it may contribute to the histological recognition of high grade dysplasia in gastric biopsies, particularly in cases of active or erosive gastritis where distinction between florid reactive epithelial hyperplasia and high grade dysplasia may be difficult.

We thank Dr S Silva (S Anatomia Patologica, Hospital Santa Marta, Lisbon, Portugal) for kindly providing some of the material included in this study; Mrs J Sutherland and Mr S Buk (Guy's Hospital, London) for technical advice; Dr Jack Cuzick (Department of Mathematics, Statistics and Epidemiology, ICRF, London) for helping with statistical analysis; and Professor D P Lane (Dundee) for the generous gift of CM1 antibody.

- 1 Wright PA, Williams GT. Molecular biology and gastric carcinoma. *Gut* 1993; **34**: 145-7.
- 2 Matozaki T, Sakamoto C, Matsuda K, Suzuki T, Konda Y, Nakano O, et al. Missense mutations and deletion of the p53 gene in human gastric cancer. *Biochem Biophys Res Commun* 1992; **182**: 215-23.
- 3 Sano T, Tsujino T, Yoshida K, Nakayama H, Haruma K, Ito H, et al. Frequent loss of heterozygosity on chromosomes 1q, 5q, and 17p in human gastric carcinomas. *Cancer Res* 1991; **51** (11): 2926-31.
- 4 Martin H, Filipe MI, Morris R, Lane DP, Silvestre F. p53 expression and prognosis in gastric carcinoma. *Int J Cancer* 1992; **50**: 1-4.
- 5 Joypaul BV, Newman EL, Hopwood D, Grant A, Qureshi S, Lane DP, Cuschieri A. Expression of p53 protein in normal, dysplastic, and malignant gastric mucosa: an immunohistochemical study. *J Pathol* 1993; **170**: 279-83.
- 6 Gannon JV, Greaves R, Iggo R, Lane DP. Activating mutations in p53 produce a common conformational effect. A monoclonal specific for the mutant form. *EMBO J* 1990; **9**: 1595-602.
- 7 Finlay CA, Hirds PW, Tan T-H, Eliyahu D, Oren M, Levine AJ. Activating mutations for transformation by p53 produce a gene product that forms an hsc70-p53 complex with an altered half-life. *Mol Cell Biol* 1988; **8**: 531-9.
- 8 Wynford-Thomas D. p53 in tumour pathology: can we trust immunocytochemistry? *J Pathol* 1992; **166**: 329-30.
- 9 Baker SJ, Markowitz S, Fearon ER. Suppression of human colorectal cell growth by wild-type p53. *Science* 1990; **249**: 912-5.
- 10 Hinds PW, Finlay CA, Quartin RS, Baker SJ, Fearon ER, Vogelstein B, Levine AJ. Mutant p53 DNA clones from human colon carcinomas cooperate with ras in transforming primary rat cells: a comparison of the 'hot spot' mutant phenotypes. *Cell Growth and Differentiation* 1990; **1**: 571-80.
- 11 Kuerbitz SJ, Plunkett BS, Walsh WV, Kastan MB. Wild-type p53 is a cell cycle check point determinant following irradiation. *Proc Natl Acad Sci USA* 1992; **89**: 7491-5.
- 12 Livingstone LR, White A, Sprouse J, Livanos E, Jacks T, Tlsty TD. Altered cell cycle arrest and gene amplification potential accompany loss of wild-type p53. *Cell* 1992; **70**: 923-35.
- 13 Williams GT. Early gastric cancer. In: Filipe MI, Jass JR, eds. *Gastric carcinoma*. Edinburgh: Churchill Livingstone, 1986: 172-96.
- 14 Murakami T. Pathomorphological diagnosis. Definition and gross classification of early gastric cancer. In: Murakami T, ed. *Early gastric cancer*. Gan Monograph on cancer research no 11. Baltimore: University Park Press, 1972: 53-5.
- 15 Watanabe H, Jass J, Sobin L. Histological typing of oesophageal and gastric tumours. In: WHO, ed. *International histological classification of tumours*. 2nd ed. Berlin: Springer-Verlag, 1990: 19-39.
- 16 Kodama Y, Inokuchi K, Soejima K, Matsusaka T, Okamura T. Growth patterns and prognosis in early gastric carcinoma. *Cancer* 1983; **51**: 320-6.
- 17 Morson BC, Sobin LH, Grundmann E, Johansen A, Nagayo T, Serck-Hansen A. Precancerous conditions and epithelial dysplasia in the stomach. *J Clin Pathol* 1980; **33**: 711-21.
- 18 Filipe MI, Jass JR. Intestinal metaplasia subtypes and cancer risk. In: Filipe MI, Jass JR, eds. *Gastric carcinoma*. Edinburgh: Churchill Livingstone, 1986: 87-115.
- 19 Bartek J, Bartkova J, Vojtesek B, Staskova Z, Reithar A, Kovarik J, Lane DP. Patterns of expression of p53 tumour suppressor in human breast tissues and tumours in situ and in vitro. *Int J Cancer* 1990; **46**: 839-44.
- 20 Bennett WP, Hollstein MC, He A, Zhu SM, Resau JH, Trump BF, et al. Archival analysis of p53 genetic and protein alterations in Chinese oesophageal cancer. *Oncogene* 1991; **6**: 1779-84.
- 21 Lauren P. The two histological main types of gastric carcinoma: diffuse and so-called intestinal-type carcinoma. *Acta Pathol Microbiol Scand* 1965; **64**: 31-49.
- 22 Barnes DM, Fisher CJ, Rasbridge SA, MacGeoch C, Lane DP. The p53 protein detected by immunohistochemical staining is not always mutant. *J Pathol* 1993; **169**: 177A.
- 23 Cripps JJ, White S, Komine K, Gledhill S, Wyllie AH. A comparative study of immunocytochemistry and PCR-SSCP in the detection of p53 mutations in colorectal carcinomas. *J Pathol* 1993; **169**: 129A.
- 24 Carder P, Wyllie AH, Purdie CA, Morris RG, White S, Piris J, Bird CC. Stabilised p53 facilitates aneuploid clonal divergence in colorectal cancer. *Oncogene* 1993; **8**: 1397-401.
- 25 Brito MJ, Filipe MI, Williams GT, Thompson H, Ormerod MG, Titley J. DNA ploidy in early gastric carcinoma (T1): a flow cytometric study of 100 European cases. *Gut* 1993; **34**: 230-4.