

Identification of a New Locus for a Peculiar Form of Congenital Muscular Dystrophy with Early Rigidity of the Spine, on Chromosome 1p35-36

Behzad Moghadaszadeh,¹ Isabelle Desguerre,² Haluk Topaloglu,³ Francesco Muntoni,⁴ Sylvana Pavsek,⁵ Caroline Sewry,⁴ Michèle Mayer,² Michel Fardeau,¹ Fernando M. S. Tomé,¹ and Pascale Guicheney¹

¹Institut National de la Santé et de la Recherche Médicale UR153, Groupe Hospitalier Pitié-Salpêtrière, and ²Service de Neuropédiatrie, Hôpital Saint-Vincent-de-Paul, Paris; ³Department of Paediatric Neurology, Hacettepe Children's Hospital, Ankara; ⁴Department of Paediatrics and Neonatal Medicine, Imperial College School of Medicine, Hammersmith Hospital, London; and ⁵Généthon-CNRS URA 1922, Evry, France

Summary

Classical congenital muscular dystrophies (CMDs) are autosomal recessive neuromuscular disorders characterized by early onset of hypotonia and weakness, atrophy of limbs and trunk muscles, contractures, and dystrophic changes in the muscle biopsy. So far, only one gene, *LAMA2* (6q2), which encodes the laminin $\alpha 2$ chain (or merosin), has been identified in these disorders. Mutations in *LAMA2* cause CMD with complete or partial merosin deficiency, detectable by immunocytochemistry on muscle biopsies, and account for ~50% of CMD cases. In a large consanguineous family (11 siblings) comprising three children affected by CMD without merosin deficiency, we undertook a genomewide search by homozygosity mapping and analyzed 380 microsatellite markers. The affected children were homozygous for several markers on chromosome 1p35-36. We identified two additional consanguineous families with affected children who also showed linkage to this locus. A maximum cumulative LOD score of 4.48, at a recombination fraction of .00, was obtained with *DIS2885*. A consistent feature in these three families was the presence of early rigidity of the spine, scoliosis, and reduced vital capacity, as found in rigid-spine syndrome (RSS). This study is the first description of a locus for a merosin-positive CMD and will help to better define the nosology of RSS.

Introduction

Congenital muscular dystrophies (CMDs) are a group of autosomal recessive neuromuscular diseases clinically characterized by an early onset of hypotonia and weakness, atrophy of limbs and trunk muscles, and multiple contractures (Banker 1994). Although these diseases are clinically heterogeneous, their common feature is the dystrophic pattern of the muscle biopsies, with variation in muscle-fiber size, necrosis, and increase of the endomysial collagen tissue. The first step toward identification of the genetic origin of these diseases was the discovery, in 1993, of the locus (*FCMD*) implicated in the Japanese form, known as "Fukuyama CMD" (MIM 253800), on chromosome 9q31 (Toda et al. 1993). This disease, which is very frequent in Japan, is characterized by severe hypotonia, mental retardation, and brain structural abnormalities (Fukuyama et al. 1960). A second gene (*LAMA2*), encoding the laminin $\alpha 2$ chain, also known as "merosin," was identified on chromosome 6q2 (Hillaire et al. 1994; Helbling-Leclerc et al. 1995b), following the discovery that the protein was deficient in the muscle in biopsies of CMD patients (Tomé et al. 1994). CMD patients with merosin deficiency (MIM 156225) show mutations in *LAMA2* and form a clinically homogeneous group characterized by severe hypotonia and muscle weakness and brain white-matter hypodensity, visualized by magnetic-resonance imaging, but normal intellectual function (Philpot et al. 1995; Fardeau et al. 1996). They represent a large proportion of children affected by classical CMD in whom there is no severe brain abnormality or mental retardation.

Patients with merosin-positive CMD present heterogeneous clinical features, suggesting the involvement of several gene defects. Attempts have been made to classify these patients, at the 50th International Workshop of the European NeuroMuscular Center (ENMC) on Congenital Muscular Dystrophy (Dubowitz 1997). They described numerous subgroups: (1) CMD clinically close to merosin deficiency but without white-matter altera-

Received February 6, 1998; accepted for publication April 9, 1998; electronically published April 24, 1998.

Address for correspondence and reprints: Dr. Pascale Guicheney, INSERM UR153, Groupe Hospitalier Pitié-Salpêtrière, 47 Boulevard de l'Hôpital, 75651 Paris Cedex 13, France. E-mail: pguichen@myologie.infobiogen.fr

© 1998 by The American Society of Human Genetics. All rights reserved. 0002-9297/98/6206-0021\$02.00

tion; (2) rigid-spine syndrome (RSS) characterized by early contractures of the spine; (3) Ullrich syndrome with a marked hyperextensibility of distal articulations; and (4) other cases of CMD, forming a heterogeneous group, that do not correspond to those described above, some of which may represent mild forms of muscle-eye-brain disease or Walker-Warburg syndrome.

In this study we performed the genetic analysis of a large merosin-positive CMD family with three affected siblings. Taking advantage of the consanguinity of this family, we identified, by homozygosity mapping (Lander and Botstein 1987), a new locus on chromosome 1p35-36. The analysis of 23 additional consanguineous merosin-positive CMD families led to the identification of two other families showing linkage to this locus. The clinical features of these patients were those of CMD with rigidity of the spine, and it is suggested that this locus accounts for a proportion of cases classified as having RSS.

Families and Methods

Family Studies

Twenty-four consanguineous families with at least one child with a merosin-positive CMD were included in the study. All the families gave their informed consent. The diagnosis of CMD was made in accordance with the criteria proposed by the ENMC on Congenital Muscular Dystrophy (Dubowitz 1996). The affected individuals of these families did not have a merosin-deficient CMD, as determined (1) by the detection, by immunocytochemistry, of normal amounts of merosin in the muscle biopsies of patients; (2) by exclusion of linkage to the *LAMA2* gene on 6q2; and (3) by the absence of white-matter changes, determined by brain imaging. Only patients with classical CMD (i.e., normal intelligence and no brain abnormality) were included in this study. The parents were first cousins, in 20 families.

Genotypic Analysis

DNA extraction from blood samples was performed in accordance with standard procedures (341 Nucleic Acid Purification, Applied Biosystems). Linkage of the disease to *LAMA2* was excluded for all the patients, by analysis of microsatellite markers *D6S407*, *D6S1620*, and *D6S1705* (Helbling-Leclerc et al. 1995a). For each member of family 1809, CA-repeat microsatellites from the Génethon human linkage map (Dib et al. 1996) were analyzed. PCRs were carried out with 80 ng DNA, as described elsewhere (Vignal et al. 1993). Four PCR products from the same DNA sample, generated with different primer sets, were pooled and comigrated in a single line of a 6% polyacrylamide gel. After transfer to Hybond N⁺ (Amersham) membranes, they were hybrid-

ized with a (CA)₁₅ probe labeled by peroxidase and were detected by chemiluminescence by use of the Enhanced ChemiLuminescence System (Amersham).

Linkage Analysis

Linkage analysis was performed by use of the LINKAGE 5.2 package, under the assumptions of autosomal recessive inheritance, an equal recombination frequency (θ) for males and females, a disease-gene frequency of .001, and the following four liability classes: $P = .4$ (0-4 years), $P = .6$ (4-8 years), $P = .8$ (8-12 years), and $P = .95$ (>12 years). The allele frequencies of the markers linked to the RSS locus were estimated by analysis of 45 unrelated Moroccan individuals and 45 unrelated Turkish individuals. Two-point LOD scores were calculated by use of the MLINK program.

Results

Clinical Data

The healthy parents of family 1809 originated from Morocco and were first cousins. Among their 11 children, 3 were affected by merosin-positive CMD (fig. 1). One girl, III-1, started walking at a normal age but fell frequently. A sister, III-6, had delays in her early motor milestones and started walking at 17 mo. They both had a waddling gait and difficulty in climbing stairs. There was no subsequent deterioration of their motor ability; however, they both developed rigidity of the spine, and the eldest of the two developed scoliosis at 11 years of age. Their 4-year-old brother, III-9, was hypotonic at birth and presented a severe and diffuse muscle weakness and atrophy. He has not been able to walk, so far. The three children had in common a similar facial weakness, but there was not any associated swallowing difficulty. They had a progressive restrictive respiratory syndrome and nocturnal hypoventilation due to central apneas during paradoxical sleep, with oxygen desaturation as low as 70%, as evidenced by a polygraphy sleep study. Ventilatory support at night was started for the three children (III-1, III-6, and III-9) at 10, 5, and 3 years of age, respectively. The biopsies performed on the two girls (III-1 and III-6), at 5 years and 18 mo of age, respectively, showed similar changes, characterized by variation in fiber size, some necrotic fibers, and minimal increase of interstitial fibrous tissue. These changes were compatible with a CMD and are referred to as "dystrophic" in table 1. Evoked auditory, visual, and somatoesthetic potentials were normal, and no heart abnormality was detected in these patients. Two other patients, from family T2 from Turkey and family E1 from Iran, showed similar features, including rigidity of the spine and respiratory failure. Their clinical data are summarized in table 1. In addition, a distant cousin (V-1) of the patient in family

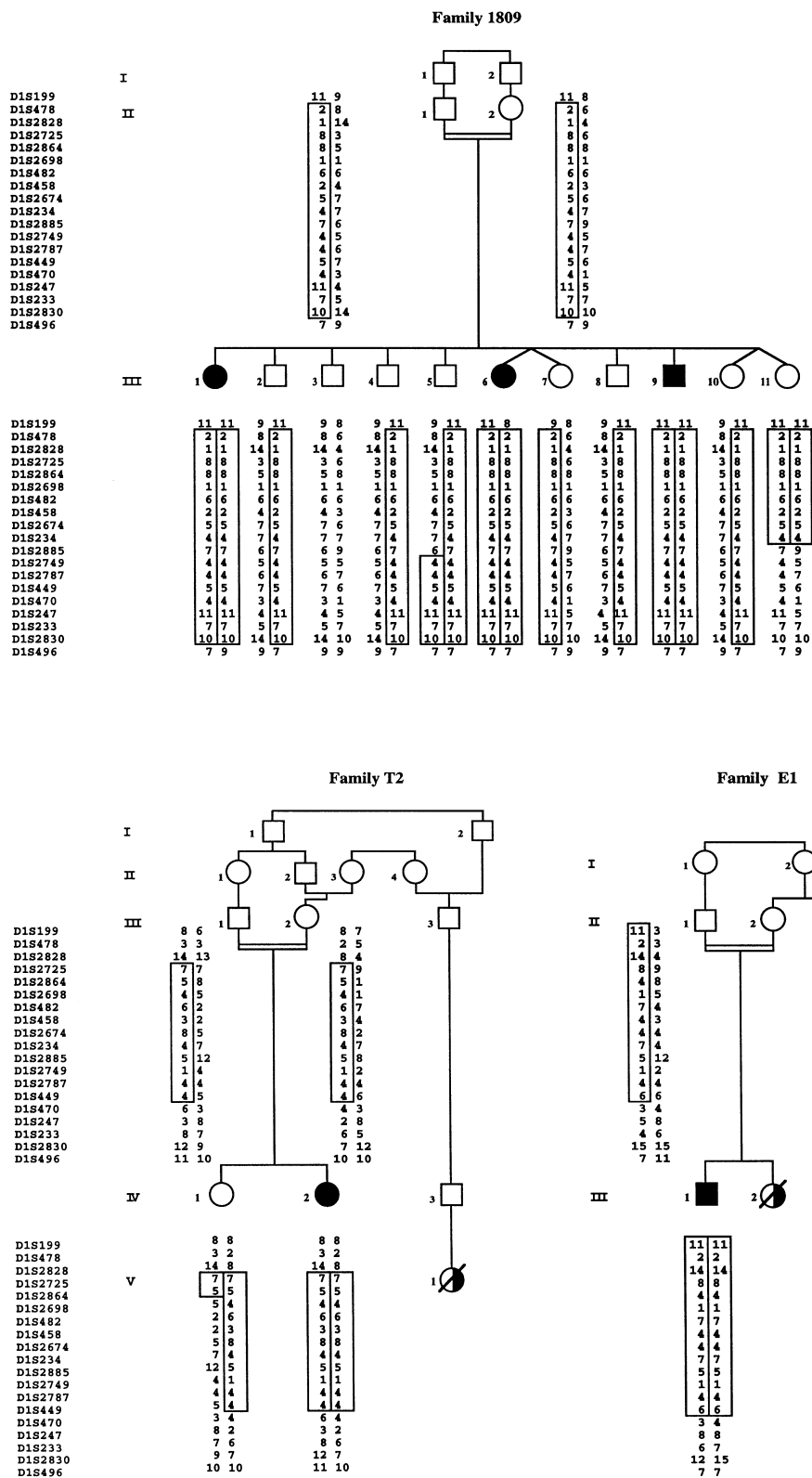


Figure 1 Pedigrees of three RSS families showing linkage to chromosome 1p. Affected individuals are represented by blackened symbols, and unaffected individuals are represented by unblackened symbols. Half-blackened symbols with a slash represent deceased subjects who are thought to have been affected and for whom genetic analysis could not be done. Disease-bearing haplotypes are boxed, for each family.

Table 1**Clinical Features of Five Patients**

	FAMILY/PATIENT				
	1809/III-1	1809/III-6	1809/III-9	T2/IV-2	E1/III-1
Sex	Female	Female	Male	Female	Male
Age in 1998 (years)	15	7	4	7	13
Age at onset (years)	1	1	Hypotonia at birth	Hypotonia at birth	Infancy
Age at walking	11 mo	17 mo	Never walked	11 mo	2.5 years
Weakness:					
Facial muscles	+	++	+++	+	+
Shoulder girdle	+	+	++	+	+
Limb muscles	+	+	+++	++	+
Foot extensors	+	+	++	+	+
Contractures:					
Spine extensors	++	++	+	+++	+++
Elbow flexors	+	-	-	-	++
Hip extensors	+	+	-	+	-
Pes equinus	+ ^a	-	-	-	+
Creatine kinase	Normal	Normal	Normal	Normal	Normal
Muscle biopsy (age)	Dystrophic (5 years)	Dystrophic (18 mo)	Not done	Atrophic and hypertrophic fibers (3.5 years)	Dystrophic (10 years)
Vital capacity (age [years])	33% (14)	55% (7)	Very limited	48% (7)	40% (10)
Age at onset of rigid spine (years)	7	6	-	3	5
Age at onset of scoliosis (years)	11	-	-	-	10

NOTE.—A minus sign (-) indicates absence; one plus sign (+) indicates discrete; two plus signs (++) indicate moderate; and three plus signs (+++) indicate severe.

^a Surgery at 7 years of age.

T2, who originated from the same village, presented the same clinical features and died at 16 years of age because of respiratory failure. Similarly, in family E1, an older sister (III-2), phenotypically similar to the proband, died at 14 years of age because of respiratory failure, and a female first cousin (III-3) had muscle weakness and died from an unspecified respiratory illness at 21 years of age.

Linkage Analysis

A genomewide search by homozygosity mapping with 380 polymorphic microsatellite markers, spaced at intervals of ~10 cM, was undertaken in all the members of family 1809. Only one marker, *D1S470*, located on chromosome 1p35-36, showed the same homozygous profile in the three affected children, whereas seven of the eight unaffected siblings were heterozygous. We confirmed this positive finding by testing the neighboring markers (fig. 1). The affected children were homozygous for the 17 markers analyzed between *D1S199* and *D1S496*. These markers were studied in 23 other consanguineous merosin-positive CMD families (data not shown): only two families, T2 and E1, showed linkage to the locus. The affected children of these families were homozygous for 13 markers and 11 markers, respectively, which reduced the locus to a 9-cM interval flanked

by *D1S2828* and *D1S470* (fig. 1). Eight markers gave significant positive cumulative LOD scores (>3), the highest being 4.48, at $\theta = .00$, for *D1S2885* (table 2).

In addition, a recombination event that occurred, between *D1S2864* and *D1S2698*, in the unaffected 13-year-old individual (IV-1) from family T2 reduced the locus to a 6-cM interval flanked by *D1S2864* and *D1S470*. In family 1809, two children, III-5 and III-11, who had no sign of the disease showed a homozygous profile for several markers. Since the girl, III-11, is only 1 year old, we cannot exclude the possibility that she may develop the disease in the future, and, therefore, we could not exclude from the locus the region between *D1S2698* and *D1S234* for which she was homozygous. However, analysis of the boy, III-5, who was clinically unaffected at 9 years of age, allowed us to exclude markers between *D1S470* and *D1S2749*, leading to a 6-cM locus flanked by *D1S2864* and *D1S2749* (fig. 2).

Discussion

Linkage data and recombinant analysis allowed us to find a new CMD locus on chromosome 1p35-36, close to the Schwartz-Jampel syndrome (SJS) locus (Fontaine et al. 1996) (fig. 2). Five patients from three CMD families showed linkage to this new locus, and four of them

Table 2
Cumulative Two-Point LOD Scores for RSS versus Chromosome 1 Markers in Families 1809, T2, and E1

MARKER	LOD SCORE AT $\theta =$							MAXIMUM LOD SCORE	MAXIMUM θ
	.00	.01	.05	.1	.2	.3	.4		
D1S199	-3.22	1.12	1.76	1.79	1.41	.90	.40	1.81	.07
D1S478	-.84	1.71	2.09	1.99	1.50	.93	.39	2.09	.05
D1S2828	-1.57	1.21	1.96	2.03	1.64	1.07	.49	2.04	.07
D1S2725	3.80	3.71	3.33	2.86	1.96	1.15	.48	3.80	.00
D1S2864	2.06	2.12	2.12	1.93	1.39	.86	.38	2.15	.03
D1S2698	1.36	1.31	1.10	.87	.47	.22	.08	1.36	.00
D1S482	1.33	1.28	1.07	.83	.46	.21	.08	1.33	.00
D1S458	3.66	3.56	3.17	2.69	1.80	1.03	.42	3.66	.00
D1S2674	3.54	3.46	3.10	2.67	1.83	1.06	.42	3.54	.00
D1S234	3.86	3.75	3.35	2.84	1.89	1.07	.40	3.86	.00
D1S2885	4.48	4.38	3.93	3.37	2.33	1.41	.63	4.48	.00
D1S2749	3.52	3.44	3.11	2.68	1.80	.99	.34	3.52	.00
D1S2787	3.06	3.01	2.75	2.40	1.67	.97	.39	3.06	.00
D1S449	3.68	3.60	3.29	2.87	2.00	1.18	.49	3.68	.00
D1S470	-1.17	1.19	1.64	1.61	1.22	.73	.29	1.65	.07
D1S247	-.83	1.41	1.86	1.83	1.40	.86	.36	1.88	.07
D1S233	-6.20	-.96	.20	.52	.59	.43	.21	.60	.15
D1S2830	-2.56	.71	1.19	1.22	.98	.64	.30	1.23	.07
D1S496	-8.47	-.55	.59	.85	.72	.39	.11	.85	.10

had distinctive and similar clinical features. In particular, they were all ambulant, with a progressive limitation of the flexion of the neck and trunk, wasting of axial muscles, facial weakness, and respiratory insufficiency requiring nocturnal ventilation support. These clinical features resemble those of RSS, first reported by Dubowitz (1973), which is characterized by a marked limitation in flexion of the whole dorsolumbar and cervical spine, owing to contracture of the spinal extensors and leading to loss of movement of the spine and the thoracic cage. There may be limitation of other joints, especially a limited extension of the elbows and the ankles. This condition is not progressive, except for the development of scoliosis and associated deformities and of respiratory failure. In the present cases, the scoliosis appeared at ~10 years of age in the two oldest patients. Subsequently to the initial description of RSS, the risk that these patients would develop a restrictive ventilatory syndrome with nocturnal hypoventilation was documented by several studies (Efthimiou et al. 1987; Morita et al. 1990; Ras et al. 1994). One of the sibs (III-9) in family 1809, a 4-year-old boy who still was unable to walk, already had some contracture of the spine extensors, resulting in a mild hyperextended posture of the neck. Like his sisters, he developed a respiratory insufficiency requiring nocturnal mechanical ventilation, at 3 years of age. For the markers of the locus, this patient presented a homozygous profile that is the same as that of his sisters, and, therefore, despite his more severe phenotype, he is predicted to have inherited the same genetic defect. Interestingly, other authors have noted an excess of males

with RSS, suggesting that this syndrome might be an autosomal recessive disorder with variable penetrance and sex-linked expression (Mussini et al. 1982). Further studies will be needed to confirm this possibility.

Among the 24 families analyzed, 2 had children with typical features of RSS who did not show linkage to chromosome 1p, suggesting genetic heterogeneity. This perhaps is not surprising, since a limitation of the flexion of the spine may develop in several neuromuscular disorders, because of the replacement of the spinal extensor

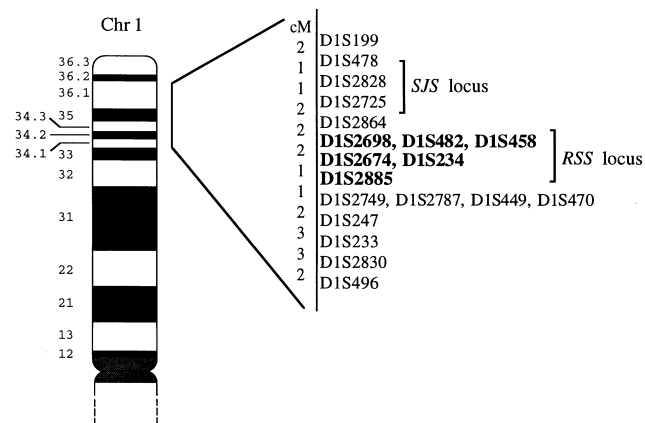


Figure 2 Ideogram of chromosome 1p, showing approximate location of RSS locus. The order of and distances between adjacent markers are based on the Génethon human linkage map (Dib et al. 1996). The markers in boldface are linked to the RSS locus. The localization of the SJS locus is shown.

muscles by fibrous and adipose tissue, resulting in their shortening (Poewe et al. 1985; van Munster et al. 1986; Merlini et al. 1989), and has been described in a variety of conditions, such as Emery-Dreifuss muscular dystrophy (Emery and Dreifuss 1966; Rowland et al. 1979), neurogenic facio-scapulo-peroneal muscle atrophy (Palmucci et al. 1991), multicore disease (Ben Hamida et al. 1987), vacuolar myopathies (Goto et al. 1981; Bertini et al. 1986; van Munster et al. 1986), and nemaline myopathy (Topaloglu et al. 1994). The identification of the locus reported here may help to better define the nosology of RSS.

In this study we identified a new locus responsible for a merosin-positive CMD. The clinical features of the affected children suggest an overlap with RSS. Since the increase of connective tissue in muscle biopsy is a common feature of the CMDs and since the laminin $\alpha 2$ chain has been identified as the culprit for CMD with merosin deficiency, extracellular matrix components represent good candidates for all these disorders. In this respect, it is interesting to note that there are two extracellular-matrix genes mapped to chromosome 1p35-36, *MFAP2* and *HSP2*, which encode the microfibril-associated glycoprotein and the heparan-sulfate proteoglycan, also known as “perlecan,” respectively (Kallunki et al. 1991; Faraco et al. 1995). These proteins are expressed in the extracellular matrix of different tissues, including skeletal muscle, and are potential candidates for this disease.

Acknowledgments

We thank Brigitte Estournet, Annie Barois, Luciano Merlini, Bernard Echenne, Jon-Andoni Urtizbera, and Victor Dubowitz for referring families, for their collaboration, and for fruitful discussions. We also are thankful to Yolaine Pothin, Isabelle Cornu, and Alexandra Durr for providing us with Moroccan DNA controls. This work was supported by the Institut National de la Santé et de la Recherche Médicale, the Association Française contre les Myopathies, and the French Research Ministry (Actions Concertées Coordonnées–Sciences du Vivant). The financial support of the Muscular Dystrophy Group of Great Britain also is gratefully acknowledged. The authors wish to thank the European NeuroMuscular Center (ENMC) for its continuous support.

Electronic-Database Information

Accession numbers and URLs for data in this article are as follows:

Online Mendelian inheritance in man (OMIM), <http://www.ncbi.nlm.gov/omim> (for Fukuyama congenital muscular dystrophy [MIM 253800] and for congenital muscular dystrophy with merosin deficiency [MIM 156225])

References

- Banker BQ (1994) The congenital muscular dystrophies. In: Engel AG, Franzini-Amstrong C (eds) *Myology*, 2d ed. McGraw-Hill, New York, pp 1275–1289
- Ben Hamida M, Hentati F, Ben Hamida C (1987) Maladie à multiminicores au cours d'un syndrome de la colonne raide. *Rev Neurol (Paris)* 143:284–289
- Bertini E, Marini R, Sabetta G, Palmieri GP, Spagnoli LG, Vaccario ML, de Barys T (1986) The spectrum of the so-called rigid spine syndrome: nosological considerations and report of three female cases. *J Neurol* 233:248–253
- Dib C, Fauré S, Fizames C, Samson D, Drouot N, Vignal A, Millasseau P, et al (1996) A comprehensive genetic map of the human genome based on 5,264 microsatellites. *Nature* 380:152–154
- Dubowitz V (1973) Rigid spine syndrome: a muscle syndrome in search of a name. *Proc R Soc Med* 66:219–220
- (1996) 41st ENMC International Workshop on Congenital Muscular Dystrophy, 8–10 March 1996, Naarden, The Netherlands. *Neuromuscul Disord* 6:295–306
- (1997) 50th ENMC International Workshop: congenital muscular dystrophy, 28 February 1997 to 2 March 1997, Naarden, The Netherlands. *Neuromuscul Disord* 7: 539–547
- Efthimiou J, McLelland J, Round J, Gribbin HR, Loh L, Spiro SG (1987) Diaphragm paralysis causing ventilatory failure in an adult with the rigid spine syndrome. *Am Rev Respir Dis* 136:1483–1485
- Emery AEH, Dreifuss FE (1966) Unusual type of benign X-linked muscular dystrophy. *J Neurol Neurosurg Psychiatry* 29:338–342
- Faraco J, Bashir M, Rosenbloom J, Francke U (1995) Characterization of the human gene for microfibril-associated glycoprotein (*MFAP2*), assignment to chromosome 1p36.1-p35, and linkage to D1S170. *Genomics* 25:630–637
- Fardeau M, Tomé FMS, Helbling-Leclerc A, Evangelista T, Ottolini A, Chevally M, Barois A, et al (1996) Dystrophie musculaire congénitale avec déficience en mérosine: analyse clinique, histopathologique, immunocytochimique et génétique. *Rev Neurol (Paris)* 152:11–19
- Fontaine B, Nicole S, Topaloglu H, Ben Hamida C, Beighton P, Spaans F, Cantu JMA, et al (1996) Recessive Schwartz-Jampel syndrome (SJS): confirmation of linkage to chromosome 1p, evidence of genetic homogeneity and reduction of the SJS locus to a 3-cM interval. *Hum Genet* 98:380–385
- Fukuyama Y, Kawamura M, Haruna H (1960) A peculiar form of congenital progressive muscular dystrophy: report of fifteen cases. *Paediatr Univ Tokyo (Tokyo)* 4:5–8
- Goto I, Muraoka S, Fujii N, Ohta M, Kuroiwa Y (1981) Rigid spine syndrome: clinical and histological problems. *J Neurol* 226:143–148
- Helbling-Leclerc A, Topaloglu H, Tomé FMS, Sewry C, Gypay G, Naom I, Muntoni F, et al (1995a) Readjusting the localization of merosin (laminin $\alpha 2$ -chain) deficient congenital muscular dystrophy locus on chromosome 6q2. *C R Acad Sci III* 318:1245–1252
- Helbling-Leclerc A, Zhang X, Topaloglu H, Cruaud C, Tesson F, Weissenbach J, Tomé FMS, et al (1995b) Mutations in

- the laminin $\alpha 2$ -chain gene (LAMA2) cause merosin-deficient congenital muscular dystrophy. *Nat Genet* 11:216–218
- Hillaire D, Leclerc A, Fauré S, Topaloglu H, Chiannikoulchaj N, Guicheney P, Grinas L, et al (1994) Localization of merosin-negative congenital muscular dystrophy to chromosome 6q2 by homozygosity mapping. *Hum Mol Genet* 3: 1657–1661
- Kallunki P, Eddy RL, Byers MG, Kestila M, Shows TB, Trygvason K (1991) Cloning of human heparan sulfate proteoglycan core protein, assignment of the gene (*HSPG2*) to 1p36.1→p35 and identification of a *Bam*HI restriction fragment length polymorphism. *Genomics* 11:389–396
- Lander ES, Botstein D (1987) Homozygosity mapping: a way to map human recessive traits with the DNA of inbred children. *Science* 236:1567–1570
- Merlini L, Granata C, Ballestrazzi A, Marini ML (1989) Rigid spine syndrome and rigid spine sign in myopathies. *J Child Neurol* 4:274–282
- Morita H, Kondo K, Hoshino K, Maruyama K, Yanagisawa N (1990) Rigid spine syndrome with respiratory failure. *J Neurol Neurosurg Psychiatry* 53:782–784
- Mussini JM, Mathé JF, Prost A, Gray F, Labat JJ, Fève JR (1982) Le syndrome de la colonne raide: un cas féminin. *Rev Neurol (Paris)* 138:25–37
- Palmucci L, Mongini T, Doriguzzi C, Maniscalco M, Schiffer D (1991) Familial autosomal recessive rigid spine syndrome with neurogenic facio-scapulo-peroneal muscle atrophy. *J Neurol Neurosurg Psychiatry* 54:42–45
- Philpot J, Sewry C, Pennock J, Dubowitz V (1995) Clinical phenotype in congenital muscular dystrophy: correlation with expression of merosin in skeletal muscle. *Neuromuscul Disord* 5:301–305
- Poewe W, Willeit H, Sluga E, Mayr U (1985) The rigid spine syndrome: a myopathy of uncertain nosological position. *J Neurol Neurosurg Psychiatry* 48:887–893
- Ras GJ, van Staden M, Schultz C, Stubgen JP, Lotz BP, van der Merwe C (1994) Respiratory manifestations of rigid spine syndrome. *Am J Respir Crit Care Med* 150:540–546
- Rowland LP, Fetell M, Olarte M, Hays A, Singh N, Wanat FE (1979) Emery-Dreifuss muscular dystrophy. *Ann Neurol* 5: 111–117
- Toda T, Segawa M, Nomura Y, Nonaka I, Masuda K, Ishihara T, Suzuki M, et al (1993) Localization of a gene for Fukuyama type congenital muscular dystrophy to chromosome 9q31-33. *Nat Genet* 5:283–286
- Tomé FMS, Evangelista T, Leclerc A, Sunada Y, Manole E, Estournet B, Barois A, et al (1994) Congenital muscular dystrophy with merosin deficiency. *C R Acad Sci III* 317: 351–357
- Topaloglu H, Gogus S, Yalaz K, Kulkali T, Serdaroglu A (1994) Two siblings with nemaline myopathy presenting with rigid spine syndrome. *Neuromuscul Disord* 4:263–267
- van Munster ETL, Joosten EMG, van Munster-Uijtdehaage MAM, Kruls HJA, Ter Laak HJ (1986) The rigid spine syndrome. *J Neurol Neurosurg Psychiatry* 49:1292–1297
- Vignal A, Gyapay G, Hazan J, Nguyen S, Dupraz C, Cheron N, Becuwe N, et al (1993) Non-radioactive multiplex procedure for genotyping of microsatellite markers. In: Adolph KW (ed) *Methods in molecular genetics*. Academic Press, New York, pp 211–221