

Effect of colloidal bismuth subcitrate on age related gastric lesions in the rat

S M Hinsull

Abstract

The purpose of this study was to determine the changes in rat gastric functional morphology that take place with age and to study the action of colloidal bismuth subcitrate on the age related degeneration of the stomach. At 95 weeks of age erosions were apparent over 80% of the gastric mucosa and this was associated with a significant decline in the numbers and mucus content of the mucosal epithelial cells. The rate of stem cell proliferation in the neck region was also significantly lower than that found in 9 week old animals. The administration of 50 mg/kg colloidal bismuth subcitrate for 14 days to 9 week old animals resulted in slight hypertrophy of the mucosal epithelial cells. When 95 week animals were placed on the same regimen there was a decline in the number of deep erosions in the mucosa and an increase in the number and mucin content of the mucosal epithelial cells. A significant increase in the proliferation of the stem cell population was also observed after colloidal bismuth subcitrate administration. It is suggested that colloidal bismuth subcitrate may ameliorate the increased susceptibility to harmful agents that occurs with age.

Colloidal bismuth subcitrate has been widely used for many years to treat a variety of gastrointestinal disorders.^{1,2} Since bismuth is a heavy metal, however, some concern has been expressed over the possible toxic effects of long term treatment, particularly in relation to the development of encephalopathy.³ In addition, its mechanism of action remains uncertain, although traditionally its gastroprotective and therapeutic properties have been attributed to the formation of a protective barrier in areas of gastric damage,^{4,6} inhibition of pepsin secretion,⁷ binding of bile salts,⁸ and eradication of *Helicobacter pylori*.⁹ Recent work, however, suggests that colloidal bismuth subcitrate may also act via other agents such as prostaglandins and epidermal growth factor. It is known to stimulate the production of prostaglandins, and members of this group of hormones have been implicated in the cytoprotective action of colloidal bismuth subcitrate.¹⁰⁻¹² More recently it has been shown to inhibit the breakdown of epidermal growth factor in the stomach,¹³ as well as increasing the accumulation of epidermal growth factor in areas of gastric damage.^{14,15} This, together with the fact that colloidal bismuth subcitrate has been shown to have a trophic action on the normal stomach,¹⁶ suggests that it may have the ability to modulate the control mechanisms involved in maintaining gastric integrity.

Ageing is associated with a deterioration in

the functional and morphological integrity of tissues.¹⁴ In the stomach this results in an increased susceptibility to conditions such as gastritis, ulceration, gastric polyposis, and intestinal metaplasia,¹⁷ together with decreased gastric resistance to aggressive agents such as non-steroidal anti-inflammatory drugs.¹⁸ The mechanisms underlying the age related deterioration of gastric tissue are unknown, but it is known that there is a decline in the secretion and action of gastric trophic agents with age.^{19,20} The established protective and trophic actions of colloidal bismuth subcitrate suggest that it may ameliorate the degeneration in gastric integrity that occurs with age. Therefore, the aim of the present work was to examine the effect of colloidal bismuth subcitrate on the gastric cellular populations of old animals.

Methods

ANIMAL TREATMENT

Twenty 9 week old and twenty 95 week old male rats of a WAB substrain were used in the present experiments. All of the animals were routinely maintained on a standard pelleted diet and tap water was freely available. Ten animals from each age group were given colloidal bismuth subcitrate in the drinking water, at a dose of 50 mg/kg body weight, for 14 days before gastric tissue samples were taken. All of the animals were fasted for 24 hours before death to ensure efficient penetration of the gastric tissue by the fixative. Colchicine, 2 mg/kg body weight, was administered by intraperitoneal injection two hours before the animals were killed by cervical dislocation.

HISTOLOGY

Ligatures were applied to the oesophageal and duodenal junctions of the stomach and approximately 1 ml of cold fixative (nine parts buffered neutral formalin:1 part acetone) was injected into the gastric lumen. The stomach was removed, immersed in fixative for 30 minutes, and subsequently opened along the greater curvature and placed in fresh fixative for 17 hours. Eight mm horizontal strips of tissue were removed from the upper surface of the fundic region, 3 mm below the squamous stomach and midway between the greater and lesser curvature. The stomach samples were embedded in a methacrylate medium and sections cut at 2 µm. Sections from each sample were stained according to three techniques as follows:

- (1) Gordon and Sweet's method for reticulin,²¹ counterstained with Mayer's haemalum.
- (2) A double nuclear stain consisting of celes-

Department of Pure and Applied Biology,
University of Wales
College of Cardiff,
Cardiff

S M Hinsull

Correspondence to:
Dr S M Hinsull, Department
of Pure and Applied Biology,
University of Wales College
of Cardiff, PO Box 915, Cardiff
CF1 3TL.

Accepted for publication
21 May 1990

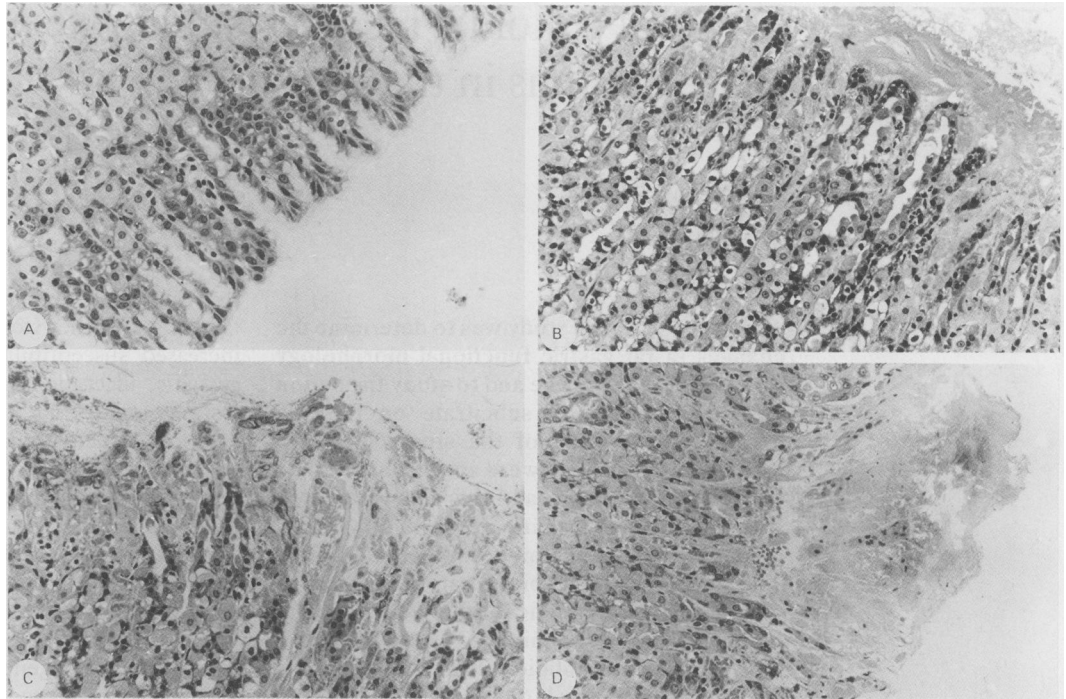


Figure 1: (A) Intact surface mucosa of young animal (original magnification $\times 200$). (B) Superficial damage in the surface mucosal region of old animals (original magnification $\times 200$). (C) Damage extending into the gastric mucosal neck region of old animals (original magnification $\times 200$). (D) Erosion in the gastric mucosa of old animals (original magnification $\times 200$).

tine blue to intensify the action of Mayer's haemalum.

(3) Periodic acid Schiff leucofuscin (PAS) for the detection of epithelial mucins.

MORPHOMETRY

All morphometric analyses were carried out on coded slides so that the person performing the analyses was unaware from which experimental group the tissue came. Reticulin stained sections were used to check the orientation of the tissue, and only tissue cut in the vertical plane was used for analysis. Reticulin stained sections were also

used to determine the total depth of the mucosa and the depth of the surface epithelium. The total depth of the mucosa was measured from the upper limits of luminal surface epithelial cells to the muscularis mucosa. The surface epithelial cell depths were determined by measuring the total depth of the mucosal epithelial cell population from the upper limits of the luminal surface to the point where parietal cells were detected. In both cases the depth measurements were determined by image analysis on 200 samples for each experimental group.

The total area of PAS positive material present in the surface epithelial cells was determined by image analysis across a standard $240 \mu\text{m}$ width of mucosa. A total of 200 determinations were carried out for each experimental group.

All of the cell counts were carried out on nuclear stained material. The total number of surface epithelial cells was counted in a standard microscope area ($170 \mu\text{m}$) covering a width of three gastric pits. The total numbers of parietal cells, epithelial cells, and mitotic figures per microscope field were determined in the corresponding neck regions. The numbers of parietal and chief cells in the respective basal regions were also scored. Two hundred microscope areas were counted for each of these three regions in each experimental group.

Each of the microscope areas counted was also assessed for the degree of tissue damage, with each area being assigned to one of the following categories of damage: intact, no microscopic evidence of damage; loss or disorganisation of the surface mucosal epithelial cells; loss of the surface epithelial cells and damage or disorganisation into the superficial neck region; and erosion into the neck region and beyond.

Throughout the data a two sample *t* test was used to test the significance between mean values.

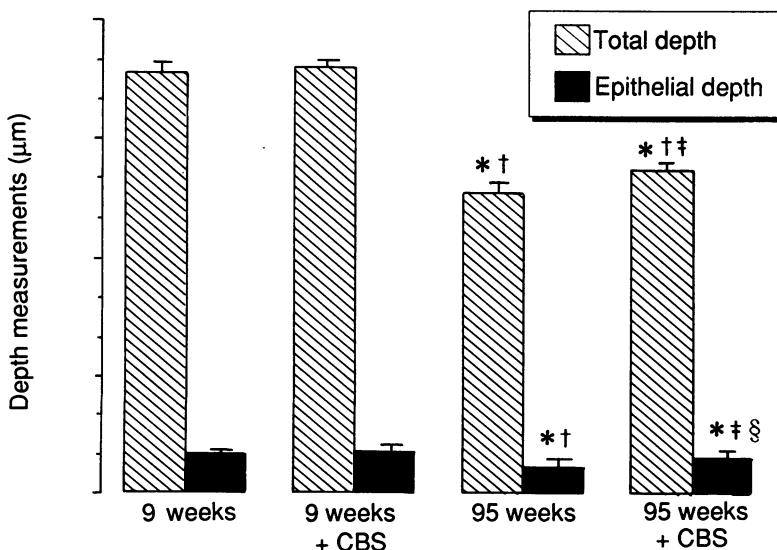


Figure 2: Total mucosal and surface epithelial depths in 9 and 95 week old control and colloidal bismuth subcitrate (CBS) treated animals. *Significantly different from the values in 9 week old control animals, $p < 0.001$; †significantly different from the values in 9 week old CBS treated animals, $p < 0.001$; ‡significantly different from the values in 95 week old control animals, $p < 0.05$; §significantly different from the values in 95 week old control animals, $p < 0.001$; (n=200).

Results

The dose of colloidal bismuth subcitrate used in these experiments was higher than the standard therapeutic doses but fell within the range given to experimental animals by other workers and, from our pilot studies, is known to have a gastroprotective effect when administered at 12 hourly intervals for a minimum of seven days.^{10-12 14 16} The administration of colloidal bismuth subcitrate at a dose of 50 mg/kg body weight over a period of two weeks had no apparent detrimental effects on the well being, growth, or food consumption of the experimental animals.

A 9 week old rat is a young, sexually mature adult, at approximately the equivalent stage of its lifespan as an 18–20 year old human, whereas 95 week old animals are at a stage comparable with that of 75 year old humans. In the young animals none of the gastric tissue examined showed any sign of damage, either in the control or the colloidal bismuth subcitrate treated animals (Fig 1A). This contrasted with the 95 week control animals where only 19.3% of the areas examined were classified as intact. Superficial damage to the mucosa was found on 32% of the tissue (Fig 1B), with damage extending into the neck region in 30% of the areas (Fig 1C). Extensive erosions were found in 7% of these areas (Fig 1D). *Helicobacter* is not found in rats and there was no indication of the presence of rat related gastric bacteria in animals of either age group.

When the old animals were treated with colloidal bismuth subcitrate there was a noticeable decline in the degree of gastric damage compared with the control animals. Treatment resulted in a threefold increase in the number of intact areas over control values. Thirty per cent of the areas had superficial damage to the mucosal surface in the colloidal bismuth subcitrate treated old animals, but only 8% of the tissue showed complete destruction of the surface epithelial cells and there were no instances where damage extended beyond the mucosal surface.

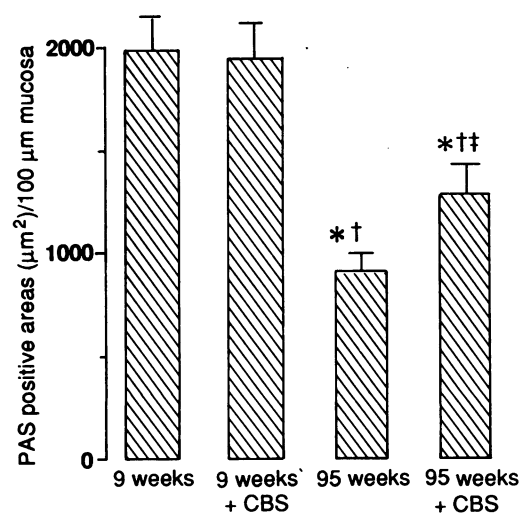


Figure 3: Total area of periodic acid Schiff positive material/100 µm of mucosa in 9 and 95 week old control and colloidal bismuth subcitrate (CBS) treated animals. *Significantly different from the values in 9 week old control animals, $p < 0.001$; †significantly different from the values in 9 week old CBS treated animals, $p < 0.001$; ‡significantly different from the values in 95 week old control animals, $p < 0.001$; (n=200).

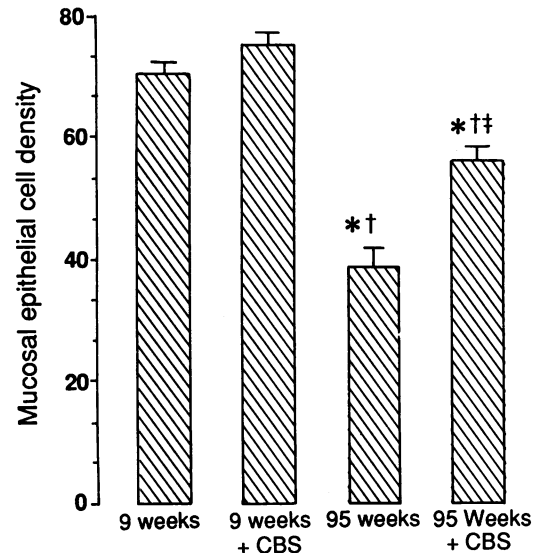


Figure 4: Density of epithelial cells in the surface mucosal region in 9 and 95 week old control and colloidal bismuth subcitrate (CBS) treated animals. *Significantly different from the values in 9 week old control animals, $p < 0.001$; †significantly different from the values in 9 week old CBS treated animals, $p < 0.001$; ‡significantly different from the values in 95 week old control animals, $p < 0.001$; (n=200).

Significant ($p < 0.001$) reductions in both the total mucosa and surface epithelial depths were observed between 9 and 95 weeks of age (Fig 2). The administration of colloidal bismuth subcitrate to 9 week old animals resulted in increases in both the total mucosa and surface epithelial depths but these were not statistically significantly different from control values. When colloidal bismuth subcitrate was given to 95 week old animals, however, there was an 8% increase in total mucosal depth and a 32% increase in surface epithelial depth compared with 95 week old control animals (Fig 2). Staining with PAS reagent was used to detect epithelial mucins. The positive areas were quantified using image analysis and the results expressed as the total area of PAS positive material per 100 µm length of mucosa. PAS positive material was found only in surface mucosal cells and did not extend as far as the neck region. The highest values were found in the 9 week old control animals, with colloidal bismuth subcitrate treatment at this age resulting in an insignificant decrease in the amount of PAS positive material compared with the control values. At 95 weeks of age the amount of PAS positive material was 54% lower than that found in 9 week old animals. In 95 week old animals receiving colloidal bismuth subcitrate, the amount of PAS positive material remained significantly ($p < 0.001$) lower than that found in the younger age group, but values were 41% higher than in control animals of the same age (Fig 3).

Quantification of the surface mucosal epithelial cells showed a significant ($p < 0.001$) decline in the numbers of these cells with age, such that at 95 weeks of age the surface epithelial numbers were 42% lower than at 9 weeks of age (Fig 4). The administration of colloidal bismuth subcitrate was associated with an increase in the density of surface mucosal epithelial cells at both 9 and 95 weeks of age. Compared with control animals of the same age, this resulted in a 7% increase in surface mucosal epithelial cells in the

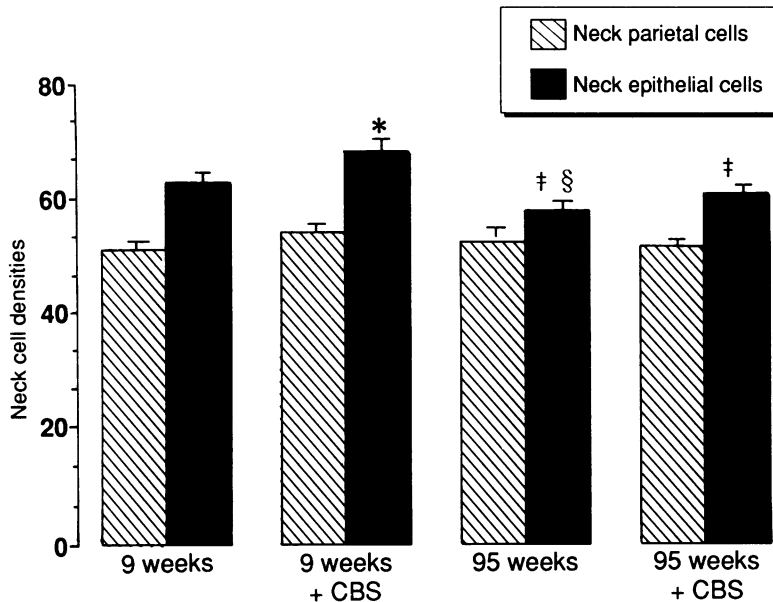


Figure 5: Density of epithelial and parietal cells in the neck region of the mucosa in 9 and 95 week old control and colloidal bismuth subcitrate (CBS) treated animals. §Significantly different from the values in 9 week old control animals, $p < 0.01$; *significantly different from the values in 9 week old control animals, $p < 0.001$; †significantly different from the values in 9 week old CBS treated animals, $p < 0.001$; (n=200).

9 week old treated animals and a 45% increase in the 95 week old treated group. The age related changes in the numbers of epithelial cells in the neck region were less apparent than those in the surface mucosa. At 95 weeks of age the neck epithelial cell numbers were 8% lower than at 9 weeks of age. Again administration of colloidal bismuth subcitrate resulted in an increase in the epithelial cell numbers in both age groups such that the numbers of epithelial cells in the neck region of the 95 weeks treated group were not significantly different from 9 week control values (Fig 5). An insignificant increase in the number of parietal cells in the neck region was observed with age, but the administration of colloidal bismuth subcitrate had little apparent effect on the numbers of these cells in either age group (Fig 5).

The number of proliferative cells fell by 57% between 9 and 95 weeks of age and this was associated with the fall in epithelial cell numbers in both the surface mucosal and neck regions between these two ages. After colloidal bismuth subcitrate administration to 9 week old animals there was a significant fall in the number of proliferative cells despite increases in the densities of the epithelial cell populations. In contrast, colloidal bismuth subcitrate administration to 95 week old animals resulted in a significant ($p < 0.001$) increase in the number of mitotic cells over control values at 95 weeks of age (Fig 6).

Although there was little morphological change in the basal region with age, there was a significant ($p < 0.001$) increase in the number of parietal cells with age but no significant age associated change in the number of chief cells. In 9 week old animals, colloidal bismuth subcitrate had no significant effect on the numbers of chief or parietal cells in the basal region, but at 95 weeks of age it resulted in parietal cell numbers falling to values that were comparable with those observed at 9 weeks of age.

Discussion

Clinically, colloidal bismuth subcitrate is administered in the fasting state, however the present requirement for its continuous administration over 14 days precluded this regimen. Previous workers have used the method of colloidal bismuth subcitrate administration adopted in the present experiments,¹² and our own work has shown that it is bound to the luminal surface of the stomach in the presence of food.¹⁶

Previous work has shown that loss of surface epithelial cells is observed after food intake^{23,24} but age related degeneration of the rat stomach is not microscopically detectable until 75 weeks of age. Thereafter there is a rapid deterioration in gastric morphology, resulting in numerous lesions of the gastric mucosa.²⁵ The present results concur with these earlier findings and show significant changes in the gastric cell population with age. The gastric lesions were associated with a significant reduction in mucosal epithelial cell numbers, together with a decrease in the amount of PAS positive material found in these cells. Both the mucosal epithelial cells and the mucins they produce are known to play a vital role in the gastric defence mechanism.²⁶⁻³¹ Therefore, the decrease in the numbers or mucus secreting capacity of the epithelial cells could be instrumental in age related gastric deterioration and increased susceptibility to damage.

In young animals stem cell proliferation follows gastric damage and contributes to the restoration of tissue integrity.^{16,28} Despite the depleted epithelial cell numbers and extensive erosions observed in the older age group in the present experiments, the rate of stem cell proliferation remained significantly lower than that observed in tissue from the young animals. This suggests that gastric ageing leads to a decrease in the functional capacity of the stem cell population, and this may underlie the inability to maintain the epithelial cell population and an effective gastric repair mechanism.

Repeated administration of colloidal bismuth subcitrate has been shown to result in hypertrophy of the gastric mucosa, with a significant decrease in the rate of mitosis.¹⁶ In the present

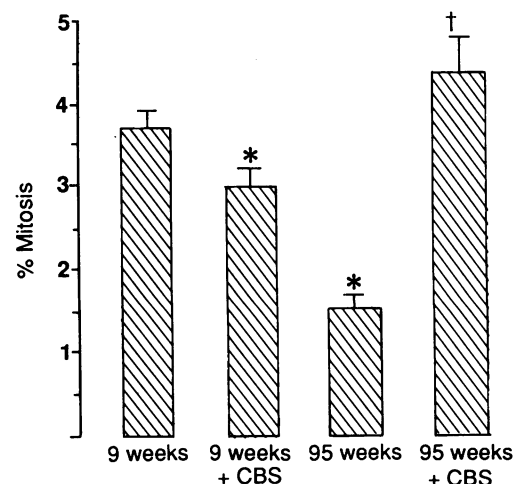


Figure 6: Rate of mitosis in 9 and 95 week old control and colloidal bismuth subcitrate (CBS) treated animals. *Significantly different from the values in 9 week old control animals, $p < 0.001$; †significantly different from the values in 95 week old control animals, $p < 0.001$; (n=200).

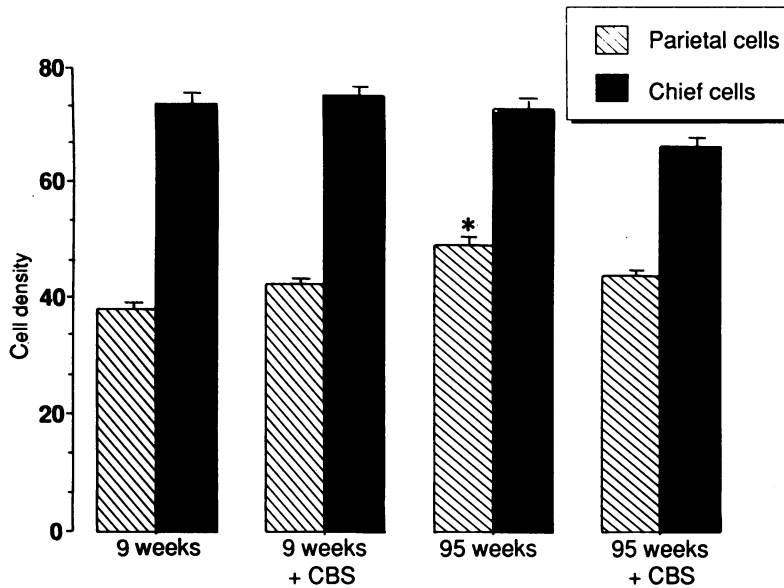


Figure 7: Density of parietal and chief cells in the basal mucosal region in 9 and 95 week old control and colloidal bismuth subcitrate (CBS) treated animals.
*Significantly different from the values in 9 week old control animals, $p < 0.001$.

experiments a similar pattern emerged, but in this instance the changes in the cellular population were less noticeable than with the higher dose of colloidal bismuth subcitrate used previously. In old animals colloidal bismuth subcitrate seemed to be particularly effective in healing the most extensively damaged regions of the stomach but resulted in little change in the number of areas with superficial damage to the mucosa. The decrease in overall tissue damage was correlated with significant increases in the number of mucosal epithelial cells. Colloidal bismuth subcitrate treatment also resulted in an increase in amount of PAS positive material present in the old animals, although no significant change was found in the amount of PAS present in the tissue from young animals after treatment. The changes in PAS positive material found in the old animals may be a result of the decreased damage to the gastric mucosa and consequent increase in the number of functional mucosal epithelial cells found with treatment. Colloidal bismuth subcitrate may be involved in the restitution of the lesions that result from the age impaired defence mechanism by, for example, protecting the stem cells against injury and thereby promoting the healing process,²¹ rather than in counteracting the ageing process itself.

Prostaglandins have been implicated as possible mediators of the actions of colloidal bismuth subcitrate.^{10-12 16 24 32-36} The fact that colloidal bismuth subcitrate retains its cytoprotective action in the presence of a cyclooxygenase inhibitor, however, suggests that other factors may also be involved.¹⁰ Epidermal growth factor has been shown to bind to colloidal bismuth subcitrate in a pH dependent manner, such that it accumulates at the site of gastric damage. Although this indicates that epidermal growth factor may play a role in the healing action of colloidal bismuth subcitrate, the fact that sialoadenectomy does not impair the gastroprotective action of the latter signifies that epidermal growth factor may not be involved in this aspect of the compound's action.¹³⁻¹⁵ It is also

feasible that changes in other gastric hormones, such as increased gastrin or decreased somatostatin values could also have a role in mediating the trophic actions of colloidal bismuth subcitrate. So far, however, there is no evidence that colloidal bismuth subcitrate affects either of these factors.

It is difficult to determine why colloidal bismuth subcitrate causes a decrease in the rate of cell division in young animals but an increase in old animals, but the extensive lesions found in the old animals contrasted with the total lack of lesions in the young animals. Its action as a healing agent has been associated with an increase in cellular turnover, whereas its long term administration as a cytoprotective agent in the absence of tissue damage is associated with a decrease in mitotic activity.¹⁶ The differential response of the stem cells to colloidal bismuth subcitrate in cytoprotection and tissue healing suggest that different mechanisms of action are involved.

In the basal region there was a significant increase in the numbers of parietal cells found in the old compared with young control animals. Other work has shown that gastric age related atrophy is associated with a decline in both the basal and pentagastrin stimulated acid secretion.³⁷ The present findings indicate that the age related change in acid secretion is a result of a decrease in secretory ability rather than a decline in parietal cell numbers. The administration of colloidal bismuth subcitrate resulted in a decline in the number of parietal cells found in old animals to values that were comparable with those found in young control animals. The fact that the number of parietal cells found in the basal region in young animals remained unchanged after colloidal bismuth administration suggests that this compound does not affect this cell population in intact healthy tissue. The results from the old animals, however, indicate that colloidal bismuth subcitrate can counteract the increase in parietal cell numbers that occurs with age.

The present results suggest that colloidal bismuth subcitrate may have beneficial effects on the age related deterioration of gastric tissue and may decrease the susceptibility of the ageing stomach to aggressive factors.

This work was supported by a research grant from Gist-brocades, The Netherlands.

- 1 Tytgat GNJ. Colloidal bismuth subcitrate in peptic ulcer - a review. *Digestion* 1987; 37 (Suppl 2): 31-41.
- 2 Wieriks J, Hesppe W, Jaitly KD, Koekkoek PH, Lavy UI. Pharmacological properties of colloidal bismuth subcitrate (CBS, De-Nol). *Scand J Gastroenterol* 1982; 17 (Suppl 80): 11-16.
- 3 Koelz, HR. Protective drugs in the treatment of gastroduodenal ulcer disease. *Scand J Gastroenterol* 1986; 21 (Suppl 125): 156-63.
- 4 Tasman-Jones C, Maher C, Thomsen L, Lee SP, Vanderwee M. Mucosal defences and gastroduodenal disease. *Digestion* 1987; 37 (Suppl 2): 1-7.
- 5 Koo J, Hoo J, Lam SK, Wong J, Ong GB. Selective coating of gastric ulcer by tripotassium dicitrato bismuthate in the rat. *Gastroenterology* 1982; 82: 864-70.
- 6 Elder JB. Recent experimental and clinical studies on the pharmacology of colloidal bismuth subcitrate. *Scand J Gastroent* 1986; 21 (Suppl 122): 14-16.
- 7 Roberts NV, Taylor WH. The effect of tripotassium dicitrato bismuthate (De-Nol) upon the individual human pepsins. *Clin Sci* 1982; 63: 65.
- 8 Stiel D, Peters TJ. Tripotassium dicitrato bismuthate (De-Nol) binds conjugated bile acids *in vitro*. A possible mechanism in gastric ulcer healing. *Proc Austral Soc Med Res* 1983; 16: 18.

- 9 Marshal BJ, McGeachie DB, Rogers PA, Glancy RJ. Pyloric *Campylobacter* infection and gastroduodenal disease. *Med J Australia* 1985; 142: 439-44.
- 10 Konturek SJ, Radecki T, Piasticki I, Brzozowski T, Drozdowicz D. Gastrocytoprotection by colloidal bismuth subcitrate (De-Nol) and sucralfate. Role of endogenous prostaglandins. *Gut* 1987; 28: 201-5.
- 11 Hall DWR, van den Hoven WE. Gastric mucosa protection and prostaglandin E₂ generation in rats by colloidal bismuth subcitrate (De-Nol). *Arch Intern Pharmacodyn Therap* 1987; 286: 308-19.
- 12 Konturek SJ, Bilski J, Kwiecien N, Obtulowicz W, Kopp B, Olesky J. De-Nol stimulates gastric and duodenal alkaline secretion through prostaglandin dependent mechanism. *Gut* 1987; 28: 1557-63.
- 13 Slomiany BL, Bilski J, Sarosiek J, Liau YH, Slomiany A. Colloidal bismuth subcitrate (De-Nol) inhibits peptic degradation of epidermal growth factor. *Gastroenterology* 1988; 94: A431.
- 14 Konturek SJ, Dembinski A, Warzecha Z, Brzozowski T, Gregory H. Role of epidermal growth factor in healing of chronic gastroduodenal ulcers in rats. *Gastroenterology* 1988; 94: 1300-7.
- 15 Konturek SJ, Dembinski A, Warzecha Z, Bielanski W, Brzozowski T, Drozdowicz D. Epidermal growth factor (EGF) in the gastroprotective and ulcer healing actions of colloidal bismuth subcitrate (De-Nol) in rats. *Gut* 1988; 29: 894-902.
- 16 Hinsull SM. The effect of repeated colloidal bismuth subcitrate treatment on the response of the rat gastric mucosa to the presence of luminal ethanol. *Gut* 1990; 31: 389-96.
- 17 Bellamy D. Degenerative diseases of ageing as problems of natural selection. *Gerontology* 1988; 34: 304-26.
- 18 Farinati F, Cardin F, DiMario F, Battaglia G, Cannizzaro R, Penon G, Naccarato R. Gastric ulcer and stomach aging: pathophysiological and clinical implications. *Gerontology* 1988; 34: 297-303.
- 19 Llewellyn JG, Pritchard MH. Influence of age and disease state in nonsteroidal antiinflammatory drug associated gastric bleeding. *J Rheumatol* 1988; 15: 691-4.
- 20 Greenberg RE. The influence of aging on gastric mucosal prostaglandins and adaptive cytoprotection. *Gastroenterology* 1988; 94: A155.
- 21 Majumdar APN, Edgerton EA, Dayal Y, Murthy SNS. Gastrin: levels and trophic action during advancing age. *Am J Physiol* 1988; 256: G538-42.
- 22 Gordon H, Sweets HH. A simple method for silver impregnation. *Am J Pathol* 1936; 12: 545-52.
- 23 Hinsull SM. Age related degeneration of the rat stomach. *J Clin Exp Gerontol* 1990; 12: 95-113.
- 24 Grant R, Grossman MI, Ivy AC. Histological changes in the gastric mucosa during digestion and their relationship to mucosal growth. *Gastroenterology* 1953; 25: 218-25.
- 25 Van Den Hoven WE, Birtwhistle RDR, Hall DWR. Morphologic evaluation of gastric mucosal protection by colloidal bismuth subcitrate (De-Nol). *Int J Tiss Reac* 1988; X: 297-304.
- 26 Ito S. Functional gastric morphology. In: Johnson LR ed. *Physiology of the gastrointestinal tract*. New York: Raven Press 1987 (2nd ed): 817-51.
- 27 Ito S, Lacy ER. Morphology of rat gastric mucosal damage, defence and restitution in the presence of luminal ethanol. *Gastroenterology* 1985; 88: 250-60.
- 28 Silen W, Ito S. Mechanisms for rapid re-epithelialization of the gastric mucosal surface. *Ann Rev Physiol* 1985; 47: 217-29.
- 29 Neutra MR, Forstner JF. Gastrointestinal mucus: synthesis, secretion and function. In: Johnson LR ed. *Physiology of the gastrointestinal tract*. New York: Raven Press 1987 (2nd ed): 975-1009.
- 30 Allen A, Garner A. Mucus and bicarbonate secretion in the stomach and their possible role in mucosal protection. *Gut* 1980; 21: 249-62.
- 31 Younan F, Pearson J, Allen A, Venables C. Changes in the structure of the mucous gel on the mucosal surface of the stomach in association with peptic ulcer disease. *Gastroenterology* 1982; 82: 827-31.
- 32 Greenberg RE. The influence of aging on gastric mucosal prostaglandins and adaptive cytoprotection. *Gastroenterology* 1988; 94: A155.
- 33 Singh P, Rae-Venter B, Townsend CM, Khalil T, Thompson JC. Gastrin receptors in normal and malignant gastrointestinal mucosa: age-related changes. *Am J Physiol* 1985; 249: G761-9.
- 34 Konturek SJ, Radecki T, Piastucki I, Drozdowicz D. Studies on the gastroprotective and ulcer-healing effects of colloidal bismuth subcitrate. *Digestion* 1987; 37: 8-15.
- 35 Terano A, Ota S, Mach T, et al. Prostaglandin protects against taurocholate-induced damage to rat gastric mucosal cell culture. *Gastroenterology* 1987; 92: 669-77.
- 36 Konturek SJ, Piastucki I, Brzozowski T, et al. Role of locally generated prostaglandins in adaptive gastric cytoprotection. *Dig Dis Sci* 1982; 27: 967-71.
- 37 Hawkey CJ, Rampton DS. Prostaglandins in the gastrointestinal mucosa: are they important in its function, disease or treatment? *Gastroenterology* 1985; 89: 1162-88.
- 38 Tytgat GNJ, Offerhaus GJA, Van Minnen AJ, Everts V, Hensen-Logmans SC, Samson G. Influence of oral 15(R)-15-methyl prostaglandin E₂ on human gastric mucosa. *Gastroenterology* 1986; 90: 1111-20.
- 39 Majumdar APN, Maitra R, Edgerton EA. Gastric secretion during aging in rats and effects of pengastrin. *Gastroenterology* 1988; 94: A278.