

## CASE REPORTS

## Familial and idiopathic colonic varices: an unusual cause of lower gastrointestinal haemorrhage

J P Iredale, P Ridings, F P McGinn, M J P Arthur

### Abstract

**A patient is described presenting with an acute lower gastrointestinal haemorrhage as a result of extensive colonic varices. Further investigation revealed that there were no oesophageal varices or splenomegaly. Liver biopsy showed grade II fatty change only, with no other specific or significant pathological features. Transhepatic portography showed a raised portal pressure (20 mm/Hg) but the portal system was patent throughout. There was an abnormal leash of vessels in the caecum thought to represent a variceal plexus. This patient was diagnosed as having idiopathic colonic varices. This case is discussed together with nine other reports of idiopathic colonic varices from the published literature. Four of these reports describe idiopathic colonic varices in more than one member of the same family. Possible modes of inheritance, aetiology of variceal change, natural history, and prognosis are discussed.**

(Gut 1992; 33: 1285-1288)

There are approximately 70 reports in the literature of bleeding colonic varices. This rare cause of lower gastrointestinal haemorrhage is almost invariably associated with liver cirrhosis and consequent portal hypertension<sup>1</sup> or portal venous obstruction.<sup>2</sup> We report a patient who presented with bleeding colonic varices. He has been extensively investigated and we conclude that he has idiopathic colonic varices. We describe his case and review the small number of similar cases reported in the literature.

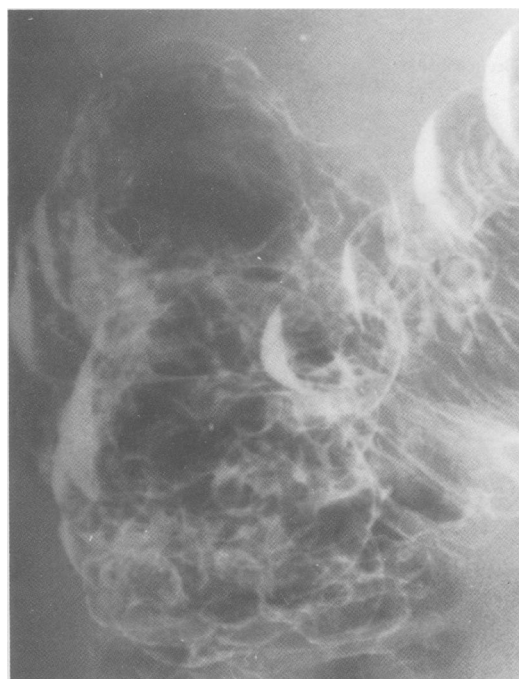
### Case report

Mr DM is a 58 year old white man who works as a labourer at an oil refinery. He presented with a 10 week history of frank rectal bleeding associated with transient left iliac fossa pain. There was no associated change in bowel habit nor any weight loss. He had passed blood per rectum 21 years previously at which stage he was diagnosed as having haemorrhoids and had been treated conservatively. Bleeding had ceased spontaneously and had not recurred. There was no relevant family history. He drank 8 units of alcohol a week and smoked a pipe which he did not inhale.

On examination he was mildly obese and looked well. His pulse rate was 90 beats per

minute and his blood pressure 140/90 mm Hg. Examination of the abdomen and rectal examination were both normal. Sigmoidoscopy to 15 cm revealed what was thought to be a polyp, this was biopsied and histology revealed normal rectal mucosa only. A barium enema was carried out and was reported as showing 'polyposis coli' (Figure). Colonoscopy was undertaken and showed extensive colonic varices. Gastroscopy showed a normal lower oesophagus. Infrared endoscopy excluded dilated submucosal veins in the stomach or oesophagus. Haemoglobin was 14.9 g/l. Clotting studies were normal, ferritin, alphafetoprotein, autoantibody profile, and immunoglobulins were all normal. Hepatitis serology was negative. The liver was bright on sonographic scan, consistent with fatty change, the spleen was normal and there was no evidence of an abnormal portal vein or variceal change around the cardia and splenic hilum.

Superior and inferior mesenteric arteriography was undertaken. This showed a normal arterial anatomy with no evidence of early venous filling, in general the venous anatomy was normal although the veins of the rectum and



Barium enema, view of transverse colon and hepatic flexure showing colonic varices which were misdiagnosed as polyposis coli.

Medicine II, University  
of Southampton,  
Southampton  
J P Iredale  
M J P Arthur

Department of Surgery,  
Southampton General  
Hospital, Southampton  
P Ridings  
F P McGinn

Correspondence to:  
Dr J P Iredale, Lecturer in  
Medicine, Medicine II,  
Southampton General  
Hospital, Tremona Road,  
Southampton, Hampshire  
SO9 4XY.

Accepted for publication  
7 January 1992

*Previous reports of idiopathic and familial colonic varices*

Case report and reference no	Sex	Age	Presentation	Family history	Comment
Hardy, 1967					
5 a	M	20	} Acute rectal bleeding	+	Patient (a) had SMV pressure 55 cm H <sub>2</sub> O. All patients ultimately required surgery for abnormal ileocolic artery which encircled and compressed SMV.
b	M	-		+	
c	F	20	10 year history rectal bleeding	+	
Solis-Herruzo, 1977					
6 a	F	18	7 year history rectal bleeding	+	Normal portogram. Portal pressure 12 cm H <sub>2</sub> O. Liver function test normal. Extensively investigated. At laparotomy varices throughout colon. No apparent cause.
b	F	26	15 year history rectal bleeding	+	Liver function tests normal
Weingart, 1982					
13	M	70	63 year history rectal bleeding	-	Parents and 3 siblings of case 7a underwent colonoscopy - all were normal Bled profusely after biopsy of varix thought to be a polyp. Varices throughout colon. Treated conservatively
Lieberman, 1983					
11	M	37	19 year history rectal bleeding	-	Hepatitis B surface antigen positive. Cirrhotic portal hypertension not excluded. Not considered further as a case of 'idiopathic' colonic varices
Hawkey, 1984					
7 a	M	66	41 year history rectal bleeding	+	Varices throughout colon. Normal barium meal. Portal vein patent and liver normal on ultrasound scan. Barium enema reported as polyposis coli
b	F	71	50 year history rectal bleeding	+	Varices noted from jejunum to rectum at laparotomy in 1944. Liver Bx at operation 'normal'. Both cases (8) treated conservatively
Planus, 1988					
10	M	75	Malaena duration not stated	-	Idiopathic nature of varices 'dubious'. Uneven liver texture at laparoscopy. Portal fibrosis on liver biopsy. Oesophageal varices at endoscopy. Wedged hepatic pressure stated to be similar to hepatic venous pressure. Managed conservatively
Beerman, 1988					
8 a	M	65	Mass felt on rectal examination	+	Varices throughout colon. Barium enema reported as polyposis coli. Severe rectal bleeding after polyp biopsied
b	F	65	13 year history rectal bleeding	+	Varices throughout colon. Dukes's B carcinoma colon resected 1981 at which time no other abnormality noted. Misdiagnosed as polyposis coli on barium enema. Both cases (9) managed conservatively
Isbister, 1989					
9	F	18	8 month history rectal bleeding	-	Portal pressure 22 cm H <sub>2</sub> O. Normal portogram. Mesenteric arteriography normal. Normal oesophagus. Varices in ascending colon and sigmoid. At laparotomy evidence of caecal arteriovenous malformation. Initially treated conservatively with transfusion. Ultimately required extended right hemicolectomy
Nikolopoulos, 1990					
12	M	22		-	Extensive colonic varices showed at colonoscopy and angiography. Liver disease not excluded. Significant variceal haemorrhage at presentation necessitated subtotal colectomy

sigmoid were prominent. Transhepatic portography and portal pressure studies showed a raised portal venous pressure, the values being: inferior mesenteric vein 20 mm Hg, distal splenic vein 19 mm Hg, portal vein 18 mm Hg. Portographic studies showed an abnormal series of tortuous submucosal veins in the caecum, thought to represent a caecal variceal plexus. Other runs confirmed that the portal system was patent throughout. A liver biopsy undertaken at the time of portography showed the histological features of grade II fatty change with no fibrosis or other specific or significant pathological features.

### Discussion

There are approximately 70 reports in the literature of bleeding from colonic varices. Compared with oesophageal varices or other upper gastrointestinal lesions, colonic varices are an infrequent source of blood loss in cirrhotic patients, but the majority of patients who present with bleeding from colonic varices have cirrhosis.<sup>1</sup> Bleeding from colonic varices has been reported to occur from 2.5% of patients attending for sclerotherapy to oesophageal varices,<sup>3</sup> and between 3.6% and 56% of cirrhotic patients have been shown to have rectal varices.<sup>2,4</sup> We have identified a patient with extensive colonic varices (Figure) which we conclude to be 'idiopathic.' Our investigations of this patient have excluded significant liver disease or any evidence of portal or mesenteric venous thrombosis. His portal venous pressure was shown to be above the upper limit of the normal range (10 mm Hg). It is possible that an arteriovenous anomaly may have caused the raised pressure and the development of varices but there was no angiographic evidence of such an abnormality.

We have identified nine other reports, comprising 14 patients, of idiopathic colonic varices in the literature (Table). Four of these reports describe an index patient with at least one first degree relative who has evidence of colonic varices.<sup>5-8</sup> Before concluding that these represent true idiopathic colonic varices significant liver disease and portal venous obstruction must obviously be excluded. In only two of the eight reports<sup>6,9</sup> has investigation been adequate to exclude portal hypertension, liver disease and oesophageal varices. Two of the other reported patients underwent liver biopsy.<sup>7b,10</sup> Both were interpreted as having no significant histological features although that reported by Planus<sup>10</sup> was said to show 'portal fibrosis' therefore the 'idiopathic' nature of varices must be viewed with some reticence in this case. In addition, three patients were said to have a normal liver at laparotomy<sup>5,8b,9</sup> and in a fourth a normal ultrasound scan texture was reported.<sup>7a</sup> Liver function tests and serological markers of hepatitis are reported in four cases.<sup>7a,9,11,12</sup> One of these patients<sup>11</sup> was shown to have hepatitis B surface antigenaemia. There is no documentation of this patient's portal venous anatomy or pressure. Because of the presence of such a significant risk factor for cirrhosis, this report<sup>11</sup> is not considered further in the review of idiopathic colonic varices.

In addition to the reports in which portal venous pressure and anatomy was documented,<sup>5a 6a 9 12</sup> indirect evidence of portal vein patency is presented for patients 5a and 10. Oesophageal varices were excluded in five patients.<sup>6a 7a 7b 8 12</sup> Thus in three cases<sup>6b 8a 13</sup> there is no documented evidence that might exclude cirrhosis or portal/mesenteric vein obstruction. Lastly, in patient 8b the varices documented to be throughout the colon at presentation had not been noted seven years previously when the patient underwent resection of a Dukes's B carcinoma of the descending colon. Colonic varices have been reported as a complication of colonic surgery<sup>14</sup> and as a result of adhesional obstruction to,<sup>15</sup> or tumour invasion of,<sup>16</sup> the mesenteric venous system.

Case 6a was extensively investigated and together with her aunt<sup>6b</sup> appears to represent a true case of familial idiopathic colonic varices. Despite the possibility that case 8b may have resulted from previous colonic surgery, the occurrence of varices in a first degree relative with no apparent predisposing factor means that the two patients reported by Beerman,<sup>8a,b</sup> like those reported by Hawkey<sup>7a,b</sup> and Solis-Herruzo,<sup>6a,b</sup> may also represent true familial colonic varices, a distinct clinical entity. There is some evidence that portal venous pressure is not raised in these patients and we must therefore assume they result from congenital vascular anomalies. The numbers are too small to draw any firm conclusion on possible modes of inheritance. The fact that case 6a's siblings and parents all had normal colonoscopies, however, would favour a recessive rather than dominant pattern if the inheritance is autosomal.

The age of presentation and treatment of patients with idiopathic colonic varices falls into two groups. Those who ultimately undergo laparotomy present in their 20s or younger. Patients 5a, 5b, and 5c presented with severe bleeding and ultimately a vascular anomaly was shown. This is perhaps the most remarkable of all the reports, comprising three first degree relatives, all of whom presented with significant rectal bleeding and evidence of mesenteric venous hypertension, in whom the same annular aneurysm of the ileocaecocolic artery was found. This bizarre vascular anomaly resulted in compression of a mesenteric vein with consequent variceal change distally. Each required vascular surgery. Case 6a also underwent exploratory laparotomy but a structural cause for colonic varices was not identified. In case 9 an attempt to manage the patient conservatively with repeated transfusion was attempted. Recurrent bleeds and the need for transfusion, however, meant that the patient missed significant amounts of schooling and surgery was therefore undertaken. Case 12 underwent subtotal colectomy for uncontrolled rectal bleeding within 12 days of presentation.

In contrast, the age of presentation in cases 7a, 7b, 8a, 8b, 10, 13 was from the fifth decade onwards. It is of interest that a history of transient rectal bleeding extended back to the third decade in two patients of these<sup>7a,b</sup> and to the first decade in one,<sup>13</sup> suggesting the presence of a congenital vascular anomaly. Late presentation

may be the result of vascular degenerative change. The proposition that simple degenerative ectasia leads to development of extensive colonic varices seems rather tenuous, however. It is important to note that even in cirrhotic and non-cirrhotic portal hypertension it is unusual for colonic varices to extend beyond the anorectal area,<sup>2</sup> in contrast with these patients. We suggest that all of these patients had a significant inborn vascular anomaly. This group were managed conservatively with blood transfusion only, no deaths as a result of variceal bleeding are reported, and although the numbers are small, it would seem reasonable to adopt a conservative approach to those patients presenting in their fifth decade or later. It is salutary to note that cases 7a, 8a, 8b, and our patient were diagnosed as having polyposis coli after barium enema. Given the familial nature of idiopathic colonic varices and the apparent similarity of the radiographic and sigmoidoscopic appearances of colonic varices to polyps, misdiagnosis, and inappropriate biopsy remain potential pitfalls in the diagnosis of this condition. The prognosis of idiopathic colonic varices would seem to be good at all ages compared with cirrhotic varices,<sup>4</sup> this may be related to low pressure in the varices as well as the absence of significant hepatocellular disease.

Idiopathic colonic varices are a very rare cause of rectal bleeding which can only be confidently diagnosed after liver disease and portal venous obstruction have been excluded. They may present at any stage from the first decade of life onwards. Presentation at a young age is associated with significant haemorrhage and there may be an identifiable vascular anomaly. Surgical treatment to prevent further haemorrhage is usually required in these patients. Presentation in later life may be successfully treated conservatively. In this group, the condition may be misdiagnosed as polyposis coli particularly if other members of the family are affected. In all age groups there may be a positive family history with a first degree relative affected and this may relate to an inherited mesenteric vascular anomaly. There is no evidence to suggest that these patients constitute a homogenous group, indeed they may represent a common result of a series of inherited or degenerative vascular anomalies. In all age groups the condition carries a good prognosis.

- 1 Gudjonsson H, Zeiter D, Gamelli R, Kaye M. Colonic varices: report of an unusual case diagnosed by radionuclide scanning, with review of the literature. *Gastroenterology* 1986; 91: 1543-7.
- 2 Chawla Y, Dilawari JB. Anorectal varices - their frequency in cirrhotic and non-cirrhotic portal hypertension. *Gut* 1991; 32: 309-11.
- 3 Fouch PG, Sirak MV. Colonic variceal haemorrhage after endoscopic infection sclerosis of oesophageal varices a report of three cases. *Am J Gastroenterol* 1984; 79: 756-60.
- 4 Rabinovitz M, Shade R, Dindzaus VJ, Belle SH, Van Thiel DH, Gavaler JS. Colonic disease in cirrhosis. *Gastroenterology* 1990; 99: 195-9.
- 5 Hardy M, Barbin J-Y, Caroli J. Hypertension mesenterique familiale. *Revue des Maladies de Foie* 1967; 6: 236-46.
- 6 Solis-Herruzo JA. Familial varices of the colon diagnosed by colonoscopy. *Gastrointest Endosc* 1977; 24: 85-6.
- 7 Hawkey CJ, Amar SS, Daintith HAM, Toghil PJ. Familial varices of the colon occurring without evidence of portal hypertension. *Br J Radiol* 1985; 58: 677-9.
- 8 Beerman EM, Lagaay MB, Van-Nonhuys JM, Overbosh D. Familial varices of the colon. *Endoscopy* 1988; 20: 270-2.
- 9 Isbister WH, Pease CW, Delahun B. Colonic varices, report of a case. *Dis Col Rectum* 1989; 32: 524-7.

- 10 Planus R, Boix J, de Leon R, Pedro-Botet ML, Humbert P, Villagrasa M. Bleeding colonic varices in a patient with idiopathic portal hypertension. *J Clin Gastroenterol* 1988; **10**: 235.
- 11 Lieberman DA, Krippaeline WW, Melnyk CS. Colonic varices due to intestinal cavernous hemangiomas. *Dig Dis Sci* 1983; **28**: 852-8.
- 12 Nickolopoulos N, Xynas E, Datnakis K, Kasapidis P, Vassilakis JS. Varicosis coli totalis: report of a case of idiopathic aetiology. *Digestion* 1990; **47**: 232-5.
- 13 Weingart J, Hochter W, Ottenjann R. Varices of the entire colon - an unusual cause of recurrent intestinal bleeding. *Endoscopy* 1982; **14**: 69-70.
- 14 Arbona JL, Lichtenstein JE, Spies JB, Hyatt JR Jr. Colonic varices as a complication of colonic surgery. *Gastrointest Radiol* 1987; **12**: 350-2.
- 15 Manzi D, Samanta AK. Adhesion related colonic varices. *J Clin Gastroenterol* 1985; **7**: 71-5.
- 16 Grangvist S. Colonic varices caused by a carcinoid tumour. *Gastrointest Radiol* 1984; **9**: 269-76.