

Pigbel-like syndrome in a vegetarian in Oxford

J M Farrant, Z Traill, C Conlon, B Warren, N Mortensen, F V Gleeson, D P Jewell

Abstract

Enterocolitis necroticans or pigbel is a rare condition characteristically affecting chronically malnourished people who abruptly increase their intake of protein. The classic presentation of the disease as seen in the highlands of Papua New Guinea is that of a necrotising enterocolitis after the ritual ingestion of contaminated pork. In this context, the presentation of the same disease in a well nourished white vegetarian in Oxford was all the more intriguing.

(Gut 1996; 39: 336-337)

Keywords: pigbel, enterocolitis necroticans, vegetarian.

Case report

A 43 year old white female tropical horticulturalist was admitted as an emergency. She complained of vomiting and bloody diarrhoea. She had recently returned from Western Samoa where she had been involved in research for four years. She had been unwell for two weeks with intermittent diarrhoea, anorexia, and fever. Her husband, who had been accompanying her, had diarrhoea for two days several weeks before, which had resolved spontaneously. She was a vegetarian who three months previously had regularly eaten a large amount of pasta and sweet potatoes while training for an international outrigger canoeing

competition. Following this and shortly before becoming ill she had been on holiday in Java where she had consumed a large amount of fish, fermented soybean, and peanut butter sauce. Her brother had Crohn's disease and an ileostomy.

On examination she appeared unwell with a temperature of 39°C, pulse rate of 120 per minute, and blood pressure of 150/80 mm Hg. The abdomen was generally soft, apart from a tender mass in the right iliac fossa. There was a fleshy violaceous perianal area and, on sigmoidoscopy, the rectal mucosa was friable. Blood tests showed the following: the haemoglobin was 15.3 g/dl; white blood cell count $10 \times 10^9/l$, platelets $453 \times 10^9/l$, ESR 30 mm/h, and C reactive protein 240 mg/l. The liver function tests were normal, apart from an albumin of 19, and uncorrected calcium of 1.83 mmol/l. The plasma phosphate was normal. No malaria parasites were seen on a thick blood film. A 'hot' stool was examined for *Entamoeba histolytica* and was negative. The stool was also negative for cysts, ova, and parasites and culture was negative. Chest radiography was normal showing no free intraperitoneal air and abdominal x ray showed dilated small bowel with an apparent mass containing a small amount of gas occupying most of the right side of the abdomen (Fig 1). Ultrasound of the abdomen showed gross thickening of the caecum and proximal ascending colon with dilated small bowel loops and a small amount of free intraperitoneal fluid. Small bowel enema confirmed dilatation of the small bowel loops with a considerable delay of six hours before barium reached the caecum (Fig 2). Abdominal computed

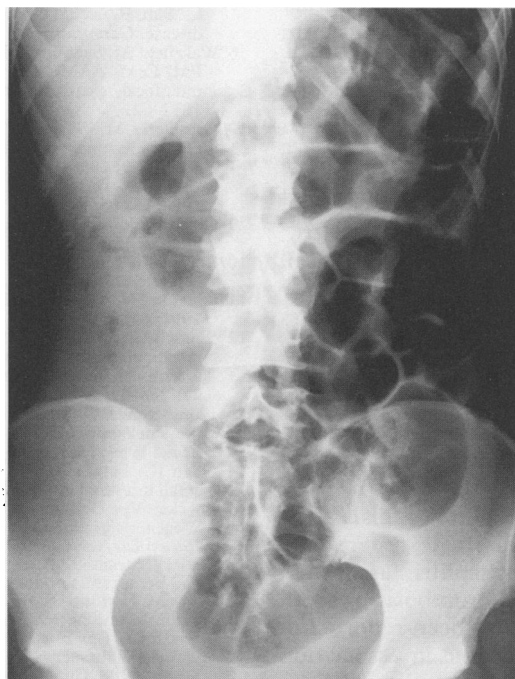

Figure 1: Plain abdominal radiograph showing dilated small intestine with an apparent mass containing a small amount of gas occupying most of the right side of the abdomen.

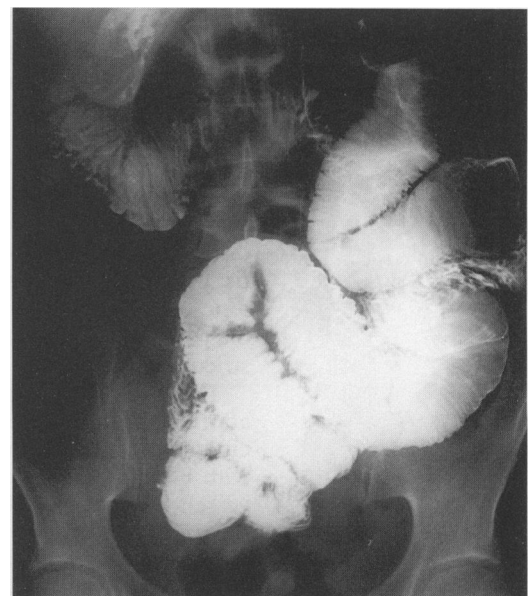


Figure 2: Small bowel enema showing dilatation of the small bowel.

Gastroenterology Unit, Radcliffe Infirmary, Oxford

J M Farrant
Z Traill
C Conlon
B Warren
N Mortensen
F V Gleeson
D P Jewell

Correspondence to:
Dr D P Jewell,
Gastroenterology Unit,
Radcliffe Infirmary,
Woodstock Road, Oxford
OX2 6HE.

Accepted for publication
27 February 1996

tomography showed gross thickening of the caecum and ascending colon.

The differential diagnosis was of Crohn's disease, infectious colitis including amoebic colitis, and pigbel. The patient was treated with intravenous fluids and intravenous metronidazole prior to laparotomy. The findings were of a thick walled but fragile colon with adhesions in the right iliac fossa. The small bowel was slightly dilated but otherwise normal. An ileo-caecal resection was carried out and a right iliac fossa ileostomy and mucous fistula were fashioned. Macroscopically the resected specimen contained discrete ulcers confined to the caecum. Microscopy showed the presence of copious Gram positive rods with the characteristic appearance of *Clostridium perfringens*. The patient made an uneventful recovery from surgery and has subsequently been re-admitted for re-anastomosis to restore continuity of bowel. Subsequently, antibody to the β toxin of *Clostridium perfringens* type C was not detected.

Discussion

This is the first report of enterocolitis necroticans caused by *Clostridium perfringens* in a white adult vegetarian. Enterocolitis necroticans was first described in Germany and Norway in the late 1940s when it was termed 'darmbrand' (literally bowel fire).¹ This was described in malnourished people who became ill after consuming large quantities of often rancid meat to which they were not accustomed. *Clostridium perfringens* type C was cultured from the intestinal lumen and anti-toxin was identified in some patients during convalescence. The term 'pigbel' was used in descriptions of the same condition in children in Papua New Guinea in the 1960s.² Studies then found *Clostridium perfringens* type C to be present in the soil and in pig faeces. This organism produces a β toxin, which has severe necrotising effects on tissues. An important co-factor in causing the disease is a low trypsin activity in the intestinal contents, which may result from the ingestion of foods containing anti-trypsins such as sweet potato, soybean, and peanut

sauce. This, in combination with a low protein diet, is believed to impair the ability of the intestine to inactivate the toxin.³ Since these early reports, the condition has been described in all ages in many countries including China,⁴ Nepal,⁵ India,⁶ and Uganda.⁷ Those affected are usually from a low socioeconomic group and there is a male preponderance. Pork ingestion is not invariably a feature because cases have been seen following a meal of raw sweet potato, peanuts, and water chestnut.⁴ In areas where the disease is frequent, immunisation offers the best control. The incidence of pigbel among children in Papua New Guinea fell rapidly during the early '80s with the introduction of a vaccine directed against the β toxin.⁸

The diagnosis of pigbel in our case is a clinical one supported by histopathology. Culture of the colonic contents was not performed. Subsequent serology for antibody to the *Clostridium perfringens* type C beta toxin was negative but this is known to occur in 50% of patients with pigbel. Our patient developed the disease as a result of the dramatic change in her diet from a comparatively low protein diet with some anti-trypsin activity while training for her outrigger canoeing competition to a higher protein diet with even more anti-trypsin activity while on holiday in Java. This sequence of events is sufficient to provide a suitable environment for growth of *Clostridium perfringens* type C in the bowel with reduced inactivation of the toxin by endogenous trypsin.

- 1 Markowitz SM. Other clostridial infections. In: Strickland GT, ed. *Hunter's tropical medicine*. Philadelphia: WB Saunders, 1991: 446-8.
- 2 Murrell TGC, Roth L, Egerton J, Samels J, Walker PD. Pigbel: enteritis necroticans. A study in diagnosis and management. *Lancet* 1966; i: 217-22.
- 3 Lawrence G, Walker PD. Pathogenesis of enteritis necroticans in Papua New Guinea. *Lancet* 1976; i: 125-6.
- 4 Shann F, Lawrence G, Jun-di P. Enteritis necroticans in China. *Lancet* 1979; i: 1083-4.
- 5 Murrell TGC. Enteritis necroticans in Nepal. *Lancet* 1979; i: 279.
- 6 Pujari BD, Deodhare SG. Necrotizing enteritis. *Br J Surg* 1980; 67: 254-6.
- 7 Wright DH, Stanfield JP. Enteritis necroticans in Uganda. *J Pediatr* 1967; 71: 264-8.
- 8 Lawrence GW, Lehmann D, Anian G, Coakley CA, Saleu G, Barker MJ, et al. Impact of active immunisation against enteritis necroticans in Papua New Guinea. *Lancet* 1990; 336: 1165-7.