

# Proximal Gastric Vagotomy Compared with Vagotomy and Antrectomy and Selective Gastric Vagotomy and Pyloroplasty

JOHN L. SAWYERS, M.D., J. L. HERRINGTON, JR., M.D., D. PATRICK BURNEY, M.D.

A prospective, randomized study of proximal gastric vagotomy without drainage (PGV) was done in 174 adult men with chronic duodenal ulcer intractable to medical therapy. PGV was randomized against truncal vagotomy with antrectomy (TV + A) and against selective gastric vagotomy with Finney pyloroplasty (SGV + P). Postgastrectomy sequelae (dumping, diarrhea and reflux gastritis) were less after PGV. One patient after PGV developed a recurrent ulcer as did one patient after SGV + P. Two patients developed gastric ulcers after PGV. Good to excellent results (Visick I and II) were obtained in 96% of patients with PGV, 94% with TV + A and 86% with SGV + P. Follow-up studies were from six months to four years.

PROXIMAL GASTRIC VAGOTOMY without drainage is being used with increasing frequency in the surgical treatment of duodenal ulcer disease, but few prospective randomized studies have been done comparing this new operation with more established procedures.<sup>7</sup> This study was designed to evaluate proximal gastric vagotomy without drainage as a practical alternative to two accepted operations (truncal vagotomy-antrectomy and selective gastric vagotomy-pyloroplasty) in the surgical treatment of duodenal ulcer.

## Materials and Methods

### Patient Selection

Only adult men with chronic duodenal ulcer intractable to medical therapy were admitted to the study. Patients may have had bleeding episodes from their duodenal ulcer in the past but were not considered for this study if active bleeding required emergency operation. Patients with acute perforation of a duodenal ulcer were also excluded as were patients with pyloric obstruction.

*From the Department of Surgery, Vanderbilt University School of Medicine, and the Surgical Services of Metropolitan Nashville General, Nashville Veterans Administration, and St. Thomas Hospitals, Nashville, Tennessee*

Patients had to be suitable candidates for either operation. Cards randomized by the biostatistical department and sealed in an envelope were used to determine the type of operation. Only after the patient's abdominal cavity had been explored and the surgeon decided that there was no contraindication to either operation, was the envelope opened. The patients were informed before operation that their surgical procedure would be randomized. This study was approved by the University's Human Rights Committee.

A total of 174 patients have been entered into the study which began four years ago. One hundred patients were randomized by JLH, Jr. into a trial of proximal gastric vagotomy (PGV) vs. truncal vagotomy-antrectomy (TV + A), and 74 patients were randomized by JLS into the trial of PGV vs. selective gastric vagotomy-pyloroplasty (SGV + P). Follow-up evaluation which was obtained on all 173 surviving patients extends from a minimum of six months up to four years (Table 1).

### Operative Technic

Proximal gastric vagotomy was based on the operative technic described by Johnston and Wilkinson<sup>10</sup> and Goligher.<sup>2</sup> To maintain a practical surgical approach, no intraoperative test was made to determine the completeness of vagotomy. The antral-parietal cell border was determined anatomically by the entrance of the branches of the anterior nerve of Latarjet onto the gastric antrum (Crow's foot). This site was usually seven centimeters proximal to the pylorus. The anterior vagal trunk was encircled with a soft rubber tube (vesselloop) for identification purposes. The gastro-

Presented at the Annual Meeting of the American Surgical Association, Boca Raton, Florida, March 23-25, 1977.

Reprint requests: John L. Sawyers, M.D., St. Thomas Hospital, P.O. Box 380, Nashville, Tennessee 37202.

TABLE 1. Length of Follow-up

|                 | No. Pts. | %    |
|-----------------|----------|------|
| 3-4 Years       | 60       | (35) |
| 2-3 Years       | 47       | (27) |
| 1-2 Years       | 39       | (22) |
| 6 Months-1 Year | 27       | (16) |
|                 | 173      |      |

Follow-up studies extending from 6 months to 4 years were obtained on the 173 surviving patients.

hepatic omentum was opened between the hepatic vagal branches and the nerves of Latarjet (Fig. 1). Denervation of the stomach was begun by detaching the anterior leaf of the lesser omentum from the stomach starting just above the insertion of the anterior nerve of Latarjet onto the antrum and continued cephalad to the esophagogastric junction and crossing over the anterior wall of the esophagus (Fig. 2). After completing the anterior part of the dissection, the posterior leaf of the lesser omentum was detached from the lesser curvature of the stomach (Fig. 3). The dissection was then carried cephalad to a point at least five centimeters above the esophagogastric junction in order to divide any vagal branches to the fundus of the stomach (Grassi's criminal nerve<sup>4</sup>). A superficial incision was made around the lower end of the esophagus to divide the fine longitudinal nerve fibrils that run distally to the proximal cardia (Fig. 4). After completion of the proximal gastric vagotomy, the bare area on the lesser curvature of the stomach was closed by suturing the cut edges of the peritoneum together (Fig. 5). No pyloroplasty or other drainage procedure was added.

Selective gastric vagotomy technic was performed as described by Griffith.<sup>5</sup> The hepatic and celiac vagal branches remain intact but all vagal fibers to the stomach were divided. The dissection extended cephalad above the esophagogastric junction for five centimeters as performed in the technic for proximal gastric vagotomy. A Finney pyloroplasty was performed in all patients after selective gastric vagotomy in order to maintain a uniform drainage procedure for all patients.

The technic of truncal vagotomy and antrectomy has been previously described by us.<sup>14</sup> A two centimeter segment of both the anterior and posterior vagal trunk was excised. After removal of the antrum, gastrointestinal continuity was reestablished by the Schoemaker modification of the Billroth I gastroduodenostomy.

### Results

There was no operative mortality in the trial of patients undergoing PGV vs. SGV + P, but one patient

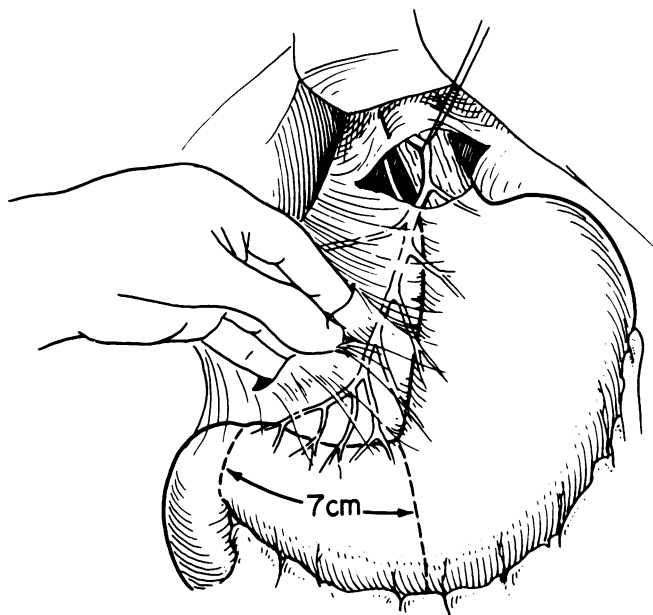


FIG. 1. Technic of proximal gastric vagotomy. The anterior vagal trunk is encircled with a soft rubber tube for identification. The lesser omentum is opened distal to the hepatic vagal branch and medial to the anterior nerve of Latarjet. The antral-parietal cell border is determined by the entrance of the branches of the anterior nerve of Latarjet onto the gastric antrum (crow's foot) which is usually seven centimeters proximal to the pylorus.

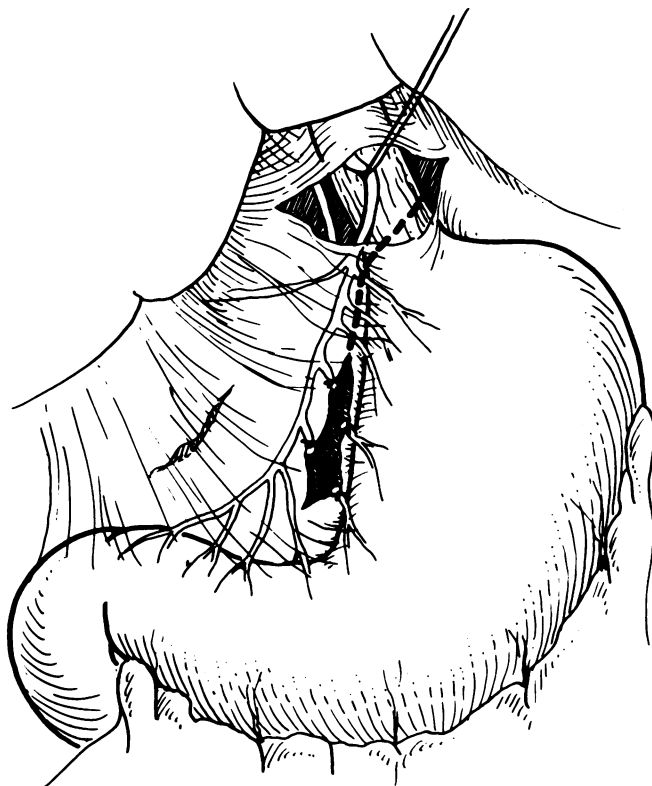


FIG. 2. Denervation of the stomach is begun by separating the anterior leaf of the lesser omentum. Dissection is started just above the "crow's foot" and continued cephalad to the esophagogastric junction and across the anterior wall of the esophagus.

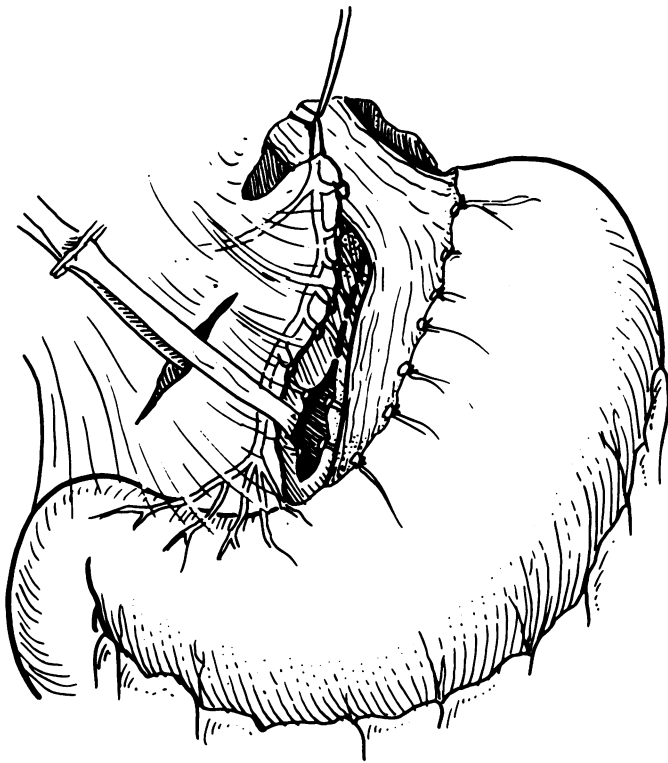


FIG. 3. The posterior leaf of the lesser curvature is detached from the stomach beginning just above the "crow's foot." Gentle traction on a tape passed around both the anterior and posterior nerves of Latarjet aids in this dissection.

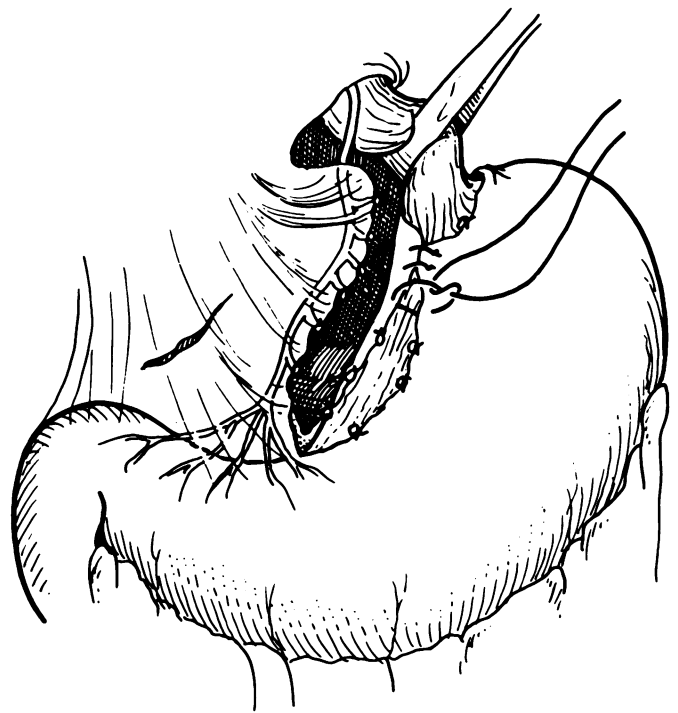


FIG. 5. The bare area on the lesser curvature is closed by suturing the cut edges of the peritoneum together. No drainage procedure is added.

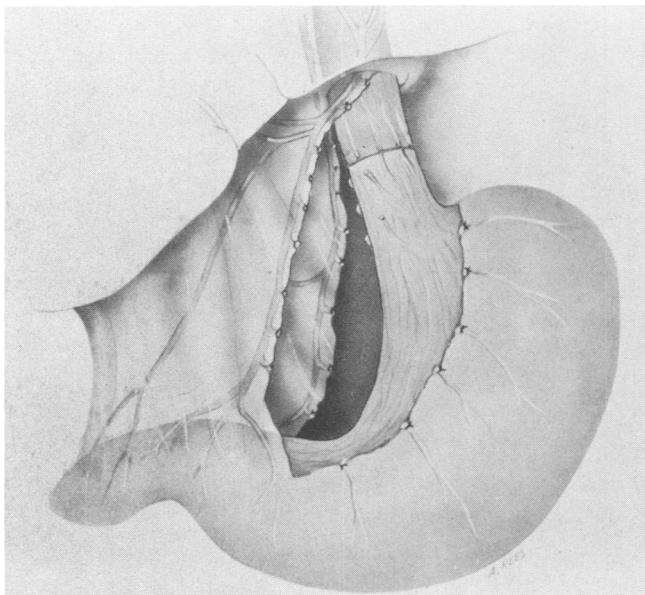


FIG. 4. Dissection is continued cephalad and completely around the esophagus for at least five centimeters above the esophago-gastric junction. A superficial, circumferential incision of the lower esophagus is done to divide the fine longitudinal nerve fibrils that run distally to the proximal cardia.

died of a pulmonary embolus on the fifth post-operative day after PGV in the group undergoing PGV vs. TV + A. No other patient in either group had a suspected or proven pulmonary embolus or any other significant pulmonary or cardiac complication during the hospital stay. Three minor wound infections occurred. One patient after TV + A developed persistent obstruction at the gastroduodenal anastomosis and later required a gastrojejunostomy for relief. Epigastric fullness and early satiety occurred in 15 patients (17%) who had PGV, but no patient required reoperation. This complication usually disappeared within two weeks after operation. Mortality and morbidity results are listed in Table 2.

All patients have been followed by clinical evaluation at regular intervals. Results have been tabulated by the Visick classification with Visick I being an excellent result indicating that the patient is in excellent nutritional condition and has no symptoms whatsoever referable to the gastrointestinal tract. Visick II is a good result indicating that the patient has excellent gastrointestinal function with no ulcer symptoms and is in a good state of nutrition but occasionally develops epigastric fullness, mild dumping symptoms or occasional bouts of diarrhea. Visick III is a fair result indicating that the patient has obtained benefit from

TABLE 2. *Mortality and Morbidity*

|                     | PGV vs. TV + A |   | PGV vs. SGV + P |   |
|---------------------|----------------|---|-----------------|---|
| Operative mortality | 1              | 0 | 0               | 0 |
| Wound infection     | 1              | 2 | 0               | 0 |
| Outlet obstruction  | 0              | 1 | 0               | 0 |

Significant hospital complications in the 174 patients entered into the trial.

the operation and is without residual ulcer symptoms but abdominal fullness, postprandial or moderate dumping symptoms are prominent sequelae. Visick IV is a poor result, and includes patients with recurrent ulcer, nutritional difficulties and postgastrectomy symptoms severe enough to interfere with regular employment.

Grading of the PGV vs. SGV + P patient's overall clinical evaluation was done by a surgeon who has a special interest in gastrointestinal diseases and who was unaware of the type of operation that the patient had received. However, a different physician evaluated the PGV vs. TV + A patients. For this reason the two groups of patients are considered separately. Results are shown in Table 3. There is a statistically significant difference between patients graded Visick I in the PGV vs. TV + A patients. No other significant difference exists in the overall clinical results according to our biostatistician. The total number of patients undergoing PGV (86) have been graded according to overall clinical result and listed in Table 4. Satisfactory results (Visick I and II) were obtained in 96% of these patients. This is not significantly different from the number of patients with satisfactory results after TV + A or SGV + P.

#### *Postgastrectomy Sequelae*

The postgastrectomy sequelae are shown in Table 5. A significant difference occurred in the incidence of dumping in both groups, being higher after both TV + A and SGV + P as compared to PGV. Diarrhea was significantly less after PGV than TV + A, but was not different from patients having SGV + P. Nine patients (18%) developed diarrhea after TV + A. Diarrhea was mild to moderate in all but one patient who has severe diarrhea despite frequent medication. This patient has lost 13.6 kg in weight.

The two patients with severe reflux gastritis after TV + A have undergone Roux-en-Y diversion. These two patients and the TV + A patient with severe postoperative diarrhea are considered poor results (Visick IV), but no recurrent ulcer has occurred in the TV + A patients.

TABLE 3. *Overall Clinical Evaluation*

|              | PGV vs. TV + A |           | PGV vs. SGV + P |          |
|--------------|----------------|-----------|-----------------|----------|
| Visick I     | 42 (86%)       | 28 (56%)* | 29 (78%)        | 27 (73%) |
| Visick II    | 5 (10%)        | 19 (38%)  | 6 (16%)         | 4 (11%)  |
| Visick III   | 0              | 0         | 1 (3%)          | 5 (13%)  |
| Visick IV    | 2 (4%)         | 3 (6%)    | 1 (3%)          | 1 (3%)   |
| Total # Pts. | 49             | 50        | 37              | 37       |

\* Significant difference,  $P < 0.01$ .

Table 6 lists postgastrectomy problems in all patients who had PGV. Dumping, diarrhea and reflux gastritis were significantly lower ( $p < 0.005$ ) after PGV than after the other two operations.

Anemia and weight loss have not been problems in these patients regardless of their operative procedure except for the one patient who has severe diarrhea after TV + A.

#### *Recurrent Ulcer*

Evaluation after operation to determine recurrent ulcer disease included a careful history and physical examination, hemogram, stool guaiac, and upper gastrointestinal radiological examination for all patients. About 75% of the PGV vs. SGV + P patients also had gastroscopy done one to two years after operation. Endoscopy was done after operation in the PGV vs. TV + A patients only if they were symptomatic.

Recurrent duodenal ulcer developed in two patients. Both patients were in the PGV vs. SGV + P trial. One patient in each group developed a recurrent ulcer which was visualized by endoscopy. Neither patient has undergone reoperation (Table 7).

The patient with a duodenal ulcer after SGV + P developed symptoms of recurrent ulcer disease one year after operation. He was taking aspirin for arthritis. Gastric analysis revealed a basal acid secretion of 2.7 mEq/hr. and a negative Hollander test. A duodenal ulcer was seen by the endoscopist. Serum gastrin was normal. After discontinuing his aspirin, the patient's symptoms improved. Repeat basal acid output studies were 1.8 and 0.5 mEq/hr. with MAO of 10.4 and 18.3 mEq/hr. The patient has been followed now for three years and complains only of occasional fullness. Repeat endoscopy has been done annually

TABLE 4. *Clinical Results in 86 Patients After PGV*

|            |          |         |
|------------|----------|---------|
| Visick I   | 71 (83%) | } (96%) |
| Visick II  | 11 (13%) |         |
| Visick III | 1 (1%)   |         |
| Visick IV  | 3 (3%)   |         |

TABLE 5. *Postgastroectomy Sequelae*

|                     | PGV<br>(49) | vs. | TV + A<br>(50) | PGV<br>(37) | vs. | SGV + P<br>(37) |
|---------------------|-------------|-----|----------------|-------------|-----|-----------------|
| Dumping             | 0           |     | 11 (22%)*      | 1 (3%)      |     | 8 (22%)*        |
| Diarrhea            | 1 (2%)      |     | 9 (18%)*       | 0           |     | 1 (3%)          |
| Reflux gastritis    | 0           |     | 2 (4%)         | 1 (3%)      |     | 2 (5%)          |
| Epigastric fullness | 4 (8%)      |     | 0              | 3 (8%)      |     | 3 (8%)          |

\* Significant difference,  $P < 0.05$ .

with no evidence of recurrent ulcer seen on the last two examinations.

The patient who developed a recurrent ulcer after PGV did well for about 18 months when symptoms developed. Gastroscopy revealed a pyloric channel ulcer. Gastric analysis results were BAO 0.6, MAO 11.7, PAO 13.4 mEq/hr. Serum gastrin was normal. Hollander test was positive with a late rise. The patient has been followed three and one half years since his proximal gastric vagotomy. He is improved on antacid therapy.

Two patients in the PGV vs. TV + A study developed a gastric ulcer after PGV and were graded as Visick IV (poor result). Antrectomy was done in one patient, but the other is being managed successfully by diet and antacids.

The 23-year-old patient who underwent antrectomy developed a three millimeter superficial gastric ulcer near the angle on the lesser curve eight months after PGV for a duodenal ulcer. There was no evidence of gastric stasis. The duodenal ulcer remained healed by gastroscopy. Because his symptoms persisted for a month, antrectomy with gastroduodenostomy was done. The excised specimen revealed scarring but no ulceration in the duodenum and a benign gastric ulcer (0.7 × 0.2 cm) on the lesser curvator of the antrum. He has remained well for the two years since his second operation.

The second patient, a 67-year-old male, had symptoms of duodenal ulcer disease for 18 years prior to PGV. He also had chronic renal disease, cirrhosis, recurrent pancreatitis and benign prostatic hypertrophy. His preoperative gastroscopy revealed a gastric ulcer on the lesser curve as well as a duodenal ulcer. Serum gastrin levels were normal. At operation there was thickening along the lesser curve area at the

TABLE 6. *Postgastroectomy Sequelae in 86 Patients After PGV*

|                     |        |
|---------------------|--------|
| Dumping             | 1 (1%) |
| Diarrhea            | 1 (1%) |
| Reflux gastritis    | 1 (1%) |
| Epigastric fullness | 7 (8%) |

Dumping, diarrhea and reflux gastritis are significantly lower after PGV as compared to TV + A and SGV + P.

TABLE 7. *Ulcer Recurrence*

|                | PGV vs. TV - A |   | PGV vs. SGV + P |   |
|----------------|----------------|---|-----------------|---|
| Duodenal ulcer | 0              | 0 | 1               | 1 |
| Gastric ulcer  | 2              | 0 | 0               | 0 |

angularis but no palpable ulcer crater. A posterior wall duodenal ulcer crater could be felt, and marked deformity of the duodenal bulb was noted. Since his PGV operation, gastroscopy on several occasions has shown that the duodenal ulcer has remained healed but the gastric ulcer has recurred, healed and recurred intermittently in the past 18 months. No gastric stasis is seen on radiological examination.

### Gastric Analysis

Gastric analysis studies could not be obtained routinely after operation in the PGV vs. TV + A patients, but were obtained before operation, and after operation at intervals of seven to 14 days, three to six months, and one to two years in most of the PGV vs. SGV + P patients. There was no significant difference in the per cent reduction of BAO, MAO or PAO following PGV vs. SGV + P. Thirty per cent of the PGV patients have developed a positive Hollander test one to two years after operation (Table 8).

### Discussion

Vagal denervation of the acid secreting fundic gland area of the stomach with preservation of an intact antral-pyloric mechanism was reported by Griffith and Harkins in 1957,<sup>6</sup> but the operation was done only in experimental animals. Holle and Hart<sup>9</sup> first performed proximal gastric vagotomy in man, but added a drainage procedure. Proximal gastric vagotomy without drainage was first reported independently by Amdrup and Jensen<sup>2</sup> and Johnston and Wilkinson<sup>10</sup> in 1970.

The advantages of proximal gastric vagotomy without drainage (PGV) over other operations for duodenal ulcer have been detailed by Jordan.<sup>12</sup> These included: 1) near normal gastric emptying, 2) preservation of inhibitory effects on acid secretion mediated via the extragastric and antral nerves, 3) an intact, functioning

TABLE 8. *Gastric Acid Secretion*

|                         | PGV | vs. | SGV + P |
|-------------------------|-----|-----|---------|
| % Reduction BAO         | 75% |     | 86%     |
| Positive Hollander Test |     |     |         |
| 7-14 Days P.O.          | 6%  |     | 0       |
| 1-2 Years P.O.          | 30% |     | 5%      |

BAO—Basal Acid Output.

pylorus which will reduce gastric reflux, and 4) preservation of duodenal innervation to permit normal release of duodenal hormones.

PGV has been enthusiastically adopted in many surgical centers in the past seven years. Johnston<sup>11</sup> has collected data on 5,539 patients undergoing PGV as an elective operation for duodenal ulcer. The mortality rate was 0.3%. Since the operation does not require opening the gastrointestinal tract, it is considered safer than any other operation currently used for duodenal ulcer. The most serious reported abdominal complication has been necrosis of the lesser curvature, and occurred in ten of the 5,539 patients. We have not encountered this problem in our patients.

Several surgical clinics have reported their clinical experience with PGV. Results of six retrospective studies have been tabulated by Amdrup.<sup>1</sup> The patient follow-up on 1,869 patients ranged from six months to seven years. The ulcer recurrence rate was between one to nine per cent. Dumping occurred in 0.4 to seven per cent, and diarrhea (mild) in zero to two per cent of patients.

Goligher<sup>3</sup> has recently reviewed his experience with 306 men undergoing PGV for duodenal ulcer. There was no operative mortality. With follow-up studies to seven years, the proven ulcer recurrence rate was two per cent. An additional three per cent of the patients have been suspected of having a recurrent ulcer. The Visick I and II grading (81%) is higher after PGV than after other operations used by Goligher for duodenal ulcer. The side effects of dumping, bile vomiting and diarrhea are less after PGV.

Several prospective studies randomizing PGV with other duodenal ulcer operations are currently being done. These studies have been summarized by Jordan<sup>12</sup> and Amdrup.<sup>1</sup> Most of these trials have involved approximately 100 patients. The mean follow-up is about two years. All studies are in agreement that PGV is accompanied by a very low mortality rate and few gastric side effects.

The unanswered question with PGV is the operation's long-term effectiveness in controlling the ulcer diathesis. High ulcer recurrence rates after PGV were reported initially by Kronborg<sup>13</sup> and Hallenbeck.<sup>8</sup> After altering their operative technic to extend the dissection cephalad five to seven centimeters above the esophago-gastric junction to clear the lower esophagus of nerves and other tissue, these surgeons reported a lower rate of recurrent ulceration.

Our prospective study comparing PGV with TV + A and SGV + P indicates that PGV is an effective operation for controlling intractable duodenal ulcer disease in man. The overall clinical evaluation showed a significantly higher percentage of patients with excellent results (Visick I) after PGV than after TV + A. Dumping is significantly less after PGV than after either TV + A or SGV + P. Diarrhea is significantly less after PGV than TV + A. The duodenal ulcer recurrence rate has not been excessive (one recurrence in 86 PGV patients or 1.2%) with follow-up studies from six months to four years. Two other patients developed gastric ulceration after PGV.

PGV desires continued evaluation by surgeons interested in duodenal ulcer disease. Long-term follow-up studies are needed to determine the ulcer recurrence rate.

### References

1. Amdrup, E., Andersen, D. and Jensen, H.: Parietal Cell (highly selective or proximal gastric) Vagotomy for Peptic Ulcer Disease. *World J. Surg.*, 1:19, 1977.
2. Goligher, J. C.: A Technique for Highly Selective (parietal cell or proximal gastric) Vagotomy for Duodenal Ulcer. *Br. J. Surg.*, 61:337, 1974.
3. Goligher, J. C.: Personal Communication, 1977.
4. Grassi, G. and Orecchia, C.: A Comparison of Intraoperative Tests of Completeness of Vagal Section. *Surgery*, 75:155, 1974.
5. Griffith, C. A.: Selective Gastric Vagotomy. *Surg. Clin. North Am.*, 46:367, 1966.
6. Griffith, C. A. and Harkins, H. N.: Partial Gastric Vagotomy: An Experimental Study. *Gastroenterology*, 32:96, 1957.
7. Hallenbeck, G. A.: Proximal Gastric Vagotomy Without Drainage for Duodenal Ulcer in Controversy in Surgery. Varco, R. L. and Delaney, J. P. (eds.), Philadelphia, W. B. Saunders Co., 1976, pp. 119-129.
8. Hallenbeck, G. A., Gleysteen, J. J., Aldrette, J. S. and Slaughter, R. L.: Proximal Gastric Vagotomy: Effects of Two Operative Techniques on Clinical and Gastric Secretory Results. *Ann. Surg.*, 184:435, 1976.
9. Holle, F. and Hart, W.: Neue Wege der Chirurgie des Gastroduodenalulcus. *Med. Klin.*, 62:441, 1967.
10. Johnston, D. and Wilkinson, A. R.: Highly Selective Vagotomy Without a Drainage Procedure in the Treatment of Duodenal Ulcer. *Br. J. Surg.*, 57:289, 1970.
11. Johnston, D.: Operative Mortality and Postoperative Morbidity of Highly Selective Vagotomy. *Br. Med. J.*, 4:545, 1975.
12. Jordan, P. H., Jr.: Current Status of Parietal Cell Vagotomy. *Ann. Surg.*, 184:659, 1976.
13. Kronborg, O. and Madsen, P.: A Controlled, Randomized Trial of Highly Selective Vagotomy Versus Selective Vagotomy and Pyloroplasty in the Treatment of Duodenal Ulcer. *Gut*, 16: 268, 1975.
14. Sawyers, J. L., Herrington, J. L., Jr. and Scott, H. W., Jr.: Vagotomy and Antrectomy for Duodenal Ulcer in Surgery of the Gastrointestinal Tract. New York, Intercontinental Medical Book Corporation, 1974, pp. 225-239.

### DISCUSSION

PROFESSOR S. HEDENSTEDT (Stockholm, Sweden): Very few, as you told us, randomized studies have been done comparing this

new operation with more established procedures. PGV, or, as we prefer to call it, selective proximal vagotomy, SPV, because SPV is the saving pylorus vagotomy. You can translate it.

Your randomized studies confirm our results in Sweden. We