

Effect of Antilymphocyte Serum and Other Immunosuppressive Agents on Canine Jejunal Allografts

MARK A. HARDY,* M.D., JEROME QUINT, M.D.,
DAVID STATE, M.D., PH.D., F.A.C.S.

*From the Department of Surgery, Albert Einstein College of Medicine,
Bronx, New York*

AS LONG AGO as 1902 Carrel⁴ transplanted portions of small intestine to the neck of dogs. Recently other investigators^{6, 17, 18, 24, 29} studied experimental heterotopic and orthotopic intestinal autografts and allografts. In a previous report¹¹ we described an accurate method for assessing and correlating intestinal allograft function with its morphologic survival. This method, based on active absorption of C¹⁴ D-glucose by the allograft, evaluated survival in terms of continuing function, as can be done with functional tests in renal allografts. This sensitive absorption test was used to evaluate the effect of several immunosuppressive regimens on cervical jejunal allografts in dogs. The effect of antilymphocyte serum alone, and in combination with prednisone and azathioprine, on jejunal allograft survival was studied. Furthermore, the morphologic and functional survival of immunosuppressed intestinal allografts was compared with that of untreated allografts and autografts.

Materials and Methods

Preparation of Horse Anti-dog Lymphocyte Serum (HADLS)

Anti-dog lymphocyte serum was prepared in two horses by the method of Monaco *et al.*²² The initial subcutaneous immunization was performed with 15×10^7 lymph-node lymphocytes obtained from exsanguinated dogs and emulsified with complete Freund's adjuvant. Booster injections of 12×10^7 lymph-node lymphocytes in saline suspension were given subcutaneously in multiple sites every 2 weeks for 6 months. Each horse was bled 5 to 6 liters once every month, one week following a booster injection. The sera were adsorbed three times with washed canine erythrocytes to remove hemagglutinins. Sera were decemplemented at 56° C. for 30 minutes, were passed through Seitz filters, and were pooled and stored at -20° C. in aliquots of 30 milliliters. Leukagglutinin titer of 1:1,200 and a hemagglutinin titer of 1:64 of the HADLS used in these experiments were determined by the methods of Amos and Peacocke¹ and Stimpffing,²⁸ respectively.

Animals. Thirty-five adult, male, unrelated mongrel dogs, weighing between 15 and 20 kilograms, received heterotopic

Submitted for publication April 28, 1969.

* Clinical Fellow of the American Cancer Society 1967-68.

This study was supported by United States Public Health Service Grant AM 08883-03 and United States Public Health Service Training Grant in Academic Surgery GM 01768-2.

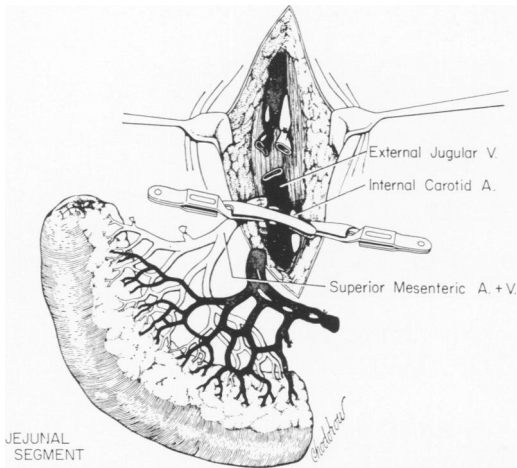


FIG. 1. Transplantation of a segment of jejunum to the neck by the end-to-end anastomoses of superior mesenteric artery to the internal carotid artery, and superior mesenteric vein to the external jugular vein.

cervical segmental jejunal autografts and allografts. Prior to operation the dogs were treated with anthelmintics. Those with signs of infections or worm infestation were not used. No attempt was made at preoperative sterilization of bowel. All animals were maintained on standard kennel rations.

Operative Procedure. Diabotal (0.5 ml./Kg.) anesthesia was used with an endotracheal tube in place. Segmental cervical jejunal autografts and allografts were performed according to the method of Lillehei *et al.*¹⁶ A six-inch segment of upper jejunum was isolated on its vascular pedicle; in the case of allografts (where the donor was sacrificed) this extended to the aorta at the origin of the superior mesenteric artery. The circulation to the graft was not clamped until the recipient's internal carotid artery and external jugular vein were dissected and prepared for the vascular anastomosis. When the recipient site was ready, the jejunal segment was resected and perfused with cold, heparinized, lactated Ringer's solution until the venous effluent was clear. Circulation to

the transplanted segment was promptly re-established by end-to-end anastomosis of the superior mesenteric artery and vein to the internal carotid artery and external jugular vein (Fig. 1). In the jejunal autografts the patch-graft technic described by Taylor *et al.*²⁹ was used for the arterial anastomosis. The segmental artery with a patch from the superior mesenteric artery was anastomosed end-to-side to the common carotid artery. This was technically easier for the very small segmental artery in the autograft than the end-to-end anastomosis. The total period of ischemia of the graft varied from 30 to 45 minutes. After circulation was re-established, a subcutaneous tunnel was made in the dog's neck and the two open ends of the intestine were brought out through the skin as separate mucous fistulae. In the autografted animals, in which a segment of upper jejunum was removed, the remaining small intestine was re-anastomosed. The autografted animals required massive fluid replacement for postoperative diarrhea, antibiotic agents (Cephalothin) and heparinization, while animals that received allografts required neither intensive postoperative care nor anticoagulation.

Assessment of Morphological Survival of Grafts. The appearance of the graft was evaluated daily and the amount and quality of secretions were recorded. Intraluminal punch biopsies were obtained daily (on alternate days in the autografted group). Tissue was fixed in 10% formalin, sectioned and stained with hematoxylin-eosin and Mowry's stains.

Assessment of Functional Survival of Grafts. Absorption studies on the transplanted segments were performed daily with uniformly labeled C¹⁴ D-glucose. After a control blood sample was obtained, 10 microcuries of C¹⁴ D-glucose in 2.5 cc. of saline were introduced into the mechanically closed graft lumen. Peripheral blood samples were then obtained at 5, 10, 15,

TABLE 1. Mean Total WBC and Lymphocyte Count Per Cubic Millimeter in Animals Receiving Jejunal Allografts

Group*	Treatment	Pretreatment		Post-treatment	
		WBC	Lymphocytes	WBC	Lymphocytes
2 (6)	None	12,300	2,660	13,600	2,280
3 (4)	NHS†	10,400	3,180	14,800	2,890
4 (5)	HADLS‡	11,200	3,260	14,300	286
5 (6)	HADLS, Prednisone, Azathioprine	12,200	3,650	4,260	69

* Numbers in parentheses denote number of dogs in each group.

† Normal horse serum.

‡ Horse anti-dog lymphocyte serum.

30, 60 and 90 minutes. Plasma fraction of each sample (0.5 cc.) was placed in Cabasil and was counted on a liquid scintillation counter (Packard).

Results

Antilymphocyte Serum. The white blood count and total lymphocyte response of control and treated groups are summarized in Table 1. All animals receiving either normal horse serum (NHS) or HADLS had elevated WBC's. A striking lymphopenia was present in animals receiving HADLS. This lymphopenia became apparent 24 hours after first subcutaneous injection of HADLS and persisted throughout the period of antilymphocyte serum administration. Many of the remaining lymphocytes appeared as lymphoblasts.

Chronic daily subcutaneous administration of NHS and HADLS was well tolerated. Two dogs developed subcutaneous abscesses which were drained and caused no further difficulties. Slight weight loss was noted in animals receiving the anti-serum. No animal had anaphylaxis or any other untoward reaction.

Morphological and Functional Graft Survival. Of the 35 animals receiving grafts, 26 were available for further studies. Nine animals succumbed to complications in the first 24-48 hours; six of these received autografts. The most common

problem was venous thrombosis at the anastomotic site or bleeding from the arterial anastomosis (seen only in the animals receiving heparin). The 26 animals reported were subdivided into five groups.

Group 1 consisted of 5 untreated animals with cervical autografts. These animals served as controls for the C¹⁴ D-glucose absorption studies. The jejunal autografts were studied for two months. During this period the graft stoma was pink and bled readily. The intestinal segment secreted clear, nonhemorrhagic fluid and exhibited excellent peristalsis. Histological sections revealed normal intestinal mucosa with a minimal decrease in the height of the villi. The mucin secreting cells remained intact.

The active absorption of C¹⁴ D-glucose in this group served as the standard for all further C¹⁴ D-glucose absorption studies in the jejunal allografts. Figure 2 shows a normal daily absorption curve with peak plasma levels of C¹⁴ D-glucose 5 to 10 minutes after the introduction of the labeled D-glucose into the autograft lumen. This type of curve of active absorption in jejunal autografts was reproducible over a period of one year. The mean peak plasma levels of C¹⁴ D-glucose in five autografts over 2 months are presented in Figure 5.

Groups 2 and 3 served as controls for the morphological and functional jejunal allograft survival without immunosuppression. Group 2 consisted of six untreated animals

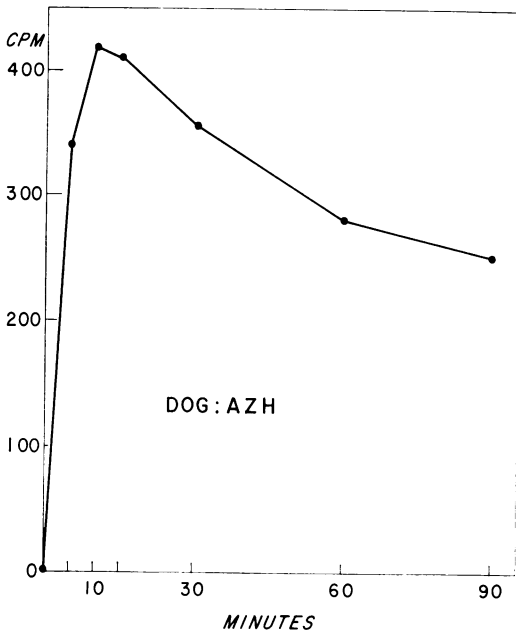


FIG. 2. Active absorption of C^{14} D-glucose in a jejunal autograft. Peak plasma level of C^{14} , as measured by counts per minute (CPM), appears 10 minutes after intraluminal installation of the labeled glucose.

with cervical jejunal allografts. The four animals in Group 3 received normal horse serum (2.0 cc./Kg.) daily for one week prior to grafting and daily thereafter until the allografts were rejected. Allograft rejection in these two control groups was associated with edema and cyanosis of the graft stoma. The secretions from the allograft were thick at first and then became blood-stained. Finally, between day 6 and 10, the graft became necrotic.

The earliest microscopic signs of rejection in Groups 2 and 3 appeared at a mean of 5.6 days. These consisted of progressively increasing interstitial lymphocytic and round cell infiltration. This progressed to complete histological allograft rejection at 6 to 8 days, characterized by the destruction of surface epithelium, absence of mucin-secreting cells, dilatation of central lacteals and marked perivascular round cell infiltration.

The study of the active transport of C^{14} D-glucose in these untreated and NHS-treated jejunal allografts forms the basis of our functional assessment of immuno-suppressed jejunal allografts. Daily absorption curves revealed a gradual fall in the peak plasma level of C^{14} as the allograft was rejected. Figure 3 demonstrates the day-to-day fall in the C^{14} peak plasma levels in four dogs in Group 3. The individual absorption curves become flat between the fifth and ninth day post-transplant. This loss of active absorption of glucose occurred concomitantly with histological rejection of the allograft. These observations on functional allograft survival were similar for the untreated (Group 2) and NHS-treated (Group 3) animals. The mean functional survival for both groups was 6.5 days.

Group 4 includes five animals that received 2.0 cc./Kg. of HADLS subcutaneously daily for 7 days prior to receiving a jejunal allograft, followed by daily post-operative HADLS injections until the allograft rejection was complete. This dose of HADLS resulted in a marked lymphopenia (0-3%) in all recipients at the time of transplantation; the lymphopenia was maintained after grafting by continued administration of HADLS. As judged by gross ap-

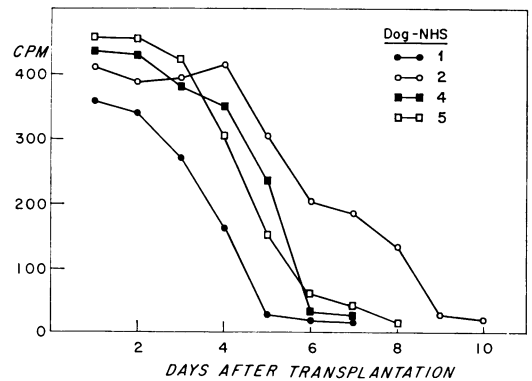


FIG. 3. Daily peak plasma levels of C^{14} D-glucose in four jejunal allografts treated with normal horse serum. There is a day-to-day fall in the peak plasma level of C^{14} as each allograft is rejected.

pearance, the survival of the jejunal allografts in this group was prolonged to 12–18 days. The graft stoma remained pink and the secretions were nonhemorrhagic for a mean of 14.8 days. Microscopic examination of the serial punch biopsies, however, revealed the jejunal allograft to be rejected at a mean of 7.8 days (range 5 to 9 days). The histological rejection was seen as a gradual increase in round cell and lymphocyte infiltration of the submucosa and submucosal hemorrhages. The mucus secreting cells disappeared and the villous architecture became flattened and finally disintegrated.

The functional studies in this group correlated well with the microscopic rejection of the allograft's mucosa. Figure 4 illustrates an individual animal's daily C^{14} D-glucose absorption curves. In this group the curves became flat between the fourth and eighth day. Active transport of D-glucose ceased one day before or on the day of complete histological rejection of the jejunal allograft.

Group 5 consisted of six dogs that received HADLS, prednisone and azathioprine (Imuran), both prior to and after jejunal allografts. HADLS was given as in Group 4, starting on day -7, while prednisone 1 (mg./Kg.) and azathioprine (5 mg./Kg.) were given daily p.o. starting on day -3 and were then continued daily. Leukocyte counts were determined every day and the dosage of azathioprine was modified if toxicity developed.

The combined immunosuppressive regimen in this group significantly prolonged the gross, microscopic and functional survival of jejunal allografts. The gross and histological rejection in this group was very gradual and usually was seen 4 to 6 days later than the cessation of function. The gradual shrinkage and fibrous replacement of the graft made judgment of gross rejection difficult and subjective. The mi-

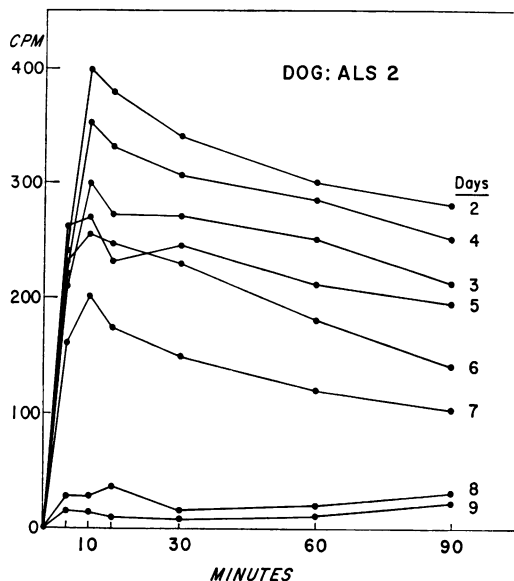


FIG. 4. Daily C^{14} D-glucose absorption curves in a jejunal allograft treated with anti-dog lymphocyte serum. There is a gradual decrease in active absorption of glucose until function ceases on day 8 when the curve becomes flat.

croscopic criteria were easier to determine but the lymphocyte infiltration was more gradual in this group and the destruction of the surface epithelium occurred over several days as opposed to the acute process observed in the untreated animals. The deterioration and flattening of the C^{14} D-glucose absorption curves was the first indication of jejunal allograft rejection. Figure 5 compares the C^{14} D-glucose absorption peaks of an allograft treated with the combined immunosuppression and the results in an allograft treated only with HADLS; the mean peak plasma levels of C^{14} in jejunal autografts are included as a control. The sensitivity of this test is well illustrated in the same figure where on day 23 and 24 the dog failed to receive his medications and the peak plasma levels of C^{14} dropped temporarily 2 days later. After immunosuppression was resumed the peak plasma levels of C^{14} rose again.

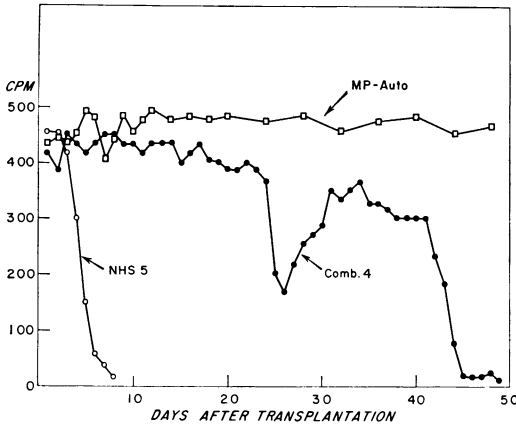


FIG. 5. Functional survival of a cervical jejunal allograft treated with antilymphocyte serum, azathioprine, and prednisone, is shown by the curve marked Comb. 4 (●—●) of daily peak plasma levels of C^{14} D-glucose. Of note is the reversal of decreased function in this allograft on day 30 (see text); function ceased on day 45. Curve NHS 5 (○—○) illustrates functional rejection (decreasing peak plasma levels of C^{14}) in an allograft treated with normal horse serum. Similar curves were obtained in untreated allografts and allografts treated only with antilymphocyte serum. No cessation of function was seen in jejunal autografts as shown by curve MP-Auto (□—□) of mean peak plasma levels of C^{14} D-glucose in five autografts.

The functional prolongation of allograft survival in this group ranged from 21 to 54 days, with mean survival of 38 days. The longest functioning graft (54 days) was rejected by histological criteria on day 57. Grossly, the same graft did not appear necrotic until day 61. Functional evaluation yielded the best end-point of allograft survival in this group and clearly predicted impending morphological rejection.

Discussion

The preceding experiments demonstrate the feasibility of intestinal transplantation, but at the same time show that the prevention of rejection of this organ by the conventional immunosuppressive regimens is more difficult than of the kidney or the heart.

Previous attempts to prevent rejection of heterotopic and orthotopic jejunal allo-

grafts using prednisone, azathioprine, or both, are difficult to evaluate. The methods of assessing graft survival were mainly morphologic and did not test the physiologic integrity of the implanted tissue. The C^{14} D-glucose absorption test that we have employed in both autografts and allografts correlated closely with the histological appearance of the intestinal mucosa and less well with the gross appearance of the intestinal segment. The jejunal autografts, even when transplanted to the neck, continued to actively absorb C^{14} D-glucose and the curves in these animals were reproducible for longer than one year. The intestinal allografts, however, ceased to absorb glucose concomitantly with early histological rejection and usually prior to the apparent gross rejection. Of even greater significance was the observation of gradual flattening of glucose absorption curves (Fig. 4) in allografts that did not yet show histological rejection by light microscopy. This decrease in function of the allograft appeared to be reversible in several animals receiving immunosuppression. Preston *et al.*²⁵ stressed the importance of mucous membrane in the function of jejunal allografts. It has been suggested that the mucosal surface of the intestine undergoes progressive desquamation and regeneration.⁸ It is also now recognized that the brush border of the apical mucosal cells of the villi operates in the active transport of glucose.⁷ It is probable that changes occur in the mucosa, and especially in the brush border, that are not detected at the light microscope level but that are reflected in the C^{14} D-glucose absorption studies. The gradually decreasing plasma levels of C^{14} D-glucose in our experiments probably represent a gradual reduction of the number of intact villi. This is difficult to evaluate histologically at light microscope level until most of the villi are involved. Minimal changes may be reversed by increased immunosuppression or may go on to com-

plete destruction of the brush border. Therefore, C¹⁴ D-glucose absorption appears to be a simple and reliable index of structural integrity of the allograft mucosa. When the peak plasma levels of C¹⁴ decrease from day to day, this test can serve as an early warning of impending rejection which may be susceptible to treatment. The cessation of absorption indicates a clear-cut endpoint.

Once a definite functional criterion of jejunal allograft rejection was established, it was possible to study the alterations in jejunal allografts by various immunosuppressive agents, with particular emphasis on antilymphocyte serum.

The immunosuppressive effect of heterologous antilymphocyte serum in dogs has been well demonstrated in experiments on renal and hepatic allografts. Although the mechanism of action of antilymphocyte serum is uncertain, its effectiveness has been in part ascribed to its leukagglutinating activity *in vitro* and the degree and persistence of lymphopenia that it produces *in vivo*.² The animals in Group 4 receiving HADLS alone showed lymphocyte counts of 0-3%. The leukagglutinating activity of HADLS used in these experiments was relatively high (1:1,200). Despite the use of what promised to be a potentially immunosuppressive pool of antilymphocyte serum we were not able to functionally or histologically prolong jejunal allograft survival in Group 4 (HADLS alone). There was no correlation between lymphopenia and prolongation of intestinal allograft survival. The apparent discrepancy, that we have observed in Group 4 between the mean time of gross survival (14.8 days) and functional survival (7.0 days) of the jejunal allografts can probably be explained by the great sensitivity of the absorption test or by a partial attenuation of rejection by HADLS which does not, however, prevent cessation of function by the allograft. This again emphasizes the

importance of the absorption studies as objective, rapid, and benign tests of function and impending rejection.

Potentialiation of antilymphocyte serum by corticosteroids, azathioprine, or both, has been studied in animals¹² and used clinically.²⁷ The use of azathioprine alone in intestinal allografts has been discussed by Taylor *et al.*²⁹ Preston and associates²⁵ reported on the use of the combination of prednisone and azathioprine on intestinal allograft survival. However, their methods of assessing allograft survival were not free from subjectivity.

We were curious if this difficulty in prolonging intestinal allograft survival could be overcome with the combination of all three immunosuppressive drugs, HADLS, prednisone, and azathioprine (Group 5). Employing strict functional criteria for evaluation of survival, the intestinal allograft survival was significantly prolonged. The longest graft lasted 54 days (function) and 59 days (gross appearance). The difficulty in prolonging functional survival of cervical intestinal allografts, despite immunosuppression effective for other organs, may perhaps be due to the lymphoid nature of a jejunal allograft. Quint *et al.*²⁶ suggested that perhaps the donor lymphocyte population may play a significant role in graft rejection. We have, therefore, pretreated donors with antilymphocyte serum, as well as recipients, and preliminary results suggest that this does not improve intestinal allograft survival. Immunosuppressed grafts in the abdomen have been reported by Preston *et al.*²⁵ to survive longer than those in the neck. These results were based, however, on mostly subjective criteria of survival. The longest surviving allograft (204 days) reported by these authors was atrophic and caused intestinal obstruction because of which it was finally removed.

Chance histocompatibility probably plays a role in determining prolonged survival

in some of these experiments, but immunosuppressive drugs, regardless of histocompatibility status, if given in proper doses and in proper combinations, can prevent intestinal allograft rejection. The observation of variable effects of these drugs may be due to a decreased functional reserve in intestinal allografts and to the variable histocompatibility differences in donor-recipient pair. The decrease in absorptive function probably reflects a relation between the amount of intestinal tissue destroyed and the degree to which the preserved tissue can compensate. In cervical segments of intestine which are short, this ratio may be swayed in favor of the destroyed tissue by the lack of regulating reserve in the length of segment utilized.

The role of intestinal allograft bacterial flora, both as an initial source of antigen and as a source of destructive pathogens during immunosuppression, has not been studied. In allografts of almost the entire small bowel Goott and colleagues⁸ described the death of the animal on the 6th to 9th day with what appears as a normal allograft. They ascribed this to a probable graft-versus-host reaction and runt phenomenon. The association between runt disease and infection is still uncertain²¹ but the studies in germ-free animals²⁰ suggest that the two are closely related. The role of the intestinal bacterial flora in transplantation of long segments of intestine needs further clarification.

It was believed earlier that the intestine requires central nervous system connections for proper functioning.¹⁵ However, we have noted, as have others, that despite the absence of an extrinsic nerve supply there is an immediate return of peristalsis in the jejunum on reimplantation. Extrinsic denervation may temporarily depress the activity of the intestine but it does not lead to impaired absorption of glucose. Grossman¹⁰ showed that the importance of neural control decreases while importance

of hormonal control increases as the intestinal tract is descended. Thus, the small intestine appears to have an intrinsic mechanism, partially based on its secretory activity, for intraluminal digestion. This was especially evident in our studies of cervical jejunal autografts where the active absorption of glucose and active peristalsis with secretions continued for longer than one year despite the initial extrinsic denervation of the bowel segment. Other investigators^{13, 16} have shown that animals receiving orthotopic autografts of the small intestine have marked diarrhea for the first few weeks. This may be explained not only by the sloughing of mucosa but also by a hyperactive, unbalanced intrinsic nervous control of the transplant. These animals then proceed to a long survival and apparently normal digestive function. Decreased blood flow has also been observed to increase intestinal motility,¹⁹ while large quantities of potassium are lost into the intestinal lumen.²³ It is possible that the acute intestinal allograft hypermotility could be avoided in the future by avoiding acute reduction in mesenteric blood flow during perfusion or preservation and by replacing intestinal cellular potassium.

The transplantation of the small intestine also requires a division of lymphatic channels. The role of the lymphatics in the intestinal absorption of fats is at present uncertain. In autotransplantation of the entire small intestine Goott *et al.*⁹ and Kocandrle *et al.*¹⁴ demonstrated roentgenographically regeneration of the intestinal lymphatic channels in 2 to 4 weeks. At the time of intestinal allograft rejection there is no lymphatic connection between the donor organ and the recipient and therefore, as in other vascularized organ allografts, the lymphatic connections do not appear to mediate the main immune response. This does not appear to be true for skin allografts.

This study demonstrates that the immunological response to intestinal allografts varies with the type and degree of immunosuppression. Antilymphocyte serum alone may attenuate the rejection process by prolonging gross survival of the transplants but not the functional survival. When prednisone and azathioprine are added to HADLS, both morphological and functional survival of jejunal allografts is prolonged. When the intestine is used as an allograft, it may become fibrotic, undergo cellular damage or become necrotic. Under these circumstances it may only lose function with minimal cellular damage. This suggests that some intestinal diseases, such as regional enteritis and ulcerative colitis, behave in a manner similar to immunosuppressed intestinal allografts. It is possible that effective immunosuppressive regimens may alone be helpful in the treatment of some intestinal diseases. However, some conditions require at least a partial replacement of the small intestine to prolong life. Further research on intestinal transplantation should provide a firm basis for future clinical application. We have shown that the transplant, despite denervation and heterotopic relocation performs surprisingly well. It remains to be demonstrated that it absorbs other substances than glucose and arabinose. Progress in histocompatibility matching and improvements in immunosuppressive agents may decrease the threat of rejection and add intestinal transplantation to the surgeon's armamentarium of treatments of intestinal diseases.

Summary

The survival of cervical jejunal autografts and allografts was studied in 26 dogs. Rejection in untreated and immunosuppressed transplants was judged grossly, microscopically, and functionally. Absorption of C¹⁴ D-glucose by the intestinal segment was employed as a sensitive and

benign test of allograft function and impending rejection. A nontoxic equine anti-dog lymphocyte serum, that was an effective lymphopenic agent, was used alone and in combination with prednisone and azathioprine to induce immunosuppression.

Cervical jejunal allografts in dogs which received HADLS alone pre- and post-transplantation showed a prolonged morphological survival but ceased to function at approximately the same time as untreated jejunal allografts. To explain this finding, speculations are offered on the role in the immune reaction of the lymphoid tissue in the donor organ. Successful prolongation of both morphologic and functional jejunal allograft survival was achieved by the administration of a combination of antilymphocyte serum, prednisone and azathioprine. This study and those of other investigators, briefly reviewed here, suggest the practicality of intestinal transplantation in the near future and point to the need of further research in this field.

References

1. Amos, D. B. and Peacocke, N.: In Proc. 9th. Congr. Europ. Soc. Hematol., Lisbon, p. 1132. S. Karger, Basel, New York, 1963.
2. Atai, M. and Kelly, W. D.: Prolongation of Survival of Canine Kidney Allografts with Antilymphocyte Serum. *Surg., Gynec. Obstet.*, 125:13, 1967.
3. Bertalauff, F. D.: Cell Renewal in the Gastrointestinal Tract of Man. *Gastroenterology*, 43:472, 1962.
4. Carrel, A.: La technique operateire des anastomoses vasculaires et la transplantation des visceres. *Lyon Med.*, 98:859, 1902.
5. Cohen, W. B., Hardy, M. A., Quint, J. and State, D.: Absorptive Function in Canine Jejunal Autografts and Allografts. *Surgery*, 65:440, 1969.
6. Couinaud, C.: La greffe du jejuno-ileon chez l'homme. *J. Chir., Paris*, 90:541, 1965.
7. Crane, R. K.: Enzymes and Malabsorption; A Concept of Brush Border Membrane Disease. *Gastroenterology*, 50:254, 1966.
8. Goott, B., Lillehei, R. C. and Miller, F. A.: Homografts of the Small Bowel. *Surg. Forum*, 10:193, 1959.
9. Goott, B., Lillehei, R. C. and Miller, F. A.: Mesenteric Lymphatic Regeneration after Autografts of Small Bowel in Dogs. *Surgery*, 48:571, 1960.

10. Grossman, M. I.: Gastrointestinal Hormones. *Physiol. Rev.*, 30:33, 1950.
11. Hardy, M. A., Quint, J., Cohen, W. B. and State, D.: C¹⁴ D-Glucose Absorption in Heterotopic Jejunal Allografts. *Gastroenterology*, 54:1295, 1968.
12. Hoehn, R. J., Weil, R. and Simmons, R. L.: Synergistic and Antagonistic Actions of Immunosuppressive Agents with Antilymphocyte Serum. *Surg. Forum*, 18:231, 1967.
13. Iijima, K. and Salerno, R. A.: Survival of Small Intestine Following Excision, Perfusion and Autotransplantation. *Ann. Surg.*, 166:968, 1967.
14. Kocandrlje, V., Houttuin, E. and Prohaska, J. V.: Regeneration of the Lymphatics after Autotransplantation and Homotransplantation of the Entire Small Intestine. *Surg. Gynec. Obstet.*, 122:587, 1966.
15. Lillehei, R. C., Goldberg, S., Goott, B. and Longerbeam, J. K.: Present Status of Intestinal Transplantation. *Amer. J. Surg.*, 105:58, 1963.
16. Lillehei, R. C., Goott, B. and Miller, F. A.: The Physiological Response of the Small Bowel of the Dog to Ischemia Including Prolonged *in vitro* Preservation of the Bowel with Successful Replacement and Survival. *Ann. Surg.*, 150:543, 1959.
17. Lillehei, R. C., Idezuki, Y., Feemster, J. A., Dietzman, R. H., Kelly, W. D., Merkel, F. K., Goetz, F. C., Lyons, G. W. and Manax, W. G.: Transplantation of Stomach, Intestine, and Pancreas; Experimental and Clinical Observations. *Surgery*, 62:721, 1967.
18. Lillehei, R. C., Longerbeam, J. K., Bloch, J. H. and Akbar, M.: The Transplantation of Organs by Direct Vascular Suture with Special Reference to the Gastrointestinal Tract and Spleen. *Military Med.*, 128:173, 1963.
19. Marston, A.: Causes of Death in Mesenteric Arterial Occlusion. *Ann. Surg.*, 158:952, 1963.
20. McIntire, K. R., Sell, S. and Miller, J. F. A. P.: Pathogenesis of the Post-Neonatal Thymectomy Wasting Syndrome. *Nature*, 204:151, 1964.
21. Miller, J. F. A. P. and Howard, J. G.: Some Similarities Between the Neonatal Thymectomy Syndrome and Graft-versus-host Disease. *J. Reticuloend. Soc.*, 1:369, 1964.
22. Monaco, A. P., Abbott, W. M., Othersen, H. B., Simmons, R. L., Wood, M. L., Flax, M. H. and Russell, P. S.: Antiserum to Lymphocytes: Prolonged Survival of Canine Renal Allografts. *Science*, 153:1264, 1966.
23. Nelson, R. A. and Beargie, R. J.: Effect of Reduced Arterial Pressure and Flow on Intestinal Function. *Surg. Gynec. Obstet.*, 120:1221, 1965.
24. Preston, F. W., Macalalad, F., Graber, R., Jackson, E. J. and Sporn, J.: Function and Survival of Jejunal Homotransplants in Dogs with and without Immunosuppressive Treatments. *Transplantation*, 3:224, 1965.
25. Preston, W. F., Macalalad, F., Wachowski, T. J., Randolph, D. A. and Apostol, J. V.: Survival of Homografts of Intestine with and without Immunosuppression. *Surgery*, 60:1203, 1966.
26. Quint, J., Hardy, M. A. and State, D.: Effects of Antilymphocyte Serum on Absorptive Function and Survival of Dog Intestinal Allografts. *Surg. Forum*, 19:184, 1968.
27. Starzl, T. E., Marchioro, T. L., Porter, K. A., Iwasaki, Y. and Cerilli, C. J.: The Use of Heterologous Antilymphoid Agents in Canine Renal and Liver Homotransplantation and in Human Renal Homotransplantation. *Surg. Gynec. Obstet.*, 124:301, 1967.
28. Stimpfling, J. H.: The Use of PVP as a Developing Agent in Mouse Hemagglutination Tests. *Transplantation*, 27:109, 1961.
29. Taylor, R. M. R., Watson, J. W., Walker, F. C. and Watson, A. J.: Prolongation of Survival of Jejunal Homografts in Dogs Treated with Azathioprine (Imuran). *Brit. J. Surg.*, 53:134, 1966.