

# Emergency Diagnosis of Upper Gastrointestinal Bleeding by Fiberoptic Endoscopy

HUGO V. VILLAR, M.D., H. ROBERTS FENDER, M.D., LARRY C. WATSON, M.D., JAMES C. THOMPSON, M.D.

Emergency esophagogastroduodenoscopy has been performed in 192 consecutive patients admitted with massive gastrointestinal bleeding. Accurate endoscopic diagnosis was made in 184 or 96%; 58 patients underwent emergency operations to control bleeding with an overall operative mortality of 26%. Excluding 16 patients who underwent emergency portacaval shunting, the operative mortality was 7%. In 6 patients, the bleeding was controlled by endoscopic electrocoagulation. There were no complications. Emergency endoscopy should be done routinely as the primary diagnostic approach in the diagnosis of upper gastrointestinal bleeding.

**F**EWER PATIENTS with massive upper gastrointestinal bleeding will die if an accurate diagnosis can be promptly made.<sup>2</sup> The availability of fiberoptic instruments that allow complete visualization of the esophagus, stomach, and duodenum has increased greatly the chances of an accurate diagnosis.<sup>1,4,8-10,12,13,17</sup> Performance of the endoscopy by the surgical team assures greater independence for the surgeon and provides strong motivation for punctual study. It may even be possible to achieve control of bleeding on unusual occasions by electrocoagulation through the fiberoptic instrument.<sup>3,14,16</sup>

The purpose of this study is to report our experience with emergency fiberoptic endoscopy in the diagnosis and treatment of massive upper gastrointestinal bleeding.

## Materials and Methods

Since March 1973, we have routinely performed emergency esophagogastroduodenoscopy in all patients admitted with massive upper gastrointestinal bleeding. (We define massive gastrointestinal bleeding as bleeding that has caused the hematocrit to drop below 25 or that has been of such magnitude as to require three or more units of whole blood to restore

*From The Department of Surgery, The University of Texas Medical Branch, Galveston, Texas*

normal vital signs. The patient has often had brief episodes of syncope.<sup>7,15</sup>) All patients were gastroscopied within one hour of admission or of detection of the bleeding. A GIF-D2 Olympus forward-view gastroscope was used in all examinations. For the purpose of endoscopic electrocoagulation, an electrode was constructed of 0.6 mm steel piano wire inside a 2 mm OD polyvinyl tube which was then introduced through the suction channel of the endoscope. A 1.8 mm silver ball was welded at the end of the wire to provide an atraumatic tip. A Cameron-Miller electrocoagulation apparatus (Model 80-7910) was used as the power source.

## Technique of Endoscopy

Most emergency endoscopic examinations were performed either in the Emergency Room or in the Intensive Care Unit. Prior to endoscopy, the stomach was emptied, usually by induction of vomiting, or by gastric lavage with a Levin or Ewald tube. No topical anesthesia was used and premedication with intravenous Valium<sup>®</sup> was used only when necessary (10% of cases). Agitated patients with alcoholic intoxication presented major difficulties and even large doses of Valium were frequently ineffective. A large rubber bite block provides protection against injury.

We have modified the suction channel valve of the gastroscope by replacing it with a large-bore irrigation fitting in order to have a large jet of water available to clean the lens and to remove blood clots from the mucosal surface. Endoscopy is greatly facilitated if irrigation and suction are carried out by an assistant.

## Results

We have studied 192 consecutive patients admitted with massive upper gastrointestinal hemorrhage. The more common diagnoses are listed in Table 1.

Submitted for publication June 15, 1976.

All correspondence: James C. Thompson, M.D., Department of Surgery, The University of Texas Medical Branch, Galveston, Texas 77550.

Supported by National Institutes of Health Grant #AM 15241.

TABLE 1. Final Diagnosis in 195 Consecutive Patients with Gastrointestinal Bleeding

Diagnosis	Number of Patients	%
Duodenal ulcer	50	26.0
Hemorrhagic gastritis	35	18.2
Bleeding esophageal varices	29	15.08
Mallory-Weiss tears	15	7.8
Gastric ulcer	20	10.4
Esophagitis	7	3.64
Carcinoma	7	3.64
Miscellaneous	15	7.8
Normal: (see Table 3)		
Lesions distal to ligament of Treitz	11	5.72
No diagnosis	3	1.56
Total	192	

### Duodenal Ulcer

Of the 50 bleeding patients in whom the final diagnosis was duodenal ulcer, a correct endoscopic diagnosis was made in 49. Radiologic examination of the upper gastrointestinal tract was performed in 37 patients and was reported as normal in 9 (that is, the false-negative rate was 24%). In the only patient in whom we failed to make the diagnosis by endoscopy, bleeding halted spontaneously before endoscopy; the ulcer crater was shown by upper gastrointestinal radiologic examination performed the next day. Gastroscopy was then repeated and it was possible to visualize the crater without difficulty. Figure 1 shows the antrum and pylorus with blood pouring back into the stomach from a bleeding duodenal ulcer. It is unusual to visualize the actual point of bleeding in the ulcer crater. Accurate early diagnosis of duodenal ulcer allowed prompt intervention in 28 patients who required operation (that is, more than half of the patients with bleeding duodenal ulcer required emergency operation). Of the 22 patients treated medically, four later died. In all patients who died, the gastrointestinal hemorrhage was an associated complication of their primary disease (two patients had sepsis and two had carcinoma). In all of these patients, gastrointestinal bleeding was a significant concomitant final complication before their deaths. Of the 28 patients who were operated upon, one died (the consequence of a leaking duodenal stump after truncal vagotomy and antrectomy). This patient was receiving steroid treatment for sarcoidosis.

### Hemorrhagic Gastritis

Hemorrhagic gastritis was the final diagnosis in 35 bleeding patients. Of this group, 6 had associated lesions (4 had esophageal varices, one had a gastric ulcer, and the sixth had a large hiatal hernia). Non-

operative management (gastric irrigation with iced saline plus antacids) controlled the bleeding in 33 patients; only two patients required operation. No endoscopic diagnosis was made in one of these patients because the massive bleeding made adequate visualization of the stomach impossible. It was possible, however, to exclude the duodenum and esophagus as possible sources of bleeding. A mesenteric angiogram was suggestive of a retrogastric mass. Laparotomy and gastrotomy revealed diffuse gastritis. The second patient had cirrhosis and underwent subtotal gastrectomy. This patient continued to bleed and he died later from heart failure in the early post-operative period.

### Case Report

One important contribution of emergency endoscopy in our hands has been the preoperative identification of lesions which will not respond well to operation. This contribution is well illustrated by the case of a 62-year-old man admitted to our emergency room with a 6-hour history of cramping abdominal pain and nausea. He had a large hematemesis in the emergency room. Two months prior to admission, he had undergone, at a hospital in California, a subtotal colectomy and transverse colostomy for carcinoma of the rectosigmoid area. Emergency endoscopy revealed extensive esophagitis, gastritis and duodenitis with coagulation necrosis of the mucosa of the distal esophagus, entire stomach, and proximal duodenum. Plain x-ray films of the abdomen showed a classical pattern of mechanical small bowel obstruction. At operation we found a high small-bowel obstruction with gangrene of two-thirds of the small bowel caused by a volvulus around the colostomy. We decided not to open his stomach in fear that a gastrotomy might not heal. He never bled in the postoperative period and an unnecessary, and possibly fatal, operation on the stomach was avoided because of the preoperative endoscopic demonstration of necrotic mucosa. The patient later told us that he was taking 500 mg of 5-fluorouracil by mouth daily. It appears likely that the mucosal necrosis was caused by the 5 FU in the presence of bowel obstruction. Repeat endoscopy one week after operation showed normal mucosa.

Hemorrhagic gastritis as a cause of massive gastrointestinal bleeding has not occurred as a primary entity, but rather as an associated finding complicating other major diseases. Many patients have localized areas of gastritis resulting from contact with nasogastric tubes. Tube ulcers are usually multiple and linear and are more prominent in the fundus and cardia. The endoscopist should be aware that these are usually incidental findings and are rarely (if ever) the source of significant bleeding. The lesions of gastritis often do not involve the whole stomach and normal areas may be interposed with severe areas of inflammation. Figure 2 shows multiple mucosal bleeding areas in the region of the incisura of the stomach. The decision that areas of hemorrhagic gastritis or duodenitis represent the source of bleeding should be a decision of

exclusion. All other possible bleeding lesions should be carefully ruled out. If other lesions, such as varices or ulcers, are present, they must be excluded as the cause of bleeding.

Diffuse duodenitis can be a significant source of blood loss in some patients. Five of the 35 cases of hemorrhagic gastritis had associated intensive duodenitis. In two other patients, admitted with hematemesis and melena after heavy ingestion of alcohol, duodenitis was the only lesion demonstrable. Upper gastrointestinal radiographic study and later endoscopic examinations were normal and the patients stopped bleeding spontaneously.

#### *Bleeding Esophageal Varices*

Of the 29 patients in whom the final diagnosis was esophageal varices, varices were demonstrated on endoscopy in all but two. Radiographic study of the upper gastrointestinal tract was performed in 15 patients (varices were demonstrated in 10 patients, and not seen in 5).

Early recognition of esophageal varices as the source of bleeding is crucial because of the specific measures needed to control variceal bleeding. Endoscopic visualization of esophageal varices is usually easy. Varices elevate the normally flat mucosa of the esophagus and they resemble hemorrhoids. They usually extend along the lower third of the esophagus. When the scope is first introduced into the distal esophagus in a patient with bleeding varices, a large pool of bright red blood is usually seen. We have been able to see the actual bleeding point in only 5 of our 29 patients with bleeding varices. Figure 3 shows a jet of bright red blood coming from a single defect in the wall of the vessel bleeding with great pressure. In patients with esophageal varices that were not bleeding at the time of examination, the introduction of the scope through the cardia has not caused bleeding or tears. This experience should partially allay the natural anxiety associated with the decision to perform endoscopy in acutely ill patients. Hypovolemia, overinsufflation of the esophagus with air and Valsalva maneuvers may cause great variation in the size and prominence of esophageal varices.

The duodenal mucosa often has a characteristic appearance in patients with portal hypertension. Distended submucosal veins make the duodenal mucosa look thick and granular, the distance between the plica circularis is diminished and the edges are less sharp. It should be emphasized that whenever esophageal varices are present, the duodenum and gastric mucosa should be carefully examined to rule out the presence of associated bleeding lesions.<sup>18</sup>

Eight patients who stopped bleeding from their varices spontaneously were treated nonoperatively; two later died in the hospital. Five other patients were controlled with tamponade with the Blakemore-Senk tube. Of the 29 patients, 16 underwent emergency portacaval shunting with a rate of operative mortality of 75%. All portacaval shunts were performed in desperately sick patients (almost all were class C in Child's classification).<sup>5</sup>

#### *Esophagitis*

The diagnosis of hiatal hernia and esophagitis can be made easily on endoscopy. If esophagitis is severe, major bleeding from cardio-esophageal mucosa may be present. Of our 7 patients with bleeding esophagitis, 3 were in a debilitated state related to a complicated and prolonged postoperative course; in all 3, the *clinical* diagnosis was stress ulcer and hemorrhagic gastritis. A hiatal hernia with reflux was present in all 7, and all responded to antacids and postural maneuvers. None of these patients had a previous history suggestive of hiatal hernia.

#### *Mallory-Weiss Syndrome*

We found 15 cases of mucosal tears at the cardio-esophageal junction in the series of 192 bleeders. This high proportion (7.8%) of patients with the Mallory-Weiss syndrome is clearly a consequence of our program of routine endoscopy in patients with major upper gastrointestinal bleeding. In none of the 15 patients was the diagnosis strongly suspected prior to endoscopy. The interruption of mucosal integrity at the cardio-esophageal junction can be appreciated in Fig. 4. The gastroscope has been retroflexed and we are looking backwards into the cardia. In our experience, the Mallory-Weiss laceration is a single vertical tear extending about 3.4 cm into the gastric mucosa. Of the 15 patients, 11 had a previous history of heavy alcohol ingestion; hiatal hernia was present in 9. Upper gastrointestinal x-ray series performed in 12 patients within 48 hours of onset of bleeding revealed a hiatal hernia in 8 patients, and esophageal varices in one; the study was reported as normal in 3 patients.

We have controlled the bleeding from these mucosal tears on three occasions with the Sengstaken-Blakemore tube (inflating only the gastric balloon), and in the last 4 patients, we have achieved control by endoscopic electrocoagulation. The most recent patient is a 46-year-old man who bled 5 units of blood on the fifth postoperative day after a right hepatic lobectomy performed for primary hematoma. On endoscopic examination, we found a laceration of the cardio-esophageal junction, probably caused by the naso-

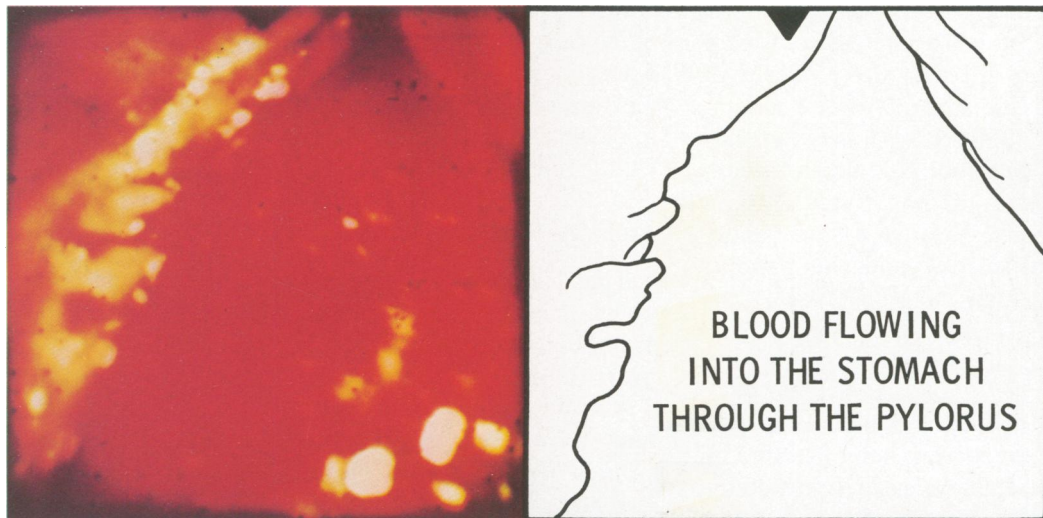


FIG. 1. View of antrum and pylorus. Blood is seen flowing into the stomach from a bleeding duodenal ulcer.

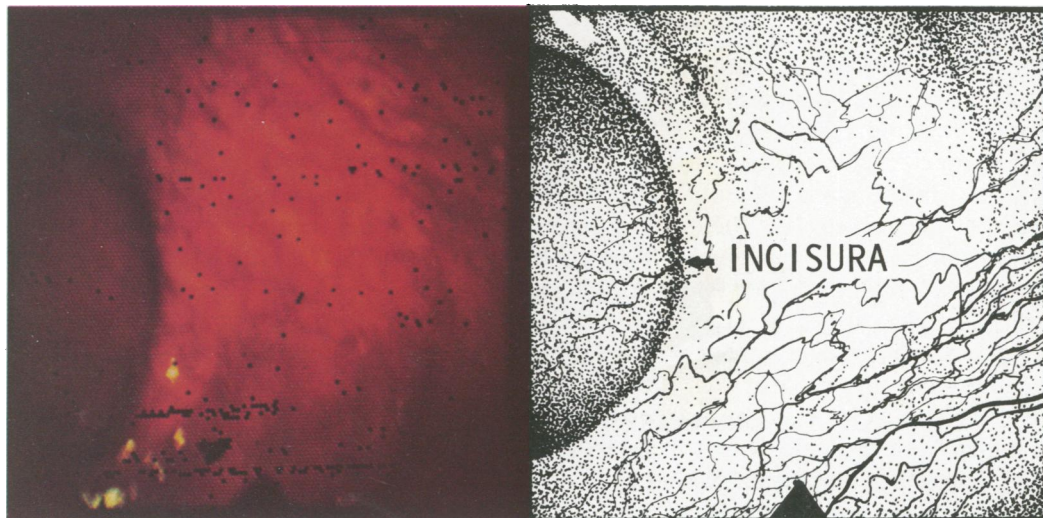


FIG. 2. Hemorrhagic gastritis. Multiple bleeding areas in the gastric mucosa in the area of the *incisura angularis*.

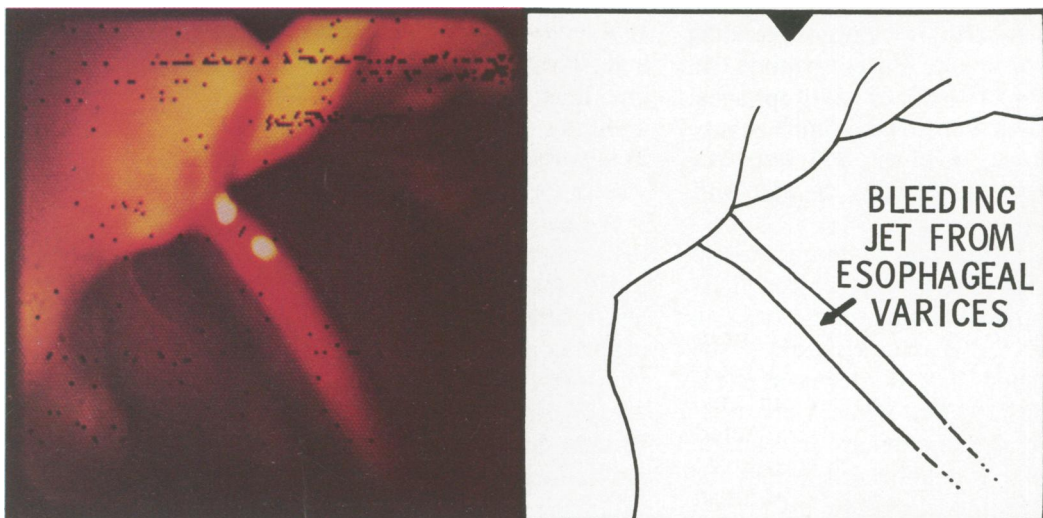


FIG. 3. Area of cardio-esophageal junction. Bleeding jet from an esophageal varix.



FIG. 4. Cardioesophageal junction as seen from the stomach. A long Mallory-Weiss tear is seen extending deep into the stomach.

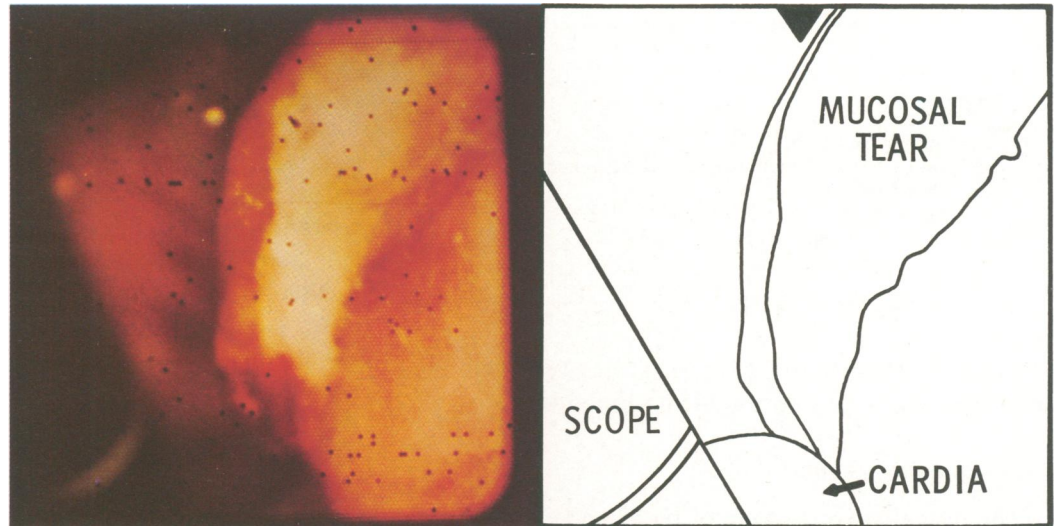
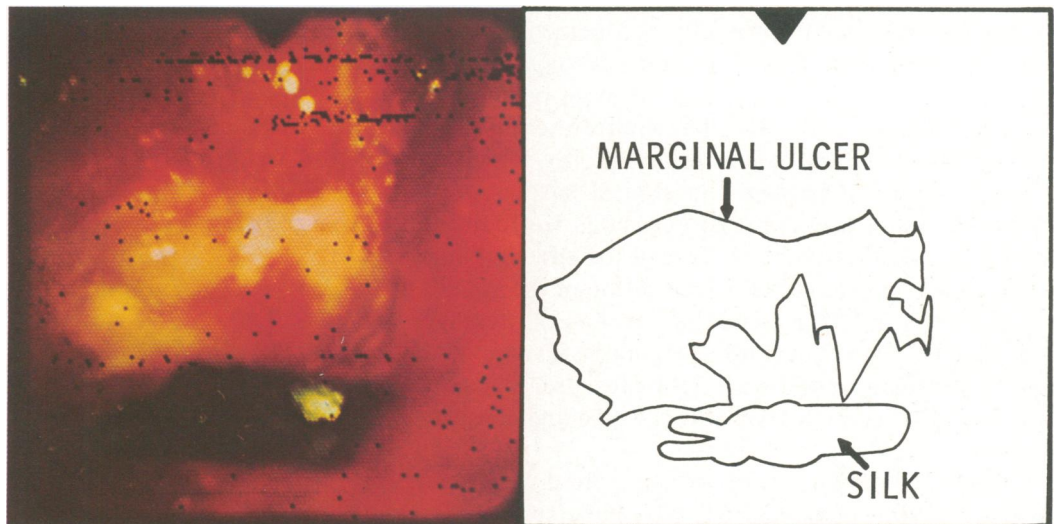
FIG. 5. Marginal ulcer of the jejunum. A piece of black silk suture is visible.



gastric tube. We secured excellent control of bleeding by electrocoagulation; there was no recurrence. In order to coagulate these tears at the cardioesophageal junction, a side-viewing endoscope is useful because it allows better exposure of the area distal to the cardia, and the electrode can be manipulated independently from the scope.

#### *Gastric Ulcer*

Gastric ulcers are usually located on the lesser curvature and are not difficult diagnostic problems, although the finding of a gastric ulcer as a cause of massive gastrointestinal bleeding has always been unexpected. Of our 20 patients with gastric ulcers, the crater was shown by x-ray examination in 17. In two patients, no upper gastrointestinal x-ray series was performed,

and in one, radiological studies were reported as normal. Twelve patients were treated successfully without operation. Eight patients underwent emergency operations for uncontrollable bleeding; of these, one died from late complications and the rest did well.

#### *Carcinoma*

Carcinoma is an unusual cause of massive upper gastrointestinal bleeding. In this series of patients, however, a carcinoma of the pancreas invading the duodenum manifested itself with massive hematemesis in two patients. In both, the admitting diagnosis was peptic ulcer disease. Diagnosis was made by endoscopy plus biopsy in both patients. There were five cases of carcinoma of the stomach which were usually associated with a continuous, slow oozing of blood. The

TABLE 2. Final Diagnosis in 15 Patients with Miscellaneous Lesions Causing Upper Gastrointestinal Bleeding

Bleeding cystogastrostomy suture line	2
Bleeding gastrostomy edges	2
Marginal ulcers	6
Bleeding gastric suture line	2
Esophageal perforation secondary to pressure necrosis from a tracheostomy cannula	1
Tear of the esophagus after dilatation	1
Bleeding choledochojejunostomy	1
Total	15

surfaces of these tumors were extremely friable and minimal trauma caused significant blood loss.

### Miscellaneous Lesions

The miscellaneous group of bleeding lesions (Table 2) is important because without endoscopy, many would not have been promptly recognized. Two patients bled from the suture line after a cystogastrostomy performed for internal drainage of large pseudocysts of the pancreas. They did not require re-exploration. Even though the entity is well-known, it was possible by endoscopy to confirm the clinical suspicion of a bleeding suture line. On two occasions we found the edges of a gastrostomy (performed for a feeding tube) to be bleeding profusely. Identification of the bleeding point by endoscopy allowed the use of a Foley catheter through the gastrostomy tube for successful tamponade of the bleeding vessel with light pressure. Today we would first attempt to coagulate the bleeding point with the electrocautery.

Six patients in our series were admitted with severe gastrointestinal bleeding from marginal ulcer. Marginal ulcers are located usually on the jejunal side of the anastomosis and are usually missed by the upper gastrointestinal x-ray examination. By endoscopy, ulcer craters almost always have a dirty white-yellow base, in sharp contrast to the inflamed surrounding mucosa. On occasions suture material is present, as in Fig. 5, which shows a large marginal ulcer after a gastrojejunostomy.

On two occasions gastric suture lines were the source of bleeding. One patient had multiple injuries caused by a gunshot wound. A pyloroplasty had been performed in repairing the pyloroduodenal injury. Bleeding from the pyloroplasty was controlled by endoscopic electrocoagulation of the hemorrhagic area, carried out on the fourth postoperative day. There was no disruption of the suture line by air used to insufflate the stomach. This was our earliest postoperative endoscopic examination in patients in whom a fresh suture line was present and the risk of disruption was present. Another patient bled on the ninth postopera-

tive day from a gastrojejunostomy performed for gastric outlet obstruction secondary to benign peptic ulcer disease. This bleeding was also controlled by endoscopic electrocoagulation.

One patient bled massively from an esophageal perforation caused by pressure from a tracheotomy cannula. This 30-year-old man developed pulmonary complications after removal of an acoustic neuroma. He later died from uncontrolled bleeding into the tracheobronchial tree. In another patient, dilatation of an esophageal stricture (which resulted in multiple longitudinal tears in the esophagus) caused severe bleeding. This patient stopped bleeding spontaneously. A 52-year-old man bled massively on the eighth day after a radical pancreaticoduodenectomy (Whipple procedure) for carcinoma of the head of the pancreas. The stomach and the distal loop of jejunum were completely normal; intubation of the proximal jejunal loop revealed a clot at the anastomosis between the common duct and the jejunum. He rebled twice and required re-exploration for control of the bleeding. In this instance, the stomach and gastrojejunal anastomosis were ruled out preoperatively as possible sources of bleeding. He subsequently recovered and was discharged after a stormy postoperative course.

### Patients with Normal Endoscopic Findings

Fourteen patients had massive gastrointestinal bleeding without hematemesis and had no blood in the nasogastric aspirate. In order to rule out completely a bleeding lesion above the ligament of Treitz (or because the history was not clear), these patients were gastroscoped. The upper gastrointestinal tract was normal in all. The final diagnoses are listed in Table 3. As might be expected, the majority were bleeding from colonic diverticulosis. A bleeding Meckel's diverticulum in a 21-year-old man was demonstrated only after laparotomy. An arteriovenous malformation of the ileum was shown by superior mesenteric artery angiogram in a 75-year-old patient and successfully removed. Two cases of mesenteric thrombosis were diagnosed at laparotomy. In three patients, we found no cause for bleeding after repeated gastroscopies,

TABLE 3. Final Diagnosis in 14 Patients with Gastrointestinal Hemorrhage and Normal Upper Gastrointestinal Tract

Diverticulosis of the colon	6
Cancer of the upper sigmoid	1
Bleeding Meckel's diverticulum	1
Arteriovenous malformation of the ileum	1
Mesenteric thrombosis	2
No diagnosis	3
Total	14

colonoscopies, and x-ray examinations including angiograms.

### Diagnostic Failures

We have missed or made the wrong diagnosis on 5 occasions in the 192 patients (Table 4). We missed a duodenal ulcer early in this study, likely because of inexperience. Duodenal ulcers can hide behind the pyloric rim and may be difficult to visualize with a forward-viewing gastroscope. We missed a gastric ulcer in one patient and hemorrhagic gastritis in another because of the massive bleeding which augmented other technical difficulties in visualizing the stomach. With truly massive bleeding, some lesions in the stomach (e.g., a gastric ulcer or diffuse hemorrhagic gastritis) may be missed because of the large clots which accumulate in the stomach. The duodenum and the esophagus are usually clear of blood and lesions in those locations give the endoscopist less difficulty. The fourth diagnostic failure was in a 45-year-old man in whom we made the diagnosis of a Mallory-Weiss tear; he was actually bleeding from esophageal varices. This man is interesting because he is the only patient with a Mallory-Weiss tear who required operation. He indeed had a mucosal tear which was documented on three examinations; however, it was sitting on top of a varix. More than a failure of perception, it was a failure of interpretation and a misjudgment. Finally, in our earlier experience, we made a diagnosis of bleeding duodenal ulcer in a patient who was actually bleeding from esophageal varices. The correct diagnosis in this patient was made at the time of exploration when a cirrhotic liver, a normal duodenum and gross evidence of portal hypertension were present. Profuse bleeding was found coming from the cardia.

In three patients we could never detect the exact site of bleeding. In two of them after laparotomy and complete endoscopic intraoperative visualization of the small bowel and colon, we still did not find the bleeding site. Two years and two months later, in repeated examinations, we have still been unable to find the source of bleeding in these three patients.

### Mortality

The overall mortality in 192 patients was 16.64% (32 patients). Of the 58 patients who underwent operation, 15 died (25.9%). Twelve deaths were in patients with emergency portacaval shunts; the other three deaths were as follows: a patient with a bleeding duodenal ulcer who died from a leaking duodenal stump, a patient with gastric ulcer who died from sepsis, and a cirrhotic patient with gastritis who died from liver failure shortly after an 80% subtotal gastrectomy. If

TABLE 4. *Diagnostic Failures in 192 Consecutive Fiberoptic Endoscopies for Massive Gastrointestinal Bleeding*

Duodenal ulcer	1
Gastric ulcer	1
Esophageal varices	2
Hemorrhagic gastritis	1
No diagnosis	3
Total	8 (4.16%)

we exclude the protacaval shunt group, our mortality for emergency operations in massive gastrointestinal bleeding was 7% (3 of 42 patients).

### Complications

We have had no complications from endoscopy except for expensive bites to the instrument and painful bites to fingers. Even though almost all patients will vomit during the procedure, we have not seen a single instance of aspiration cause any later problem. To prevent aspiration, we avoid pillows under the head and allow the gastric secretions simply to run out of the mouth. We do not aspirate the oropharynx during the procedure. Three patients have died within less than one-half hour of the endoscopic procedure. Two were cirrhotic patients who were bleeding massively from esophageal varices, before, during and after endoscopy. They bled to death before adequate control could be obtained. The third patient had chronic renal failure, congestive heart failure and hemorrhagic gastritis.

### Comments

In 1963, Berkowitz<sup>2</sup> reported 200 cases of fatal gastrointestinal hemorrhage, in whom the correct diagnosis was made in only 67%. Furthermore, in 11% of the patients, the site of bleeding could not be determined. In 8% of the cases, the diagnosis was not even suspected. Mortality rates in gastrointestinal bleeding are much higher when the diagnosis is unknown. It is vitally important to improve diagnostic accuracy, and furthermore, it is often possible to identify lesions that will not respond well to operation. We believe that this is a most important asset.

The improvement in diagnostic accuracy provided by early fiberoptic endoscopy of the esophagus, stomach and duodenum in patients with major upper gastrointestinal bleeding is well established.<sup>8,11-13</sup> A recent panel<sup>6</sup> on massive gastrointestinal bleeding agreed that after a history and physical examination had been obtained, and while blood replacement is on the way, the next step in the management of massive upper gastrointestinal bleeding is visualization of the esophagus, stomach and duodenum with the fiberoptic scope. In

the vast majority of the cases, a carefully performed endoscopy will make the diagnosis. In the group of 192 patients reported here, the specific diagnosis was made in 184, or 96%.

An additional advantage of endoscopic diagnosis is the possibility of control of some lesions by endoscopic electrocoagulation. Preliminary reports are encouraging.<sup>3,14</sup> Certain lesions are obviously more amenable to this type of treatment (e.g., Mallory-Weiss tears, localized mucosal bleeders, suture line bleeders). Attempts at cauterization of some lesions (e.g., bleeding varices) would probably be disastrous.

The question of who should perform endoscopy is often raised. We believe that it should be done by those individuals (gastroenterologists, surgeons, or others) who are well-trained and who provide prompt, accurate and conscientious service for these sick patients. For the surgeon, performance of the endoscopy by the surgical team is a great advantage: the procedure is readily and rapidly available (even during the small hours of the morning and on weekends) and the search for specific diagnosis is perhaps more intense since the next step could be blind exploration of the patient. Motivation is high.

### References

1. Belber, J. P.: Gastroscopy and Duodenoscopy. *In*: Gastrointestinal Disease. M. H. Sleisenger and J. S. Fordtran (eds.), Philadelphia, W. B. Saunders Co., 1973; pp. 521-535.
2. Berkowitz, D.: Fatal Gastrointestinal Hemorrhage: Diagnostic Implications From a Study of 200 Cases. *Am. J. Gastroenterol.*, 40:372, 1963.
3. Blackwood, W. D. and Silvis, S. E.: Electrocoagulation of Hemorrhagic Gastritis. *Gastrointest. Endosc.*, 18:53, 1971.
4. Bonanno, C. A., Robilotti, J. G. and Martel, A. J.: The Value of Emergency Endoscopy in Active Bleeders. *Gastroenterology*, 62:883, 1972.
5. Child, C. G., III: The Liver and Portal Hypertension. Philadelphia, W. B. Saunders Co., 1964.
6. Dunphy, J. E., Mikkelsen, W. P., Moody, F. G. and Silen, W.: Massive Gastrointestinal Bleeding. A Panel by Correspondence. *Arch. Surg.*, 107:367, 1973.
7. Foster, J. H., Hickok, D. F. and Dunphy, J. E.: Factors Influencing Mortality Following Emergency Operation for Massive Upper Gastrointestinal Hemorrhage. *Surg. Gynecol. Obstet.*, 117:257, 1963.
8. Gang, M. J. and McCray, R. S.: Emergency Endoscopy in a Voluntary Hospital. *Gastrointest. Endosc.*, 16:231, 1970.
9. Hedberg, S. E.: Endoscopy in Gastrointestinal Bleeding. A Systematic Approach to Diagnosis. *Surg. Clin. North Am.*, 54:549, 1974.
10. Katon, R. M. and Smith, F. W.: Panendoscopy in the Early Diagnosis of Acute Upper Gastrointestinal Bleeding. *Gastroenterology*, 65:728, 1973.
11. Mann, N. S.: Hemorrhagic Duodenitis: Endoscopic Study. *Am. J. Med. Sci.*, 266:437, 1973.
12. McGinn, F. P. and Wilken, B. J.: Endoscopy in Upper Gastrointestinal Haemorrhage. *J. Roy. Coll. Surg. (Edin.)*, 19:112, 1974.
13. Papp, J. P.: Endoscopic Experience in 100 Consecutive Cases with the Olympus GIF Endoscope. *Am. J. Gastroenterol.*, 60:466, 1973.
14. Papp, J. P.: Endoscopic Electrocoagulation in Upper Gastrointestinal Hemorrhage. A Preliminary Report. *JAMA*, 230:1172, 1974.
15. Stewart, J. D., Cosgriff, J. and Gray, J. G.: Experiences with the Treatment of Acutely Massively Bleeding Peptic Ulcer by Blood Replacement and Gastric Resection. *Surg. Gynecol. Obstet.*, 103:409, 1956.
16. Sugawa, C., Shier, M., Lucas, C. E. and Walt, A. J.: Electrocoagulation of Bleeding in the Upper Part of the Gastrointestinal Tract. A Preliminary Experimental Clinical Report. *Arch. Surg.*, 110:975, 1975.
17. Sugawa, C., Werner, M. H., Hayes, D. F., et al.: Early Endoscopy. A Guide to Therapy for Acute Hemorrhage in the Upper Gastrointestinal Tract. *Arch. Surg.* 107:133, 1973.
18. Waldram, R., Davis, M., Nunnerley, H. and Williams, R.: Emergency Endoscopy After Gastrointestinal Haemorrhage in 50 Patients with Portal Hypertension. *Br. Med. J.*, 4:94, 1974.