

# Tracheal Stenosis Following Prolonged Cuffed Intubation: Cause and Prevention

DON R. MILLER, M.D., GULSHAN SETHI, M.D.

*From the Department of Surgery, University of Kansas School of Medicine,  
Kansas University Medical Center, Kansas City, Kansas*

RECENT technics to provide prolonged respiratory assistance by positive pressure ventilation through endotracheal or tracheostomy tubes have saved lives which otherwise may have been lost. The tubes have required a mechanism to occlude the trachea so that gas under pressure inflates the lungs and does not escape through the larynx into the pharynx. This has usually been accomplished by inflation of an elastic cuff about the tube to a pressure sufficient to prevent escape of gas from the assist-system.

Increased use of assisted ventilation has been associated with reports of tracheal stenosis.<sup>2, 3, 4, 5, 12, 15, 18, 19</sup> Although Pearson and associates<sup>16</sup> showed that the stoma is most commonly the site of stenosis, other reports almost all point to the site of the cuff.<sup>4, 5, 9, 13, 18</sup> Subglottic injury<sup>9</sup> by the tip of the tube also has been described. The injury has been ascribed to the tracheostomy itself,<sup>14</sup> type of tube,<sup>2, 5, 11, 13, 15, 18</sup> trauma of the tip,<sup>18, 19</sup> infection,<sup>4, 18</sup> and the pressure within the cuff.<sup>5, 9, 18, 19</sup> Direct tracheal trauma may also be responsible.<sup>5</sup> These reports and the development of similar lesions in two patients stimulated

the present study of cause and pathogenesis and the development and evaluation of a tube for ventilation which eliminates the inflated cuff and which may prevent tracheal stenosis. The study included: (1) review of the clinical findings and course of two patients with tracheal stenosis, (2) observations of tracheal morphology in seven patients who had assisted ventilation for 36 hours to 23 days prior to death from other causes and (3) animal experiments to test cuffed and uncuffed tracheostomy tubes.

## Case Reports

**Case 1.** A 40-year-old woman sustained injuries to the thorax, abdomen, and bony pelvis in an automobile collision. At laparotomy traumatic lesions of the liver, spleen, small intestine and urinary bladder required surgical correction. There were extensive fractures of ribs on both sides posteriorly, the left clavicle and pelvis. Left and right pleural tubes were placed to drain hemopneumothoraces and tracheostomy with plastic cuffed tube was established. Ventilatory assistance was necessary for effective ventilation and bronchoscopy was repeatedly done to clear tracheobronchial secretions. At the time bilateral pulmonary infiltrates developed, arterial blood gases were  $P_{O_2}$ , 68 mm. Hg;  $P_{CO_2}$ , 20 mm. Hg; and pH, 7.5. By the 8th postinjury day it was possible gradually to withdraw respiratory assistance and one week later the cuffed tube was exchanged for a metallic one and assistance was

---

Submitted for publication May 16, 1969.

Supported in part by a grant from the Kaw Valley Heart Association.

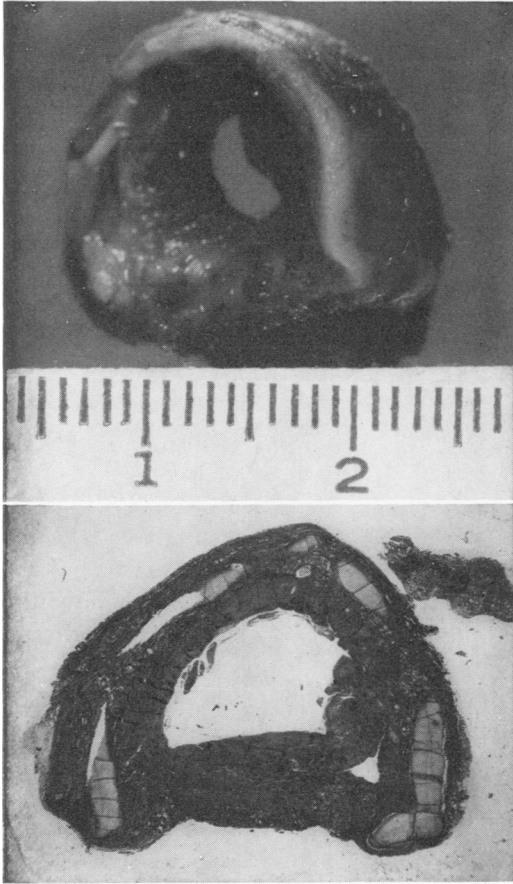


FIG. 1 (top). Gross specimen of tracheal stenotic lesion removed from patient in Case 1. The lumen is narrowed to 5 mm. by fibrous proliferation and granulation tissue. FIG. 2 (bottom). Cross section of tracheal stenotic lesion removed from patient in Case 2. Note marked fibrous thickening of the wall internal to the cartilages.

discontinued. The tracheostomy tube was removed and the patient was dismissed 27 days following injury. She returned to her activities of teaching but 10 weeks later developed symptoms of weakness, coughing, dyspnea, stridor and mucous production with choking. Chest x-ray showed the lungs clear, however, and tracheogram showed marked stenosis. Bronchoscopy confirmed the presence of a stenotic lesion 5 mm. in diameter located 5 cm. proximal to the carina in the region of the cuff site. The stricture was dilated with the bronchoscope with clinical improvement. Ten days later the maximum breathing capacity was only 53% of that predicted with marked reduction in the mid-inspiratory flow rate. Although initially the stenotic lesion was mem-

branous, on subsequent dilatations, the scar became thickened, tough, and resisted dilatation. Inspiration and expiratory flow rates doubled after dilatation but were still only 50% of normal. After four dilatations and progressive thickening of the stenosis, bronchoscopic dilatations were discontinued and resection of the involved segment was done 14 weeks after the original injury. The right posterolateral approach was used for mobilization of the trachea, bifurcation and the right lung, and excision of the lesion with end-to-end anastomosis. The early and subsequent course was uncomplicated and the patient has remained well without symptoms.

The removed specimen was 1.5 cm. in length and contained a thick fibrous stricture narrowing the lumen to 0.6 cm. (Fig. 1). The fibrous tissue proliferation was most marked on the internal side of the cartilages, the histologic section of which demonstrated loss of nuclei in the inner zone of the cartilage when compared with the outer zone.

**Case 2.** A 50-year-old woman had symptoms and findings upon cardiac catheterization of severe mitral stenosis associated with pulmonary obstructive disease confirmed by preoperative pulmonary function studies.

On 10-26-68 mitral valve replacement was done using a Starr-Edwards prosthesis. Postoperative support of ventilation was required and bronchoscopy was done to eliminate retained secretions. Ventilatory assistance was instituted for 8 days, then gradual discontinuance was initiated and the tracheostomy was terminated on the 17th day. The patient was readmitted one month later because of dyspnea and development of a prominent systolic murmur. Retrograde aortic catheterization showed displacement of a portion of the mitral valve prosthetic fixation. The mitral valve was replaced on 12-27-67 and the tracheostomy was re-established with ventilatory assistance through a cuffed tube for 4 days when intermittent assistance was begun. The tracheostomy tube was removed on the 13th day. Small bowel obstruction developed and adhesions required lysis on the 6th postoperative day. The patient complained of increasing dyspnea associated with stridor approximately 7 weeks after the second valve replacement. Tracheogram on 2-23-68 suggested tracheal stenosis. The mid expiratory flow rate was 0.85 liters/minute with a predicted value of 3.0 liters/minute.

Bronchoscopy on 2-22-68 showed tracheal stenosis 6 cm. proximal to the carina with an orifice 6 ml. in diameter, composed of granulations and contracted membrane, at the site of the tube cuff. Bronchoscopic dilatations were nec-

TABLE 1. *Gross and Microscopic Findings of the Tracheas in Seven Patients Who Died of Other Causes after Having Received Respiratory Support*

No.	Duration of Tracheostomy	Duration of Cuff Inflation	Gross Findings	Microscopic Findings
1	36 hours	36 hours	Erosion of cartilage rings	Deep mucosal ulceration
2	36 hours	36 hours	Deep ulceration with exposure of cartilage	Mucosal ulceration with cartilage destruction
3	4 days	72 hours	Circumferential deep erosion with exposure of cartilage	Acute ulceration with destruction of mucosa
4	13 days	10 days (intermittent)	Partial circumferential necrosis of the tracheal rings	Deep ulceration with destruction of cartilage
5	15 days	11 days (intermittent)	Erosion of the cartilage rings	Deep mucosal ulceration with destruction of cartilage
6	22 days	15 days (intermittent)	Erosion and necrosis of cartilage. Perforation of posterior wall of trachea	Deep ulceration with destruction of cartilage
7	23 days	17 days (intermittent)	Erosion and necrosis of cartilage rings	Deep ulceration with destruction of cartilage

essary on four occasions at 2 to 3 week intervals but became progressively difficult and on 5-16-68 tracheal resection was done through the right posterolateral approach. The postoperative course was uncomplicated. There has been no recurrence of tracheal obstruction in spite of the persistent symptoms of cardiac decompensation which required a third cardiectomy.

The tracheal specimen was 2.2 cm. in length and the lumen of the stenotic segment was 7 ml. in diameter. There was marked fibrous proliferation as in the previous specimen (Fig. 2). Squamous metaplasia was present at the site of stenosis. Loss of nuclei in the inner zone of cartilage was evident (Fig. 3).

*Comment.* These two patients, in spite of careful management by knowledgeable nurses and on a program of frequent cuff deflation, developed tracheal stenosis at the site of the cuff. Both patients had assisted ventilation over a period of several days.

These, and others reported to have succumbed without recognition of the obstruction, demonstrate the insidiousness of onset and the severe degree of obstruction

which may develop prior to significant symptoms of stridor. Chest x-ray is unchanged by the lesion and unless the possibility of tracheal stenosis is recognized progression to death from suffocation can ensue. Bronchoscopy confirms the diagnosis and may provide temporary relief.




FIG. 3. Cartilage and overlying proliferating fibrous tissue in specimen from tracheal stenotic lesion in Case 2. Nuclei of cartilages are degenerated on the luminal side corresponding to area of the cuff.

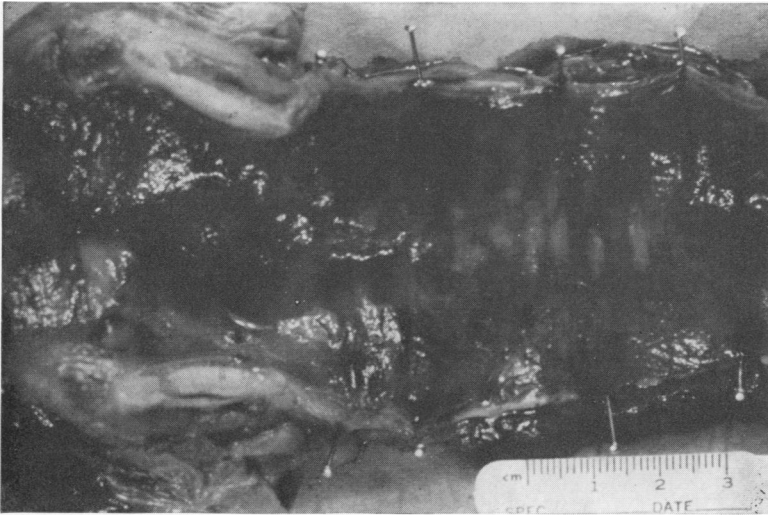


FIG. 4. Tracheal changes of erythema, inflammation and early ulceration at the site of cuff after 36 hours of endotracheal intubation in Case 1.

### Autopsy Material

Seven patients who were treated by assisted ventilation by cuffed plastic tracheostomy tube or endotracheal tube and who died of other causes were autopsied and the tracheas were grossly and microscopically examined. The duration of tracheal intubation varied from 36 hours to 23 days. Data is tabulated in Table 1 which summarizes the gross and microscopic morphology of trachea, the duration of the tracheostomy and period of inflation of the cuff. All patients had tracheal injuries which corresponded to the site of the cuff, the degree of which was directly related to the duration of ventilatory support. Gross findings were early mucosal inflammation after 36 hours (Fig. 4). This extended to deep ulceration and destruction of cartilaginous rings (Figs. 5, 6, 7). Microscopically ulceration and surrounding perichondral inflammatory reaction and granulation proliferation were found (Fig. 8).

All patients had had good tracheal tube care with periodic deflation of the cuff by competent personnel of the intensive care unit.

### Development of Flanged Tube

These findings implicate pressure in the cuff as the major etiologic factor in tracheal injury. It appeared that injuries could be avoided by elimination of the cuff.

The concept of a series of thin flanges on the tracheostomy tube to function as a cuff in prevention of escape of inflating gas into the oropharynx was explored. A

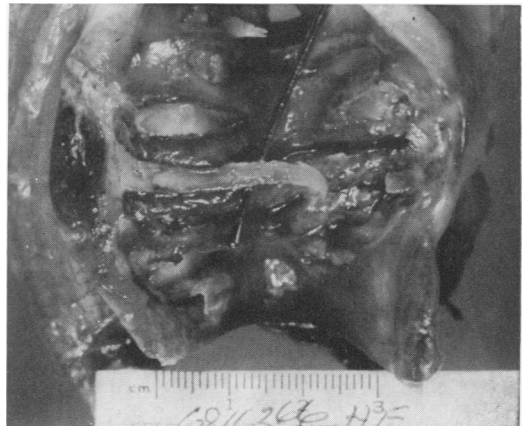

FIG. 5. Severe tracheal destruction at the site of the cuff in patient 7 who had assisted ventilation with cuffed tube for 17 days. Note fragmented and exposed cartilage rings.

FIG. 6. Ulceration and cartilage fragmentation at site of cuff in autopsy Case 5, after 11 days of tracheal intubation with cuffed tracheostomy tube.



simple injection mold to produce a silastic sleeve with attached concentric circular flanges of silastic rubber was fabricated.

Circular rings of the material were made by the injection mold which consisted of four blocks of plexiglas with a central hole the size of the tracheostomy tube (Fig. 9). Cardboard spacers were inserted between the plexiglas blocks and a punched out central circular portion provided space for the flanges. Liquid silastic was injected into the central cavity by needle inserted through a small defect in one cardboard insert. The mold was assembled and held together by bolts.

After mounting the blocks and cardboard spacers and a plexiglas rod the size of the tube, medical adhesive silastic was injected into the spaces of the mold produced by the plexiglas and cardboard spacers. After curing 48 hours, the mold was disassembled and the cast removed.

This cast sleeve and flanges was then cemented to a standard plastic tracheostomy tube after first removing the cuff (Fig. 10A, B). The flanges were thin and collapsible yet were resilient enough to

resist escape of gas into the oropharynx without producing significant pressure on the tracheal wall. Linear contact with the tracheal wall is over a lesser area than that with the conventional cuff (Fig. 11). Repeated use of the mold resulted in adherence of the silastic to the surface of the mold, making removal of the cast difficult without disruption. Subsequent models of the flange device were fabricated by stamping discs, 22 mm. in diameter, 0.020 inch thick, from silastic sheeting which were cemented to the tracheostomy tube using small segments of silastic tubing for support. Although three flanges were initially used, two rings 4 mm. apart have been found sufficient to prevent escape of gas at 50 Cm. H<sub>2</sub>O pressure.

#### Animal Experiments

Mongrel dogs of 14 to 25 Kg. were used. Animals were anesthetized with intravenous pentobarbital sodium 30 mg./Kg. and using sterile technic, a low tracheostomy was performed removing a small portion of a cartilage ring. Three groups of experiments were done.

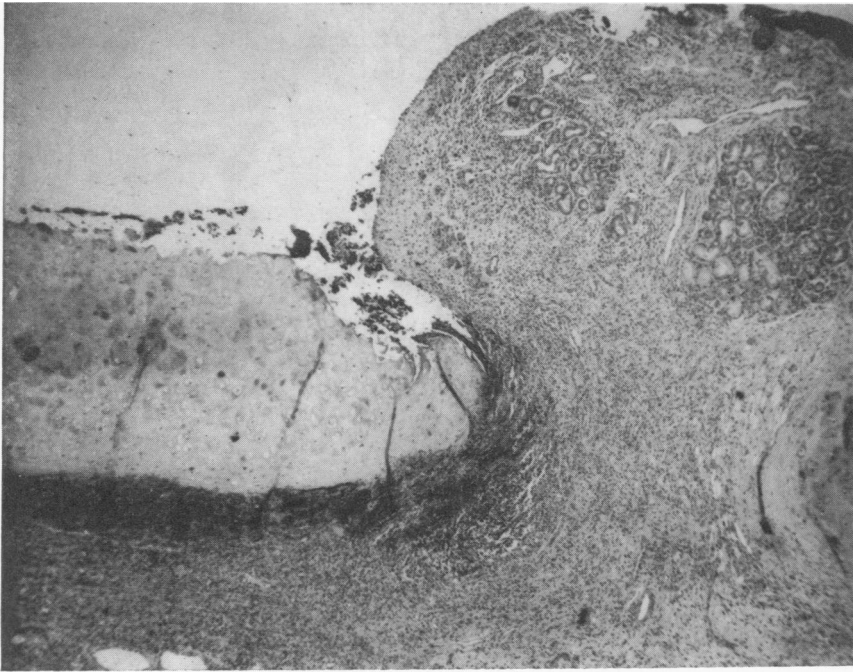


FIG. 7. Microscopic section of tracheal wall of autopsy Case 4, showing proliferating granulation tissue between cartilage rings and the mucosal ulceration and exposure of tracheal rings.

### Group I—Constant Cuff Inflation

In 7 dogs a #36 plastic Portex tube was used and the cuff inflated to a pressure just sufficient to prevent leakage of gas around the tube when attached to a pressure cycled respirator delivering 50 centimeters H<sub>2</sub>O pressure. The cuff was kept constantly inflated for periods up to 14 days except when tubes were changed daily. Several dogs died of mucoid obstruction of the tracheostomy tube while unattended. All surviving dogs except one were then sacrificed within 12 days. One was permitted to survive and was sacrificed after 3 months. The lungs and trachea were removed and examined grossly

and preserved in formalin, sectioned and stained with hematoxylin and eosin and microscopic sections studied.

### Group II—Intermittent Cuff Inflation

Six animals were used. Experiments were similar to Group I except the cuff was deflated for 5 minutes each hour. Experiments were similar to Group I except the cuff was deflated for 5 minutes each hour. Experiments were continued for 24 to 48 hours.

### Group III—Flanged Cuff Tube

Ten dogs were used in which the silastic flanged tracheostomy tube was used. The

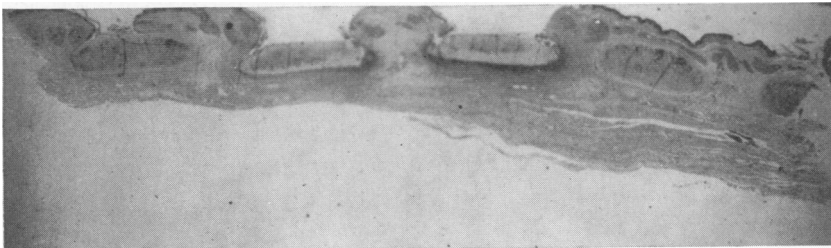


FIG. 8. Lower power of autopsy Case 4, demonstrating ulceration of tissues over the luminal surface of the tracheal cartilages at the site of the cuff.




FIG. 9. Injection mold assembled.

remainder of the method was the same as in Group I.

### Results

The results are summarized in Tables 2, 3 and 4.

Dogs in Group I in which the cuff was inflated constantly for 2 to 12 days had severe ulcerations of tracheal mucosa in an area corresponding to the site of the cuff as shown in Fig. 12. The cartilage rings were exposed in most animals, and acute and chronic inflammatory changes, necrosis and granulation tissue were seen in more mature lesions. One animal sacrificed 3 months following 12 days of constant cuff inflation developed tracheal stenosis similar to that seen clinically (Fig. 13).

In Group II, in which experiments extended to 48 hours with intermittent deflation of the cuff, the changes were limited to mucosal erosion and ulceration with infiltration of acute inflammatory cells.

In Group III, using the flanged tube without cuff, the findings were similar to those of Group II although 8 of 10 experiments extended for more than 4 days. One trachea, in which the tube was disproportionately large, was severely ulcerated. Marked cartilage destruction, granulations

and deep ulceration seen uniformly in the group with constant cuff pressure was not observed (Fig. 14).

### Discussion

Although injury at the laryngeal, subglottic,<sup>9</sup> stomal,<sup>13</sup> and tube tip<sup>14, 19</sup> locations have been described, most reports locate tracheal stenosis at the site of the cuff.<sup>4, 5, 9, 13, 18, 19</sup>

Variables in tube construction<sup>2, 11</sup> and methods of tracheostomy care led to con-

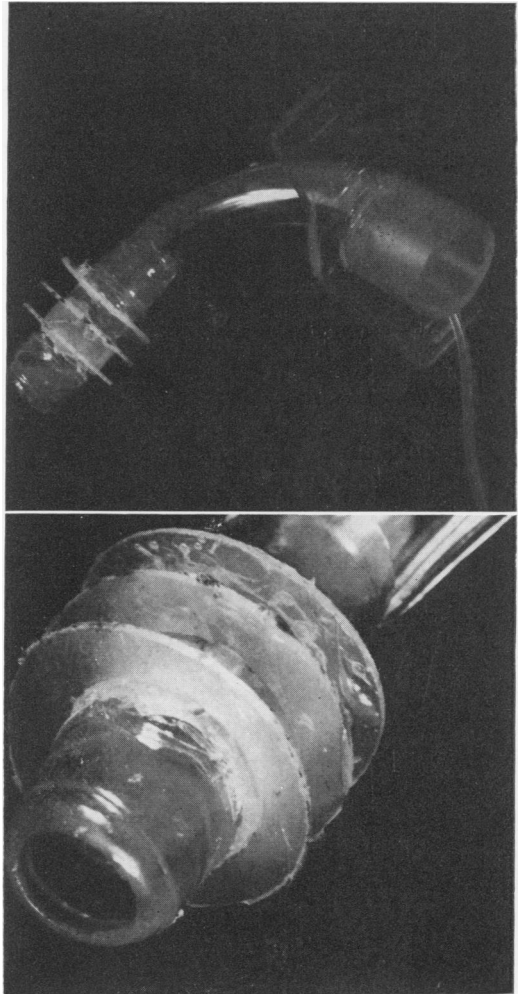


FIG. 10A. First model of the flanged tube with three flanges. Subsequent model used only two flanges. FIG. 10B. Enlarged view showing details of flanges.

TABLE 2. Controls with Constant Inflation of the Cuff

No.	Duration of Intubation	Death or Sacrifice	Gross Findings	Microscopic Findings
1	2 days	Sac.	Marked ulceration with exposure of cartilage	Severe ulceration of mucosa and necrosis of cartilage
2	3 days	Died	Marked ulceration	Deep ulceration with cartilage destruction
3	3 days	Sac.	Marked ulceration with exposure of cartilage	Focal ulceration, thickening and fibrosis of submucosa, acute inflammatory cells
4	4 days	Sac.	Marked ulceration and exposure of cartilage	Ulceration and exposure of cartilage, acute inflammatory cell infiltration
5	4 days	Died	Marked ulceration with exposure of cartilage	Marked ulceration, destruction of cartilage and acute inflammatory reaction
6	7 days	Died	Marked ulceration with perforation of trachea	Severe ulceration, necrosis cartilage, granulations
7	12 days	Sac.	Severe ulceration with necrosis of cartilage	Severe ulceration, perichondritis, granulation tissue, polymorphonuclear leucocyte infiltration

fusion regarding major factors causing tracheal injury. Infection<sup>4</sup> and movement of the tube<sup>1, 4, 19</sup> are common. Although these variables may be important, accumulating evidence<sup>3, 4, 5, 9</sup> indicates that pressure within the cuff produces ischemic necrosis of the tracheal wall which undergoes ste-

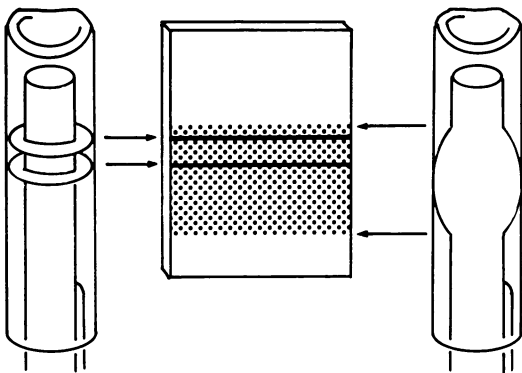


FIG. 11. Diagrammatic sketch demonstrating comparisons of the relative areas of contact of the tube cuff (right) and the flanged tube (left). Tracheal stenosis is probably related to the area as well as depth of the injury.

nosis in healing. Duration of pressure is important, in that severity of injury is often directly related to the length of time artificial ventilation is maintained.<sup>14, 18</sup> Significant changes occurred after only 36 hours in this study. At what level is cuff pressure safe? Probably that minimum pressure which allows close contact of the cuff to the tracheal wall without obliterating capillary blood flow. Periodic deflation and reinflation has not prevented tracheal injury in our patients nor in those reported by others.<sup>5, 18</sup>

Efforts to prevent injury have been ineffective because the importance of cuff pressure has not been recognized, but phasic deflation of the cuff during the respiratory cycle and use of the fenestrated tube<sup>12</sup> are theoretically sound measures. Prevention is aided by prompt discontinuance of intubation when it is no longer needed.

Recommendations that the cuff be long rather than short<sup>9, 10, 19</sup> are not valid un-



TABLE 3. *Controls with Intermittent Deflation of the Cuff*

No.	Duration of Intubation	Death or Sacrifice	Gross Findings	Microscopic Findings
1	24 hours	Sac.	Minimal inflammation	Acute inflammatory changes
2	24 hours	Sac.	Minimal inflammation	Focal superficial ulceration and acute inflammation
3	36 hours	Sac.	Erythema and superficial ulceration	Focal erosion of mucosa
4	36 hours	Sac.	Superficial mucosal ulceration	Focal ulceration
5	48 hours	Sac.	Superficial ulceration	Focal mucosal ulceration and polymorphonuclear leucocyte infiltration
6	48 hours	Sac.	Superficial ulceration	Mucosal ulceration, cartilage normal

less cuff pressure is reduced because a large area of circumferential injury results in greater likelihood of stricture than does a smaller one. Linear contact of the circumference of the flanges, therefore, is theoretically favorable and has been found to be an actuality in experiments.

Results in both animal and human studies <sup>4, 9, 18, 19</sup> support the concept of pressure necrosis which initially erodes tracheal mucosa and extends to involve cartilage and deeper layers. The presence of infection increases the destructive process.<sup>4, 18</sup> Chondritis may induce marked fibrous tis-

TABLE 4. *Experimental Dogs with Flanged Tracheostomy Tube*

No.	Duration of Intubation	Death or Sacrifice	Gross Findings	Microscopic Findings
1	1 day	Sac.	Normal trachea	Acute inflammatory changes
2	3 days	Sac.	Normal trachea	Superficial loss of epithelium
3	4 days	Died	Superficial ulceration of mucosa	Mucosal ulceration with erosion of cartilage destruction, increased fibrous tissue
4	5 days	Sac.	Erythma, no ulceration	Epithelium intact, polys in lumen
5	6 days	Died	Erythma, no ulceration	Mucosa intact
6	6 days	Sac.	Superficial ulceration	Deep ulceration of mucosa, cartilage normal, submucosal hemorrhage
7	7 days	Sac.	Deep ulceration with occasional exposure of cartilages	Deep ulceration of epithelium, submucosal thickening
8	8 days	Sac.	Superficial erosions	Superficial ulceration of mucosa
9	11 days	Died	Superficial ulceration	Superficial epithelial loss, cartilage normal, acute inflammatory cells
10	12 days	Sac.	Superficial ulceration	Loss of epithelium, cartilage normal, inflammatory cells present

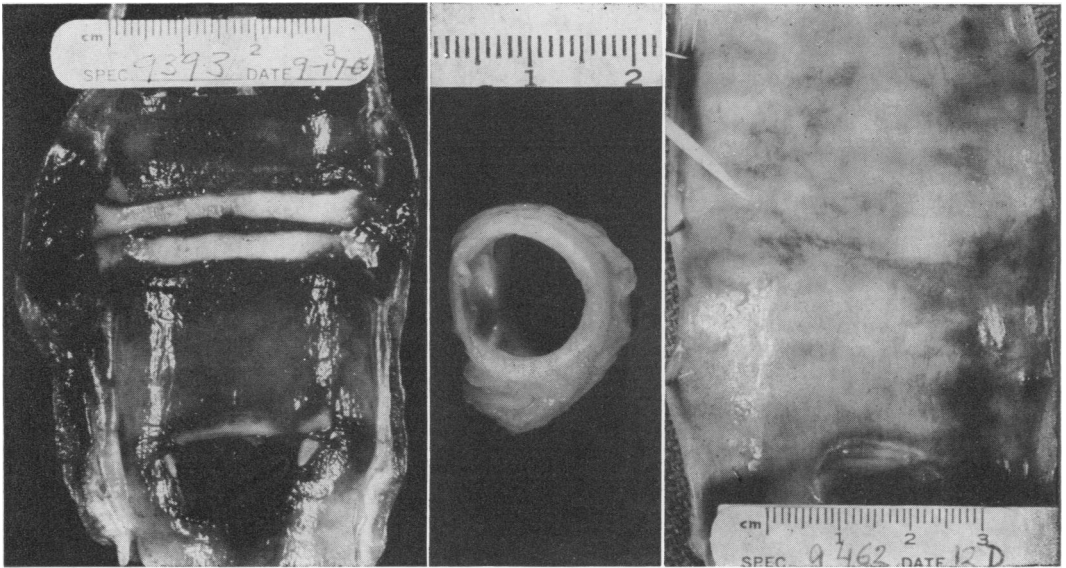


FIG. 12 (left). Trachea of dog subjected to constant cuff inflation for 7 days. Note ulceration of mucosa and exposure of the underlying cartilages at the site of the cuff.

FIG. 13 (center). Stenotic lesion in a dog at cuff site 3 months after constant cuff inflation of 12 days duration.

FIG. 14 (right). Trachea of animal after the flanged tube had been in place 12 days. Only minimal superficial erosive change is noted.

sue proliferation. The process is worse on the unyielding anterior and lateral walls supported by cartilage than on the distensible posterior wall. Bronchoesophageal fistulization has been reported, however.<sup>18</sup> Both clinically and experimentally induced strictures followed cuff inflation of approximately 2 weeks duration. Granulation tissue progressed to fibrosis and a stenotic mucosal lined stricture, initially membranous,<sup>4</sup> became thickened, fibrous, and unyielding to dilatations. In Grillo's<sup>5</sup> experience the symptom-free interval varied widely, but most patients developed symptoms within 3½ weeks after removal of the tube.

Although dilatations have been attempted repeatedly over prolonged periods well developed strictures require surgical excision.<sup>2,5</sup> Numerous operative approaches have been employed. Grillo<sup>5</sup> reports good results with a cervical-mediastinal approach through a cervical incision if the lesion is high, to permit mobilization and excision of the stenotic area

and re-anastomosis. The sternal splitting incision has been employed and although feasible,<sup>2,5</sup> the anterior mediastinal vascular structures prevent easy access to the trachea and mobilization of the bronchi. Other methods described include staged plastic reconstruction,<sup>4,5</sup> cervical mediastinal incision and autologous skin grafts,<sup>5,13</sup> and pectoral flaps.<sup>13</sup>

In our two patients posterolateral thoracotomy provided excellent exposure for mobilization of the trachea and hilus and careful reapproximation of the trachea using the technic developed by Grillo.<sup>6,7,8</sup> This route permits access to the trachea beneath the superior mediastinal pleural and visualization of recurrent laryngeal nerves. The anterior mediastinal vascular structures are outside the immediate field of dissection.

### Summary and Conclusions

1. Tracheal stenosis after cuffed endotracheal intubation has been reported with increasing frequency with evidence that

excessive pressure in the inflated cuff is the major underlying cause.

2. Two patients who developed tracheal stenosis after prolonged ventilatory assistance and whose stenoses have been excised are reported.

3. Tracheas of patients who required ventilatory assistance and who subsequently died of other causes were studied and have shown ulceration in the area of the inflated cuff after 36 hours of inflation and progression to severe destruction after 2 weeks.

4. Ulcerated lesions similar to those observed in man were produced in dogs with continuous inflation of tracheostomy cuff 48 hours to 12 days. One long-term survivor developed a typical stenotic lesion. If the cuff was deflated hourly, the mucosal changes were minimal after 24 to 48 hours.

5. A new flanged tube which prevents tracheal gas reflux without a cuff has been developed and used in dogs for periods comparable to controls with constantly inflated cuffed tubes and has shown only minimal tracheal mucosal changes in 9 of 10 dogs. Clinical trial appears warranted.

6. The pathogenesis and treatment of tracheal stenosis have been discussed.

### References

1. Beaver, R. A.: The Design and Application of Positive Pressure Respirators. *Postgrad. Med. J.*, 37:22, 1961.
2. Byrn, F. M., Davies, C. K. and Harrison, G. K.: Tracheal Stenosis Following Tracheostomy. *Brit. J. Anaesth.*, 39:171, 1967.

3. Fraser, K. and Bell, P. R. F.: Distal Tracheal Stenosis Following Tracheostomy. *Brit. J. Surg.*, 54:302, 1967.
4. Gibson, P.: Aetiology and Repair of Tracheal Stenosis Following Tracheostomy and Intermittent Positive Pressure Respiration. *Thorax*, 22:1, 1967.
5. Grillo, H. C.: The Management of Tracheal Stenosis Following Assisted Respiration. *J. Thorac. Cardiovasc. Surg.*, 57:52, 1969.
6. Grillo, H. C., Benixen, H. H. and Gephart, T.: Resection of the Carina and Lower Trachea. *Ann. Surg.*, 158:889, 1963.
7. Grillo, H. C.: Circumferential Resection and Reconstruction of the Mediastinal and Cervical Trachea. *Ann. Surg.*, 162:374, 1965.
8. Grillo, H. C., Dignan, E. F. and Miura, T.: Extensive Resection and Reconstruction of the Mediastinal Trachea without Prosthesis or Graft: An Anatomical Study in Man. *J. Thorac. Cardiovasc. Surg.*, 48:741, 1965.
9. Hedden, N., Ersoz, C. J., Donnelly, W. N. and Safar, P.: Laryngotracheal Damage after Prolonged Use of Orotracheal Tubes in Adults. *JAMA*, 207:703, 1969.
10. Hewlett, A. B. and Ranger, D.: Tracheostomy. *Postgrad. Med. J.*, 37:18, 1961.
11. Little, K. and Darkhouse, J.: Tissue Reaction to Polymers. *Lancet*, 2:857, 1962.
12. Martinez, H. E.: An Improved Cuffed Tracheostomy Tube for Use with Intermittent Positive Pressure Breathing. *J. Thorac. Cardiovasc. Surg.*, 47:404, 1964.
13. McComb, M.: Treatment of Tracheal Stenosis. *Plast. Reconstr. Surg.*, 39:43, 1967.
14. McNelis, F. L.: Clinical and Experimental Experiences with Cuffed Tracheostomy Tubes. *Rhode Island Med. J.*, 50:27, 1967.
15. Pearson, F. G., Goldber, M. and da Silva, A. J.: Tracheal Stenosis Complicating Tracheostomy with Cuffed Tubes. *Arch. Surg.*, 97:380, 1968.
16. Reading, P.: Some Postoperative Hazards in Tracheostomy on Infants. *J. Laryng.*, 72:785, 1958.
17. Salt, R. H., Parkhouse, J. and Simpson, B. R.: Improved Material for Radcliffe Tracheostomy Tube. *Lancet*, 2:407, 1960.
18. Stiles, P. J.: Tracheal Lesions after Tracheostomy. *Thorax*, 20:517, 1965.
19. Watts, J. M.: Tracheostomy in Modern Practice. *Brit. J. Surg.*, 50:954, 1963.