

Benign Duodenal Tumors: Unusual Surgical Problems

WALTER LAWRENCE, JR., M.D., DONALD D. MCNEILL, JR.,* M.D.,
ALAN COHEN,* M.D., JOSE J. TERZ, M.D.

*From the Divisions of Surgical Oncology and Surgical Pathology of the Medical
College of Virginia (Health Sciences Division of Virginia
Commonwealth University), Richmond, Virginia*

BENIGN and malignant neoplasms may develop in the duodenum, but are rarely considered as diagnoses in patients with anemia, gastrointestinal bleeding, partial obstruction of the stomach, or other upper gastrointestinal symptoms. This is not surprising in view of the rarity of these tumors. Although a number of benign duodenal tumors have been reported in various studies,^{1-4, 6-9} it is striking that most patients were asymptomatic and the lesions were incidental findings at operation, or at post-mortem examination. This presentation reports experience with three benign duodenal tumors and one secondary duodenal tumor; each producing symptoms that led to surgical intervention.

Surgical treatment of benign duodenal tumors is usually simple if the tumor is on a pedicle, since local resection is appropriate. If the neoplasm is malignant, or is an unusually large benign lesion, pancreatoduodenectomy is usually necessary. Occasionally the head of the pancreas and the ampulla of Vater are uninvolved, and less extensive resection is appropriate, particularly in patients who are unsuited for pancreatoduodenectomy. In two of the four patients here reported local resection

was possible, but gastrointestinal reconstruction could not be accomplished by simple duodenal closure due to the extent of resection. A simple method of reconstruction was employed that has not been previously described.

Case Reports

Case 1. M. M., a 68-year-old woman, was admitted with a history of dizziness and weakness, and her stools were black and positive for blood. The primary finding on upper gastrointestinal x-rays was distortion of the duodenum thought to be a retroperitoneal mass or pancreatic pseudocyst. The patient was discharged without operation and 10 months later was readmitted complaining of profound weakness. Hemoglobin was 3.8 Gm./100 ml. A 3 × 3 cm. right upper quadrant mass was found just lateral to the midline. Radiographic examination showed cholelithiasis and an intraluminal mass in the duodenum (Fig. 1).

Operation: (10/25/67) A 5 cm. polypoid mass was found attached to a stalk in the second portion of the duodenum (Fig. 2). The lesion was resected by division and ligation of the stalk through a duodenotomy incision. Cholecystectomy was also performed.

Pathology: The polypoid lesion measured 4.5 × 2.2 × 1.6 cm. and a large ulcer was present over the distal aspect (Fig. 2). Microscopic examination revealed normal duodenal mucosa overlying a broad zone of adenomatous hyperplasia of the Brunner's glands within the submucosa (Fig. 3). Cystic spaces were also seen. The microscopic diagnosis was adenoma of Brunner's gland. In addition to chronic cholecystitis and cholelithiasis, there were several elevations of well differentiated intramucosal carcinoma of the gallbladder.

Submitted for publication January 14, 1970.

Presented at meeting of the Halsted Society, Nashville, Tennessee, 9/12/69.

* Clinical Fellows of American Cancer Society.

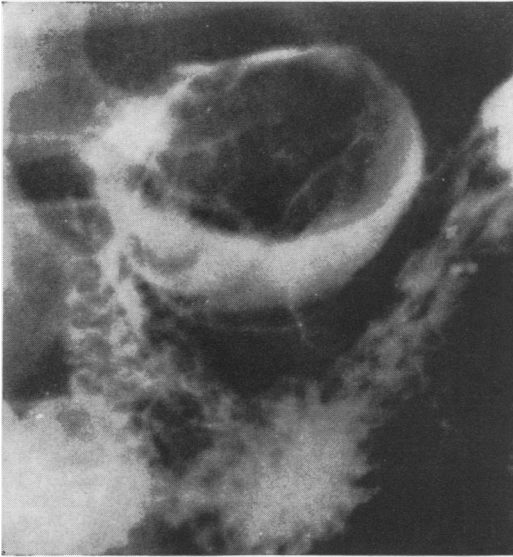


FIG. 1. Preoperative radiograph demonstrating duodenal mass that later proved to be Brunner's gland adenoma (Case 1).

Course: The patient had an uneventful recovery and has remained well.

Comment: Adenomatous polyps do not reach the size of this Brunner's gland ade-

noma, and rarely produce symptoms. Despite its relative rarity, the likely diagnosis for a *large* polypoid tumor of the duodenum is Brunner's gland adenoma.

Case 2. E. J., a 42-year-old man, had a 3-month history of epigastric pain, nausea and vomiting. Physical examination was unremarkable except for evidence of weight loss. Serum amylase was slightly elevated in the 200–300 mg./100 ml. range. Bilirubin and alkaline phosphatase determinations were normal. Radiologic examination showed a large duodenal mass (Fig. 4), and a preoperative diagnosis of Brunner's gland adenoma was made.

Operation (11/25/68): There was a mobile 5 cm. mass in the second portion of the duodenum and some induration of the head of the pancreas. Duodenotomy was performed, and the polypoid mass was found to arise from a stalk in the first portion of the duodenum (Fig. 5). A small ulceration was present on the tip of this polyp. The mass was excised through the mucosal stalk and the duodenotomy closed.

Pathology: The soft mass was grossly multicystic on transection, and histologic examination revealed a typical Brunner's adenoma.

Course: The patient's postoperative course was uneventful.

TABLE 1. *Primary Duodenal Tumors* (1951–1969)

	Diagnosis	Symptoms	Treatment
Benign			
M. M.	Brunner's gland adenoma (# 1)	GI bleeding	Excision
E. J.	Brunner's gland adenoma (# 2)	Obstruction	Excision
R. L.	Adenomatous polp	GI bleeding	Excision
W. M.	Leiomyoma	None	Excision
L. L.	Leiomyoma	None	Excision
V. H.	Leiomyoma (# 3)	GI bleeding	Excision and duodenal reconstruction
F. K.	Islet cell adenoma	Stomal ulcer	Excision
E. F.	Islet cell adenoma	Stomal ulcer	Excision
W. C.	Islet cell adenoma	Perforated gastric ulcer (? incidental)	Excision
A. G.	Lipomatosis	Epigastric distress and dyspepsia	Bypass
Malignant			
D. H.	Adenocarcinoma	Obstructive symptoms	Pancreatoduodenectomy
M. S.	Adenocarcinoma	Nausea, vomiting and epigastric pain	Pancreatoduodenectomy
W. J.	Leiomyosarcoma	No; Incidental findings at laparotomy	None
C. S.	Carcinoid	Duodenal obstruction	Pancreatoduodenectomy
H. E.	Carcinoid	Nausea, vomiting and epigastric pain	Excision
J. L.	Carcinoid	None	Excision
J. L.	Carcinoid	Unknown	Excision
W. R.	Carcinoid	None	Excision

FIG. 2A. Operative views of patient with large Brunner's gland adenoma (Case 1). Large (4.5 cm.) adenoma seen after duodenotomy. Note the mucosal ulceration over the distal half of this lesion.

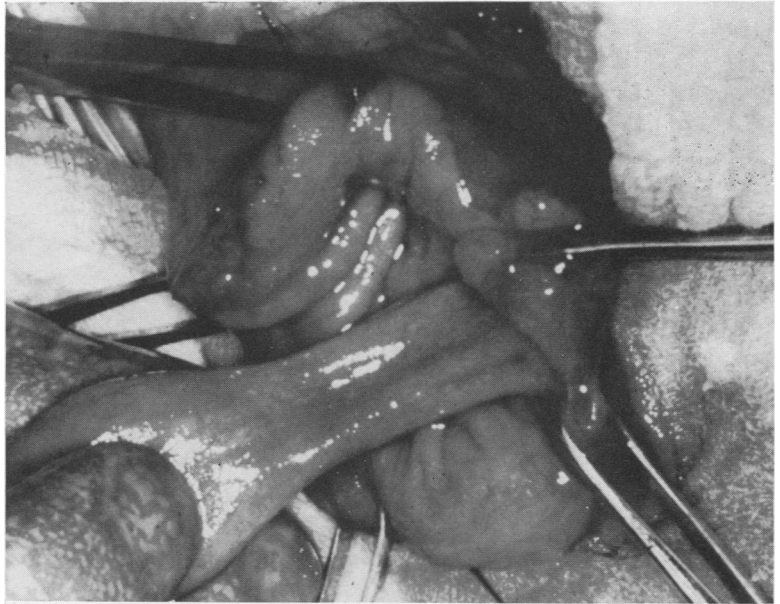
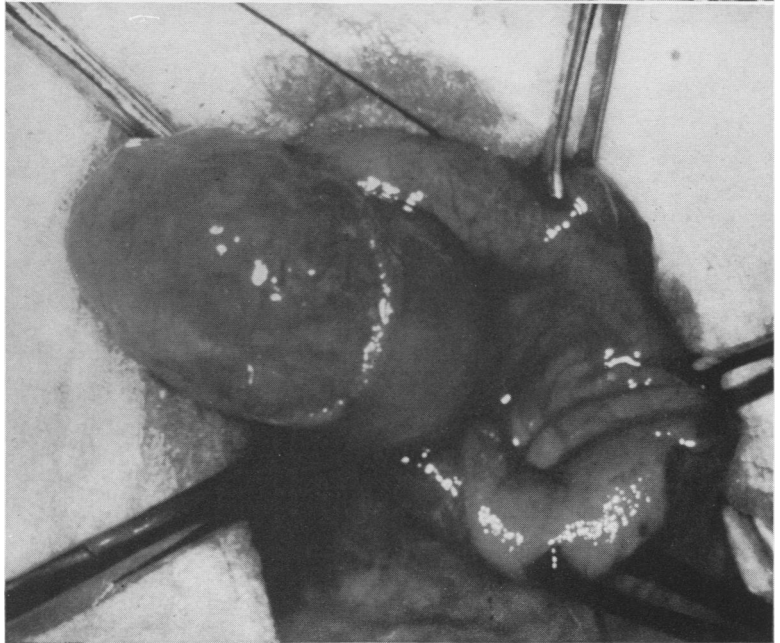


FIG. 2B. Mucosal stalk of adenoma.



Comment: Despite confusing findings prior to operation, the radiographic evidence led to a correct preoperative diagnosis. As in Case 1 it was possible to resect the lesion by transecting the stalk. Both this and the previous lesion were gigantic compared to most reported Brunner's gland adenomas.⁸

Case 3. V. H., a 78-year-old woman, complained of dizziness, weakness, and palpitation for 2 weeks prior to admission on March 12, 1969. She had anemia (Hgb. 4.5 Gm.), stools positive for blood, and pneumonia. The pneumonia was treated, and anemia corrected with transfusions of packed red cells. Gastrointestinal x-rays showed a deformity of the second portion of the duodenum with effacement of the mucosal pattern. The radiologist's impression was duodenal

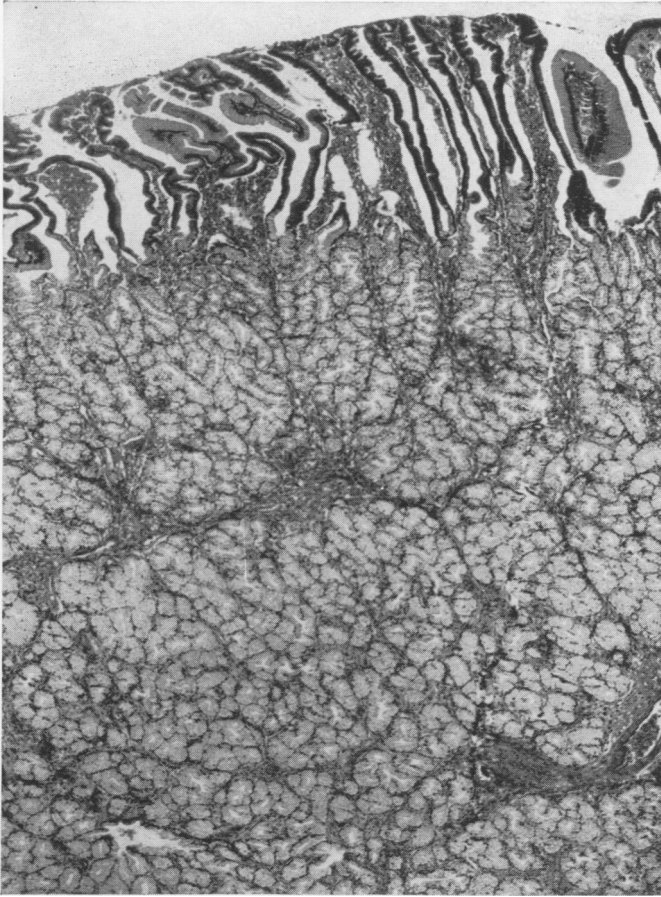


FIG. 3A. Microscopic views of Brunner's gland adenoma (Case 1). Photomicrograph shows diffuse adenomatous proliferation of the Brunner's glands underlying the intact duodenal mucosa ($\times 40$).

invasion by carcinoma of the head of the pancreas, but post-bulbar ulcer disease with scarring could not be eliminated. This patient had a history of upper gastrointestinal bleeding $2\frac{1}{2}$ years before this admission, and the roentgenographic diagnosis at that time was carcinoma of the pancreas. In view of these two episodes of major gastrointestinal hemorrhage and positive stools operation was performed with the clinical diagnosis post-bulbar ulcer.

Operation (4/1/69): There was a 6 cm. mass involving the second portion of the duodenum which initially was thought to involve the head of the pancreas. Dissection revealed, however, that the neoplasm was confined to the lateral aspect of the duodenum (Fig. 6). A probe was placed in the distal common duct after choledochotomy to identify and preserve the common duct (Fig. 7). The wall of the duodenum was then resected with a margin around the mass. There was a small ulceration on the mucosal sur-

face. The gross appearance was of a large benign leiomyoma or leiomyosarcoma. The histologic diagnosis was benign leiomyoma.

Reconstruction of the duodenum could not be carried out due to the extent of the resection (Fig. 7). Accordingly, an incision was made from the proximal portion of the duodenal defect through the pylorus and longitudinally through the anterior gastric wall as far as the junction of the middle and distal thirds of the stomach (Fig. 8). The gastric wall was used to form a new gastroduodenal pouch, and thus close the large duodenal defect. Truncal vagotomy was then performed.

Course: Twenty-four hours postoperatively an episode of atrial fibrillation was corrected by digitalization. Because of poor gastric emptying in the postoperative period reoperation and gastrojejunostomy were performed on the 17th day. On the 25th day the T-tube was removed, and on the 27th day the patient suffered a cerebrovascular accident. She recovered satisfactorily and was discharged in good condition.

FIG. 3B. With higher magnification the mucin-filled glands are seen and a cystic duct structure filled with mucin and cellular debris (\times).

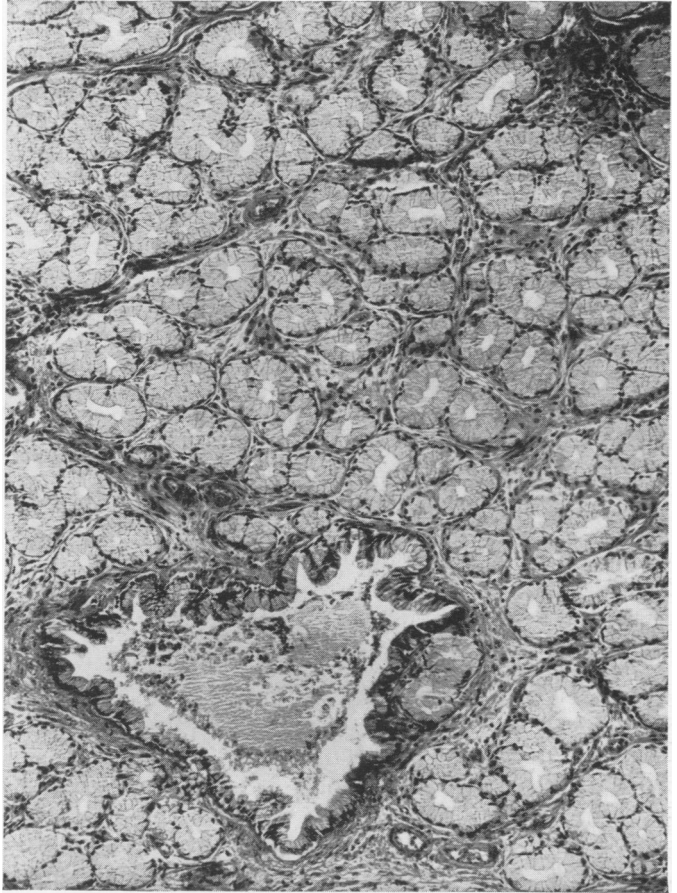
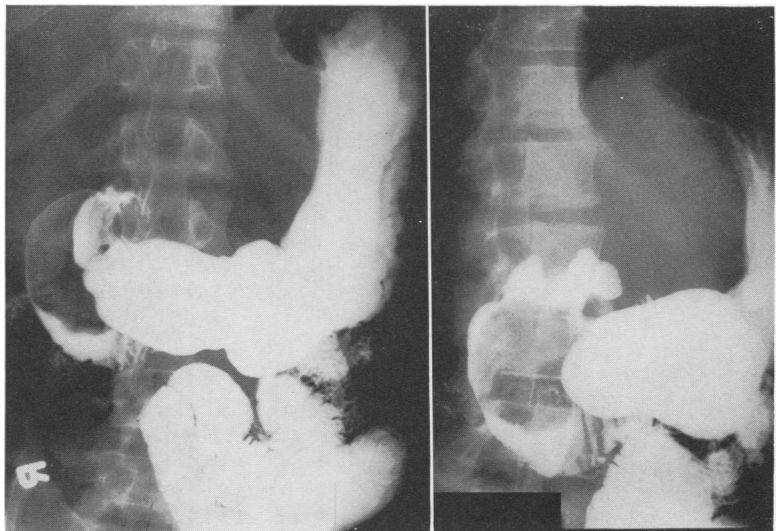


FIG. 4. Preoperative gastrointestinal x-ray shows large duodenal mass in patient with Brunner's gland adenoma (Case 2).



Comment Regarding Duodenal Reconstruction: Reconstruction of the duodenal defect required a generous incision in the

anterior wall of the stomach and across the pylorus to provide tissue for the reconstruction. The inferior edge of gastric wall

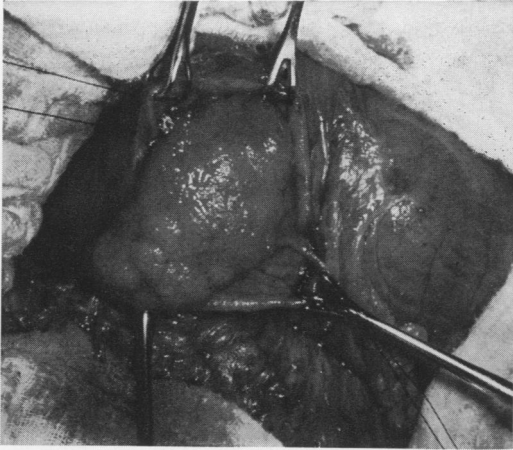


FIG. 5. Operative view of Brunner's gland adenoma after duodenotomy (Case 2).

was sutured to the anterior edge of the duodenal wall in two layers, using sero-muscular silk sutures and a running catgut suture on the mucosal surface. The superior edge of the gastric wall was sutured to the posterolateral wall of the duodenum defect in a similar fashion. By bringing point "B" to point "A" at the junction of the second and third portions of the duodenum (Fig. 8), the duodenal defect was covered with gastric wall, a technic similar to the Finney pyloroplasty.

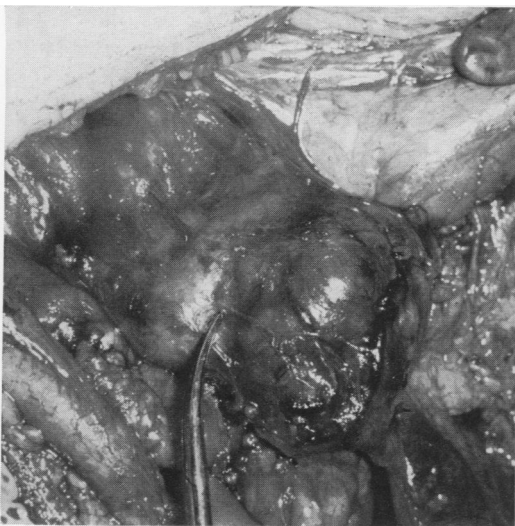

FIG. 6. Operative view showing large leiomyoma of duodenum (Case 3).

Although normal gastric emptying returned, gastrojejunostomy was necessary when gastric atony was prolonged (Fig. 9). Despite the theoretical possibility of stimulation of gastrin by alkaline secretions in the antrum, vagotomy was probably unwarranted.

Case 4. C. W. This patient had a neoplasm not primary in the duodenum but the anatomical defect produced by resection was similar to that in Case 3, and was corrected by the reconstruction described.

A 47-year-old man underwent right hemicolectomy for carcinoma of the proximal transverse colon in February 1966. The tumor was adherent to the anterior wall of the second portion of the duodenum, but it was dissected free without opening the duodenum. In January 1967, he was reoperated upon for a polyp in the remaining colon, but no residual cancer was found at this "second look" procedure. A few months later a metastatic mass in the quadratus lumborum muscle, with no other evidence of recurrence was resected with an envelope of normal tissues. Approximately 1 year later, vague gastrointestinal symptoms and roentgenologic findings of a deformity of the duodenum prompted operation.

Operation (3/18/68): An area of recurrent carcinoma involved the anterolateral wall of the second portion of the duodenum, but there was

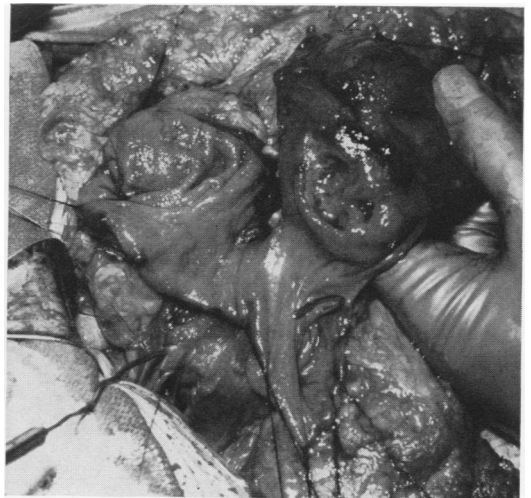


FIG. 7. Operative view showing dilator in common duct via choledochotomy, and partially resected duodenal leiomyoma (Case 3). Only a narrow strip of duodenal wall remains *in situ* in region of ampulla of Vater.

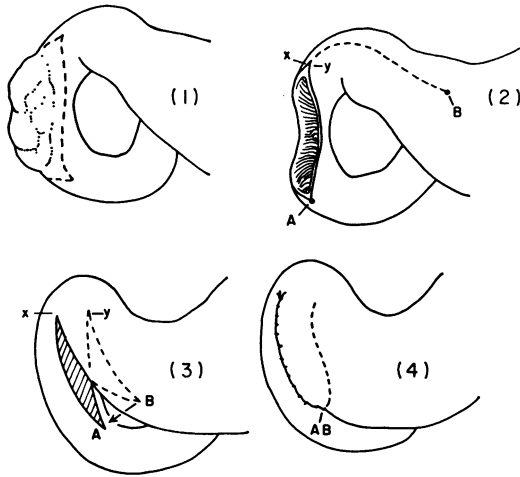


FIG. 8. Diagrammatic representation of operative reconstruction which was used in Cases 3 and 4.

no other evidence of recurrence. The second portion of the duodenum was resected along with the adherent gallbladder, leaving a large defect in the wall of the duodenum. Reconstruction was accomplished as in Case 3 (Fig. 8). Postoperative radiographic studies showed good function after this atypical reconstruction.

Pathology: The segment of duodenum was 6 cm. in length, and there was an ulcer on the mucosal surface which measured 1 cm. in diameter and 1.5 cm. in depth. The base and walls of the ulcer crater were grossly involved by firm tumor tissue which also appeared to invade the adherent wall of the gallbladder. Histologically the tumor was a well-differentiated carcinoma similar to that observed in the prior pathologic material. Invasion of the gallbladder was confirmed in addition to invasion of all layers of the duodenum itself.

Course: The patient recovered without complications, and intermittent postoperative courses of 5 fluorouracil were given. Chemotherapy was continued for 1 year and reoperation was performed in March 1969, three years after the original operation. At laparotomy there was no gross evidence of local recurrence or distant metastasis. Six months following this procedure a recurrent mass in the flank was excised from the site of resection done 2½ years before. There were no other areas of cancer, and the duodenal area was free of tumor. The patient is doing well 13 months after this procedure, and has returned to work.

Discussion

The largest series of benign tumors of the duodenum were reported by Hoffman and Grayzel³ and Botsford *et al.*¹ In the former, all 14 were *asymptomatic* lesions found at autopsy. Only one of 19 benign duodenal tumors in Botsford's series produced symptoms. Most *symptom-producing* benign duodenal tumors are Brunner's gland adenomas, and are isolated cases reported in the literature.

If tumors of the ampulla of Vater are eliminated, the most common symptoms of duodenal tumors are bleeding and obstruction. Peptic ulcer is a greater diagnostic possibility than duodenal tumor in such circumstances. Radiologic diagnosis is the only preoperative possibility.

In the 18 years from 1951-1969 there

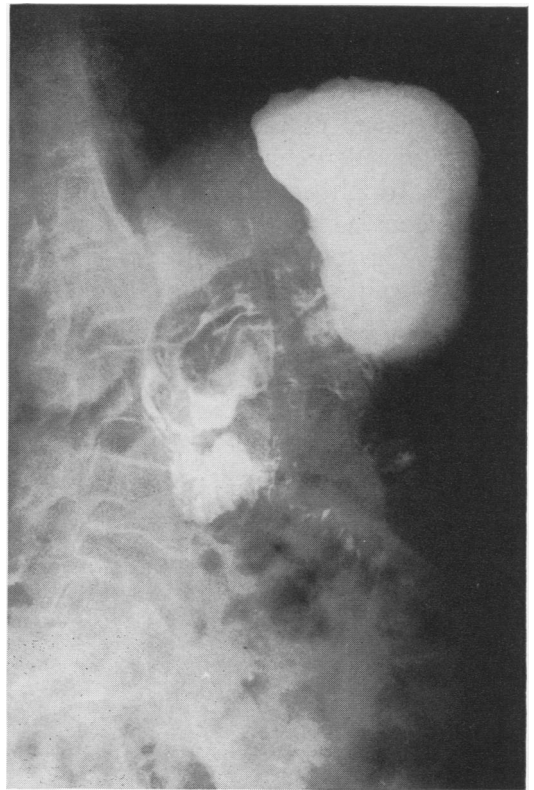

FIG. 9. Postoperative gastrointestinal x-ray after extensive resection of duodenal wall and reconstruction with method outlined (Case 3).

have been 18 primary duodenal tumors diagnosed in our surgical material (Table 1). Ten were benign, and eight were malignant with five primary carcinoids in this latter category. Two were primary carcinomas of the duodenum and one was a leiomyosarcoma. Benign lesions included one adenomatous polyp and the two large Brunner's gland adenomas here reported. In addition to the leiomyoma described, two additional lesions were found incidentally. There were three islet cell adenomas, two considered functional.

Of the 18 patients, five (and possibly six) had no symptoms that could be related to the duodenal lesions. Three of 10 benign lesions were asymptomatic, and were excised at operations performed for unrelated conditions.

Most benign tumors of the duodenum are either on a stalk or small enough to be resected by local excision. Occasionally, adequate excision requires major resection of the duodenal wall. Most resectable malignant tumors of the duodenum require pancreatoduodenectomy and removal of adjacent lymph nodes. Even with malignant tumors the risk of pancreatoduodenectomy may be too great, and local resection may be acceptable if the ampulla of Vater and its surrounding mucosa are free of tumor.

Although it has been suggested that large duodenal defects can be closed with the serosal surface of jejunum,^{5, 10} this procedure has drawbacks. A full thickness pedicled patch graft of jejunum might suffice, but this operation is more complex than the modified pyloroplasty described.

Summary

Four patients with unusual symptomatic duodenal tumors are presented in detail and various aspects of the diagnosis and surgical therapy discussed. A simple method of reconstruction after extensive duodenal resection is described as used in two of these patients.

References

1. Botsford, T. W., Crowe, P. and Crocker, D. W.: Tumors of the Small Intestine. *Amer. J. Surg.*, 103:358, 1962.
2. Golden, T. and Stout, A. P.: Smooth Muscle Tumors of the Gastrointestinal Tract and Retroperitoneal Tissues. *Surg. Gynec. Obstet.*, 73:784, 1941.
3. Hoffman, B. P. and Grayzel, D. M.: Benign Tumors of the Duodenum. *Amer. J. Surg.*, 70:394, 1945.
4. Kaplan, E. L., Dyson, W. L. and Fitts, W. T.: Hyperplasia of Brunner's Glands of the Duodenum (Collective Review). *Surg. Gynec. Obstet. (Int. Abstr. Surg.)*, 126:371, 1968.
5. Kobold, E. E. and Thal A. P.: A Simple Method for the Management of Experimental Wounds of the Duodenum. *Surg. Gynec. Obstet.*, 116:340, 1963.
6. Rankin, F. W. and Newell, C. E.: Benign Tumors of the Small Intestine (Report of Twenty-four Cases). *Surg. Gynec. Obstet.*, 57:501, 1933.
7. River, L., Silverstein, J. and Tope, J. W.: Benign Neoplasms of the Small Intestine, A Critical Comprehensive Review with Reports of 20 New Cases (Collective Review). *Surg. Gynec. Obstet. (Int. Abstr. Surg.)*, 102:1, 1956.
8. Silverman, L., Waugh, J. M., Huizenga, K. A. and Harrison, E. G.: Large Adenomatous Polyp of Brunner's Glands. *Amer. J. Clin. Path.*, 36:438, 1961.
9. Weichert, R., Reed, R. and Creech, O.: Carcinoid-Islet Cell Tumors of the Duodenum. *Ann. Surg.*, 165:660, 1967.
10. Wolfman, E. F., Trevino, G., Heaps, D. K. and Zuidema, G. D.: An Operative Technic for the Management of Acute and Chronic Lateral Duodenal Fistulas. *Ann. Surg.*, 159: 563, 1964.