

Clinical Experience with the Modified Bovine Arterial Heterograft

JOHN M. KESHISHIAN, M.D., NICHOLAS P. D. SMYTH, M.D.,
PAUL C. ADKINS, M.D., FRANK CAMP, LT. COL., MC, USAF,
WILLIAM Z. YAHR, MAJ., MC, USAF

From The George Washington University Medical Center, The Washington Hospital Center, The Malcolm Grow USAF Hospital, Washington, D. C.

THIS REPORT represents our experience with 81 modified bovine arterial heterografts * which have been implanted in 67 patients.

Since the pioneer work begun by Carrel,³ the search for an ideal arterial replacement continues. The criteria⁴ for such a graft were promulgated by the Committee for the Study of Vascular Prostheses of the Society for Vascular Surgery in 1960. In essence, this graft should be readily available, non-antigenic, easily handled and be a satisfactory conduit for blood.

Many materials to be used as grafts were tested and abandoned. The gradual development of synthetic plastic arterial prostheses was regarded with cautious optimism. Of all, the crimped knitted Dacron graft is considered to be the most satisfactory when used in the aorta and iliac arteries.¹² Its use in the lower extremities, however, has not been satisfactory due to a high failure rate. Szilagyi³⁸ reported late thrombosis in 40% of his patients with use of Helanca weave plastic tubes. Edwards⁹ reported 50-75% failure rates in the first

3 years in his series. Graft failure in each series was probably due to the gradual compliance loss of the graft by encasement in scar tissue. When crossing a flexion crease, these rigid tubes become kinked with flexion of the joint with resultant thrombosis. Discouraged by these reports, interest was renewed in the use of autogenous saphenous vein^{6, 18, 21} as an arterial replacement. When used as a bypass graft, patch graft or combination patch-bypass in conjunction with endarterectomy,¹⁹ it has proved to be a very satisfactory substitute artery.

The saphenous vein is generally regarded as the best replacement tissue for femoropopliteal artery revascularization.⁵ There are several drawbacks associated with use of this vein, however:

1. It may have been surgically removed;
2. It may be present, but unusable due to:
 - a. Multibranching;
 - b. Varicosities;
 - c. Inadequate size.²¹

The latter finding is an unfortunate corollary of the disease since the chronically ischemic leg may have a small shrunken vein unsuitable for use where it is most needed. If this vein measures less than 5 mm. in diameter when used as a graft, it is likely to fail.

Removing and preparing an adequate length of vein adds considerably to the

Supported in part by The Potomac Fund for Cardiovascular Research.

Presented at the American Surgical Association meeting held at White Sulphur Springs, West Virginia, April 27-29, 1970.

* The Arterial Grafts (Bovine origin) were supplied through the generosity of John Henderson, M.D., Corporate Director of Medical Affairs, Johnson & Johnson, New Brunswick, New Jersey.

operative time and may increase the post-operative morbidity.

Unmodified arterial homografts and heterografts have been discarded because of difficulties in procurement and unpredictable host-graft interaction.³⁹

Impressed by the reports of Rosenberg,^{23, 27, 29, 36} and associates on the development of a chemically modified non-antigenic bovine heterograft, we as well as others,^{7, 24, 37} used them cautiously in selected instances when the saphenous vein was not available. We soon broadened our indications, however, to parallel those for implantation of a saphenous vein based on early satisfactory experiences.

Materials

These grafts are prepared from fresh beef carotid arteries in the following manner.^{15, 31} All extraneous tissue is removed, all tributaries are ligated and the arteries are thoroughly washed. They are then bathed in a solution of ficin (a proteolytic enzyme derived from the wild fig) containing a trace of L-cystein, the enzyme activator, buffered to pH 5.5. After digestion for 2½ hours at 37° C., the enzymatic activity is terminated by deactivating the protease with a 1% aqueous solution of sodium chlorite. The graft is slipped over a glass rod, then tanned in a 1.3% dialdehyde starch solution buffered to pH 8.8. After tanning is completed, the graft is tested for air leaks using air pressure equivalents to 150 mg. Hg. On the completion of processing, the graft is stored in a glass tube in a 40% ethanol solution containing 1% propylene oxide.

After the enzyme/tanning process,³⁸ the resulting graft becomes a non-viable collagen tube, the muscularis and elastica of which have been removed rendering it non-antigenic to the host.⁸ Fixation by the aldehyde-starch solution alters the cross linkages of the collagen molecules making them more stable, resulting in a stronger

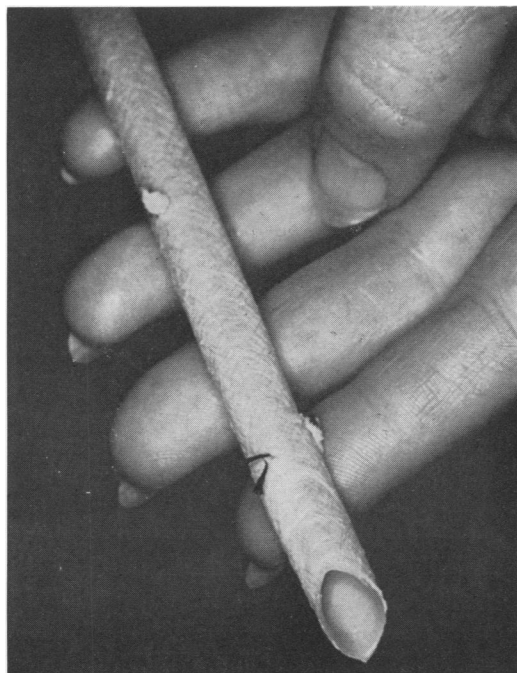

FIG. 1. Bovine heterograft. Shaggy crisscross adventitial fibers can be seen. Bevel will be recut prior to suturing.

graft, the tensile strength of which is comparable to the untreated heterograft.¹ Krafka^{16, 17} has shown that the collagen portion of arteries is several hundred times more resistant to pressure and stress than the muscularis portion. Studies of the electrical nature of the inner wall of this tube reveal a Zeta potential which is negative²⁴; this has been shown to be unfavorable to thrombus formation.^{15, 31} These features clearly indicate that this treated bovine carotid artery might prove to be a satisfactory biological arterial graft.

Since adequate reproduceable animal experimentation had been carried out by Rosenberg *et al.*,^{14, 26, 28, 30, 31, 32, 34, 35, 39} and Dale,⁷ and independent laboratory studies⁸ showed this graft to have outstanding credentials, it seemed to us that extensive clinical trial was warranted. It is to the credit of Rosenberg and associates³² that their persistent research into the mysteries of leather chemistry finally produced

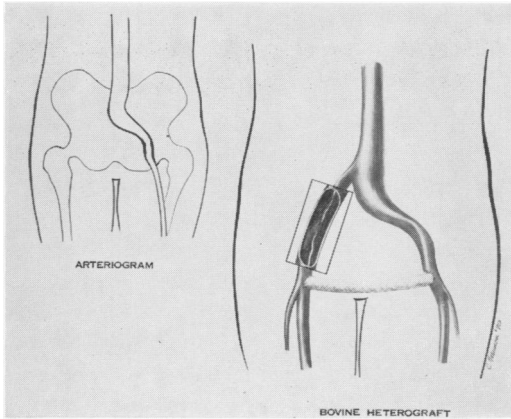


FIG. 2a. (Case 1) Artist's sketch showing preoperative arteriogram and cross leg femoral graft.

this graft after some early failures in animal studies. This graft was produced, despite the fact, that the reaction to bovine heterograft implantation in dogs is completely different from man both in response and healing.¹⁰

Selection of Patients

All patients in whom some form of arterial reconstruction was indicated were considered potential candidates for bovine heterografts. In almost all instances, preliminary studies included arteriography to document the site of lesion, its extent, and

the condition of the artery, but most importantly, the degree of runoff. If runoff was not visualized, the artery was explored initially at the time of operation to determine whether distal runoff capable of accepting the graft existed.

Technic

Grafts (Fig. 1) are removed from the glass container and soaked in a basin containing 500 cc. normal saline solution containing approximately 50 mg. heparin for 10 minutes before use. The lumen is irrigated several times so as to remove as much of the preservative as is physically possible. The appropriate length of the graft is used; the remainder is replaced on the glass rod and may be used for another case. When it is necessary to join two or even three sections together, the anastomoses are made with 4-0 or 5-0 Ethiflex, Tycron or Tevdek sutures over the glass rod. We have had no instance of aneurysm formation or thrombosis at the suture lines as a result of this maneuver. When used as a femoro-popliteal bypass, it is recommended that the graft be tunneled beneath the fascia using a tunnelling device. This permits correct placement of the graft and prevents snagging or kinking which

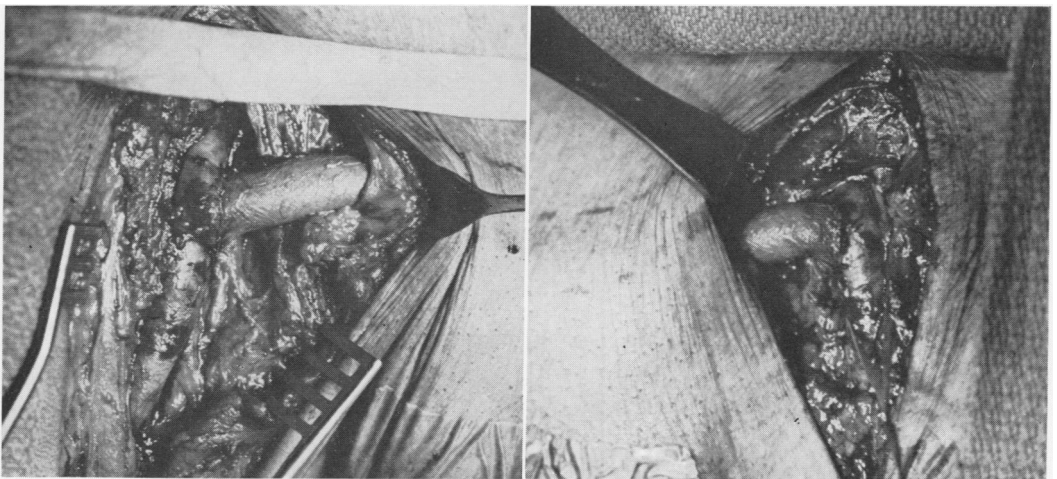


FIG. 2b. Photographs taken at conclusion of bypass. Graft anastomosed end-to-side to common femoral artery and passed subcutaneously.

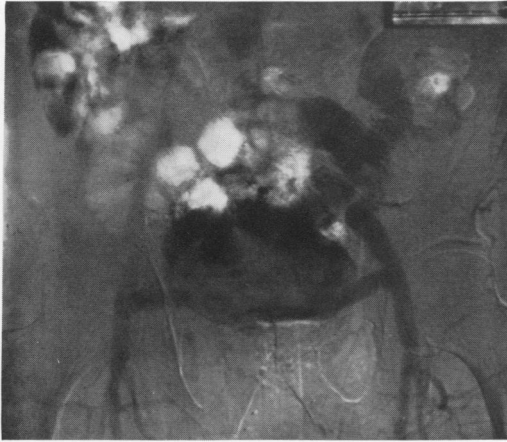

FIG. 2c. Postoperative subtraction study of arteriogram showing filling of right side from left side via graft.

may otherwise be encountered owing to the drag of the shaggy adventitia. We prefer end-to-side anastomoses with the stoma trimmed so that the graft will flare out with arterial pressure. When properly anastomosed and implanted, the graft should lie flat in its tunnel with no evidence of puckering or kinking at the anastomotic sites. Ethiflex, Tevdek or Tycron sutures of 4-0 or 5-0 are used and recommended for the anastomoses between graft and host artery.

Clinical Material and Results

In all, 81 bovine grafts were implanted either as a tube or a patch graft in 67 patients. There were 14 graft failures for an overall success rate of 83%. Table 1 reflects a breakdown of the total experience.

The largest group of grafts in this series were the femoro-popliteal bypasses which totalled 47 (Table 2). There were 11 failures, two early and nine late. There were four deaths, one occurred on the third postoperative day from a massive myocardial infarction, one occurred 23 days postoperative of acute renal failure and two died of myocardial infarctions at 7 months and 10 months. Of the failures, four required am-

putations. The causes for failure were not always clear. One early failure was due to a technical deficiency. Of the late failures, loss of runoff was demonstrated in five patients when re-explored. Of these 47 bypass grafts, a total of 27 were combined; that is, two segments were combined to provide the needed length. There were two failures in the combined graft group. In one instance, three grafts were joined to perform axillary-popliteal bypass. There were four composite grafts either as a result of salvage procedures or deliberate anastomosis of heterograft to Dacron prostheses.

TABLE 1.

	No. of Grafts	Current Status
(1) Aorto-renal	1	patent
(2) Iliac femoral	3	3 patent
(3) Femoro-popliteal	47	36 patent
(4) Femoro-posterior tibial	2	2 patent
(5) Cross femoral	6	4 patent 2 deaths*
(6) Patch grafts	7	5 patent
(7) Carotid-subclavian	3	3 patent
(8) Axillary-popliteal	3	patient died*
(9) Aorto-iliac	1	patent
(10) Aorto-femoral	5	4 patent
(11) Subclavian-brachial	2	2 patent
(12) Femoral artery replacement	1	patent
(13) Composite grafts	(4)	4 patent
(04) Combined grafts	(27)	22 patent
	81	63 patent 14 failures 4 deaths*

* All deaths were from unrelated causes.

TABLE 2. Femoro-popliteal Bypass Grafts

Total patients	32
Total grafts	47
Failures	11
Early failures	2
Late failures	9
Amputations	4
Deaths (unrelated causes)	4
Longest follow-up	22 months

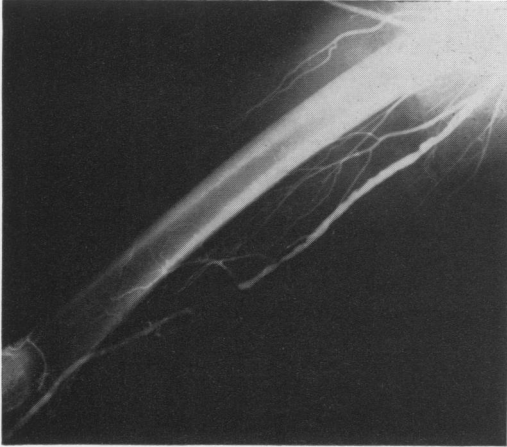


FIG. 3a. (Case 2) Preoperative arteriogram in 1968.

Examples of some of these graft applications are seen in the accompanying case reports. They are being reported in detail elsewhere.

Case Reports

Case 1. V. P., a 71-year-old male Jehovah's Witness had severe claudication in his right leg and was unable to walk without assistance. Several intra-abdominal procedures had been performed in the past and he was presently anemic. Since transfusion was proscribed, revascularization was carried out by cross leg femoro-femoral graft with excellent results (Fig. 2).

Case 2. P. C., a 74-year-old man with sudden acute leg ischemia required two revisions of a Dacron femoro-popliteal graft. Thirty-three years earlier he had had bilateral saphenous vein ligation. A composite graft was constructed using a bovine graft extension of the Dacron graft, anastomosed end-to-side to the posterior tibial artery (Fig. 3). This graft has functioned satisfactorily for 22 months despite diseased distal vessels.

Case 3. M. S., a 59-year-old post-menopausal woman required bilateral femoro-popliteal bypass grafts. The saphenous vein was used on the left and a bovine arterial heterograft on the right since the right saphenous vein was too small. Only two incisions were needed for the bovine graft emplacement as opposed to four on the left. There was rapid healing on the right; delayed on the left, due to fat necrosis and persistent drainage. Both grafts function well.

Case 4. R. B., a 53-year-old man had progressive disabling claudication in the right leg. Arteriograms demonstrated total occlusion of the superficial femoral artery with adequate runoff. A long bovine femoro-popliteal bypass was implanted with full return of pulses. Postoperative arteriograms showed excellent position and function of this graft (Fig. 5).

Case 5. B. O., a 55-year-old woman developed incapacitating bilateral upper arm claudication in 1968, which was worse in the right arm. Brachial and radial pulses were absent, the right thumb developed an indolent ulcer. Arteriograms showed severe narrowing and segmental occlusion in both axillary and brachial arteries. Bilateral sympathectomies were performed, followed by bilateral subclavian-brachial bypass grafts using bovine grafts. All pulses returned immediately with remission of symptoms and rapid healing of the ulcer. Follow-up arteriograms showed good filling of the distal arteries (Fig. 6). The patient is asymptomatic 1½ years postoperatively.

Case 6. G. T., a 55-year-old man had recurrent intermittent claudication on the left side. Eight years earlier a Helanca plastic prosthesis had been implanted for occlusive disease of the aortic bifurcation. Subsequently one limb oc-

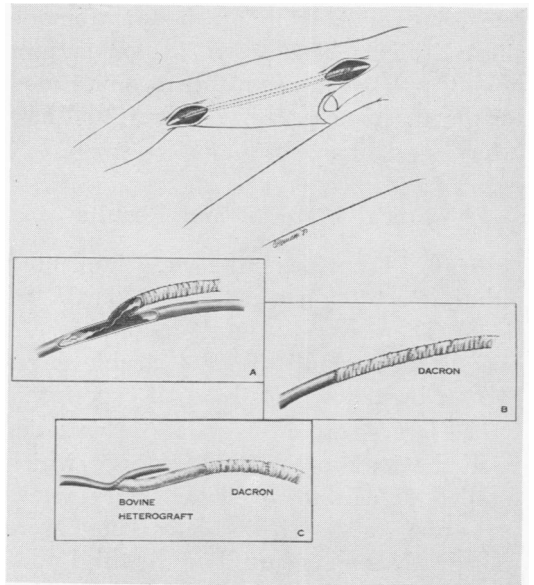
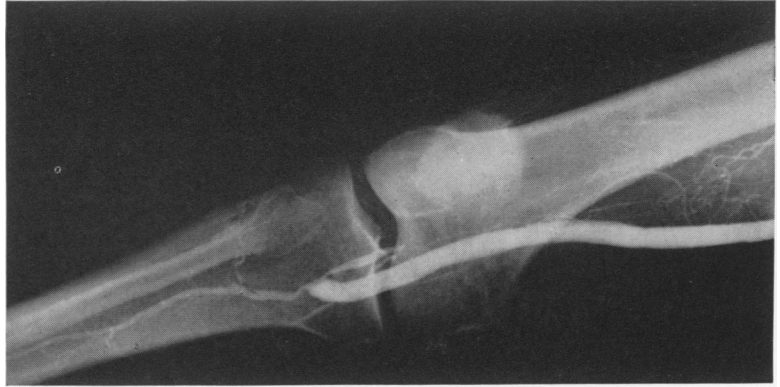

FIG. 3b. Sketch depicting operative procedures: a) Initial occluded Dacron bypass graft. b) Resection of clotted area and small Dacron segment inserted end-to-end above and below. c) Extension to posterior tibial using bovine graft. Graft remains patent despite extensive vascular disease.

FIG. 3c. Current arteriogram. Extensive disease allows only one vessel runoff.



cluded and was bypassed with a straight plastic graft. The patient had a known horseshoe kidney. Arteriograms showed diminished flow in the left limb. At exploration, the left limb was replaced with a segment of bovine heterograft with relief of claudication and full return of pulses (Fig. 7).

Case 7. A. C., a 38-year-old man had a progressively enlarging soft tissue tumor. At exploration, the tumor had compromised the superficial femoral artery at its midpoint as well as the nerve and vein. The tumor and the entire medial compartment were resected. Arterial continuity was restored by a bovine heterograft. A postoperative arteriogram showed good function (Fig. 8).

Discussion

As is often the case with surgical innovations, the earliest attempts are not always performed on ideal candidates or under optimal characteristics. Some of the early patients were "distress" cases, and the results were not predictable since none of the early investigators knew how the bovine grafts would behave. This is faintly reminiscent of the arterial homograft era with some notable exceptions. The homograft was the true biological prosthesis of its time, biologically inert and electrically negative; easily stored and easily handled. However, it was tediously obtained and difficult to process. The most serious drawback was its proclivity for late failure, although we have followed one patient with a functioning bifurcation homograft inserted in 1958. Meade has reported 74%

failure in 5 years with homograft replacement of femoral arteries due to aneurysm formation and rupture or caused by stenosis.²² These aneurysms developed at the suture lines which joined graft segments.¹³ This same phenomenon has been seen by others in a few instances with bovine heterografts.²⁵ For a while it was seriously considered to discontinue the practice of joining segments end-to-end or as an alternative, to girdle the anastomosis with a piece of Teflon mesh. Since this type of aneurysm is a false aneurysm caused by deficient suturing, we strove to make every anastomosis as technically sound as possible. We have continued to join segments when necessary. No aneurysms have occurred in our series. In one particularly difficult femoro-popliteal bypass, we were plagued by small leaks from needle holes at the juncture of the two bovine grafts. This was quickly controlled by girdling the anastomosis with a small cuff of heterograft slit lengthwise, then applied and sutured adventitia to adventitia. The shaggy coats coalesced quickly to seal the leaks.

Since most peripheral vascular surgical procedures are performed for leg ischemia, the greatest need is for long, wide bore arterial substitutes. It has been shown that cloth prostheses are generally unreliable after 2 years. Thromboendarterectomy may be successful initially in certain local lesions (carotid bifurcation), but extended

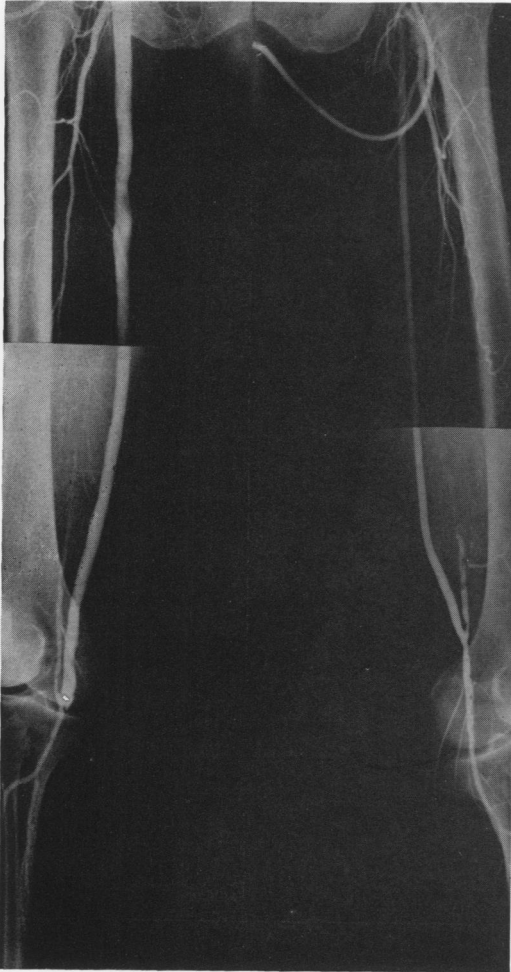

FIG. 4. (Case 3) Postoperative arteriograms. Left side is saphenous vein bypass functioning satisfactorily. Right leg has been revascularized using two bovine heterografts combined. Excellent run-off despite extensive disease.

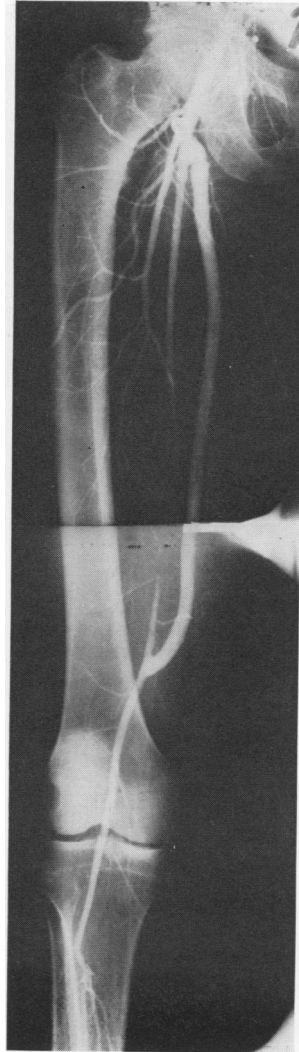

FIG. 5. (Case 4) Postoperative arteriogram of single bovine heterograft bypassing complete central occlusion of superficial femoral artery 2 months postoperative.

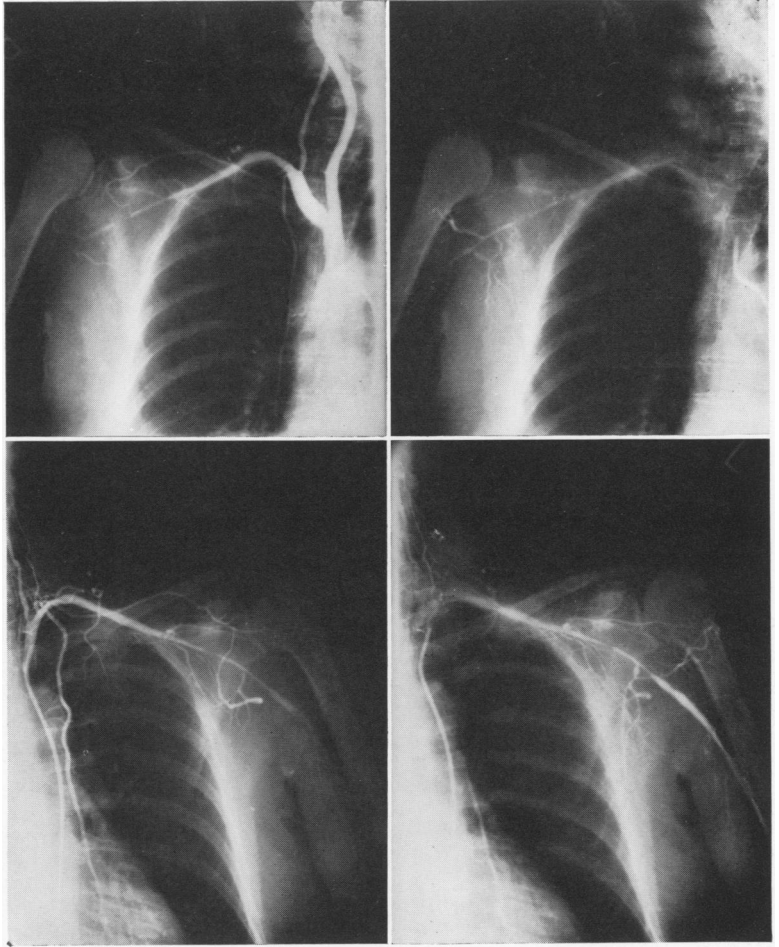
endarterectomy has led to gradual narrowing of that segment with closure in 50% of the patients in 2 years. When endarterectomy has been combined with long venous patch graft,¹¹ the failure rate decreases to 25%. Others^{2, 9} have had better results with endarterectomy.

Under ideal conditions the saphenous vein is probably the best material to use as an arterial substitute. However, as indicated earlier, there are certain drawbacks to its use.

In our experience with the bovine graft, we were gratified by the decreased operating time, the fewer number of incisions required and rapid healing of the incisions. There were no instances of infection in the skin or graft and no fat necrosis.

We have not hesitated to cross the flexion creases since the bovine graft maintains its flexibility. In one patient, this was demonstrated to a remarkable degree in both arms, in which the grafts have functioned perfectly through a full range of

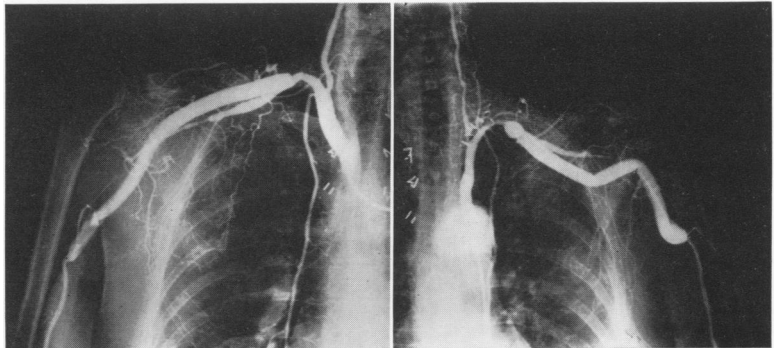
FIG. 6. (Case 5) a, b) top; and c, d) bottom. Preoperative arteriograms showing extensive disease bilaterally and very small brachial arteries.



arm motion for 1½ years. Because of its availability in all lengths, we have not had to compromise by combining endarterectomy or other methods to assure adequate length of patent vessel. Any suitable un-

involved portion of host artery is used, above and below, for the anastomosis site. The bovine graft segment is trimmed to size or augmented, as the situation demands.

FIG. 6e) right; and f) left. Postoperative arteriograms after staged upper thoracic sympathectomy and bilateral bypass grafts. These grafts measured 9.5 and 9 mm., respectively. Note that patency is maintained even on extensive adduction of upper arm with flexing of the graft. This is one of the gratifying features of these grafts.



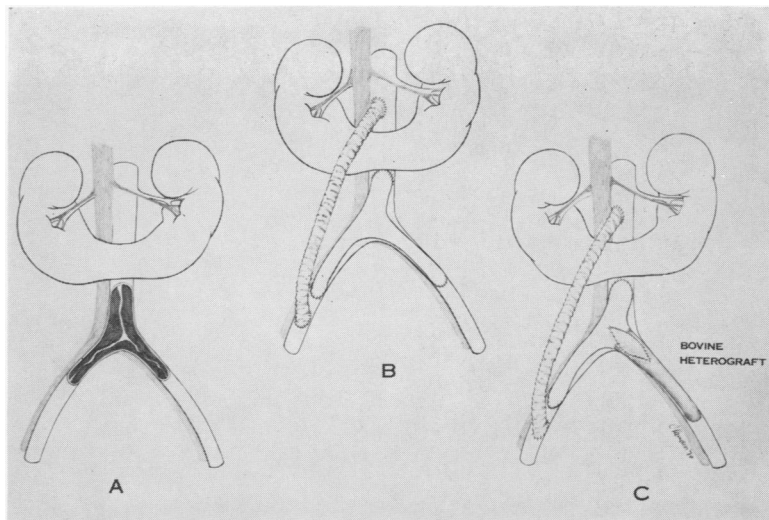


FIG. 7. (Case 6) Artist's sketch demonstrating horseshoe kidney, previous Helanca aortic graft, right limb bypass with straight Dacron tube graft and left limb of Helanca graft replaced by short bovine segment using patch graft at upper end to widen the anastomosis.

Those experienced with the use of vascular grafts will be pleased with its handling properties. We urge the use of plastic sutures. Occasionally it may be necessary to use vaselined sutures to prevent "drag" through the coarse adventitial fibers. Need-

dles should be smooth rather than cutting edged to minimize needle hole leaks in the graft, and tension on the suture should not be excessive. Either interrupted or running whipstitches are satisfactory. Rather than an acute 45% bevel at the anastomosis

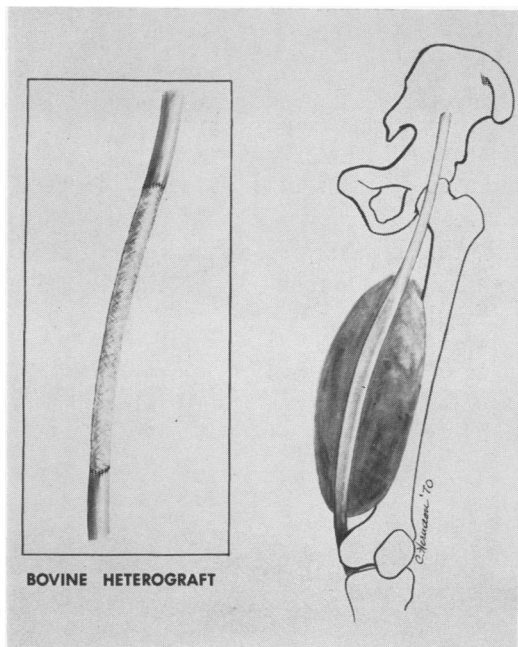


FIG. 8a. (Case 7) Artist's sketch shows location of neurofibrosarcoma involving medial compartment.

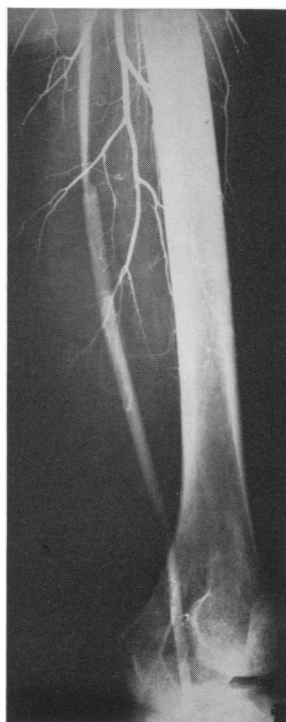

FIG. 8b. Postoperative arteriogram shows streaming at upper anastomosis, but excellent runoff through the graft.

when performing bypass, we prefer a curved bevel with a small extension of the stoma back into the graft. This maneuver prevents kinking or buckling and allows the graft to lie flat with proper ballooning at the anastomosis assuring unimpeded blood flow.

Our overall results show a failure rate of 17.5% for all procedures performed over a 3-year period. The failure rate for femoro-popliteal bypass procedures is 23%. These values are for all patients in the series, including the earliest instances. Our more recent experience will probably yield better results.

Buttressed by these figures as well as the 7-year follow-up studies by Rosenberg,³² we feel justified in continuing to use bovine heterografts as arterial substitutes.

Summary and Conclusions

Sixty-six patients have been operated upon for arterial disease and 81 bovine heterografts have been implanted with an overall success rate of 83%. The rate of success for femoro-popliteal bypasses is 77%.

The longest follow-up period has been 22 months documented by oscillometry and arteriograms.

This graft material is biologically acceptable in human tissue and functions satisfactorily as an arterial conduit or as a patch graft. It has an acceptable success/failure rate when compared with existing materials and has the added feature of reducing operating time and complications. The graft is readily available in large sizes and is easy to use.

It is concluded that this graft is both safe and satisfactory for use in all arterioplastic operations in man.

Addendum

Since this report was submitted, the number of grafts implanted now stands at 109. Seventy-seven remain patent with 26

failures and 6 deaths. This is a gross overall figure. Of these, there were 48 femoro-popliteal bypass procedures utilizing 64 grafts with 14 failures. The longest follow-up in this series is now 27 months. A more complete report is in preparation.

References

1. Bothwell, J. W., Lord, G. H., Rosenberg, N., Burrowes, C. B., Wesolowski, S. A. and Sawyer, P. M.: Modified Arterial Heterografts: Relationship of Processing Techniques to Interface Characteristics, Bio-Physical Mechanisms in Vascular Homeostasis and Intravascular Thrombosis, edited by Philip N. Sawyer, M.D. (Appleton-Century-Crofts, New York, 1965).
2. Caldwell, R. L., DeWeese, J. A. and Rob, C. G.: Femoral Popliteal Bypass Graft Utilizing Saphenous Vein. *Circulation*, 37-38:37, 1962.
3. Carrel, A.: Heterotransplantation of Blood Vessels Preserved in Cold Storage. *J. Exp. Med.*, 9:226, 1907.
4. Creech, O., Jr., Deterling, R. A., Jr., Edwards, S., Julian, O. C., Linton, R. R. and Schumaker, H., Jr.: Vascular Prostheses: Report of Committee for Study of Vascular Prostheses of the Society for Vascular Surgery. *Surgery*, 41:62, 1957.
5. Dale, W. A.: Autogenous Vein Grafts for Femoro-popliteal Arterial Repair. *Surg. Gynec. Obstet.*, 123:1282, 1966.
6. Dale, W. A., DeWeese, J. A. and Scott, W. J. M.: Autogenous Venous Shunt Grafts. *Surgery*, 46:145, 1959.
7. Dale, W. A. and Lewis, M. R.: Modified Bovine Heterografts for Arterial Replacement. *Ann. Surg.*, 169:927, 1969.
8. DeFalco, R. J.: Immunologic Studies of Untreated and Chemically Modified Bovine Carotid Arteries. *J. Surg. Res.*, 10:95, 1970.
9. Edwards, W. S.: Late Occlusion of Femoral and Popliteal Fabric Arterial Grafts. *Surg. Gynec. Obstet.*, 110:714, 1960.
10. Edwards, W. S., Dalton, D. and Quattlebaum, R.: Anastomoses Between Synthetic Graft and Artery: A Study of Tensile Strength. *Arch. Surg.*, 86:477, 1963.
11. Edwards, W. S., Holdfelder, W. F. and Moh-tashemi, M.: Importance of Proper Caliber of Lumen in Femoro-popliteal Artery Reconstruction. *Surg. Gynec. Obstet.*, 127:37, 1966.
12. Edwards, W. S. and Tapp, J. S.: Peripheral Artery Replacement with Chemically Treated Nylon Tubes. *Surg. Gynec. Obstet.*, 102:443, 1956.
13. Gwathmey, O.: Personal communication.
14. Henderson, J., Rosenberg, N., Gaughran, E. R. L., Lord, G. H. and Douglas, J. F.: Factors Involved in Success or Failure of Arterial Grafts. *AMA Arch. Surg.*, 77:958, 1958.
15. Johnson & Johnson Investigational Brochure: Bovine Heterografts.

16. Krafka, J.: Changes in Elasticity of Aorta with Age. *Arch. Path.*, 29:303, 1940.
17. Krafka, J.: Comparative Study of Hystophysics of Aorta. *Am. J. Physiol.*, 125:1, 1939.
18. Kunlin, J.: Le Traitement de l'ischemic Arteritique par la Greffe Veneuse Longue. *Rev. Chir.*, 70:206, 1951.
19. Linton, R. R. and Darling, R. C.: Autogenous Saphenous Vein Bypass Grafts in Femoropopliteal Obliterative Arterial Disease. *Surgery*, 51:62, 1962.
20. Linton, R. R. and Wilde, W. L.: Modifications in the Technique for Femoro-popliteal Saphenous Vein Bypass Autografts. *Surgery*, 67:234, 1970.
21. Lord, J. W., Jr., and Stone, P. W.: The Use of Autogenous Venous System Grafts in the Peripheral Arterial System. *AMA Arch. Surg.*, 74:71, 1957.
22. Meade, J. W., Linton, R. R., Darling, R. C. and Menendez, C. V.: Long-term Clinical Follow-up of Arterial Homografts. *Aruch. Surg.*, 93:392, 1966.
23. Rosenberg, N.: Arterial Heterografts and Their Modifications, Chapter 15, *Fundamentals of Vascular Grafting*, edited by Wesolowski, S. A. and Dennis, C., McGraw-Hill, pp. 233-251, 1963.
24. Rosenberg, D.: Discussion of paper by Dale, W. A. and Lewis, M. *Surgery*, 169:927, 1969.
25. Rosenberg, D.: Personal communication.
26. Rosenberg, N., Gaughran, E. R. L., Henderson, J., Lord, G. H. and Douglas, J. F.: The Use of Segmental Arterial Implants Prepared by Enzymatic Modification of Heterologous Blood Vessels. *Surg. Forum*, VI: 242, 1956.
27. Rosenberg, N., Henderson, J., Lord, G. H. and Bothwell, J. W.: "An Arterial Prosthesis of Heterologous Vascular Origin." *JAMA*, 187: 741, 1964.
28. Rosenberg, N., Henderson, J., Lord, G. H., Bothwell, J. W. and Gaughran, E. R. L.: Biological Arterial Prosthesis of Heterologous Vascular Origin, A Progress Report. *Bul. Soc. Int. Chir.*, XXI (1): 13, 1962.
29. Rosenberg, N., Henderson, J., Lord, G. H., Bothwell, J. W. and Gaughran, E. R. L.: The Use of Enzyme-Treated Heterografts as Segmental Arterial Substitutes (Follow-up Observations on Five-Year-Old Implants). *AMA Arch. Surg.*, 83:950, 1961.
30. Rosenberg, N., Henderson, J., Lord, G. H., Bothwell, J. W. and Gaughran, E. R. L.: The Use of Enzyme-Treated Heterografts as Segmental Arterial Substitutes (Follow-up Observations on Five-Year-Old Implants). *AMA Arch. Surg.*, 83:950, 1961.
31. Rosenberg, N., Henderson, J., Douglas, J. F., Lord, G. H. and Gaughran, E. R. L.: The Use of Arterial Implants Prepared by Enzymatic Modification of Arterial Heterografts (The Physical Properties of the Elastica and Collagen Components of the Arterial Wall). *AMA Arch. Surg.*, 74:89, 1957.
32. Rosenberg, N., Lord, G. H., Henderson, J., Bothwell, J. W. and Gaughran, E. R. L.: Collagen Arterial Graft of Bovine Origin. Seven Year Observations in the Dog. *Surg.*, in press.
33. Rosenberg, N., Henderson, J., Lord, G. H. and Bothwell, J. W.: Collagen Arterial Prosthesis of Heterologous Vascular Origin: Physical Properties and Behavior as an Arterial Graft. *Electrochemistry & Surface Physics*, pp. 314.
34. Rosenberg, N., Henderson, J., Lord, G. H., Gaughran, E. R. L. and Douglas, J. R.: Use of Enzyme-Digested Heterografts as Segmental Arterial Substitutes (Follow-up Observations on Two-Year-Old Aortic Implants). *AMA Arch. Surg.*, 76:275, 1958.
35. Rosenberg, N., Henderson, J., Lord, G. H., Bothwell, J. W. and Gaughran, E. R. L.: Use of Enzyme-Treated Heterografts as Segmental Arterial Substitutes (Influence of Processing Factors on Strength and Invasion by Host). *AMA Arch. Surg.*, 85:192, 1962.
36. Rosenberg, N., Martinez, A., Sawyer, P. N., Wesolowski, S. A., Postlethwait, R. W. and Dillon, M. L.: Preliminary Studies in Man of a Collagen Arterial Prosthesis of Bovine Carotid Artery. *Ann. Surg.*, 164:247, 1966.
37. Rosenberg, N., Martinez, A., Sawyer, P. M., Wesolowski, S. A., Postlethwait, R. W. and Dillon, M. L.: Tanned Collagen Arterial Prosthesis of Bovine Carotid Origin in Man: Preliminary Studies of Enzyme-Treated Heterografts. *Ann. Surg.*, 164:247, 1966.
38. Szilagyi, D. E.: Quoted by W. S. Edwards *in* Late Occlusion of Femoral and Popliteal Fabric Arterial Grafts. *Surg. Gynec. Obstet.*, 110:714, 1960.
39. Szilagyi, D. E., Shonnard, C. P., Lopez, J. and Smyth, N. P. D.: The Replacement of Long and Narrow Arterial Grafts. *Surgery*, 40:1042, 1956.

DISCUSSION

DR. PAUL NEMIR, JR. (Philadelphia): I should like to congratulate the authors for bringing to our attention this very satisfactory alternative method for an arterial conduit in those instances where a vein is unavailable.

We were rather discouraged in using the bovine heterograft after studies in animals carried out a few years ago. [Slide] We implanted segments, somewhat similarly prepared to those reported and stored in varying concentrations of plasma for 4 to 6 weeks, into the thoracic and