

# An Operative Technic for the Management of Acute and Chronic Lateral Duodenal Fistulas \*

EARL F. WOLFMAN, JR., M.D., GUILLERMO TREVINO, M.D.,  
DAVID K. HEAPS, M.D., GEORGE D. ZUIDEMA, M.D.

*From the Department of Surgery, The University of Michigan Medical School,  
Ann Arbor, Michigan*

DEFINITIVE surgical management of major acute injuries to the second and third portions of the duodenum has been enigmatic. Furthermore, should the patient survive the initial injury, and a chronic duodenal fistula develop, the morbidity and mortality rates from surgical intervention have been high.<sup>1-3, 4, 9, 11, 13, 15, 19, 20, 22, 24, 27</sup> The experience of most observers indicates that lateral duodenal fistulas demonstrate little tendency to heal spontaneously.<sup>5, 26</sup> While distal obstruction is often cited as a cause for the development and persistence of fistulas in other viscera, this seldom contributes to the chronicity of lateral duodenal fistulas. Probable factors responsible for their chronicity are: 1) increased intraduodenal pressure during peristalsis;<sup>6, 14</sup> and 2) the propensity of the duodenal mucosa to extrude, once a defect has been made, completely through the bowel wall, and to grow outside of the bowel lumen. It has been noted that fistulas occurring due to a dehiscence of a duodenal stump,<sup>7, 12, 26</sup> or those occurring following an end or lateral catheter duodenostomy usually close spontaneously.<sup>16</sup> The likely reason is that in these latter instances the mucosa is prevented from extruding either by the sutures used to hold the catheter in place, or by the chronic inflammatory reaction about the site of an end duodenal fistula.

The present experiments were undertaken to determine whether the duodenal

mucosa would extrude and spread over a contiguous surface once a defect was made through the muscularis propria of the bowel wall. We postulated that if such spread did occur, perhaps the mucosa would cover a *serosal patch* abutted against a defect in the duodenum and result in the restoration of duodenal continuity. Such an operation for duodenal fistulas and injuries would have the obvious advantages of technical simplicity and broader application than previously recommended procedures such as primary closure, sleeve excision with end-to-end anastomosis, subtotal gastric resection, and pancreaticoduodenectomy. In the present study, the use of a serosal patch was investigated in covering acute and chronic lateral duodenal openings and gastric defects. The purpose of this latter investigation was to determine whether or not acid chyme in contact with the serosa of the bowel might lead to digestion. Finally, as an alternative procedure, for use in instances where large areas of the duodenal wall are destroyed or excised, a Roux-Y duodenojejunostomy to the side of a lateral duodenal defect was studied to determine if peptic digestion of the Roux limb might occur from acid chyme passing over it.

## Method

Twenty-two healthy mongrel dogs weighing between 15 and 17 Kg. were anesthetized intravenously with thiopental (25 mg./Kg.). The abdomen was scrubbed

\* Submitted for publication May 22, 1963.

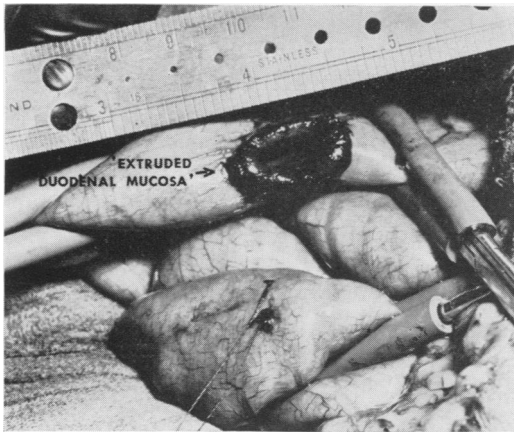


FIG. 1. Excisional defect in duodenum of dog. Note tendency of duodenal mucosa to extrude out onto the serosal surface.

with pHisoHex®, sprayed with Betadine®, and sterile drapes applied. A midline celiotomy incision was then made and the duodenum exposed.

In 12 of these animals (Group I) an acute duodenal fistula was created and covered with a serosal patch in the following manner: The duodenum was exposed and a defect  $2.0 \times 3.0$  cm. created by excising the complete thickness of the lateral wall 7.5 cm. from the pylorus. This position was approximately opposite the level of the pancreatic duct. The duodenal mucosa was allowed to extrude (Fig. 1) and the defect was then closed by anastomosing an intact segment of jejunum six inches from the ligament of Treitz about the opening with a two layer anastomosis of an outer row of interrupted 4-0 silk and an inner layer of continuous 3-0 chromic catgut (Fig. 2, 3). Care was taken not to constrict the duodenal lumen at the site of anastomosis. The abdomen was then closed without drainage. Five hundred milliliters of lactated Ringer's solution was given intravenously during the operative procedure and standard kennel rations resumed on the first postoperative day. The animals were sacrificed at varying periods ranging from 28 to 159 days and the site of the repaired fistulas studied, both grossly and histologi-

cally, for evidence of mucosal regeneration over the serosal patch.

In three other animals a lateral duodenostomy was created 7.5 cm. from the pylorus by suturing a No. 18 Robinson catheter into the duodenum (Group II). On the fourth postoperative day the catheter was removed, and the resultant defect closed in a manner identical to that described above. These animals were sacrificed at 100 to 110 days following the second operation.

In another four animals a Roux-Y duodenojejunostomy was employed to cover the duodenal defect created (Group III). In these, following excision of a portion of the duodenal wall, a Roux-Y limb was created by dividing the jejunum 15 cm. distal to the ligament of Treitz. The distal end of the transected bowel was anastomosed to the lateral duodenal defect using a two-layer technic of an outer row of interrupted 4-0 silk and an inner row of continuous 3-0

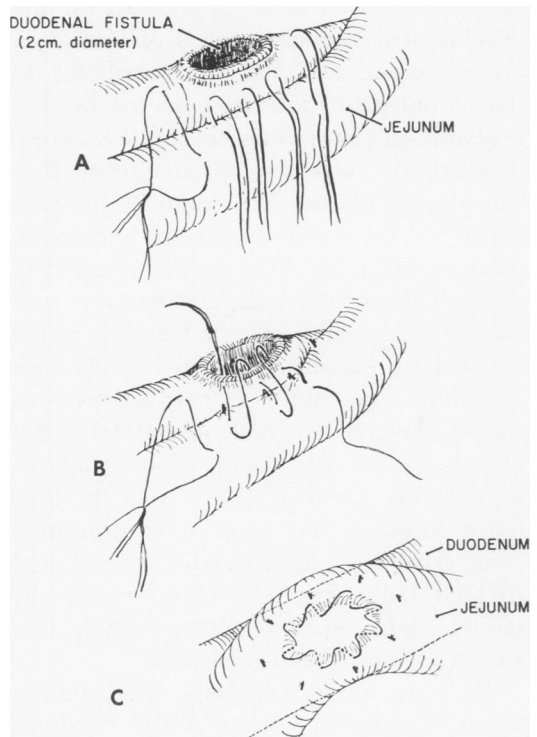


FIG. 2. Technic of anastomosing jejunum about duodenal defect

chromic catgut. Fifteen cm. distal to the duodenojejunostomy an end-to-side jejunojunction was made. These animals were sacrificed at periods ranging from 111 to 134 days. One dog died on the third postoperative day from an anastomotic leak.

In three dogs a gastric defect was made by excising  $2.0 \times 3.0$  cm. of the anterior wall of the distal stomach (Group IV). This opening was closed in a manner identical to that employed in Group I utilizing a serosal patch. These animals were sacrificed between 118 and 150 days.

### Results

Those animals treated with a serosal patch immediately sutured over the defect in the duodenal wall all survived without sequelae until sacrificed. At postmortem examination there was no sign of anastomotic leakage, intestinal obstruction, or digestion of the serosal patch. Upper gastrointestinal x-rays revealed no evidence of constriction of the duodenal lumen and this was confirmed at autopsy. Gross and microscopic examination of the repaired defect demonstrated partial mucosal spread over the jejunal surface by 28 days (Fig. 4).

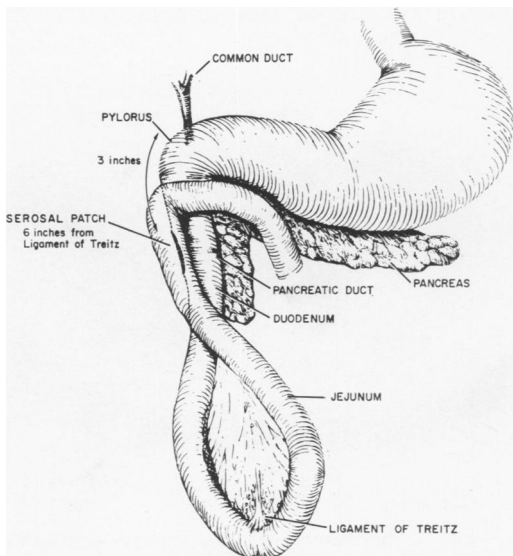


FIG. 3. Completed anastomoses showing serosal patch occluding duodenal opening.

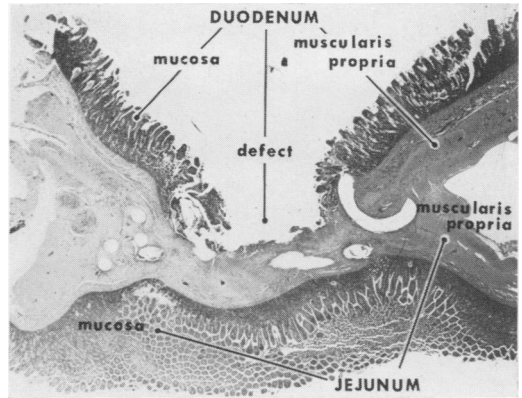


FIG. 4. Histologic section of duodenal defect covered with a serosal patch obtained 28 days postoperatively. There is a thin band of granulation tissue over the jejunal serosa and beginning epithelialization at the edges.

At this time the serosa of the jejunum was covered by a thin band of granulation tissue. There was regeneration of a single layer of duodenal mucosa at the edges of the defect, but the center was not yet epithelialized. Numerous goblet cells were present and the mucosa of the duodenum heavily infiltrated with plasma cells. At seven weeks the defect was covered by duodenal mucosa which although lower in height than normal, had formed villi and small glands (Fig. 5). Numerous goblet cells were present. In an animal sacrificed at 130 days, the defect was completely cov-

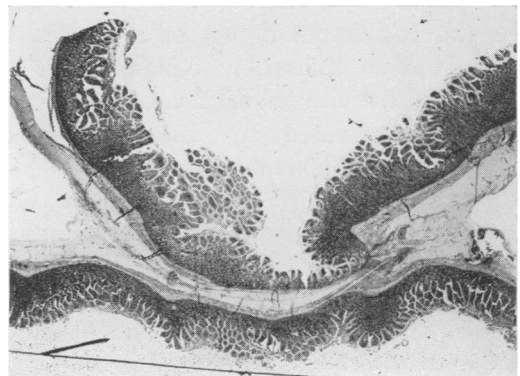


FIG. 5. Repaired defect seven weeks postoperatively. Jejunal serosa is entirely covered by duodenal mucosa which although low in height shows beginning villous and gland formation.

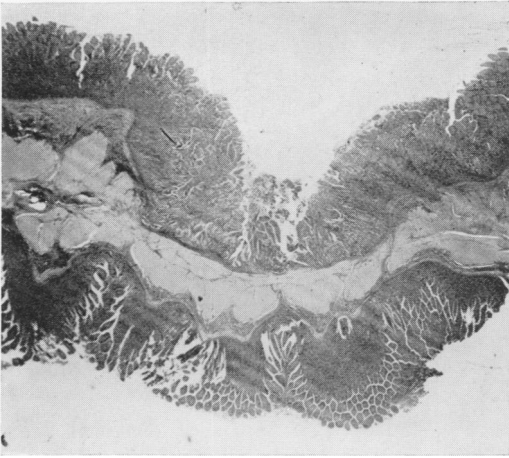


FIG. 6. Repaired defect 130 days postoperatively shows complete coverage of the jejunal serosa by mature duodenal epithelium one-half to two-thirds normal height.

ered by mature duodenal epithelium which was one-half to two-thirds normal height (Fig. 6). A final section examined approximately six months postoperatively showed the site of the duodenal opening to be well healed and covered by mucosa of normal thickness (Fig. 7).

Those animals with *chronic* duodenal fistulas (Group II), treated in a manner identical to that in Group I, demonstrated a similar healing process. Repaired fistulas examined grossly and histologically at periods ranging from 100 to 120 days, showed the defects to be covered by mature duodenal mucosa somewhat less than normal height. It was noted that in all instances there was an infiltration of plasma cells in the duodenal and jejunal mucosa.

Animals treated by anastomosing a Roux-Y limb of jejunum about the duodenal opening (Group III) were sacrificed between 111 and 134 days and similar signs of healing to the above two groups were noted. Of interest, was the absence of evidence of peptic digestion in the jejunum adjacent to the suture line.

The gastric wall openings covered with a serosal patch were examined grossly and histologically between 118 and 150 days.

Grossly the repaired defects were well healed as evidenced by gastric epithelium bridging the defect. This epithelialization was confirmed histologically. Furthermore, there was no evidence of digestion of the jejunal serosa, but a moderate infiltration of chronic inflammatory cells in the underlying muscularis propria of the jejunum was noted.

### Discussion

A defect in the duodenal wall too large to be closed by primary suture is often encountered associated with blunt abdominal trauma, or may be unintentionally produced during resection of a tumor of the right kidney or right colon. Such tissue losses may also follow the excision of chronic lateral duodenal fistulas as a result of the foreshortening and scarring occasioned by chronic inflammatory reaction. A myriad of operative procedures have been advocated for the repair of such lesions,<sup>1, 2, 4, 10, 11, 13, 15, 17, 21, 23-25</sup> but despite these, morbidity and mortality rates from such repairs remain high. Since many of the patients with acute traumatic lesions of the duodenum also have severe associated injuries, the definitive treatment of the duodenal injury should be simple and complicated resec-

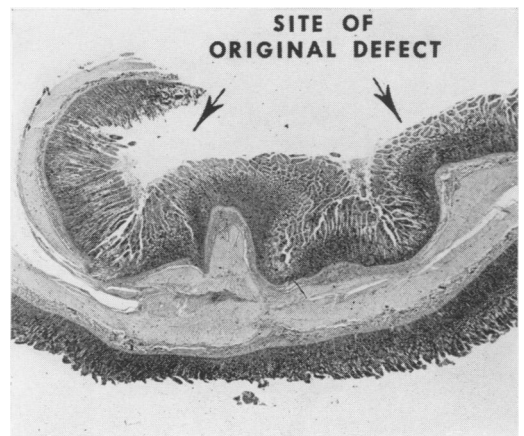


FIG. 7. Repaired defect six months postoperatively. There is complete epithelialization over the jejunal serosa by mature villous producing, gland forming duodenal mucosa of normal height.

tions and anastomosis avoided if possible. Furthermore, many of those operated upon for closure of chronic duodenal fistula, or in whom a portion of the duodenum is resected because of malignant invasion, are poor operative risks from a nutritional and metabolic viewpoint. Here, too, the simplest operative procedure should be productive of the best results.

Recent reports by Kobold and Thal<sup>18</sup> and Jones and Joergensen,<sup>17</sup> have emphasized the need for the simple technic for the closure of acute duodenal defects. The study here reported supports these authors' observations. From our studies it appears that the serosal patch is the operation of choice when one-half to two-thirds of the duodenal wall remains intact and is viable. Experimentally, under these circumstances, the duodenal mucosa will spread over the abutted jejunal serosa and restore the mucosal continuity of the duodenum. Such an operation could also be employed for large duodenal wall defects proximal to the ampulla of Vater, for the passage of acid chyme over the serosal patch has not caused either digestion of the jejunal wall, or prevented the ingrowth of normal duodenal mucosa. In those instances where one-half or less of the duodenal wall remains, usually as a result of intentional resection, a Roux-Y anastomosis, either side-to-side, or end-to-side, would be preferable in order to avoid producing duodenal stenosis. If this operation is utilized the anastomosed limb of jejunum should be either at the level of or below the ampulla of Vater. Experimentally, animals with such anastomoses did not develop anastomotic ulceration of the jejunal limb.

Finally, the serosal patch principle seems applicable in those cases where excision of a chronic duodenal fistula results in a defect too large to close primarily, or to reinforce a primary closure. Those animals in whom such fistulas were *patched* demonstrated mucosal coverage similar to that observed in acutely repaired defects. We

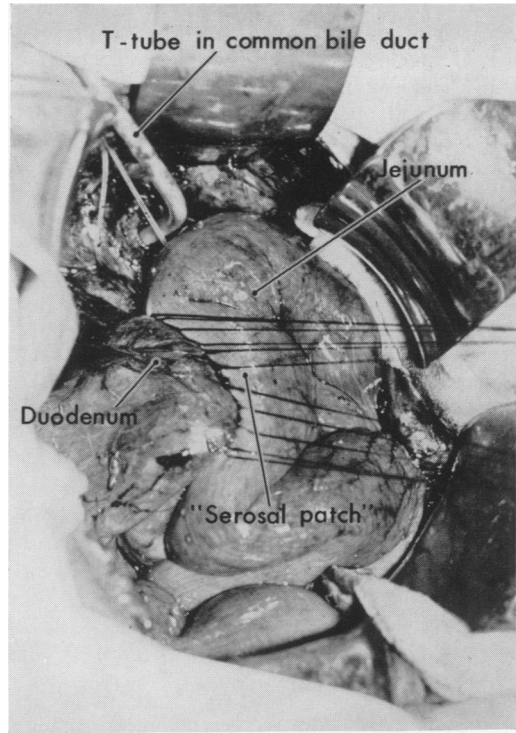


FIG. 8. Chronic duodenal fistula treated by excision and primary closure reinforced with a serosal patch.

recently had occasion to employ this serosal patch technic clinically in association with primary closure in the management of a chronic, lateral duodenal fistula.

### Case Report

A 62-year-old man was admitted in extremis on 12-27-61, with a lateral duodenal fistula occurring after cholecystectomy, transduodenal sphincterotomy and common bile duct exploration 10 days previously. Initial treatment was supportive consisting of fluid and electrolyte maintenance, antibiotics, and sump drainage to the abdominal wound. Because of the inability to maintain fluid, electrolyte and metabolic hemoestasis by parenteral routes, a gastrostomy, and feeding jejunostomy were done under local anesthesia on 1-2-62. Postoperatively he showed gradual, but progressive improvement. At the time of discharge on 3-8-62, the abdominal wound had healed, the fistula had ceased draining and he was able to maintain his nutrition orally. Five days later the fistula reopened and drainage of bile through an opening in the right upper quadrant operative incision was

noted. Radio-opaque contrast medium injected into the fistulous opening on the skin demonstrated the internal opening to extend into the second portion of the duodenum. Supportive treatment was re-instituted and operation advised, but the patient preferred waiting until a later date. During the next four months he maintained his nutrition without difficulty, but continued to have intermittent external biliary drainage from the abdominal incision. He was re-admitted to the hospital on 7-15-62 and after a two-week period of skin preparation the fistula was excised on 7-31-62. At the time of operation the fistula extended into the second portion of the duodenum. An additional finding was a 2.0 cm. stone impacted in the distal portion of the common bile duct. A choledochostomy was done, the stone removed, and the common bile duct closed about a T-tube. The fistula was then excised producing a 3 cm. defect in the duodenal wall. Although it was possible to obtain a two-layer primary closure in a transverse direction without compromising the lumen of the duodenum, a loop of jejunum was sutured to the duodenum about the site of closure (Fig. 8). The patient's postoperative course was entirely uneventful.

In the case reported, the jejunum was sutured about the site of primary closure to act as a deterrent against recurrence of the fistula. Cleveland and Waddell<sup>8</sup> have reported duodenal fistula as being the most common postoperative complication in their series of patients operated upon for retroperitoneal rupture of the duodenum occurring in 33 per cent, and found an over-all incidence of 14 per cent in a collected series of 28 similar cases reported between 1951 and 1961.

### Summary

Laboratory data are presented in support of the serosal patch technic for repairing acute defects of the duodenal wall too large to be closed primarily. Experimentally such closures were resistant to acid digestion of the jejunal wall and were also satisfactory for the repair of chronic duodenal fistulas. Roux-Y repairs were also efficacious in repairing lateral duodenal defects providing the duodenojejunostomy was at the level of, or below, the entrance of the bile and pancreatic ducts.

The operative management of a patient with a chronic duodenal fistula treated by primary closure reinforced with a serosal patch is presented.

### References

1. Albright, H. L. and C. L. Field: Duodenal Fistula—Problems in Management. *Ann. Surg.*, 132:49, 1950.
2. Barnett, W. O.: Investigations Regarding the Management of Duodenal Stump. *Surg., Gynec. & Obst.*, 113:197, 1961.
3. Bartlett, M. K. and H. W. Lowell: Acute Post-operative Duodenal Fistula. *N. Engl. J. Med.*, 218:587, 1938.
4. Berg, A. A.: Duodenal Fistula: Its Treatment by Gastrojejunostomy and Pyloric Exclusion. *Ann. Surg.*, 45:721, 1907.
5. Brown, R. B., R. C. Speir and J. W. Trenton: Duodenal Fistula. *Ann. Surg.*, 132:913, 1950.
6. Brody, D. A. and J. P. Quiegly: Intralumen Pressures of the Stomach and Duodenum in Health and Disease. *Gastroent.*, 9:570, 1947.
7. Chambler, K.: The Management of Duodenal-stump Fistula. *Lancet*, II:1303, 1958.
8. Cleveland, C. H. and W. R. Waddell: Retroperitoneal Rupture of Duodenum Due to Non-penetrating Trauma. *Surg. Clin. N. Amer.*, 43:413, 1963.
9. Colp, R.: External Duodenal Fistula. *Ann. Surg.*, 78:725, 1923.
10. Copobianco, A.: Complete Transverse Division of Duodenum Caused by Non-penetrating Trauma to Abdominal Wall. *U. S. Armed Forces Med. J.*, 7:1809, 1956.
11. Craighead, C. C. and A. H. St. Raymond, Jr.: Duodenal Fistula. *Am. J. Surg.*, 87:523, 1954.
12. Edmunds, H., G. Williams and C. Welch: External Fistulas Arising from the Gastro-intestinal Tract. *Ann. Surg.*, 152:445, 1960.
13. Einhorn, M.: Duodenal Perforation (Fistula) Treated by Duodenal (Jejunal) Alimenta-tion. *J.A.M.A.*, 74:790, 1920.
14. Gardner, A. M. N.: Use of Modified Miller-Abbott Tube in the Treatment of Duodenal Fistula. *Brit. J. Surg.*, 39:65, 1951.
15. Hanley, J. A.: Retroperitoneal Duodenal Rupture. *Brit. Med. J.*, 5069:505, 1958.
16. Hodgson, P. E. and D. C. Hunter: Protection of a Duodenal Stump Closure. *Surg. Clin. N. Amer.*, 41:1323, 1961.
17. Jones, S. A. and E. J. Joergensen: Closure of Duodenal Wall Defects. *Surgery*, 53:439, 1963.

18. Kobold, E. E. and A. P. Thal: A Simple Method for the Management of Experimental Wounds of the Duodenum. *Surg., Gynec. & Obst.*, 116:340, 1963.
19. Ransom, H. K. and F. A. Collier: Intestinal Fistulas. *J. Mich. State Med. S.*, 34:281, 1935.
20. Schechter, J. and D. Barrow: Duodenal Fistula Following Subtotal Gastrectomy. *Illinois Med. J.*, 116:140, 1959.
21. Siler, V. E.: Management of Rupture of Duodenum Due to Violence. *Am. J. Surg.*, 78:715, 1949.
22. Smith, D. W. and R. M. Lee: Nutritional Management in Duodenal Fistula. *Surg., Gynec. & Obst.*, 103:66, 1956.
23. Snyder, W. H., C. J. Berne and E. L. Turner: Closure of Duodenal Fistula, "A New Technique." *Surgery*, 18:562, 1945.
24. Stransky, J. J.: Retroperitoneal Rupture of Duodenum due to Nonpenetrating Abdominal Trauma. *Surgery*, 35:928, 1954.
25. Todd, J. D.: Rupture of the Duodenum from Non-penetrating Abdominal Trauma. *West. J. Surg.*, 64:638, 1956.
26. Welch, C. E. and L. H. Edmunds: Gastrointestinal Fistulas. *S. Clin. N. Amer.*, 42:1311, 1962.
27. West, J. P., E. M. Ring, R. E. Miller and W. P. Burke: A Study of the Causes and Treatment of External Postoperative Intestinal Fistulas. *Surg., Gynec. & Obst.*, 113:490, 1961.

---

(Continued from page 562)

*The Management of Internal Derangements of the Knee.* Helfet, Arthur J., M.D., B.Sc. J. B. Lippincott Co., 1963, 230 pages, \$12.00.

*Fundamentals of Vascular Grafting.* Wesolowski, Sigmoid A., and Dennis, Clarence, M.D. McGraw-Hill Book Co., 1963, 500 pages, \$22.50.

*Anesthesia for Surgery of the Heart.* Keown, Kenneth K., M.D. Charles C Thomas, 1963, 206 pages, \$7.75.

*Gynecologic Surgery and Urology.* Ball, Thomas L. C. V. Mosby Co., 1963, 648 pages, \$22.50.

*Campbell's Operative Orthopaedics*, Vol. 1-2. Crenshaw, A. H., M.D. C. V. Mosby Co., 1963, Vol. 1, 858 pages, Vol. 2, 778 pages, \$57.50.

*Anesthesia for Infants & Children.* Smith, Robert M., M.D. C. V. Mosby Co., 1963, 470 pages, \$13.50.

*Doctors Made in America.* Bauer, Edward L. J. B. Lippincott Co., 1963, 370 pages, \$5.00.

*The Postgastrectomy Syndromes.* Woodward, E. R., M.D. Charles C Thomas, 1963, 56 pages, \$3.75.

*Pathology of Tumors of the Nervous System.* Russell, Dorothy S., M.D., Rubinstein, L. J., M.D., and Lumsden, C. D., M.D. Williams & Wilkins Co., 345 pages, \$3.50.

*Atomic Energy Encyclopedia in the Life Sciences.* Shilling, Charles W., M.D., D.Sc. W. B. Saunders Co., 1964, 474 pages.

*Current Pediatric Therapy.* Cellis, Sydney S., M.D., and Kagan, Benjamin M., M.D. W. B. Saunders Co., Philadelphia, Pa., 747 pages.

*Orthopedic Diseases—Physiology—Pathology—Radiology*, Second Edition. Aegerter, Ernest, M.D., and Kirkpatrick, Jr., John A., M.D. W. B. Saunders Co., 1963, 786 pages, \$16.00.

*Pediatric Cardiology*, Second Edition. Nadas, Alexander S., M.D., F.A.A.P. W. B. Saunders Co., 1963, 828 pages, \$16.00.

*Clinical Neurosurgery*, Volume 9. Congress of Neurological Surgeons. The Williams & Wilkins Co., 1963, 314 pages, \$12.00.

*Handbook of the Practice of Anesthesia.* Shields, John R. The C. V. Mosby Co., 1963, 203 pages, \$6.85.

*Hernia.* Koontz, Amos R. Appleton-Century-Crofts, Inc., 1963, 227 pages, \$11.95.

(Continued on page 598)