

Two cases of 'pancreatic cholera' with features of peptide-secreting adenomatosis of the pancreas

W. SIRCUS¹, P. W. BRUNT, R. J. WALKER, W. P. SMALL,
C. W. A. FALCONER, AND CHRISTINE G. THOMSON

From the Gastro-Intestinal Unit, and Teaching and Research Centre, Western General Hospital, Edinburgh

SUMMARY The clinical data are presented of two women with profound metabolic upset from exceptional water and electrolyte losses in diarrhoea. One had an islet-cell adenoma of the pancreas and the other abnormal islets. Gastric and pancreatic function were abnormal in both, consistent with the subsequent demonstration of a pancreatic and choleric secretagogue in the tumour tissue and pancreatic and gastric secretagogues in circulating blood (Cleator, Thomson, Sircus, and Coombes, 1970).

A variety of clinical constellations may be associated with the secretion into the circulation of polypeptides and other biologically active substances from hyperplastic or neoplastic endocrine structures. One such consists of the association of a tumour or of hyperplasia of non-beta islet cells of the pancreas with intractable watery diarrhoea, hypokalaemia, and often hypercalcaemia, and achlorhydria (Priest and Alexander, 1957; Parkins, 1961; Espiner and Beaven, 1962; Hindle, McBrien, and Creamer, 1964; Matsumoto, Peter, Schultze, Hakim, and Franck, 1966; Marks, Bank, and Louw, 1967).

A proportion of patients with peptide-secreting adenomata (Sircus, 1968) show much variation in the clinical and biochemical phenomena, so that either simultaneously or sequentially, the features of gastric hypersecretion of a gastrinoma may be associated with those of the vascular and motility derangement of the carcinoid syndrome, the hypoglycaemia of an insulinoma, the hypercalcaemia of hyperparathyroidism, the diabetes and dermatitis of a glucagonoma, and the water-losing, electrolyte-losing non-steatorrhaeic diarrhoea, with or without achlorhydria. Likewise, the lesions may be shown to consist of more than one cell type and the tissue to elaborate more than one biologically active amine compound or polypeptide. The circulation may then contain an excess over the physiological levels of more than

one such substance. These phenomena have been recently reviewed (Levin, 1968; Sircus, 1969).

The clinical data are reported of two patients, both female, with water-losing, electrolyte-losing diarrhoea causing profound illness. In one of the patients an islet adenoma was found on the head of the pancreas, and in the other, abnormal islet cells were found in the resected portion of distal pancreas. In both patients, evidence was obtained of abnormality in gastric and pancreatic function. An extract of tumour of the first case contained, on bio-assay, a pancreatic secretagogue and the blood of the second case had both gastric and pancreatic secretagogue properties (Cleator, Thomson, Sircus, and Coombes, 1970).

First Case

A 33-year-old housewife presented in May 1967 with a nine months' history of persistent watery diarrhoea. Prior to delivery of her first child in August 1966, she had been in excellent health, apart from occasional urinary tract infection. Diarrhoea had commenced quite suddenly two and a half weeks after delivery. Normal bowel habit was thereafter never re-established. The stools were liquid, often watery, of normal colour, inoffensive, and numbering up to 15 daily. There was occasional mucus but never blood

¹Member of external scientific staff, Medical Research Council.

Pain, tenesmus, fever, and constitutional disturbance were strikingly absent, though there was over half a stone weight loss. Her social circumstances were satisfactory and there was no relevant family history.

Clinical examination revealed a healthy woman with no abnormal physical signs. The pelvic colon was palpable. Sigmoidoscopy showed a slightly hyperaemic mucosa. Soon after admission to the unit, *Shigella sonnei* was isolated from the stool and the patient was accordingly transferred to an infectious diseases hospital where she was treated with neomycin. She was discharged when stool cultures became negative, but the diarrhoea persisted despite symptomatic therapy with codeine phosphate and hydrophilic colloids. On her consequent re-referral to the unit, outpatient investigation demonstrated a disordered radiological pattern in a barium meal followed through the small bowel, which appeared due to flocculation and abnormal motility. Chemical (1.8 m-equiv/l) and electrocardiographic evidence of hypokalaemia was present but faecal fat excretion was normal (6.8 g in 72 hours). She was therefore re-admitted in September 1967, having experienced a worsening of the diarrhoea, and severe weakness which was found to be the result of a myasthenia associated with hypokalaemia and dehydration. There was no complaint of pain, vomiting, or blood loss. Physical examination showed her to be pale, profoundly weak and dehydrated. The blood pressure was 95/65. The abdomen was soft, minimally distended with occasional bowel sounds only, there was no tenderness, and no masses were elicited. Sigmoidoscopy again showed hyperaemia. Frothy, loose, watery, pale, but inoffensive faeces poured from the rectum, and had an odour resembling that of sweat.

Initial investigations showed that the haemoglobin was 17.3 g/100 ml, the haematocrit 51%, and the mean corpuscular haemoglobin concentration 34%. The white blood count was 13,600 with a normal differential; the peripheral blood film was normal. The erythrocyte sedimentation rate was 7 mm/hr, sodium 132 m-equiv/l, potassium 2.0 m-equiv/l, chloride 99 m-equiv/l, carbon dioxide content 21.5 m-equiv/l, urea 53 mg/100 ml, calcium 10.8 mg/100 ml, and magnesium 2.1 mg/100 millilitre. The liver function tests were normal. The total protein was 7 g/100 ml, the albumin 4.1 g/100 ml, and the globulin 2.9 g/100 millilitre. Pathogens were absent from repeated cultures of stools. Plain x-rays of the chest and abdomen were normal. Rehydration was achieved by oral and intravenous routes.

Subsequently, the haemoglobin stabilized at 12.9 g/100 ml, with a total white blood count of 9,700/cubic millimetres. The serum level of potassium gradually rose to 4.3 m-equiv/l only after considerable oral and intravenous replacement (Figure 1 a, b, and c). Serum calcium values, corrected for protein, varied as follows:

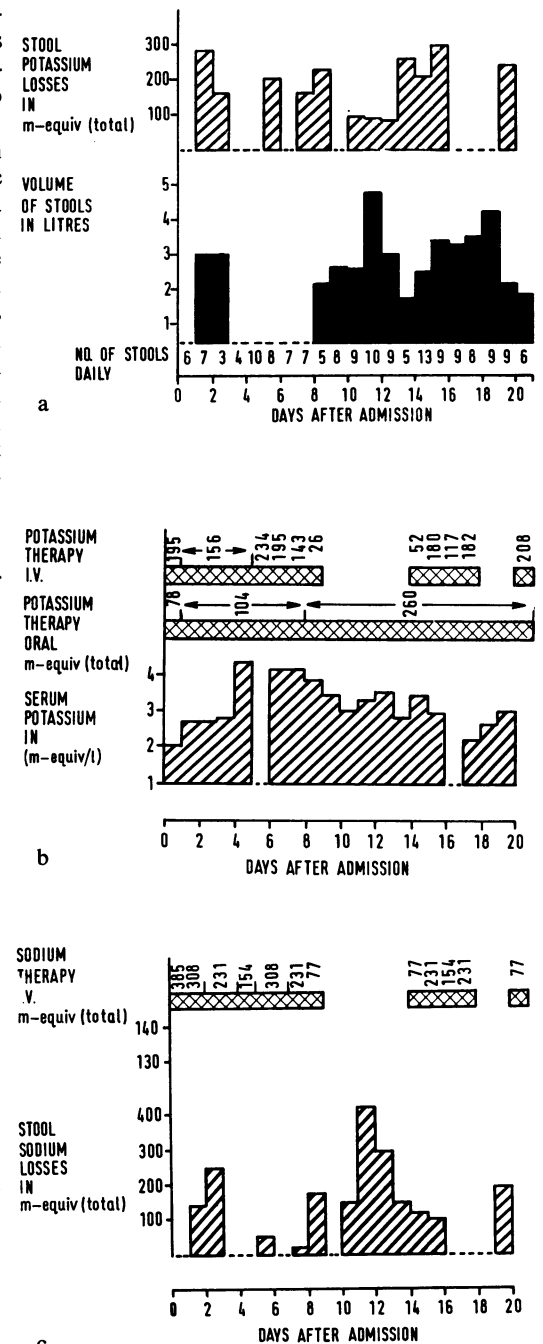


Fig. 1 (a) Stool potassium losses, (b) potassium therapy, (c) sodium losses and therapy (Case 1).

10.8, 10.2, 9.5, 9.8, 10.3, 12.3 mg/100 millilitre.

Other investigations showed that the urinary excretion of calcium was 330 mg in 24 hours with a volume of 1,980 ml, and 298 mg in 24 hours with a volume of 1,600 millilitres. Serum magnesium was 1.6, 2.2, 1.6, 1.7 mg/100 ml, urinary magnesium excretion 167 mg in 24 hours with a volume of 3,340 millilitres. Serum protein electrophoresis showed a slight increase in alpha-2




Fig. 2 Pancreatic scintillogram (case 1).

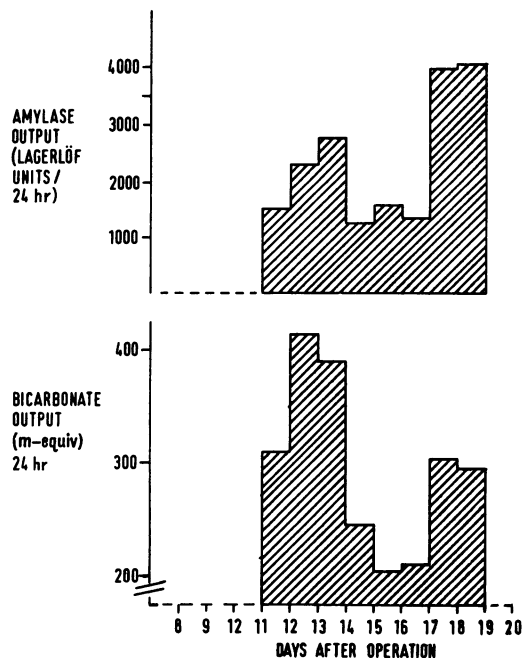


Fig. 4 Postoperative amylase and bicarbonate losses (case 1).

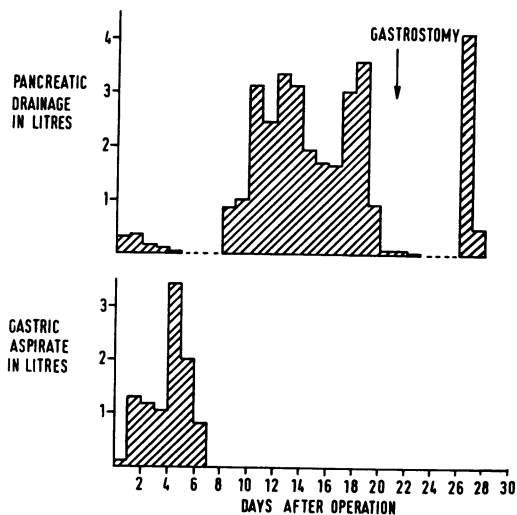


Fig. 3 Postoperative gastric and pancreatic bed drainage (case 1).

globulin. The protein-bound iodine was 4.6 mg/100 millilitres. Plasma cortisol was 16 μ g/100 ml at 10 pm, and 19 μ g/100 ml at 9 am. Urinary 17-ketosteroids were normal at 4.9 mg, urinary 17-hydroxycorticoids were also normal at 10.6 milligrams. Urinary hydroxyindole acetic acid and hydroxymethoxy-mandelic acid excretions were both normal. A barium meal showed a small hiatus hernia, markedly hypertrophic gastric folds and some flocculation and segmentation of barium in the small bowel, and the terminal ileum appeared normal. The barium enema was

also normal, and x-ray films of skull, hands, pelvis, and spine showed no abnormality. A 75 selenomethionine pancreatic scintillogram showed an unusually dense uptake over a wide area in the region of the pancreas (Figure 2). A complementary liver scan with 99m technetium showed no abnormality, and scanning of the parathyroid zones, also with 75 selenomethionine, did not demonstrate any excess of uptake. Small bowel motility was assessed with a telemetered endosonde capsule and was found to be grossly diminished and, for long periods, absent. Gastric acid secretory function was studied but many tests had to be carried out at times during which serum electrolytes were depleted; nevertheless, the unstimulated basal hourly output ranged from 8 to 14.5 m-equiv HCl, and during an 11-hour overnight collection the patient produced between 6 and 12 m-equiv/hour. Stimulation with 0.04 mg of histamine acid phosphate per kg body weight resulted in a total of only 10.4 m-equiv in the post-stimulation hour. Plasma from lithium-heparinized blood removed before, during, and after operation, was kept frozen and reserved for subsequent bio-assay. A hormone-stimulated pancreatic function test was technically unsatisfactory.

On 10 October 1967 laparotomy was carried out (W.P.S.) with a provisional diagnosis of water-losing electrolyte-losing diarrhoea due to a peptide-secreting adenoma of pancreas. This was embarked upon as a matter of some urgency, as it was proving increasingly difficult to replace the losses of electrolytes and fluid (Figure 1 a, b, and

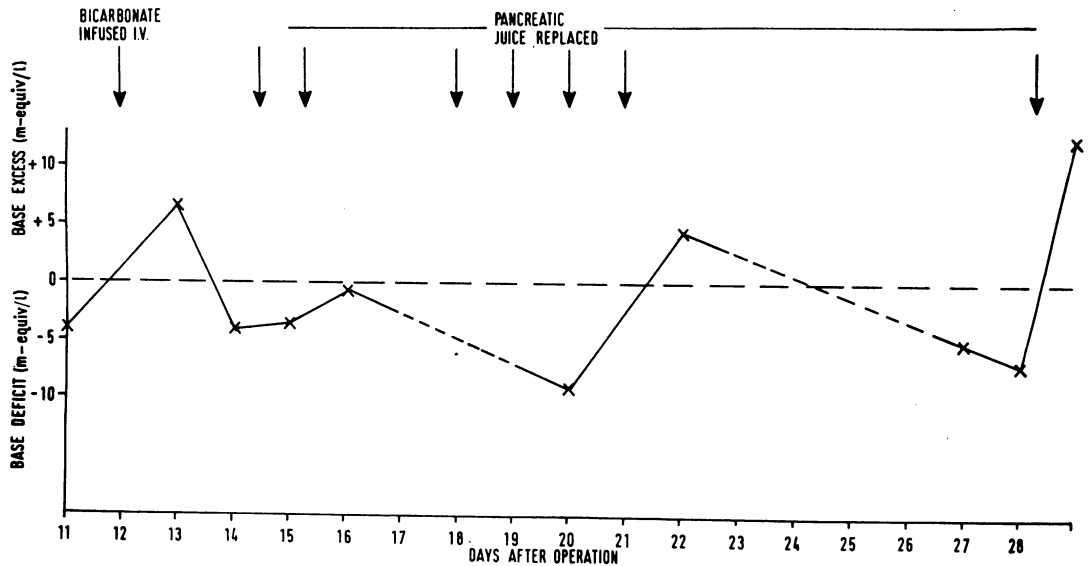


Fig. 5 Acid/base changes postoperatively (case 1).

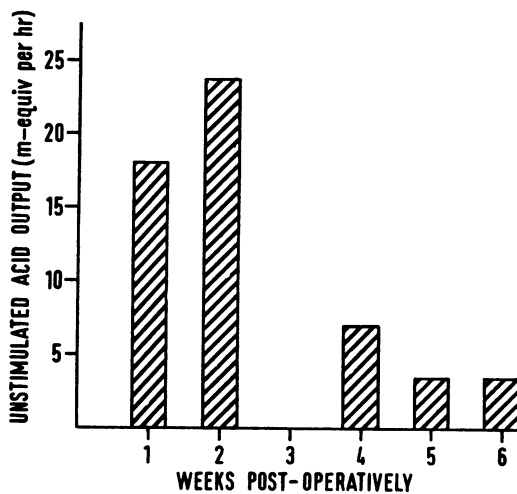


Fig. 6 Postoperative basal acid output (case 1).

c). The exploration revealed a tumour related to the head of the pancreas, which was 5 cm × 4 cm × 3 cm and weighed 10 grams. The tumour was enucleated, and there was no evidence of metastases. A redivac polythene tube drain was placed at the site of tumour resection in close proximity to the main pancreatic duct.

Postoperatively, large aspirates were obtained by nasogastric suction with a Levin tube and ranged from 790 ml in 24 hours to 3,400 ml in 24 hours (Figure 3). On the sixth day, 127 m-equiv HCl was recovered. On the eighth postoperative day the intragastric tube was removed because of the ion losses. The next day there appeared a dramatic increase in the drainage from the tube placed in the pancreatic bed of the tumour. This

varied in volume from 850 ml per 24 hours to 3,600 ml per 24 hours. The fluid was crystal clear, alkaline, and contained amylase and bicarbonate, but not bile. The losses incurred by this further drainage of fluid and electrolytes (Figs. 4 and 5) produced a base deficit. To assist management, on day 21 after the operation, a gastrostomy tube was placed under general anaesthesia with the idea of putting the daily pancreatic aspirate into the stomach. It was assumed from the quantity of the drainage that a pancreatic fistula had developed, possibly due to penetration of the pancreatic duct by the drain. However, immediately after the operation for the insertion of the gastrostomy tube, pancreatic drainage virtually ceased. Six days later pancreatic drainage suddenly recurred, reaching 4 litres in 24 hours, and was possibly due to the discharge of a loculated collection as all drainage ceased thereafter. The gastrostomy tube was not required for its intended purpose, though it incidentally allowed serial gastric function studies with minimal discomfort to the patient. Scintillation scans of liver and pancreas, two weeks and two months after operation, showed no abnormality. Furthermore, the unstimulated gastric acid output fell progressively and had reached a mean output of 3.5 m-equiv/hr by five weeks after operation (Figure 6). Subsequently the unstimulated gastric acid output, monitored at intervals, became normal and was still normal when last measured on 22 July 1969.

The patient made a gradual recovery after operation and gained weight from the third week. Bowel action recommenced on the fifth postoperative day, and thereafter stools remained

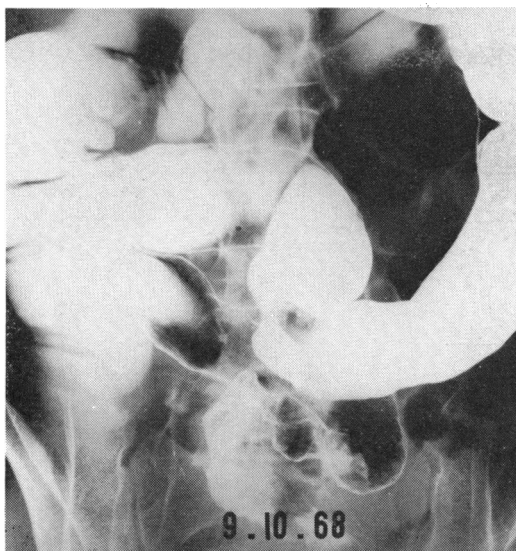


Fig. 7 Barium enema, showing partial volvulus and tendency to pseudostricture formation (case 2).

soft, or formed, with a maximum of three in 24 hours. The patient has since had no recurrence of diarrhoea and when last seen, 20 months after the operation, was in normal health with one normal stool daily. During this period of time she has had a second and completely uneventful pregnancy. Bio-assays for gastrin-like activity were carried out on plasma before, during and after operation (Cleator *et al*, 1970).

The tumour had a thin capsule, and consisted of compacted ribbons of cells formed into sheets. These cells had abundant cytoplasm, vesicular nuclei with prominent nucleoli, and mitotic figures were scarce. The appearance was that of a non-specific islet cell adenoma, or of islet cell carcinoma of very low-grade malignancy. A portion of the frozen tumour was sent to Mr R. Shields for study of the effects of extracts upon water and ion transport through canine intestinal mucosa.

Second Case

The patient was a 43-year-old spinster. She had worked in various places overseas between 1953 and 1960. While in Uganda in 1954, she was diagnosed as having amoebiasis and treated accordingly. Subsequently, she had occasional episodes of diarrhoea lasting between one and three days. There had been several hospital admissions for a depressive illness which was of 25 years' duration. For a period she was alcohol dependent but at the time of her admission had been abstinent for several months. Her father had died of a gastric carcinoma, but there was no other family history of alimentary disease.

Five weeks before being seen, she had developed severe watery diarrhoea, passing up to 20 stools in 24 hours. There was umbilical cramping discomfort and lower abdominal distension with occasional vomiting. During this time weight loss amounted to more than 7 kilograms. The copious daily loss of faeces was observed during a preliminary period of care in a private hospital by one of us before admission to the unit. Physical examination revealed a tall, extremely weak individual who was not obviously depressed but looked older than her years, and was wasted. Alopecia was evident and telangiectases were noted on the face. Blood pressure was 90/60 millimetres of mercury. The lower limbs showed non-pitting oedema with cyanotic discoloration. The abdomen was noisy, distended and tympanic, and tendon reflexes were hypotonic. A barium meal revealed flocculation with dilution of barium in the ileum and an atonic distended proximal colon.

Following admission to the unit on October 5, 1968, the patient continued to pass large volumes of inoffensive, watery, yellow stools similar to those of the previous patient. The maximum amount passed was 4 litres in 24 hours. Hypokalaemia was marked and required intravenous replacement. Three days after admission, the rectal flux stopped and an *x*-ray of the abdomen showed marked distension of the large bowel with multiple fluid levels. Chest *x*-ray was normal. A barium enema demonstrated colonic ileus with a partial volvulus in the descending sigmoid colon. The colon was voluminous and there was a suggestion of the presence of pseudostrictures (Figure 7). Subsequent serial abdominal films showed resolution of the distension and apart from one minor episode of diarrhoea, she remained relatively well with a semi-formed stool.

The results of the consequent investigations were as follows. Repeated cultures of stools and urine failed to reveal any pathogens or evidence of parasites. Haemoglobin was 13.1 g/100 ml, the packed cell volume was 40%, and the platelet count was normal. The erythrocyte sedimentation rate was raised, with a maximum of 44 mm fall in one hour. Plasma proteins had a maximum level of 6 g% of which 2.7 g was albumin. Serum B₁₂ was 369 µg/ml, serum folic acid 1.3 and 1.4 µg/ml, fasting serum iron 72 µg%, and total iron-binding capacity 251 µg%. A prothrombin assay was normal. Liver function tests, including alkaline phosphatase and bromsulphthalein retention, were also normal. The urinary excretion of 5-hydroxyindole acetic acid was normal. Steatorrhoea was present with a maximal excretion of 15 g of fat in 24 hours. The urinary excretion of xylose after 25 g oral load was 2.2 g in five hours. Blood levels of calcium and magnesium corrected for protein-binding capacity were normal. Serum potassium was 2.6 m-equiv/l and considerable potassium supplements were required to restore the serum

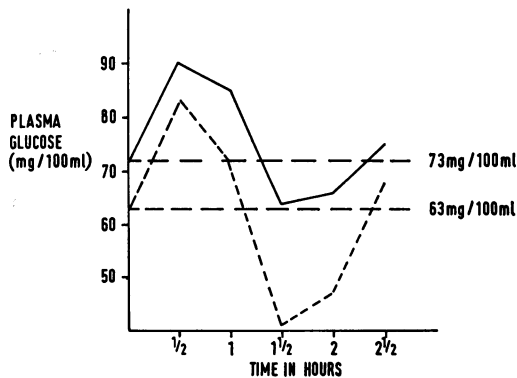


Fig. 8 Glucose tolerance curves (case 2).

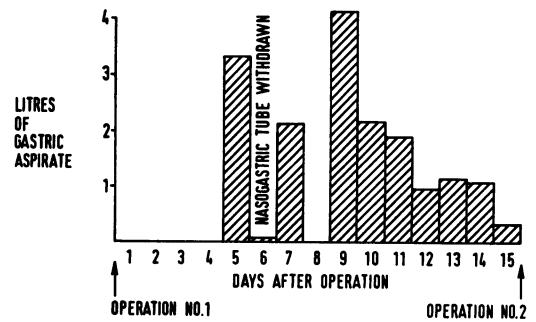


Fig. 9 Postoperative gastric aspiration (case 2).

levels to normal. Sodium was 133 m-equiv/l, protein-bound iodine 3.2 $\mu\text{g}\%$. Jejunal biopsy on two occasions showed total villous atrophy, and culture of the aspirate from the jejunum yielded yeasts $10^6/\text{ml}$ and *E. coli* $10^7/\text{ml}$. Two glucose tolerance tests appeared abnormal with a tendency for the glucose to fall steeply between one and one and a half hours to hypoglycaemic levels (Figure 8). A tolbutamide test was carried out with assay of immuno-reactive plasma insulin. The plasma insulin values in response to intravenous tolbutamide were within normal limits, but the plasma glucose values showed a minor abnormality.

Pancreatic function was twice stimulated with secretin and pancreozymin. In the first 80-minute test only 16 ml volume was recovered with a maximal carbon dioxide content of 62 m-equiv/l and only 1.0 unit of amylase per millilitre. In the second test, 72 ml was obtained in 80 minutes with a maximal carbon dioxide concentration of 59 m-equiv/l, and a maximal amylase concentration of 1.2 Lagerlof units per millilitre.

A modification of the Lundh pancreatic function test meal (Zeitlin, 1969) showed a very low trypsin output, the highest concentration being 5.9 $\mu\text{-equiv H}^+$ released/ml/min (normal, 10.4-39.6 $\mu\text{-equiv H}^+$ /ml/min) and a mean two-hour tryptic activity of 5.3 $\mu\text{-equiv H}^+$ released/ml/min (normal, 9.6-21.2 $\mu\text{-equiv H}^+$ released/ml/minute).

A ^{99}Tc scan of the liver was normal, but a ^{75}Se scan of pancreas revealed unusually widespread activity in the region of that organ. Sigmoidoscopy and rectal biopsies were normal. An examination of the urine failed to show any purgative derivatives.

On 15 October 1968, the gastric acid output in the unstimulated hour was 0.7 m-equiv in 19 ml recovered, and 14.9 m-equiv in 138 ml recovered in the hour after the injection of pentagastrin in a dose of 6 $\mu\text{g}/\text{kg}/\text{body weight}$.

In view of the total villous atrophy, treatment

was started with folic acid and a gluten-free diet. Although subjective improvement occurred, the stool became formed, and there was a little weight gain, the steatorrhoea continued. It was felt wise to perform laparotomy because of the possibility that the total villous atrophy was secondary to a neoplastic lesion of the pancreas or of the small intestine, and because initial bio-assay on the anaesthetized cat (Cleator *et al*, 1970) suggested secretin-like activity in the circulating blood.

At operation on 17 December 1968 (C.W.A.F.) the jejunum was dilated. The ileum was apparently normal. There were abundant fleshy nodes in the mesentery of the small bowel and glands around the head of pancreas. The pancreas appeared smoother and flatter than normal, but a tumour could not be located. Three centimetres of the tail of the pancreas was removed for the purposes of histology and for bio-assay. An operative pancreatogram was normal. A large redundant loop of pelvic colon was partially rotated on its narrow axis and this was re-arranged and fixed in position. The histopathology of the one node removed from near the head of the pancreas showed no abnormality, nor did a node from the mesentery. The spleen, which had been removed at the time of the distal pancreatic resection, was normal. A full thickness operative jejunal biopsy confirmed marked villous atrophy with a heavy infiltration with plasma cells, lymphocytes, and a few histiocytes. A similar biopsy in the ileum showed a number of chronic inflammatory cells in the lamina propria but otherwise was within normal limits. In the tail of the pancreas, no gross abnormality appeared in the ducts, blood vessels, or exocrine glands. There was mild hyperplasia of islet tissue. Some of the islets were large and consisted of immature small cells with little cytoplasm and there was an overwhelming predominance of beta cells with alpha cells relatively sparsely represented.

	1 January 1969	19 February 1969	26 May 1969
1	0.2	5.6	0.9
2	2.4	6.2	0.1
3	10.2	7.7	0.6

Table Basal acid output over one-hour periods (m-equiv)

Postoperative progress was marred by several episodes of small bowel obstruction which eventually required further operation for division of adhesions and release of a jejunal intussusception. Prior to this operation large gastric aspirates had appeared (Fig. 9), often but not invariably, bile stained, and the pH was never higher than 2.7.

The volume of gastric aspirates fell gradually and after 10 days the nasogastric tube was removed. Alimentation was initially assisted with feeding through a jejunostomy tube. There were minor episodes of abdominal colic and distension suggestive of subacute obstruction after this, but gradual progress was made. The stool was formed but still contained an excess of fat (13.9 g in 24 hours). The patient was discharged five weeks after the second operation. Her total stay in hospital was four months.

Three months after discharge (May 20, 1969) the patient remains very well on a regime of trimiprimine, folic acid, iron, gluten-free diet, and ascorbic acid supplements. Her bowel function is normal, weight has risen from 45 kg on 1 January 1969 to 70 kilograms. Three further studies of gastric secretion were obtained in the subsequent convalescent period and blood was serially sampled for peptide bio-assay. Despite the possibility that trimiprimine with its anticholinergic properties might have depressed gastric secretion, the unstimulated output of hydrochloric acid over three hours of continuous aspiration remained abnormal for some time, but when last examined, in May 1969, was normal (Table).

Discussion

Diarrhoea was a feature of some of the patients with non-beta islet cell tumours in the first review by Zollinger and Ellison (1955). In subsequent years there emerged a group in which the phenomenon of diarrhoea with, or without, achlorhydria could not be ascribed to overproduction of gastrin. There are, however, many mechanisms by which excessive production of gastrin could be responsible for diarrhoea and these have been reviewed (Jesseph, Moore, Endahl, and Parssi, 1967; Shimoda, Saunders, and Rubin, 1968; Mansbach, Wilkins, Dobbins, and Tyor, 1968).

In some patients with choleraic diarrhoea and a clinical suspicion of a peptide-secreting adenoma of the pancreas, gastric hypersecretion

and peptic ulceration were absent and gastrin was not extractable from tumour tissue. Furthermore, the clinical presentation in an individual patient may change with the passage of time (Sircus, 1963). Likewise, alteration in the secretion of biologically active humoral agents, coincident with the changing clinical picture, raises the possibility that humoral substances other than gastrin could be responsible for the diarrhoea. The dependency of the diarrhoea upon the pancreatic lesion was recognized by Matsumoto *et al* (1966) when they coined the phrase 'pancreatic cholera'. The syndrome has been held to be entirely independent of the Zollinger-Ellison syndrome (Goulon, Rapin, Charleux, Baguet, Kuntziger, Nonailhat, Barois, and Breteau, 1966), but Marks *et al* (1967) accepted the possibility that the syndrome 'merges imperceptibly with that clinical variant of the Zollinger-Ellison syndrome presenting with severe diarrhoea and marked acid hypersecretion'. As with others (Matsumoto *et al*, 1966), they believed the diarrhoea to be due to an isolated defect of water and electrolyte transport in the bowel caused by an unidentified islet cell hormone.

The first case reported here is important for several reasons. Prior to the removal of the tumour the gastric secretion from an unstimulated stomach was of such an order that, in relation to the body weight, should raise suspicion of an excessive drive on the parietal cells. That this could be due to gastrin is suggested by the failure of histamine to increase the basal output more than 50%. Subsequent to removal of the tumour, and coincident with the dramatic cessation of diarrhoea, the gastric secretion rose to such a high level that aspiration was stopped after seven days because of the ion losses. At this time rat bio-assay showed abnormal plasma levels of gastrin-like secretagogue (Thomson, Cleator, and Sircus, 1970). Two hypotheses could be postulated in explanation. First, that the tumour produced more than one humoral substance, and that one of these was stimulatory and trophic to the parietal cells, eg, gastrin, and the other acted as a functional inhibitor to the parietal cells, eg, secretin (Greenlee, Longhi, Guerrero, Nelsen, El-Bedri, and Dragstedt, 1957). Second, considering the post-operative positive 'gastrin' bio-assay an explanation that offers itself is a rebound hyperactivity of a previously repressed antrum. Parietal cell hyperplasia once established would result in gastric acid hypersecretion until the excessive trophic drive had been removed. It would then fall progressively, probably taking thirty or more days to return to normal (Sircus, 1965).

Extracts of this tumour were studied for an effect on intestinal transport of electrolytes and water (Shields and Ryan, 1969). None was found in keeping with the observations of Matsumoto *et al* (1966) but in distinction to those of Gardner and Cerda (1966). However, the

tissue was deep frozen without prior acetone dehydration and defatting, so it is possible that some secretin-like activity may have been lost.

The experience of this case indicates that, in the investigation of a case of choleraic diarrhoea, the clinical focus on a possible pancreatic origin should ideally include repeated bio-assays of plasma for evidence of circulating gastrin-like and secretin-like activity. In due course other humoral substances such as glucagon with its choleric effects, and others which may influence the glandular secretions of the alimentary tract, as well as water and ion transport, should be sought. Investigation at any particular moment into the natural history of these disorders may disclose only, or predominantly, one cell type in a tumour, and perhaps one physiologically active substance in excess in the circulation. Up to date, unfortunately, extracts of tumours have usually been prepared for the identification of a single substance. Likewise most workers have sought a single secretagogue in the circulation. With awareness of the possible pluripotentiality of the tumours for peptide production there is a need for the development of techniques allowing serial bio-assays of tissue extracts and blood for a number of different peptides. Only then will we learn what proportion of apparently 'pure' situations, such as that assumed to be the case with most insulinomas or most gastrinomas (Zollinger-Ellison syndrome), are in fact so, and how many are, or become, otherwise.

Hypercalcaemia, as in the first case, has been commonly observed in the twenty subjects with 'pancreatic cholera' thus far described. While this could be an indication of coexisting parathyroid adenoma it may alternatively be a manifestation of tertiary hyperparathyroidism triggered by an initial low serum calcium induced by hyperglucagonaemia (Paloyan, Paloyan, Worobec, Ernst, Deininger, and Harper, 1966). Supporting this latter explanation is the experience in the present case that after removal of the tumour, the serum calcium returned rapidly to normal. The persistence of a massive pancreatic hypersecretion after removal of the tumour could have a similar explanation to that put forward for the abnormal gastric function: that the pancreatic secretory cell hyperplasia persisted for some period after removal of the tumour. Unfortunately pancreatic tissue was not available as a biopsy was not taken. The unusually dense uptake of ^{75}S selenomethionine in the scintillogram has been interpreted here as evidence in support of this suggestion.

Because a tumour was not located in the second case the inclusion of this patient as an example of the same phenomenon is dependent upon the clear evidence of substances in the circulation with gastric and pancreatic secretagogue activity (Cleator *et al*, 1970). The presence of abnormal islet cells in the resected portion of the tail of the pancreas is noteworthy, but the pathogenic signi-

ficance of this finding is uncertain. This case is less easy to evaluate because of the presence of unusual features, including the villous atrophy of unknown aetiology and the severe colonic ileus with partial volvulus and pseudostrictures. Total villous atrophy was also a feature of another case of diarrhoea due to a pancreatic islet cell tumour (Paloyan *et al*, 1966). In that instance the jejunal mucosa returned to normal six months after resection of the tumour. Similar atrophic changes in the jejunum of varying degree have been described by others in cases of the Zollinger-Ellison syndrome (Shimoda *et al*, 1968; James, 1964; Creamer, 1964). Colonic ileus of this type is also seen in longstanding uncontrolled coeliac disease and in severe hypokalaemia. Equally difficult to evaluate is the tendency to hypoglycaemia in response to a glucose load (Fig. 7) as the same finding has been observed both in starvation states and in hyperglucagonaemia. It is notable that before the first operation on the second case reported here the pancreatic function was subnormal by two modes of testing, but had returned to normal some months later. Is it possible that this observation represents the pancreatic counterpart of the transient gastric achlorhydria seen in some other examples of 'pancreatic cholera'? Even though, on an anti-depressive drug with anticholinergic properties, unstimulated acid secretion from the stomach remained excessive in serial estimations over some months after discharge.

Although the diarrhoea of the first case could be ascribed to pancreatic hypersecretion, this clearly does not explain the diarrhoea in the second case in which pancreatic secretion was diminished. The choleraic diarrhoea syndrome may be an end result of a number of differing mechanisms. Thus in some instances, as in the first of the two cases excessive pancreatic, and perhaps gastric, secretions may be responsible, but in others (Gardner and Cerda, 1966) also excessive loss of fluid and electrolytes through the gut mucosa. There was no tumour tissue available in the second of the cases, and extracts of the resected tail of pancreas were not studied for effects on water and ion transport. There may well prove to be tumours with the capacity to alter both stomach and pancreatic secretions and also to influence ion and water transport.

We wish to express our sincere thanks to Dr N. Maclean, of the Department of Pathology of the Western General Hospital, for his advice on the histology of the tissues in the cases and for most helpful criticism of the communication. We are grateful to Dr Joyce Baird for the plasma insulin assay.

References

- Cleator, I. G. M., Thomson, C. G., Sircus, W., and Coombes, M. (1970). Bio-assay evidence of abnormal secretin-like and gastrin-like activity in tumour and blood in cases of 'choleraic diarrhoea'. *Gut*, 11, 197-205.

- Creamer, B. (1964). Variations in small-intestinal villous shape and mucosal dynamics. *Brit. med. J.*, 2, 1371-1373.
- Espiner, E. A., and Beaven, D. W. (1962). Non-specific islet-cell tumour of the pancreas with diarrhoea. *Quart. J. Med.*, 31, 447-471.
- Gardner, J. D., and Cerda, J. J. (1966). *In vitro* inhibition of intestinal fluid and electrolyte transfer by a non-beta islet-cell tumor. *Proc. Soc. exp. Biol. (N.Y.)*, 123, 361-364.
- Goulon, M., Rapin, M., Charleux, H., Baguet, J. C., Kuntziger, H., Nonailhat, F., Barois, A., and Breteau, M. (1966). Diarrhée acquise et hypokaliémie associées à une tumeur langerhansienne non-insulino-sécrétante. A propos d'un cas avec guérison immédiate et définitive de la diarrhée par exérèse tumorale. Discussion nosologique de ce syndrome avec celui de Zollinger at Ellison. *Bull. Soc. med. Hôp. Paris*, 117, 623-646.
- Greenlee, H. B., Longhi, E. H., Guerrero, J. D., Nelsen, T. S., El-Bedri, A. L., and Dragstedt, L. R. (1957). Inhibitory effect of pancreatic secretin on gastric secretion. *Amer. J. Physiol.*, 190, 396-402.
- Grossman, M. I. (1966). Treatment of duodenal ulcer with secretin: a speculative proposal. *Gastroenterology*, 50, 912-913.
- Hindle, W. D., McBrien, D. J., and Creamer, B. (1964). Watery diarrhoea and an islet cell tumour. *Gut*, 5, 359-362.
- James, A. H. (1964). Gastric epithelium in the duodenum. *Ibid.*, 5, 285-294.
- Jesseph, J. E., Moore, F. T., Endahl, G., and Parssi, R. B. (1967). Peptic ulceration and enteritis: a differential diagnosis. *Amer. J. Surg.*, 113, 188-193.
- Levin, M. E. (1968). Endocrine syndromes associated with pancreatic islet cell tumors. *Med. Clin. N. Amer.*, 52, 295-312.
- Mansbach, C. M., II, Wilkins, R. M., Dobbins, W. O., and Tyor, M. P. (1968). Intestinal mucosal function and structure in the steatorrhea of Zollinger-Ellison syndrome. *Arch. intern. Med.*, 121, 487-494.
- Marks, I. N., Bank, S., and Louw, J. H. (1967). Islet cell tumour of the pancreas with reversible watery diarrhea and achlorhydria. *Gastroenterology*, 52, 695-708.
- Matsumoto, K. K., Peter, J. B., Schultze, R. G., Hakim, A. A., and Franck, P. T. (1966). Watery diarrhea and hypokalemia associated with pancreatic islet cell adenoma. *Gastroenterology*, 50, 231-242.
- Paloyan, D., Paloyan, E., Worobec, R., Ernst, K., Deininger, E., and Harper, P. V. (1966). Serum glucagon levels in experimental acute pancreatitis in the dog. *Surg. Forum*, 17, 348-349.
- Parkins, R. A. (1961). Severe watery diarrhoea and potassium depletion associated with an islet-cell tumour of pancreas. *Brit. med. J.*, 2, 356-357.
- Priest, W. M., and Alexander, M. K. (1957). Islet cell tumour of the pancreas with peptic ulceration, diarrhoea, and hypokalaemia. *Lancet*, 2, 1145-1147.
- Shields, R., and Ryan, C. (1969). Personal communication.
- Shimoda, S. S., Saunders, D. R., and Rubin, C. E. (1968). The Zollinger-Ellison syndrome with steatorrhea. II. The mechanisms of fat and vitamin B₁₂ malabsorption. *Gastroenterology*, 55, 705-723.
- Singleton, J. W., Kern, F., Jr., and Waddell, W. R. (1965). Diarrhea and pancreatic islet cell tumor: Report of a case with a severe jejunal mucosal lesion. *Gastroenterology*, 49, 197-208.
- Sircus, W. (1963). The lessons of the Zollinger-Ellison syndrome. In *Proceedings of the Symposium on Alimentary Surgery and Physiology*, Royal College of Surgeons, Edinburgh.
- Sircus, W. (1965). Prolonged augmentation of the maximal secretory responses of canine gastric pouches, by chronic obstruction: a preliminary report and a hypothesis. *Amer. J. dig. Dis.*, 10, 499-505.
- Sircus, W. (1968). Peptide-secreting adenomata with special reference to the Zollinger-Ellison syndrome. *Postgrad. med. J.*, 44, 742-747.
- Sircus, W. (1969). Peptide-secreting tumours with special reference to the pancreas. *Gut*, 10, 506-515.
- Thomson, C. G., Cleator, I. G. M., and Sircus, W. (1970). Experiences with a rat bio-assay in the diagnosis of the Zollinger-Ellison syndrome. *Gut* (in the press).
- Zeitlin, I. J. (1969). Personal communication.
- Zollinger, R. M., and Ellison, E. H. (1955). Primary peptic ulcerations of the jejunum associated with islet cell tumors of the pancreas. *Ann. Surg.*, 142, 709-728.