

Intestinal spirochaetosis

F. D. LEE, A. KRASZEWSKI, J. GORDON, J. G. R. HOWIE, D. McSEVENEY,
AND W. A. HARLAND

*From the Departments of Pathology, Bacteriology, and Immunology, the University of Glasgow,
Western Infirmary, Glasgow*

SUMMARY An abnormal condition of the large intestine is described in which the surface epithelium is infested by short spirochaetes. Diagnosis can be made by light microscopy. A review of 14 cases diagnosed by rectal biopsy and 62 cases involving the appendix shows no consistent symptom complex. The possible significance is discussed.

It has been known since the last century that spirochaetes may be found in the human alimentary tract. Early bacteriological studies of intestinal spirochaetes emphasized their association with diseases such as cholera and infantile diarrhoea (Escherich, 1884 and 1886), appendicitis and ulcerative colitis (Thiroloux and Durand, 1911), anaemia and rheumatoid arthritis (Thomson and Thomson, 1914), and dysentery (le Dantec, 1903; Werner, 1909). Apart from cases of so-called 'spirochaetal dysentery', however, there has always been doubt as to the pathological significance of these organisms.

Spirochaetes have been found in the faeces of apparently healthy individuals, although there appears to be a marked geographical variation in incidence. Fantham (1916) found spirochaetes in 1.2% of faecal specimens from British soldiers, whereas Parr (1923) found the incidence to be 30% in Chicago, and Macfie (1917) showed that this figure approached 100% in West Africa. It is of interest that Macfie (1917) was able to demonstrate spirochaetes in the stomach as well as in the colon and small intestine, although Parr could only find these organisms in the large bowel. Kuisl (1885) and Escherich (1886) also found spirochaetes predominantly in the large bowel and only occasionally in the small intestine.

Since these early studies interest in intestinal spirochaetes has been sporadic. Saenz (1925) drew attention to dysentery-like diseases associated with spirochaetes and responding only to treatment with arsenicals. Sanarelli (1927) claimed that spirochaetes are responsible for guinea-pig diarrhoea. Mazza (1930) found spirochaetes morphologically identical to an organism called *Spirochaeta eurygyrata* (Werner, 1909; Hogue, 1922) in 9.6% of appendices removed because of appendicitis-like symptoms. Hurst and Vollum (1943) encountered a case of

ulcerative colitis associated with Vincent's organisms. More recently Shera (1953 and 1962) has also incriminated Vincent's organisms in a series of patients with colonic symptoms and characteristic sigmoidoscopic appearances ('the strawberry lesion'). This disease appeared to be related to vitamin C deficiency and responded to arsenical therapy. Thomas (1956) described a similar case, but there have been no further reports of this condition.

In a recent study, organisms with the morphological features of spirochaetes have been observed, both with the electron microscope and the light microscope, attached to the surface of the colonic epithelium (Harland and Lee, 1967). An identical case has since been reported (Gear and Dobbins, 1968). Further details of this phenomenon, which we have called 'intestinal spirochaetosis', are now presented.

Methods and Materials

ELECTRON MICROSCOPY

The original material was obtained from a rectal biopsy of a patient with diarrhoea. Representative portions of the biopsy were diced into small fragments, fixed immediately in 1% osmium tetroxide in phosphate buffer at pH 7.4 and embedded in Araldite. The sections were examined with a Siemens Elmiskop 1A electron microscope. The remainder of the biopsy was fixed in 10% formalin for routine histological processing. Later a series of 10 rectal biopsies initially processed for histology were examined under the electron microscope. Small fragments of tissue were excised from the paraffin wax in which they had been stored. The wax was removed with chloroform and the tissue postfixed in buffered osmium tetroxide and processed as before. Negatively stained preparations of material from a rectal swab on the original patient were also examined.

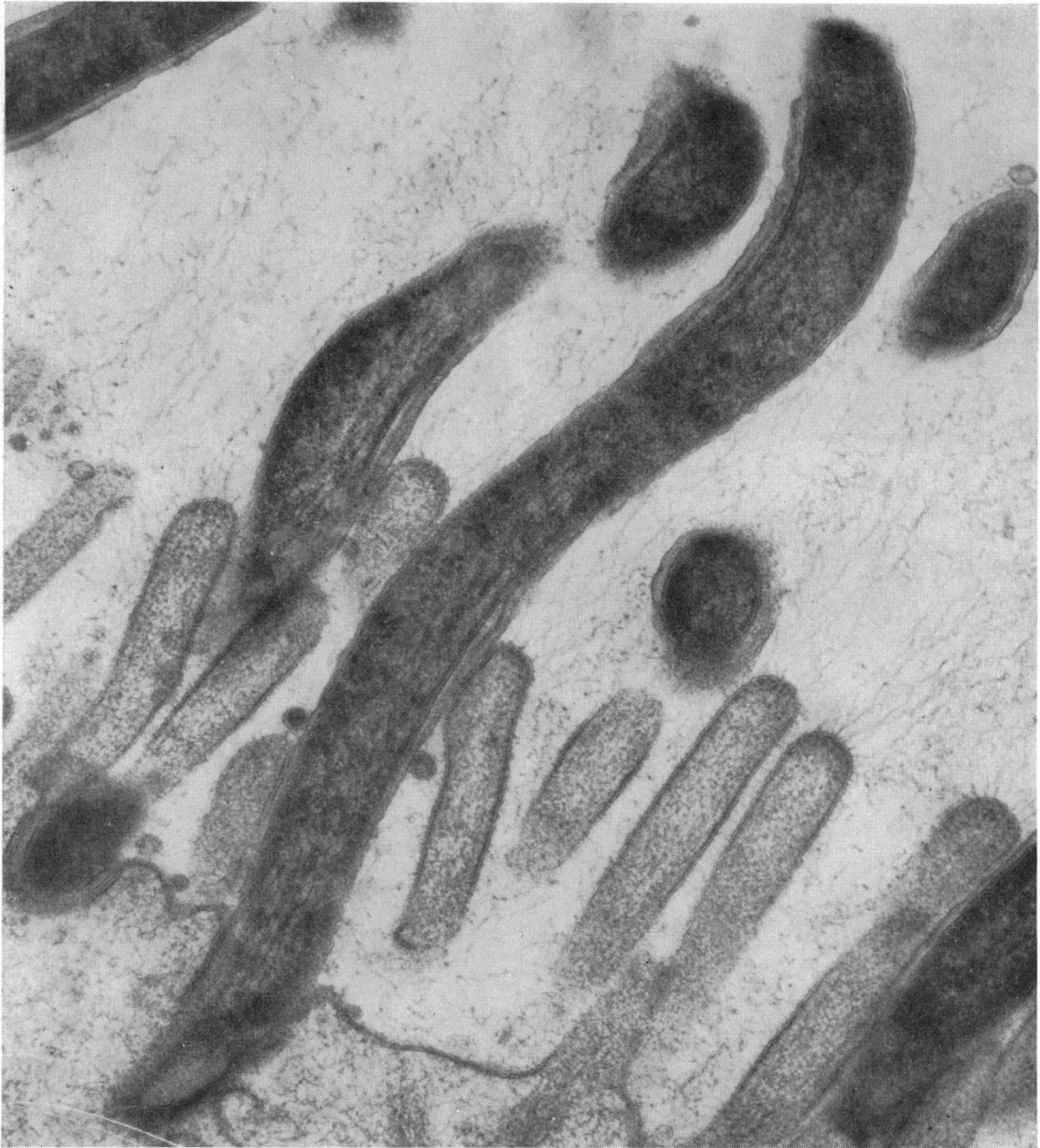

Fig. 1 *Electron micrograph showing spirochaetes between the microvilli of the colonic epithelium. ×75,000.*

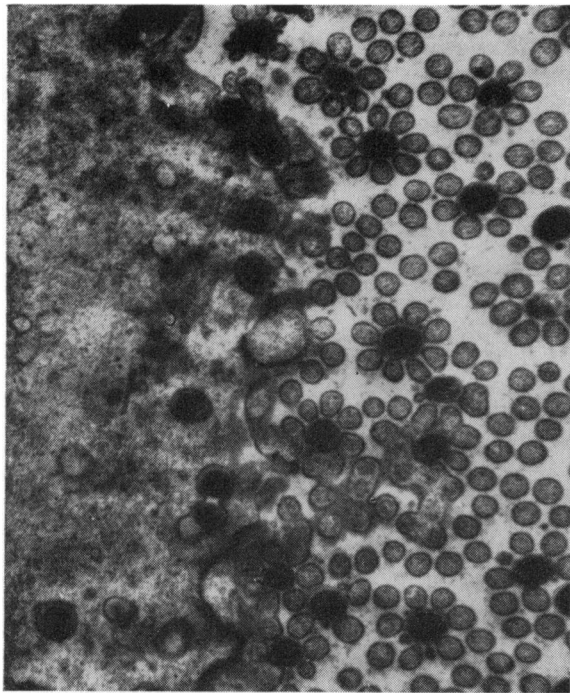


Fig. 2a

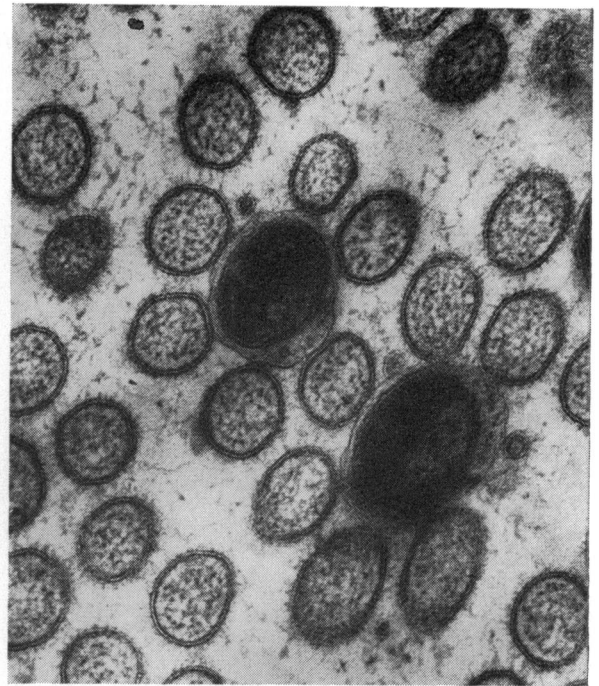


Fig. 2b

Fig. 2 *Transverse sections show 'rosette formation' with spirochaetes surrounded by microvilli a. $\times 8,000$. Note the indentation of the epithelial cell membrane by organisms b. $\times 20,000$. The spiral filaments are visible on section.*

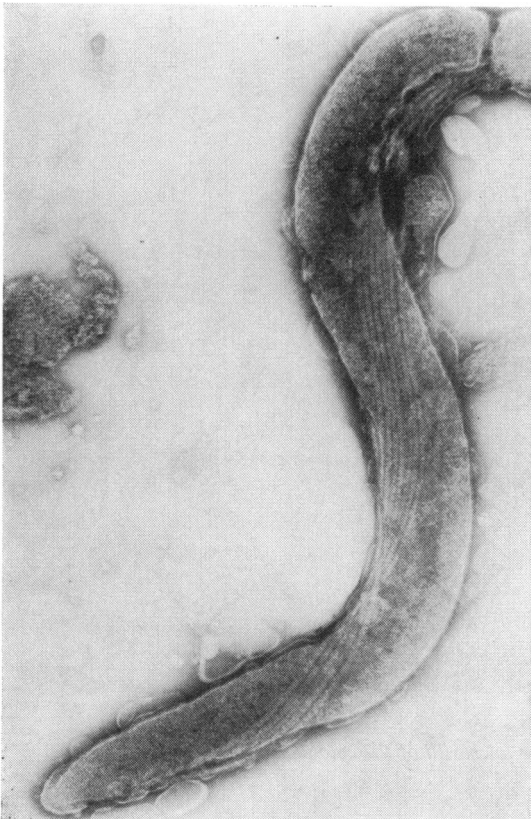


Fig. 3

Fig. 3 *Negatively stained electron micrograph of organism obtained from rectal swab from the same case, showing typical structure of a spirochaete. $\times 40,000$.*

Fig. 4 *Photomicrograph (haemalum-eosin section) showing the haematoxyphilic zone in the region of the brush border of colonic mucosa.*

Fig. 5 *Photomicrograph showing silver staining of the organisms on the colonic surface.*

Fig. 6 *Electron micrograph on formalin-fixed tissue embedded in paraffin wax confirming that the organisms seen by the light microscope were spirochaetes. $\times 50,000$.*

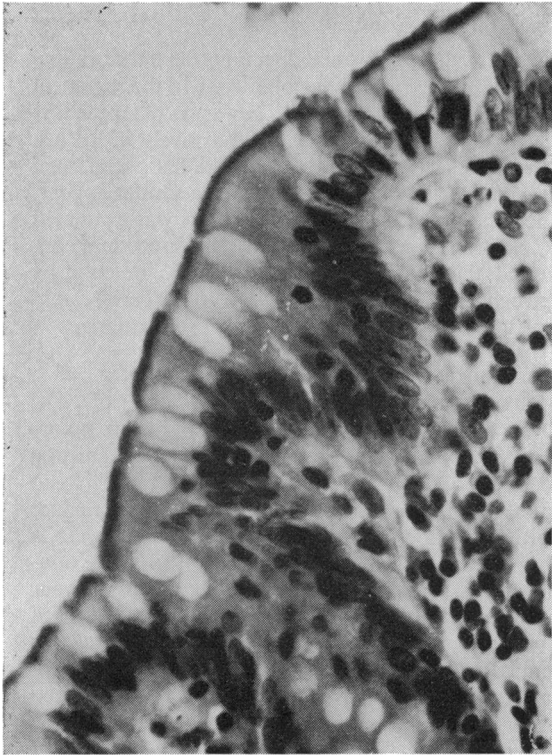

Fig. 4

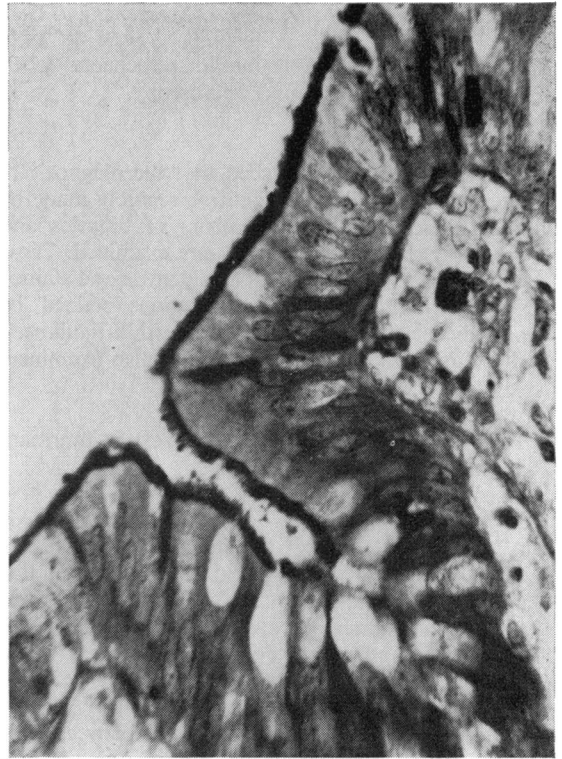

Fig. 5

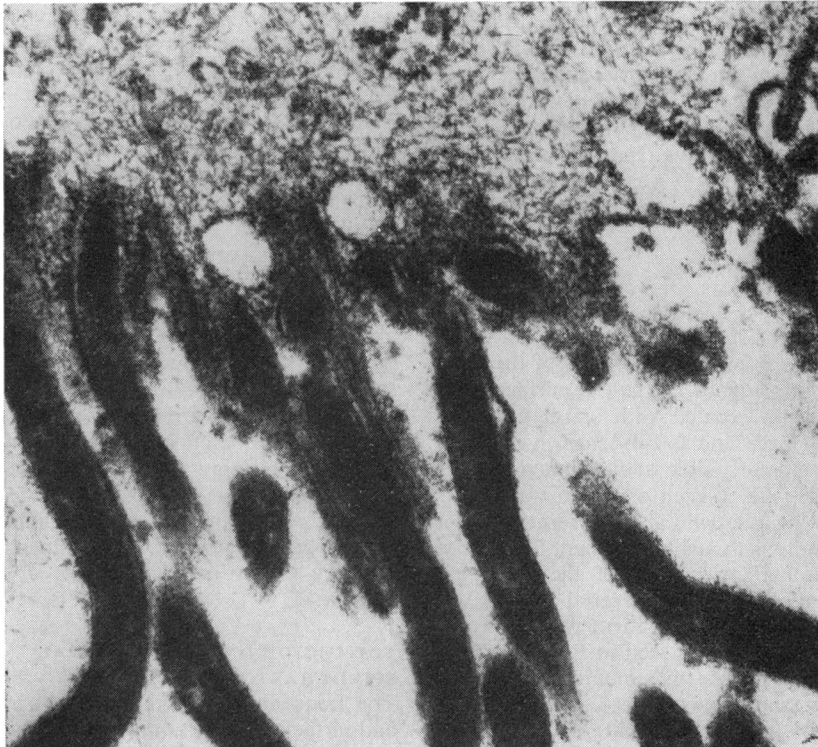


Fig. 6

This had shown actively motile spirochaetes when examined by dark ground microscopy.

LIGHT MICROSCOPY

Once it had been established that the diagnosis of intestinal spirochaetosis could be securely made by light microscopy, large numbers of biopsies and surgically resected specimens were examined. These had all been fixed in 10% formaldehyde and stained with haemalum and eosin. Sections stained by periodic acid-Schiff (PAS) and Warthin-Faulkner's silver impregnation technique were also examined.

MATERIALS

Two groups of material from the Western Infirmary in Glasgow were studied.

Rectal or colonic biopsies

All 144 rectal biopsies taken in 1961 were reviewed. These covered a wide clinical spectrum, including neoplasm, ulcerative colitis, Crohn's disease, diverticulitis, haemorrhoids, etc. There were 70 females and 74 males, the mean age being 54 years.

Vermiform appendix

All 790 appendices surgically excised between 1963 and 1966 were reviewed. On clinical grounds they were divided into three groups. (1) The control group of 107 cases (76 females and 31 males) in which the appendix had been removed incidentally during some other surgical procedure, eg, cholecystectomy. (2) Simulated appendicitis: a group of 523 patients (169 males and 356 females) who had an appendicitis-like illness but no histological evidence of appendicitis. (3) A group of 160 patients with histologically proven acute appendicitis (96 males and 64 females).

Results

The electron microscopic appearances of the initial biopsy are seen in Figure 1. The free surface of the epithelial cells was coated with spiral organisms 3 microns in length and 0.2 microns in diameter. Axial filaments were visible at high magnification. In cross section (Fig. 2) each organism was seen to be surrounded by microvilli giving a rosette appearance. This feature is thought to account for the consistent longitudinal orientation of the organisms. Organisms demonstrated in material obtained by rectal swabs from the same patient were of similar dimensions. An example is seen in Figure 3. These were spirochaetes with a maximum of seven components in the axial filaments.

Examination under the light microscope of

haematoxylin-eosin-stained sections from the original biopsy revealed a distinct blue zone in the region of the brush order (Fig. 4). This zone was blackened by silver stains (Fig. 5) and stained positively with PAS. It was realized that this appearance had been seen previously, and in 10 cases showing a similar appearance, the tissue stored in paraffin wax was examined by electron microscopy (Fig. 6). This procedure confirmed that infestation of the colonic mucosa by spirochaetes could be recognized from the histological appearance, even on routine preparations.

HISTOLOGICAL FEATURES IN INTESTINAL SPIROCHAETOSIS

Over 70 cases of rectal and appendicular spirochaetosis were examined and certain interesting features of the condition emerged. Spirochaetal infestation was strictly limited to the surface epithelium and seldom extended for more than a short distance into the crypts (Fig. 4). Only non-neoplastic epithelium was affected; in tumour biopsies it was noted that spirochaetal growth ceased abruptly at the point of neoplastic transformation and never extended onto tumour epithelium. It is of interest, however, that spirochaetal growth has been observed on the epithelial surface of a metaplastic polyp. There was no evidence of a specific cellular pattern in the affected colonic mucosa with no obvious leucocytic or vascular changes and no increase in mucus secretion.

Although it was not possible to estimate the extent of spirochaetal infestation, there was indirect evidence that the condition might be quite extensive. Thus the condition was found in the appendix and subsequently in a rectal biopsy from the same patient, and on several occasions in two or more rectal or colonic biopsies from the same patient.

There was evidence that spirochaetosis may persist for considerable periods of time. In one patient two rectal biopsies taken five months apart and in another five rectal biopsies taken over a period of six years all showed clear evidence of spirochaetosis.

It is of some interest that, so far, spirochaetosis has only been demonstrated in specimens obtained by appendicectomy and rectal biopsy. In neither of these procedures is bowel sterilized with antibiotics as a routine and may explain the absence of these organisms in resected specimens, even if preliminary biopsy had shown the condition to be present.

THE INCIDENCE OF INTESTINAL SPIROCHAETOSIS

The frequency of spirochaetosis in rectal biopsies and in the appendix is recorded in Tables I, II, and

III. It is apparent that this condition is by no means uncommon in the west of Scotland. Spirochaetosis was found in 6.9% of rectal biopsies. The incidence was slightly higher in tumour cases than in non-tumour cases, but the difference was not statistically significant ($P < 0.1$). It should be noted that most of the patients in the rectal biopsy series come from the older age groups (Table I).

	Total No. of Cases	Age in Years (mean \pm SD)	No. with Spirochaetosis	Incidence of Spirochaetosis (%)
All rectal biopsies	144	54.0 \pm 18.3	10	6.9
Non-tumour cases	70	46.3 \pm 17.5	3	4.3
Tumour cases	74	61.2 \pm 12.9	7	9.5

Table I Incidence of spirochaetosis in rectal biopsies taken in one year (1961)

In contrast, the great majority of appendectomies were carried out in patients below the age of 40 years (Table II) and the overall incidence of spirochaetosis in the appendix was 7.8%. Spirochaetosis was most often found in the 'simulated' appendicitis group and reached its highest incidence in the third and fourth decades (Tables II and III).

Group	Total No. of Cases	Age in Years (mean \pm SD)	No. with Spirochaetosis	Incidence of Spirochaetosis (%)
All appendices	790	27.7 \pm 15.8	62	7.8
'Simulated' appendicitis	523	25.9 \pm 13.6	51	9.8
Acute appendicitis	160	28.0 \pm 15.1	7	4.4
Incidental appendectomy	107	35.9 \pm 19.0	4	3.7

Table II Incidence of spirochaetosis in the appendix

Case	Sex	Age	Complaint	Duration of Symptoms	Clinical Diagnosis
1	M	64	Diarrhoea	3 yr	?
2	M	52	Mucoid diarrhoea	2-3 dys	Carcinoma of colon
3	M	49	Diarrhoea	4 wk	?
4	F	19	Abdominal pain	18 mth	Appendicitis, haemorrhoids
5	F	64	Constipation	5 yr	Carcinoma of colon
6	M	56	Rectal bleeding	6 mth	Haemorrhoids
7	M	56	Rectal bleeding	8 mth	Carcinoma of colon
8	M	60	Intermittent rectal bleeding	1 yr	Multiple adenomatous polyp, carcinoma of colon
9	M	61	Rectal bleeding	2 yr	Haemorrhoids, adenomatous polyp of colon
10	M	63	Diarrhoea	2 wk	Carcinoma of colon
11	F	62	Rectal bleeding	1 yr	Carcinoma of colon
12	M	75	Congestive cardiac failure, rectal bleeding	1 wk	Ischaemic colitis
13	M	55	Diarrhoea and rectal bleeding	Many years	Ulcerative colitis, carcinoma of rectum
14	M	45	Rectal bleeding	3 mth	Metaplastic polyp

Table IV Clinical diagnosis in 14 cases of intestinal spirochaetosis diagnosed by rectal biopsy

	All Cases	Age (yr)				
		10-20	20-30	30-40	40-50	50+
All cases	523	238	141	69	31	44
Spirochaetosis	51	12	17	12	3	7
Percentage	9.8	5.0	12.5	17.4	9.7	15.9

Table III Age incidence of spirochaetosis in 'simulated' appendicitis

Despite the great predominance of females in this group there was no significant sex difference in incidence. The patients with 'acute appendicitis' also came mainly from the younger age groups, and here the incidence was considerably lower. It is notable that spirochaetosis was least common in the control group of appendectomies, the incidence being comparable to that observed in non-tumour rectal biopsies, and that most of patients in this control group come from the older age groups. Spirochaetosis thus appeared to be especially common in young adults and the incidence tended to decrease with age (Table III).

CLINICAL ASPECTS

We have now studied 14 cases of spirochaetosis diagnosed by rectal biopsy. The clinical diagnoses in these cases are recorded in Table IV. It is apparent that, with two exceptions, the symptoms in each case could be readily attributed to the underlying disease, usually tumour (eight cases). Simple haemorrhoids (two cases), metaplastic polyp (one case), and ischaemic colitis (one case) are other conditions with which spirochaetosis was associated. There was no evidence of spirochaetosis in the 16 cases of ulcerative colitis in the rectal biopsy series, although it is of interest that this combination has been observed in case 13 in which ulcerative colitis was complicated by anaplastic rectal carcinoma.

In two patients, males aged 49 years and 64 years,

diarrhoea was the presenting complaint, although no organic cause for this was found. It is unfortunate that both patients, one of whom was a Pathan seaman, were lost to follow up, since it is possible that they were suffering from 'spirochaetal dysentery'. It is notable that in neither of these cases, nor in any of the other cases of rectal spirochaetosis, was there any sigmoidoscopic abnormality that could be attributed to spirochaetal growth.

Review of the clinical records of the cases of appendicular spirochaetosis failed to reveal any symptoms or clinical feature which distinguished these cases from comparable appendicectomy cases without spirochaetosis. Further attention was nevertheless focused upon the 'simulated appendicitis' group, in which there was an unusually high incidence of spirochaetosis. A follow-up study carried out on the patients in this group by one of us (J.G.R.H.) did not show any significant difference in the clinical cure rate between patients with or without spirochaetosis, the rate in both groups being of the order of 85%.

Discussion

It is clear from this study that spirochaetes frequently colonize the surface epithelium of the large bowel and that this phenomenon, which we have called 'intestinal spirochaetosis', can be readily recognized in routine histological preparations as a haematoxyphilic zone about 3 microns in thickness occupying the site of the luminal brush border.

In view of the frequency with which spirochaetes have been detected in the human alimentary tract, it is surprising that the histological lesion in the large bowel which we first described (Harland and Lee, 1967) had not been previously reported. It is true that Doenges (1939) demonstrated an almost identical lesion in 43% of human stomachs at necropsy and suggested an association with carcinoma but these observations were not extended to the colon and the possibility of postmortem artefact could not be excluded. It seems probable, however, that the 'haematoxyphilic zone' characteristic of spirochaetal growth in the large bowel has been observed often enough in the past but has been misinterpreted as artefactual in nature.

The identity of the organisms colonizing the surface epithelium of the large bowel cannot be established with certainty without cultural or serological studies. However, there is no doubt that the organisms are spirochaetes and the ease with which they are stained with haematoxylin and eosin and PAS indicates that they should be classified with the *Borrelia* rather than the *Treponemata*. Further support for this is provided by electron microscopic appearance

(Swain, 1955). It is to be noted that there is no evidence that Vincent's fusiform bacilli are associated with this entity nor is there any obvious relationship to the disease described by Shera (1963).

From the evidence that has been presented it appears unlikely that intestinal spirochaetosis has any serious pathological importance. A possible exception to this general statement is the first case we described (Harland and Lee, 1967) in which the patient suffered from severe mucoid diarrhoea without any obvious cause apart from spirochaetosis. A second, less well investigated case, may also fall into this category. These indeed may be examples of 'spirochaetal dysentery' as described by le Dantec (1906) and Werner (1909). Apart from this, spirochaetosis of the distal large bowel has not been correlated sigmoidoscopically with any specific pathological appearance. Carcinoma is the lesion most often associated with spirochaetosis, but it can also be found in association with haemorrhoids and ischaemic colitis.

It is of interest that the overall incidence of spirochaetosis was 9.8% in patients with appendicitis-like symptoms. This is very close to the incidence with which spirochaetes were isolated from the appendix in a similar group of patients (Mazza, 1930). However, it seems unlikely that the organisms were responsible for the symptoms because we were unable to distinguish any difference in clinical course and ultimate prognosis between affected and unaffected cases.

References

- Dantec, le (1903). Dysenterie spirillaire. *C.R. Soc. Biol. (Paris)*, **55**, 617.
- Doenges, J. L. (1939). Spirochetes in the gastric glands of *Macacus Rhesus* and of man without related disease. *Arch. Path.*, **27**, 469-477.
- Escherich, T. (1884). Klinisch-therapeutische Beobachtungen aus der Cholera-Epidemie in Neapel. *Arztl. Intell.-Bl.*, **31**, 561-564.
- Escherich, T. (1886). Beiträge zur Kenntniss der Darmbacterien. *Münch. med. Wschr.*, **33**, 815 and 833.
- Fantham, H. B. (1916). Observations on *Spirochaeta eurygyrata* as found in human faeces. *Brit. med. J.*, **1**, 815-816.
- Gear, E. V., Jr., and Dobbins, W. O. III. (1968). Rectal biopsy: a review of its diagnostic usefulness. *Gastroenterology*, **55**, 522-544.
- Harland, W. A., and Lee, F. D. (1967). Intestinal spirochaetosis. *Brit. med. J.*, **3**, 718-719.
- Hogue, M. J. (1922). *Spirochaeta eurygyrata*. *J. exp. Med.*, **36**, 617-626.
- Hurst, A., and Vollum, R. L. (1943). Ulcerative colitis caused by Vincent's organisms. *Guy's Hosp. Rep.*, **92**, 118-120.
- Kuisl, M. (1885). Beiträge zur Kenntniss der Bacterien im normalen Darmtractus. *Arztl. Intell.-Bl.*, **32**, 433 and 454.
- Macfie, J. W. S. (1917). The prevalence of *Spirochaeta eurygyrata* in Europeans and natives in the Gold Coast. *Lancet*, **1**, 336-340.
- Mazza, S. (1930). Espiroquetosis apendiculares. *Pren. méd. argent.*, **17**, 464-468.
- Parr, L. W. (1923). Intestinal spirochetes. *J. infect. Dis.*, **33**, 369-383.
- Sanarelli, G. (1927). Les spirochètes caecaux. *Ann. Inst. Pasteur*, **41**, 1-44.
- Sáenz, A. (1925). Espiroquetosis intestinal pura. Reinsta general. Su estudio en el Uruguay. *An. Fac. Med. Montevideo*, **10**, 621-672. Abstracted in *J. Amer. med. Ass.* (1926), **86**, 916.

- Shera, A. C. (1953). A syndrome associated with intestinal Spirochaetosis. *J. clin. path.*, 6, 327-328.
- Shera, A. G. (1962). Specific granular lesions associated with intestinal spirochaetosis. *Brit. J. Surg.*, 50, 68-77.
- Swain, R. H. A. (1955). Electron microscopic studies of the morphology of pathogenic spirochaetes. *J. Path. Bact.*, 69, 117-128.
- Thirolaix, J., and Durand, F. (1911). Spirochetemie au cours d'une appendicite aigue. *Bull. Soc. Méd. (Paris)*, 31, 653-662.
- Thomas, G. K. (1956). 'Strawberry lesion' of the recto-sigmoid. *Brit. med. J.*, 2, 209-211.
- Thomson, J. G., and Thomson, D. (1914). Some researches on spirochaetes occurring in the alimentary tract of man and some of the lower animals. *Proc. roy. Soc. Med.*, (Gen. Rep. Soc.) 7, 47-70.
- Werner, H. (1909). Über Befunde von Darmspirochäten beim Menschen. *Zbl. Bakt., Abt. I. Orig.*, 52, 241-243.