

The dynamic structure of a flat small intestinal mucosa studied on the explanted rat jejunum

C. A. LOEHRY AND R. GRACE

From the Royal Victoria Hospital, Bournemouth, and St Thomas' Hospital, London

SUMMARY Small pieces of jejunum with an intact blood supply were explanted to the anterior abdominal wall in rats. Six weeks after explantation the mucosa appeared totally flat in many areas, both histologically and under the dissecting microscope. The structure of the flattened mucosa was shown to be identical to that in coeliac disease with hypertrophied intervillous ridges. A dynamic study with tritium-labelled thymidine demonstrated a considerably increased turnover in the flat mucosa with some disorganization of cell production and migration.

In the normal small intestinal mucosa delicate intervillous ridges have been demonstrated running between adjacent crypts and joining up onto villi, and it is likely that these structures represent the normal migration lines of epithelial cells. It has been shown that it is the hypertrophy of these intervillous ridges that provides the structural basis for the evolution of mucosal patterns in disease states (Loehry and Creamer, 1969a), and it has been experimentally demonstrated that the final three-dimensional structure of the mucosa is determined by its dynamic state (Loehry and Creamer, 1969b). From these experiments it was considered likely that the flat mucosa typified in the coeliac syndrome was the result of a 'haemolytic' change in epithelial cell dynamics with a primary increase in cell loss causing shortening of the villi, and a compensatory increased cell production in the crypts causing hypertrophy of the intervillous ridges to form a convoluted and flattened structure.

In order to test this hypothesis further experiments were undertaken to study the changes in both mucosal structure and in mucosal dynamics in a situation where there was a primary increase of cell loss from the small intestinal mucosa. For this reason explanted rat jejunum has been studied, as here the mucosa is subject to continuous external trauma and increased cell loss.

Methods

OPERATIVE METHOD

Albino rats weighing between 250 and 300 g were used. Under nembutal anaesthesia the abdomen was

Received for publication 26 February 1974.

opened by a midline incision. A length of jejunum between 3 and 4 cm which had at least one main vessel leading to it was selected and isolated and the small bowel anastomosed together. The explant with its blood supply was then brought through the anterior abdominal wall using a stab incision to the left of the midline. An area of skin was excised from the anterior abdominal wall and the explant opened along its anti-mesenteric border and sutured in its place, the mucosal surface uppermost. The abdomen was closed and the animals were allowed to recover.

SAMPLING OF SPECIMENS

Three pairs of rats were killed at one, three, and six weeks after operation and the explants removed and divided in half. One half was placed directly into 10% formalin and the other allowed to autolyse for 24 hours and then cleaned and fixed (Loehry and Creamer, 1969a). Specimens were studied through the dissecting microscope. Samples for histology were taken from the immediately fixed tissue and stained with haematoxylin and eosin.

DYNAMIC STUDIES

Mitotic counts

Mitotic counts were done at a magnification of $\times 270$ with a binocular microscope. Two thousand crypt cells were counted in specimens of the explanted mucosa and from the control jejunum. Mitotic activity was expressed as the number of mitoses per 1000 cells.

Autoradiographic studies

Eight male rats with six-week-old explants and eight

controls of similar weight received an intraperitoneal injection of 300 μg of tritium-labelled thymidine. Pairs of explanted animals and controls were killed at one, three, five, nine, 12, 15, 24, and 48 hours after injection. Specimens of jejunum were taken from the controls and from the explanted animals; the explant and specimens of jejunum were fixed in 10% formalin and autoradiographs performed.

Results

HISTOLOGICAL CHANGES

Histological sections taken from the explanted jejunum showed progressive shortening and blunting of villi, with lengthening of the crypts until, at six weeks, the mucosa appeared almost totally flat (fig 1). These changes were consistently seen in all the explants. The overall thickness of mucosa was not greatly reduced as the average thickness of the explanted mucosa was 600 μm of which 90% was made up of crypt and 10% of villous structures. The control mucosal height was 650 μm made up of 20% of crypt cells and 80% of villous cells. The outer surface of the mucosa was covered in many places by a layer of desquamated epithelial cells and the tops of the shortened villi often showed evidence of trauma. The mucosal changes were often patchy in nature with flattened areas adjacent sometimes to more normal looking villi. The more prominent areas showed the most severe changes whereas in the depths of the troughs the histology appeared almost normal (fig 2).

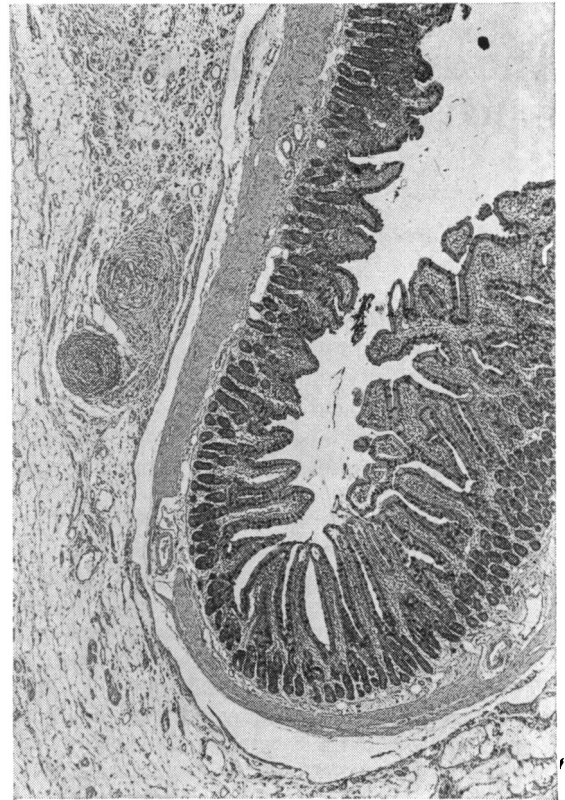


Fig 2 A six-week explant demonstrating a flattened mucosa on the crest and more normal villi in the protected fold. $\times 42.5$.

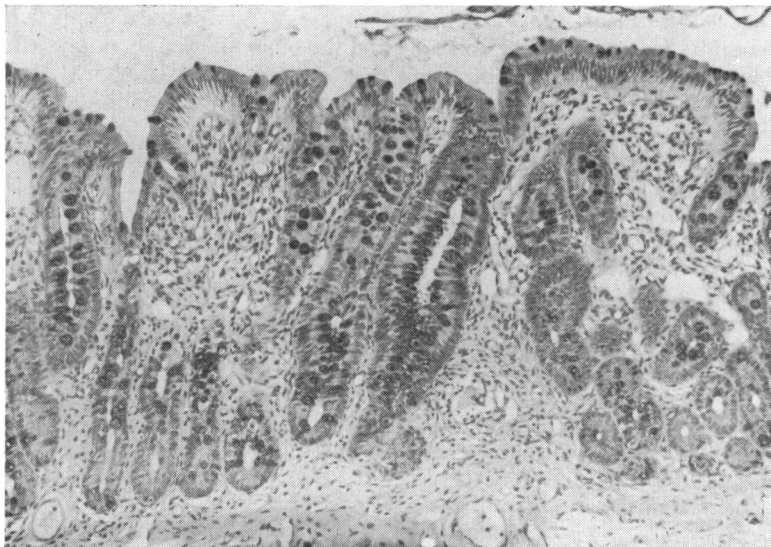

Fig 1 A 'flat' mucosa from a six-week old explant. $\times 170$.

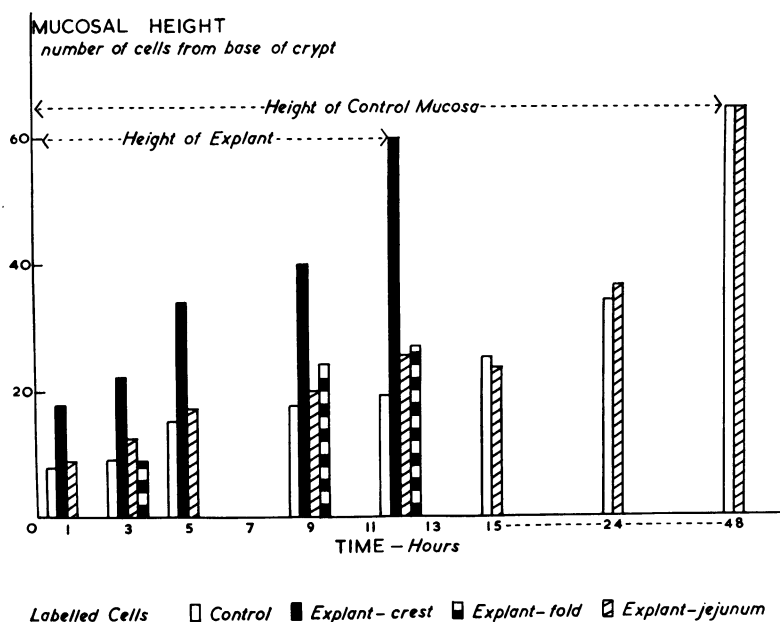


Fig 3 Representation of the height of the labelled cell column in the explant (crests and folds) in the jejunum of the explanted animals and in normal control rats.

STRUCTURAL CHANGES

Explants examined under the dissecting microscope at one and three weeks after operation showed several areas where the villi had broadened and fused into convolutions, though a more normal appearance was still apparent in the more protected part of the explant. At six weeks many areas were totally flat, and in appearance closely similar to the mucosa in coeliac disease. After autolysis it was shown that the flattened mucosa was made up totally of hypertrophied intervillous ridges which had become taller and broader to incorporate villous structures.

DYNAMIC CHANGES

Mitotic activity

The mitotic activity in the explanted mucosa was 510

mitoses per 1000 crypt cells with a control mitotic activity of 250 mitoses per 1000 crypt cells in the normal mucosa.

Autoradiographic studies

These are illustrated in fig 3 which demonstrates the height of the labelled cell column in the control jejunum, in the flat mucosa of the explant, both at the crests and in the more normal looking villi in the folds. The labelled cell column in the normal jejunum of the explanted rats is also demonstrated. It was apparent that at one hour after injection the height of the labelled cell column in the explant was twice that in the control jejunum and that the difference between the two progressively increased, till at 12 hours the whole of the flattened mucosa, including the elongated crypts and shortened villi,

Explant No.	Time after Injection of Labelled Thymidine				
	One to Three Hours	Three to Five Hours	Five to Nine Hours	Nine to 12 Hours	
Explants	1	50 μm	120 μm	60 μm	200 μm
	2	30 μm	90 μm	82 μm	100 μm
	3	28 μm	80 μm	79 μm	120 μm
	4	70 μm	80 μm	90 μm	100 μm
Controls	1	40 μm	60 μm	20 μm	70 μm
	2	60 μm	40 μm	30 μm	60 μm
	3	70 μm	50 μm	50 μm	80 μm
	4	30 μm	20 μm	60 μm	60 μm

Table I Progression of labelled epithelial cells after the injection of tritium-labelled thymidine in four jejunal explants and in the jejunum of four control rats¹

¹The rate of progression in the explanted group is statistically significant at the 1% level.

showed labelling. By 15 hours the explanted mucosa was labelled largely near the crypt mouth or on the shortened villi, and by 24 hours only occasional labelling was seen. The table demonstrates the migration rate of the labelled cells in the explanted and control mucosa and shows the greatly increased turnover time in the explant. It was also apparent that in the explant labelling was a more patchy process than in the controls, and labelled cells were sometimes seen near the surface of the mucosa followed by a series of cells without evidence of radioactivity with labelling again at the crypt base. In the three places where structurally normal looking villi were demonstrated in a fold of the explant (three-, nine-, and 12-hour rats) the labelled cell column was the same as in the controls, and the normal jejunum of the explanted animals had the same turnover as in the control rats.

Discussion

Previous authors have demonstrated changes in the small intestinal mucosa explanted to various abnormal sites. Joseph (1960) showed that columnar epithelial cells had disappeared after explantation of ileum to the ear in rabbits. Zetterlund (1962) demonstrated flattening of the mucosa in segments of small intestine transplanted to the anterior abdominal wall in rats. Stephens, Finckh, and Milton (1964) explanted duodenum to the abdominal wall in dogs and noted flattening of the mucosa six weeks after explantation with gradual reversion to normal after the explant had been covered with skin flaps and protected from external trauma. Watson, Watson, and Walker (1965) have also demonstrated 'partial villous atrophy' after pieces of ileum had been transplanted to the colon in rats.

In addition to these experiments several authors have demonstrated flattening of the mucosa both in experimental animals and in man where segments of small intestine have been used as a urinary conduit (Joseph and Thomas, 1958; Rattner, Moran, and Murphy, 1959; Goldstein, Melamed, Grabstald, and Sherlock, 1967). The development of the mucosal changes in all these situations depends on the exposure of the mucosa to an abnormal environment, where increased trauma might be expected to affect the epithelium, and Townley, Cass, and Anderson (1964) have shown similar changes in loops of jejunum in the dog after repeated instillation of a dilute acid.

The histological results in the present experiments confirm the findings by previous investigators in that the appearance of the mucosa becomes very similar to that seen in coeliac disease with absent villi and long hyperplastic crypts. The changes in the three-dimensional mucosal structure, however, have not

previously been well documented and only Watson *et al* (1965) have demonstrated a convoluted-looking ileum after transplantation to the colon. In this study we have shown how the appearance of the flattened mucosa under the dissecting microscope closely resembles that in human disease, and how after autolysis the structure is seen to be made up of hypertrophied intervillous ridges that have been shown to be responsible for the structural characteristics in coeliac disease (Loehry and Creamer, 1969a). The dynamics of this structure identical to that in human disease is therefore of interest, and in previous studies we have suggested that a 'haemolytic'-like change in mucosal dynamics is responsible for the production of flat mucosa (Loehry and Creamer, 1969b). In the present study we have no direct evidence of an increase in cell loss, but the situation of the explants and the histological appearance of trauma to the tips of the villi are strong indirect evidence that cells are being lost at a faster rate than normal. Certainly in a previous study where similar mucosal changes were induced in the rat using the nematode *Nippostrongylus brasiliensis* considerably increased cell loss was directly demonstrated (Loehry and Creamer, 1969b).

The experiments with tritium-labelled thymidine demonstrate a considerably increased turnover of epithelial cells in the flattened mucosa, and it seems likely that this increase in cell production was a reaction to the increased loss in the abnormal environment. It is interesting that this increased turnover state appears to be a purely 'local' reaction at the sites where the mucosa is most exposed and that where there were normal villi in protected folds the turnover was normal. Certainly there was no evidence of any circulating stimulus to cell turnover as the normal jejunum in the explanted animals had a normal turnover time. It is of interest that the progression of labelled cells in the explanted mucosa appeared uneven because the crypt cell column often appeared to be labelled in a patchy fashion with areas of unlabelled cells between groups that contained radioactivity. This would suggest that there had been some disorganization of cell production and migration in the flattened mucosa, and that some cells had undergone rapid division and migration, but others had remained dormant. It is theoretically possible that other factors apart from trauma were important in the causation of the changes in the explant, such as impairment of blood supply, but this is unlikely in view of the findings of Stephens *et al* (1964) who demonstrated that the flattened mucosa of an explant reverts to normal simply by protecting it from external trauma.

If, as we believe likely, the 'haemolytic'-like change in mucosal dynamics is applicable to the flat mucosa of coeliac disease, several interesting factors may be

considered. First, there is the possibility that with the increased cell loss there may be a parallel increase in the loss of intracellular substances which the abnormal mucosa may be unable to reabsorb. We have demonstrated increased iron loss in the flattened rat mucosa (Loehry, Croft, Singh, and Creamer, 1969) and the loss of other substances is under investigation. Secondly, as well as the obvious loss of absorptive surface area in the flat mucosa due to loss of villi, a considerably increased turnover would result in each epithelial cell being available for a shorter period for its absorptive function, and it is possible that some of the cells may still be functionally immature when they reach the crypt mouth. Finally, if there is some disruption of epithelial cell production, as this study suggests, it is possible that many cells may never be fully available for absorption, although the functional capability of these cells remains still to be investigated.

We are grateful to the Research Committee of the Wessex Regional Hospital Board and Endowment Fund of St Thomas' Hospital for providing funds that have made this study possible.

References

- Goldstein, M. J., Melamed, M. R., Grabstald, H., and Sherlock, P. (1967). Progressive villous atrophy of the ileum used as a urinary conduit. *Gastroenterology*, **52**, 859-864.
- Joseph, J. (1960). Autograft of ileum and lining of urinary bladder to the ears of rabbits. *Plast. reconstr. Surg.*, **25**, 27-38.
- Joseph, J., and Thomas, G. A. (1958). The behaviour of autographs of ileum transplanted into the urinary bladder in rabbits. *J. Anat. (Lond.)*, **92**, 551-558.
- Loehry, C. A., and Creamer, B. (1969a). Three dimensional structure of the human small intestinal mucosa in health and disease. *Gut*, **10**, 6-12.
- Loehry, C. A., and Creamer, B. (1969b). Three dimensional structure of the rat small intestinal mucosa related to mucosal dynamics. *Gut*, **10**, 112-120.
- Loehry, C. A., Croft, D. N., Singh, A. K., and Creamer, B. (1969). Cell turnover in the rat small intestinal mucosa: an appraisal of cell loss. *Gut*, **10**, 13-18.
- Rattner, W. H., Moran, J. J., and Murphy, J. J. (1959). The histologic appearance of small bowel segments as urinary conduits. *J. Urol.*, **82**, 236-239.
- Stephens, F. O., Finckh, E. S., and Milton, G. W. (1964). Changes in exteriorized duodenal mucosa. Loss of villi, with recovery after skin coverage of explant. *Gastroenterology*, **47**, 626-630.
- Townley, R. R., Cass, M. H., and Anderson, C. M. (1964). Small intestinal mucosal patterns of coeliac disease and idiopathic steatorrhoea seen in other situations. *Gut*, **5**, 51-55.
- Watson, A. J., Watson, J. W., and Walker, F. C. (1965). The behaviour of pedicle autograft of ileum transplanted into the colon in the rat. *Amer. J. Path.*, **46**, 553-565.
- Zetterlund, C. G. (1962). Buried strips of intestinal wall: process of healing studied in the rat. *Acta. chir. scand.*, **124**, 467-473.