

Polyposis in ulcerative colitis

R. H. TEAGUE AND A. E. READ

From the University Department of Medicine, Bristol Royal Infirmary, Bristol

SUMMARY One hundred and fifty cases of ulcerative colitis were assessed by total colonoscopy with multiple biopsies. Inflammatory polyposis was found in 25 (17%) cases and six of these had a large (> 1.5 cm) solitary polyp which radiologically resembled carcinoma in four cases. Adenomatous polyps were discovered in four cases. Three carcinomas were found at endoscopy, of which two were entirely unsuspected. In all cases endoscopic polypectomy or surgical intervention was performed to establish the exact histological diagnosis.

Inflammatory polyposis of the large bowel as a complication of ulcerative colitis has been recognized since the beginning of this century. Some authors (Goldgraber and Kirsner, 1957; Dawson and Pryse-Davies, 1959) believed that the polyps were premalignant but today the generally accepted view is that they are a consequence of severe mucosal damage occurring in 10 to 20% of cases (Edwards and Truelove, 1964; Jalan, Sirus, Walker, McManus, Prescott, and Card, 1969).

It is recognized that inflammatory polyposis is most common following severe total colitis, has a positive association with toxic dilatation of the colon and bears no relationship to the chronicity of the disease (Lumb, 1961; De Dombal, 1966; Jalan *et al*, 1969).

Patients Studied

In the present study 150 patients with ulcerative colitis were assessed by total colonoscopy. Two long colonoscopes were used—the ACMI 9000 PL and the Olympus CF-LB with their appropriate light sources and accessories. In each case a visual record was made of the extent and severity of the colitis and this was supplemented by multiple biopsies taken at intervals of 10 cm throughout the colon. In this way the exact extent and severity of the colitis was established and the presence or absence of premalignant change (Morson and Pang, 1967) was recorded.

Total colitis was defined as colitis occurring at all biopsy levels from the caecum to the rectum and was termed 'chronic' when the disease had been present for more than eight years. The term 'partial

colitis' was used for those patients in whom total colitis was not found. The majority of these cases had involvement of the colon distal to the splenic flexure, ie, had left-sided colitis only.

Results

The extent and chronicity of colitis in the patients examined is shown in table I. It will be seen that

Number of colitics examined	150
Chronic colitis > 8 years	54
Total colitics	48
Chronic total colitis	37
Partial colitics (acute and chronic)	102

Table I *Extent and chronicity of colitis*

most of the colitics examined had either acute or chronic partial colitis but a significant proportion (25%) had chronic total colitis and were therefore at risk of developing malignant change (Edwards and Truelove 1964). A careful search was made for the presence of polypoid lesions (table II).

Number of colitics examined	150
Patients with inflammatory polyposis	25 (17%)
Patients with adenomatous polyps	4 (3%)
Patients with carcinoma	3 (2%)

Table II *Types of polypoid change*

This revealed inflammatory polyposis in 17% of cases, adenomatous polyps in 2.7% of cases, and carcinoma in 2%. Thus a total of 23% of the colitics examined had some form of polypoid lesion present.

Three histological types of inflammatory polyp were recognized (Lumb, 1961). The polypoid

mucosal remnants consisted of oedematous, raised areas of mucosa in a previously ulcerated zone. The granulomatous polyp was composed of heaped-up areas of non-epithelialized granulation tissue. Granulation tissue and mucosal remnants made up the mixed type of polyp. This type was often epithelialized macroscopically, resembling an adenoma.

Four adenomatous polyps were discovered in the colitics examined. In each case the exact histology was determined by endoscopic polypectomy.

Three carcinomas were found in the group with chronic total colitis and in each case the carcinoma was accompanied by premalignant mucosal change. In two cases the premalignant change was present at all levels and in one case at all levels excepting the rectum (Evans and Pollock, 1972). In our series premalignant change was never found in association with inflammatory polyposis nor in the absence of carcinoma.

The association of inflammatory polyps with the extent of the colitis is shown in table III. Inflammatory polyposis was most commonly associated with total ulcerative colitis but a common factor in all 25 cases was a history of at least one severe attack of colitis which in most cases necessitated hospital admission. In addition to this toxic dilatation had been diagnosed in two of the 20 cases with total colitis and in one of the five cases in which only left-sided colitis was present.

Number of cases of inflammatory polyposis	25
Cases associated with total colitis	20
Cases associated with left-sided colitis	5

Table III Association of extent of colitis with inflammatory polyposis

At the time of the colonoscopy nine patients were found to have a large, ie, > 1.5 cm, solitary polyp (table IV). The size of the polyps was determined in two ways, first using the ACMI calibration accessory and secondly the previously calibrated opened biopsy forcep blades. In all the polyps removed a good correlation was obtained between the endo-

Number of cases of inflammatory polyposis	25
Cases of solitary inflammatory polyp	6
Number of cases of adenomatous polyp	4
Cases of solitary adenomatous polyp	3

Table IV Types of solitary polyp present

scopically assessed size and that of the resected specimen. Three of the nine cases had a solitary adenomatous polyp and the remaining six had a solitary inflammatory polyp. We were particularly interested in the cases of solitary inflammatory polyp the details of which are shown in table V.

It will be seen that, with the exception of case 6, all patients had chronic total colitis and in all cases the polyps were found distal to the splenic flexure. At barium enema examination four of the cases (cases 1, 3, 4, 5) polyps were mistaken for carcinomas both because of their size and their obvious association with chronic total colitis.

The diagnostic confusion encountered at barium enema in these cases is well illustrated by case 5 of the series—a patient with total colitis which had been present for nine years. This patient had recently experienced a bout of diarrhoea and bleeding per rectum following four years of almost symptom-free disease. The air-contrast film (see fig) shows a suspicious lesion at the splenic flexure. At endoscopy a large polypoid tumour (1.8 cm × 3 cm) was visualized and multiple biopsies were taken. All biopsies showed inflammatory and granulation tissue with no evidence of malignancy but because of the change in the patient's symptoms and the scepticism of the consultant in charge, total colectomy was performed. This confirmed a benign inflammatory polyp consisting mainly of granulation tissue.

In the remaining five polyps a definitive histological diagnosis was established in three cases by endoscopic polypectomy, in one case by colotomy and polypectomy and in one by multiple follow-up biopsies taken over a two-year period. In one (case 3) removal of the polyp resulted in a complete remission of the patient's symptoms of blood and mucus per rectum.

Case No.	Duration of Colitis in Years	Extent	Site	X-ray Diagnosis	Histology	Size (cm)
1	12	Total	Sigmoid colon	Carcinoma	Granulation tissue	2.5
2	10	Total	Descending colon	Normal	Granulation tissue	1.8
3	15	Total	Recto-sigmoid	Carcinoma	Mixed	2
4	15	Total	Sigmoid colon	Carcinoma	Mixed	2
5	9	Total	Splenic flexure	Carcinoma	Granulation tissue	1.8
6	2½	Left sided only	Sigmoid colon	Normal	Polypoid mucosal remnant	1.5

Table V Details of cases of solitary inflammatory polyp

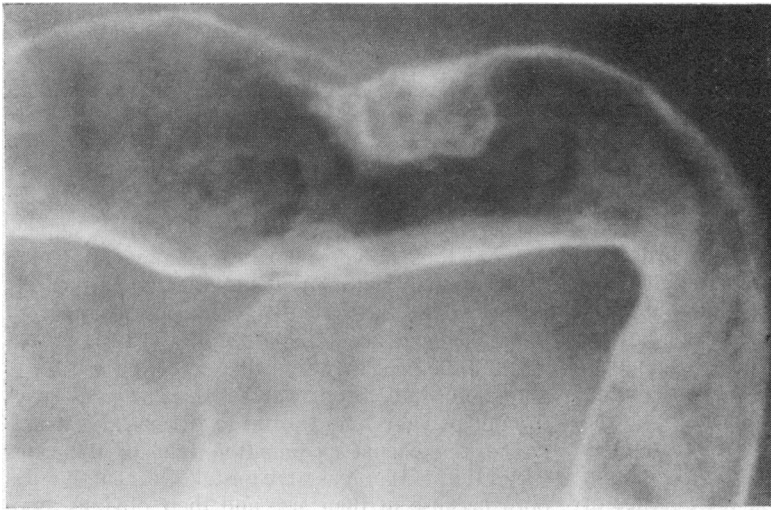


Fig Air-contrast barium enema of case 5

Discussion

In this series we have found the incidence of polyps in patients with ulcerative colitis to be 22%. Four adenomatous polyps were found in the 150 colitics examined and three of these were solitary. This number is too small to attach any significance to their association with the colitis and only one polyp was seen at barium enema examination.

Three carcinomas were discovered and two of these were entirely unsuspected. There would seem to be a considerable diagnostic advantage in colonoscopying all chronic total colitics for the detection of premalignant or malignant change. It is not yet known how rapidly premalignant change becomes frank carcinoma but this is probably a slow process and endoscopy at yearly intervals for the detection of premalignancy may well suffice. In view of the findings of Evans and Pollock (1972), and of our own experience of one case, we believe that biopsy at all levels is necessary for the detection of premalignant change. A complete evaluation of the place of total colonoscopy in chronic colitics is the subject of a later paper (Williams and Teague, 1975).

Inflammatory polyposis was discovered in 17% of the colitics examined. This figure agrees closely with that of the most modern series (Jalan *et al*, 1969). Our findings have confirmed endoscopically that inflammatory polyps are most common in severe total colitis but may be found in left-sided disease only following a particularly severe attack.

The finding of six large solitary inflammatory polyps is, we think, of particular significance. These have not been previously reported and were present in 16% of the group with chronic total colitis. Even

allowing for selection of cases this must still be a relatively common complication and we can only assume that their previous lack of publicity is the result of the reluctance of clinicians to admit that they have removed the colon for a benign lesion. When seen on barium enema there is obvious difficulty in distinguishing the solitary polyps from carcinoma, particularly as they occur in the group of chronic total colitics where malignant change can be expected and they may be giving rise to the patient's symptoms. Their presence in the left colon means that they are easily accessible to sigmoidoscopy or limited colonoscopy (an easy procedure in chronic colitis) and we suggest that before radical surgery is undertaken the possibility of this type of lesion should be considered and steps taken to obtain a tissue diagnosis.

The advent of total endoscopic examination of the bowel in ulcerative colitis means that colectomy can in some cases be avoided or at least delayed until the clinician is sure that the patient would definitely benefit from this procedure.

We would like to thank Dr J. Davies for his assistance with pathology and Miss C. Neumann for skilled endoscopic nursing.

References

- Goldgraber, M. B., and Kirsner, J. B. (1957). Polyps and carcinoma of the colon. *Arch. intern. Med.*, **100**, 669-677.
- Dawson, I. M. P., and Pryse-Davies, J. (1959). The development of carcinoma of the large intestine in ulcerative colitis. *Brit. J. Surg.*, **47**, 113-128.
- Edwards, F. C., and Truelove, S. C. (1964). The course and prognosis of ulcerative colitis. III and IV. *Gut*, **5**, 1-22.
- Jalan, K. N., Sirius, W., Walker, R. J., McManus, J. P. A. Prescott, R. J., and Card, W. I. (1969). Pseudopolyposis in ulcerative colitis. *Lancet*, **2**, 555-559.

Lumb, G. (1961). Pathology of ulcerative colitis. *Gastroenterology*, **40**, 290-297.
De Dombal, F. T., Watts, J. McK., Watkinson, G., and Goligher, J. C. (1966). Local complications of ulcerative colitis: stricture, pseudopolyposis and carcinoma of colon and rectum. *Brit.*

med. J., **1**, 1442-1447.
Morson, B. C., and Pang, L. S. C. (1967). Rectal biopsy as an aid to cancer control in ulcerative colitis. *Gut*, **8**, 423-434.
Evans, D. J., and Pollock, D. J. (1972). In-situ and invasive carcinoma of the colon in patients with ulcerative colitis. *Gut*, **13**, 566-570.

The September 1975 Issue

THE SEPTEMBER 1975 ISSUE CONTAINS THE FOLLOWING PAPERS

Studies of intestinal lymphoid tissue M. N. MARSH
I Electron microscopic evidence of 'blast transformation' in epithelial lymphocytes of mouse small intestinal mucosa

II Aspects of proliferation and migration of epithelial lymphocytes in the small intestine of mice

The cellular infiltrate of the jejunum in adult coeliac disease and dermatitis herpetiformis following the reintroduction of dietary gluten M. LANCASTER-SMITH, PARVEEN J. KUMAR, AND A. M. DAWSON

Postoperative motility of the large intestine in man J. P. WILSON

A relation between the energy of food and gastric emptying in men with duodenal ulcer D. F. STUBBS AND J. N. HUNT

The pseudomembranous colitis associated with clindamycin therapy—a viral colitis H. W. STEER

A prospective comparative trial between early endoscopy and radiology in acute upper gastrointestinal haemorrhage F. P. MCGINN, P. B. GUYER, B. J. WILKEN, AND H. W. STEER

Factors relevant to the prognosis of chronic gastric ulcer D. W. PIPER, MARGARET GREIG, G. A. E. COUPLAND, ELIZABETH HOBBIN, AND JANE SHINNERS

Gastric pH and microflora of normal and diarrhoeic infants H. V. L. MAFFEI AND F. J. NÓBREGA

The agglutinating antibody response in the duodenum in infants with enteropathic *E. coli* gastroenteritis A. S. MCNEISH, N. EVANS, H. GAZE, AND K. B. ROGERS

Modification of the cerebrovascular response to noradrenaline by bile duct ligation D. S. BLOOM, B. H. EIDELMAN, AND T. A. MCCALDEN

Quantitative liver imaging using ¹³¹I Rose Bengal as an index of liver function and prognosis T. R. GAMLEN, D. R. TRIGER, D. M. ACKERY, J. S. FLEMING, R. W. GRANT, R. W. KENNY, A. G. MACIVER, AND RALPH WRIGHT

Progress report Normal and abnormal food intake R. J. C. HALL

Progress report Hepatic adenomas and oral contraceptives SHEILA SHERLOCK

Notes and activities

Notes on books

Copies are still available and may be obtained from the PUBLISHING MANAGER, BRITISH MEDICAL ASSOCIATION, TAVISTOCK SQUARE, LONDON, WC1H 9JR, price £2.00, including postage