

CLINICAL AND GENETIC PROBLEMS IN FAMILIAL INTESTINAL POLYPOSIS

BY

A. M. O. VEALE*

*From the Galton Laboratory, University College, London, and the Research Department,
St. Mark's Hospital, London*

The history of a family suffering from familial intestinal polyposis is presented, showing how a delayed onset of symptoms together with a lack of knowledge of affected relatives may obscure the familial nature of the disease. The necessity of examining all accessible relatives, irrespective of their advancing years, is stressed. Further, it is shown that in the absence of any familial incidence the proper diagnosis of an isolated case of polyposis is that the disease is the result of a fresh mutation.

The possibility of a non-familial form of this disease cannot be proved at present and will require a special genetic investigation. It is emphasized that the diagnosis of non-familial polyposis should not be made, as this will lead to a relaxation of the vigil that should be kept on the descendants of all patients with polyposis.

The disease now known as familial intestinal polyposis was recorded in the eighteenth century, but it was Cripps (1882) who first described the condition in two siblings and suggested a familial incidence. The association of the condition with intestinal cancer had also been reported but was not generally known. The all-important fact that polyposis precedes cancer was not established until the sigmoidoscope came into general use in the first and second decades of this century. In 1925, Lockhart-Mummery published a paper which aroused widespread interest and stimulated, at St. Mark's Hospital, London, the beginnings of a research which has continued ever since. This and other investigations have shown that familial intestinal polyposis behaves as if controlled by a dominant gene although there are still many points concerning its inheritance which are still unsettled. An outstanding advance in treatment was the adoption of the operation of early colectomy and ileo-rectal anastomosis about 20 years ago, and experience has shown that this is satisfactory in many cases and especially in those where the disease is in its pre-malignant phase.

The true frequency of a familial intestinal polyposis is difficult to assess accurately. Neel (1954) placed a lower limit on its frequency in Michigan as 1 in 29,000. Later Reed and Neel (1955), using further data, amended this to 1 in 8,300 and still thought that this could be an underestimate. At St. Mark's Hospital, London, there

are records of the families of 82 propositi (the index case of a family) and the disease is well known to geneticists and to surgeons specializing in intestinal diseases. Lockhart-Mummery (1925) and Lockhart-Mummery and Dukes (1939) presented data from 41 families collected at St. Mark's Hospital. It is now known that polyposis may be associated with other lesions, and pedigrees showing polyposis associated with sebaceous cysts (Oldfield, 1954), epidermoid cysts, fibromata (Gardner and Plenk, 1952) and osteomata (Gardner and Richards, 1953), and cerebral tumour (Turcot, Despres, and St. Pierre, 1959) have been described.

In addition Peutz (1921) and Jeghers, McKusick, and Katz (1949) have described a condition where polyps may be present throughout the alimentary tract but more frequently in the small intestine. This condition is associated with a spotty pigmentation of the lips, face, buccal mucosa, and the digits. It has been thought that the Peutz-Jeghers syndrome is another variant of familial intestinal polyposis, the polyps all being true adenomata and those in the large intestine showing the same tendency to undergo malignant change as in familial intestinal polyposis. Bartholomew and Dahlin (1958) and Bartholomew, Dahlin, and Waugh (1957) have cast some doubt on this theory and suggest that the polyps in the Peutz-Jeghers syndrome are the result of local tissue malformation (hamartomata) rather than true neoplasms, and accordingly there is little risk of a cancerous change.

This paper is concerned only with familial intestinal polyposis without any of these additional

* New Zealand Medical Research Council Fellow.

features. Dukes (1952) described fully the course of the disease and recorded details of 22 families in which there was more than one member affected. In addition there were eight families in which the details were incomplete and 11 families in which there was only one affected member. Carter (1953) suggests that these 11 cases could all be ascribed to fresh mutations, but this paper will cast some doubt on this explanation. Dukes did not suggest that any of the 11 isolated cases were fresh mutations but rather that they were non-familial phenocopies, *i.e.*, non-genetic copies of the condition, and that only long observation of the families could resolve this point. The idea of the non-familial case of polyposis is quite widely held and it has been said in support of its existence that there is no recorded instance of such a patient passing the condition on to the offspring. This is only to be expected, since the inheritance of the condition would automatically exclude the patient from that class we were seeking to establish. However, it may be that this point will be resolved in the future when a satisfactory marker for the polyposis locus is discovered. In the meantime isolated cases of polyposis will continue to arise and will always present a problem in the management of the family. Dukes (1958) has described the problems that arise in the management of a polyposis family in which several cases are known or soon discovered. This paper will present the natural history of a polyposis family and show the difficulties that may arise in making a correct diagnosis of polyposis and in establishing that there is, in fact, a familial incidence.

Gates (1946) has stated that the condition may occasionally skip a generation. This fact seems to have escaped the attention of many writers on the subject, and although Dukes (1952) recorded two instances of "skipping" he did not comment upon it. In one of these the maternal grandfather of two polyposis patients died from cancer of the colon (according to the testimony of relatives) whereas the mother died at the age of 42 from pneumonia. It may well be that the mother would have developed polyposis had she lived longer, but, as the family stands, the gene was not manifested in her. In the other case the evidence for a "skip" is not so clear but it is certainly an example of an apparently unaffected woman passing the condition to three of her children: she had two sisters who died of carcinoma of the colon. The patient herself died at the age of 44 from "ovarian tumours". Instances such as these should serve to remind us that, when the parents of a polyposis patient have died from some other cause or are alive and well and perhaps already in middle life, one must not be tempted too easily to ascribe the polyposis either to a

fresh mutation or to a non-familial phenocopy.

The clinical course of the typical case of polyposis has been described many times but in all of these the natural history of the kindred has been neglected. The family to be described lives in New Zealand, and in that country all its members are now known. All living members, with only two exceptions, have been interviewed by me, some of them many times. From an acquaintance with the family extending over eight years I have been able to reconstruct the extent of the knowledge that the various members had of their relatives at different periods in the evolution of the pedigree. The first period begins with the earliest recorded death from carcinoma of the rectum and the second period covers an interval of 11 years during which further deaths occurred but the familial nature of the disease was not recognized. The third period begins with the detection of intestinal polyps and covers the first investigations of the family following the diagnosis of familial intestinal polyposis. The fourth period covers the present investigation.

The object of presenting the pedigree in this way is to show how families suffering from polyposis may easily be missed. The final pedigree as it is known today, and as it would be presented in any normal type of paper on this condition, is shown in Fig. 5, but the evolution of this family illustrates several interesting features which make the condition a difficult one to study genetically.

FAMILY HISTORY

FIRST PERIOD, 1907-1927.—It seems that the first opportunity to diagnose polyposis presented itself in 1907 when Case II.5 (see Fig. 1) died at the age of 37 from carcinoma of the rectum. This information was obtained from the records of the Registrar-General and there was no mention of polyposis. However, the subsequent history of her descendants leaves the diagnosis in little doubt. Her father had died in a shooting accident while still a young man and her mother had married again and had several children by her second husband. None of these children or any of their descendants have been affected with polyposis. Interest in the familial nature of polyposis was not widespread in 1907 but it is interesting to imagine ourselves in the position of investigating the family of this patient at the time of her death. Fig. 1 shows the family as it actually existed at this time and as the patient or one of her near relatives may have been able to report it. It is unlikely that the patient knew anything of her father's relatives in England, as her mother had emigrated with her new husband and the five children shortly after her first husband's death. An examination of II.1 and II.2 at this stage may have shown polyposis, as it is now known that these two men must have been carrying the gene. But in the light of their subsequent history it is highly probable that no polyps were present at this time.

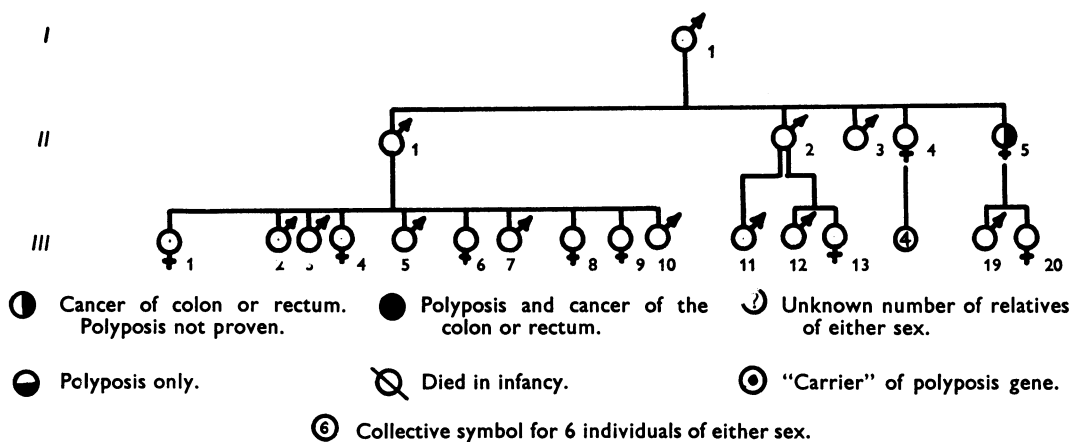


FIG. 1.—The family in 1907, as it may have been known to II.5.

SECOND PERIOD, 1928-1939.—After a period of 21 years, Case III.1 died from carcinoma of the colon at the age of 46. This was in 1928 and there is no mention of polyposis on the death certificate, but the history of some of her children again leaves little doubt that she too carried the gene for polyposis. Her father (II.1) died in 1927 from chronic bronchitis and heart failure at the age of 68 according to the death certificate. Family "lore" now has it that this man also had cancer of the bowel but this view is not universal within the family, and I think it should be disregarded in view of the information given in the death certificate, although it is clear that he also must have been carrying the gene for polyposis.

In 1934 Case III.4 died from carcinoma of the bowel at the age of 41. She had had very little in the way of symptoms and only presented in the terminal stage of her illness when the condition was found to be inoperable. If a diagnosis of polyposis had been made at this stage the information obtainable would have been meagre, as there was only one other case of carcinoma in the sibship and the patient who had died in 1907 was thought to have died from typhoid fever. In 1937, a brother (III.7) of these two women died, aged 39, from carcinoma of the rectum and the information obtainable would have been the same as before.

In the meantime there had been a further death from carcinoma in 1935 in Case III.12, then aged 34 (see Fig. 1). This man presented at hospital with a short history of bleeding per rectum with other intestinal symptoms and a loss of 28 lb. in weight over the previous five weeks. A tumour was felt per rectum and secondary deposits were palpable in the liver and elsewhere. The growth was considered inoperable and the patient died shortly afterwards. A diagnosis of polyposis was not made, but even if it had been the family history would have been of little value. From his younger unaffected brother III.14 (see Fig. 5) I have been able to ascertain that they had no knowledge of the whereabouts of any of their relatives on their father's side of the family although they knew that there were some. At the time of the present investigation (1954) Case III.14 was amazed to hear of the number of relatives that he had in

other parts of the country. He was not aware that he had a half-brother. The father of this patient (II.2) had died suddenly in the street in 1929 at the age of 69 and had been examined at necropsy. The cause of death as recorded by the Registrar-General is "heart failure" and there was no mention of any pathology of the large bowel although it is clear that this man too must have been carrying the polyposis gene.

It is tragic to record that if a diagnosis of polyposis had been made during this period, and a vigorous and complete investigation of the family undertaken, several lives would undoubtedly have been saved. It should be noted here that none of the patients mentioned so far who died from cancer of the colon or rectum had an affected parent even though they came from three separate sibships. In each case the parent whom we now know to have been carrying the gene had already died from some other cause. Furthermore each of the five patients, whom we have considered presented in the terminal stages of their illness with a malignant polyp and secondary deposits already established. It is known for all these cases except the first that there were apparently no symptoms of the condition until the last few weeks of life. This absence of symptoms until the advent of malignancy has proved to be most common in this particular family.

THIRD PERIOD, 1940-1951.—It was not until 1940 that the first patient presented for medical care with a polyp. This was Case IV.41 and the family tree as known to him is shown in Fig. 2. This man was found to have a polyp 1½ cm. in diameter and 5 cm. from the anus. It was surrounded by "several" smaller polypi and the rest of the mucosa was clear up to a distance of 15 cm. The polyps were treated by diathermy excision, since when the patient has remained well but declines any further examination. From Fig. 2 it can be seen that he knew little of his relatives and nothing of their causes of death. His father (III.11) was alive and well aged 54. At this point I think it would have been a bold surgeon who would have made the diagnosis of familial intestinal polyposis as, from the patient's testimony, there was no

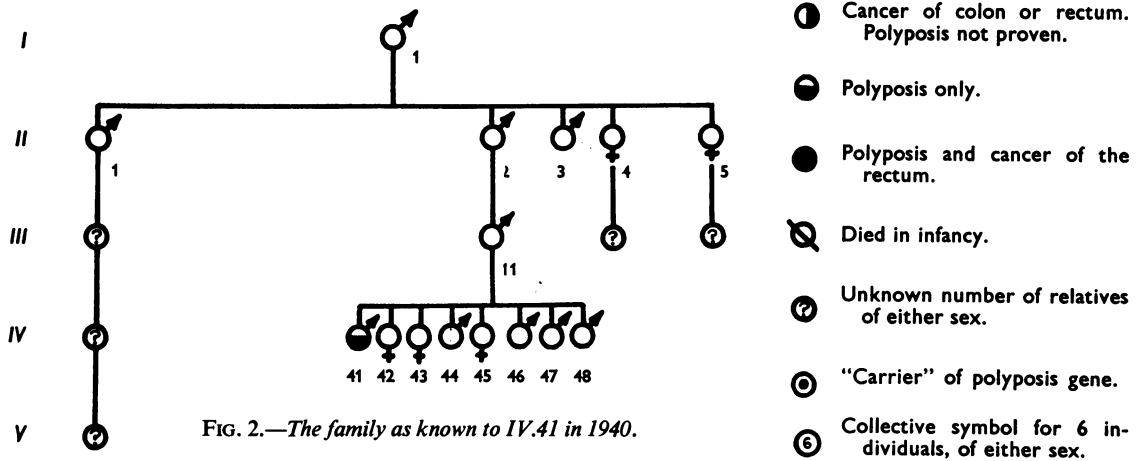


FIG. 2.—The family as known to IV.41 in 1940.

familial incidence at all, and, even if he had been in possession of more information, the most he could have said was that three of his father's cousins had died from carcinoma of the bowel.

This man shows clearly that it is not necessary for large numbers of polypi to be present in order to consider the possibility of polyposis. This patient had only one large polyp and "several" smaller ones but these could have provided the key to the family complaint that was still to claim further victims.

After 1940 events were to move more swiftly. In 1941, two men, Cases III.2 aged 53 and III.3 aged 49, brothers of the patients who had died in 1928, 1934, and 1937, presented with polyposis and cancer of the rectum. Both were treated by abdomino-perineal resection as a palliative measure as secondary deposits were already present. In 1942 another brother (III.5), aged 47, died of carcinoma of the colon. It was in 1941 that the diagnosis of familial intestinal polyposis was first attached to this branch of the family and an investigation of this sibship was undertaken. The pedigree as known to these patients

is shown in Fig. 3. At about this time Case IV.3, living in another part of the country, had been found to have polyposis and had been treated by colectomy. Unfortunately he had died post-operatively from secondary haemorrhage.

The diagnosis of familial intestinal polyposis was now firmly established for the main branch of the family shown in Fig. 3 and a number of members were examined but with negative results. It seems now that the genetic advice given to the family at this time was misconstrued, because I found in 1952 that the majority of the family believed that they were all fated to suffer from polyposis and cancer. This led, naturally enough, to a sense of futility and a feeling of complete resignation and resistance to any investigations. When the nature of the disease was re-explained to them and the probabilities involved clarified there was a marked change in the attitude of nearly all of them. As Dukes (1958) says the information received was "good news".

In 1942 a further case of polyposis presented in the collateral branch of the family shown in Fig. 2. This was

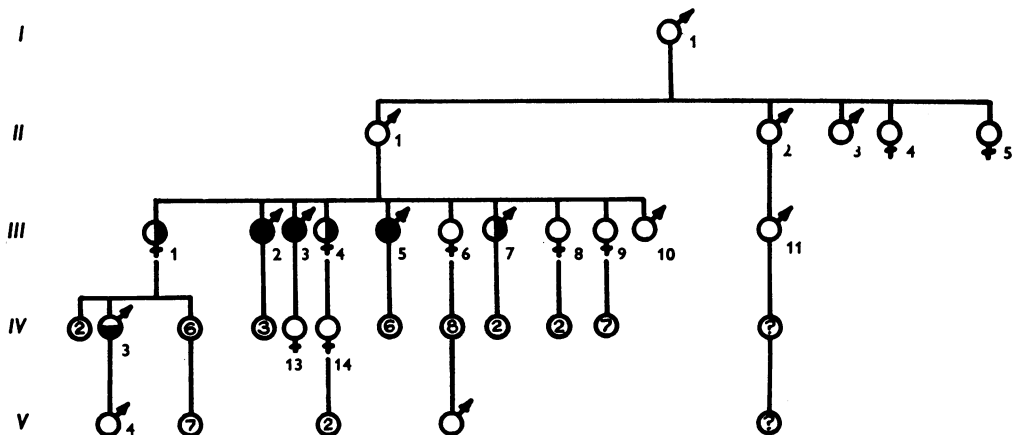


FIG. 3.—The family as known to the sibship III.1-10 in 1942.

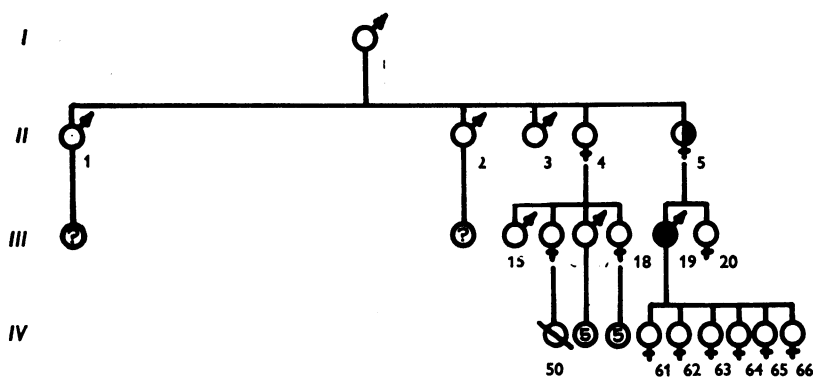


FIG. 4.—The family as known to III.19 in 1947.

Case IV.43 who presented to her physician, in another part of the country, complaining of bleeding per rectum. It was found that she had a prolapsed rectal polyp which was excised. This patient continued without any further symptoms until 1945 when she reported to a distant hospital with carcinoma of the rectum and secondary deposits in the liver. She died shortly afterwards at the age of 32. Her account of the family tree would have been essentially the same as that of her brother (see Fig. 2) who was seen in 1940. Her father (III.11) was now aged 59 and in robust health.

At this stage (1945) polyposis had appeared in two collateral branches of the family but the familial character of the disease had only been recognized in one (see Fig. 3). Even though each branch was aware of the existence of the other the contact between them was minimal and certainly did not extend to a knowledge of intimate medical detail. Because of this no investigations were made of the branch shown in Fig. 2.

In 1947, a new case of polyposis arose in a hitherto unaffected branch of the family in another part of the country. However, the diagnosis of familial intestinal polyposis was made and a family investigation undertaken but no new cases of polyposis were found because of the patient's ignorance of the existence of his affected relatives. The affected man was Case III.19 and his account of the family is shown in Fig. 4. The patient died of carcinoma of the colon in 1947 at the age of 43 and local medical interest in the family waned until 1954.

FOURTH PERIOD, SINCE 1952.—Other cases continued to arise in the branch of the family shown in Fig. 3, and it was as a result of one of these that my own interest was aroused and a complete investigation of the family undertaken. The ultimate linking up of the branch of the family shown in Fig. 3 with that shown in Fig. 4 was only possible after information was received from a descendant of the wife of I.1, following her second

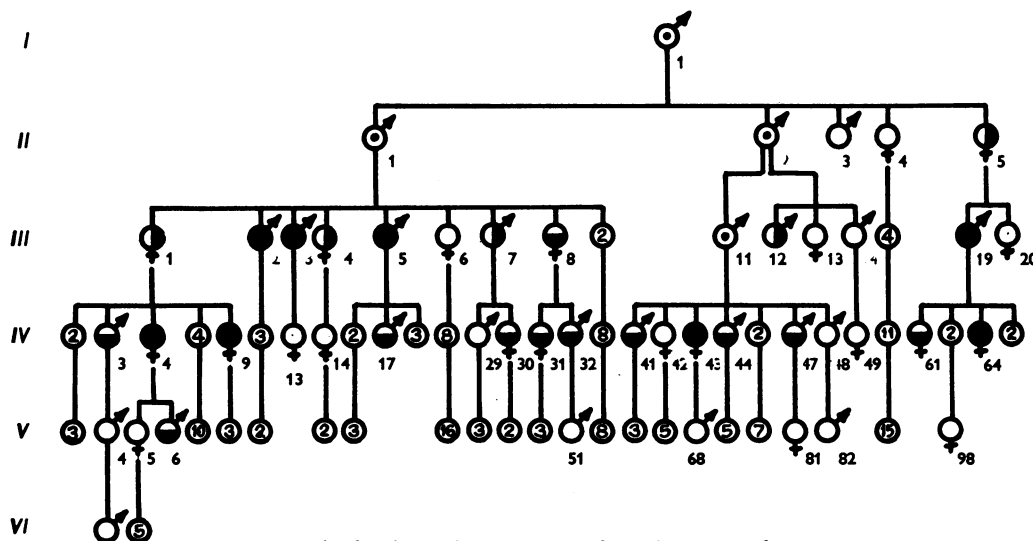


FIG. 5.—The family in 1954. See text for a discussion of III.11.

marriage. As a result of this investigation the complete pedigree was established and all members over the age of 16 were asked to submit to sigmoidoscopy and x-ray examinations. Patients younger than this were examined at the request of parents. Several new cases of polyposis were discovered and in one of these (IV.64), a girl of 18, a carcinoma was already present.

The family as it existed in 1954, is shown in Fig. 5 and interest naturally enough focused on III.11 who was still alive and well aged 68. I saw this man first in 1952 and found a vigorous, slightly overweight farmer still leading an active working life. Unfortunately I was never able to persuade him to submit to any kind of examination. He remained friendly and cooperative on all other matters, saying that he had never had anything to do with hospitals during his life and he wasn't planning to begin now. He always maintained, until I saw him for the last time in 1954, that he was perfectly well and had no symptoms at all. During 1956 he began to lose weight and later became jaundiced. He eventually died early in 1957 at the age of 71. The efforts of one of his daughters, who appreciated the genetic interest of her father's condition, overcame some family opposition and a necropsy was performed. The peritoneal cavity, stomach, and small intestine were all normal. In the large bowel, small polyps, generally less than 5 mm. in diameter, were scattered sparsely throughout its length. In the transverse colon there was a larger pedunculated tumour 3 cm. in diameter. In the rectum there was a massive ulcerating tumour involving subserous tissues, lymph nodes, and veins. The liver was enormously enlarged by multiple deposits of tumour tissue.

This patient provides clear evidence of the necessity of examining everyone who may be carrying the polyposis gene. No person should be omitted because they are symptomless or have reached an age beyond which the probability of polyposis is commonly and erroneously believed to be unlikely. The fact that symptoms may be delayed until the age of 70 is not readily apparent from the literature as it is usually those families showing a striking incidence in the younger age groups which are reported. Such a delay in the onset of symptoms increases the chances of these persons dying from other causes, so that the subsequent appearance of polyposis in one of their progeny may be regarded erroneously as the result of a fresh mutation. Since we have seen how misleading a family history can be, this interpretation of the isolated case should not be made without a full investigation and examination of all accessible relatives. If no evidence is obtained of a family incidence, then it is proper to conclude that an isolated case of polyposis may be the result of a fresh mutation and the full genetic situation should be explained to the patient so that in time any offspring can be examined in their turn. It should never be concluded that a case is a non-familial phenocopy, as this will auto-

matically lead to a relaxation of the vigil that should be kept on descendants, possibly with tragic results. That fresh mutations do occur is not doubted but the frequency with which this is likely to happen will not be discussed here. The estimation of the mutation rate depends on the incidence of the condition in the general population and on the relative biological fitness of the individuals affected.

There is a further question which arises from a study of this family and that concerns the factors conspiring to bring about the considerable delay in the onset of symptoms in some patients but not in others. There have been no striking differences in environment within the family over the last 40 years so it may be that the observed differences in behaviour of the polyposis gene are due to differences in the total genetic background on which it plays. Whether this difference affects the number of polyps, their time of appearance, or their tendency to undergo malignant change cannot all be answered from one pedigree but more extensive material may throw some light on these questions.

I wish to express my gratitude to the New Zealand Medical Research Council for a research grant.

REFERENCES

- Bartholomew, L. G., and Dahlin, D. C. (1958). Intestinal polyposis and mucocutaneous pigmentation (Peutz-Jeghers syndrome). *Minn. Med.*, **41**, 848-852.
- , and Waugh, J. M. (1957). Intestinal polyposis associated with mucocutaneous melanin pigmentation (Peutz-Jeghers syndrome). Review of literature and report of six cases with special reference to pathologic findings. *Gastroenterology*, **32**, 434-451.
- Carter, Cedric (1953). *Clinical Genetics*, p. 419, ed. A. Sorsby. Butterworth, London.
- Cripps, W. H. (1882). Two cases of disseminated polypos of the rectum. *Trans. path. Soc. Lond.*, **33**, 165-168.
- Dukes, C. E. (1952). Familial intestinal polyposis. *Ann. Eugen. (Lond.)*, **17**, 1-29.
- (1958). Cancer control in familial polyposis of the colon. *Dis. Colon Rect.*, **1**, 413-423.
- Gardner, E. J., and Plenk, H. P. (1952). Hereditary pattern for multiple osteomas in a family group. *Amer. J. hum. Genet.*, **4**, 31-36.
- and Richards, R. C. (1953). Multiple cutaneous and subcutaneous lesions occurring simultaneously with hereditary polyposis and osteomatosis. *Ibid.*, **5**, 139-147.
- Gates, R. R. (1946). *Human Genetics*, Vol. 2, 1172. Macmillan, New York.
- Jeghers, H., McKusick, V. A., and Katz, K. H. (1949). Generalized intestinal polyposis and melanin spots of the oral mucosa, lips and digits. A Syndrome of diagnostic significance. *New Engl. J. Med.*, **241**, 993-1005.
- Lockhart-Mummary, P. (1925). Cancer and heredity. *Lancet*, **1**, 427-429.
- , and Dukes, C. E. (1939). Familial adenomatosis of colon and rectum. *Ibid.*, **2**, 586-589.
- Neel, J. V. (1954). Problems in the estimation of the frequency of uncommon inherited traits. *Amer. J. hum. Genet.*, **6**, 51-60.
- Oldfield, M. C. (1954). The association of familial polyposis of the colon with multiple sebaceous cysts. *Brit. J. Surg.*, **41**, 534-541.
- Peutz, J. L. A. (1921). Over een zeer merkwaardige, gecombineerde familiaire Polyposis van de Slijmvliezen van den Tractus intestinalis met die van de Neuskeelholte en Gepaard met eigenaardige Pigmentaties van Huid en Slijmvliezen. *Ned. Maandschr. Geneesk.*, **10**, 134.
- Reed, T. Edward, and Neel, James V. (1955). A genetic study of multiple polyposis of the colon (with an appendix deriving a method of estimating relative fitness). *Amer. J. hum. Genet.*, **7**, 236-263.
- Turcot, J., Despres, J. P., and St. Pierre, F. (1959). Malignant tumors of the central nervous system associated with familial polyposis of the colon. *Dis. Colon Rect.*, **2**, 465-468.