

Peutz-Jeghers syndrome associated with gastrointestinal carcinoma

Report of two cases in a family

B. COCHET¹, J. CARREL, L. DESBAILLETS, AND S. WIDGREN

From the Clinique Médicale Thérapeutique, the Gastroenterology Unit, Department of Medicine, and the Department of Pathology, Geneva University Hospital, Geneva, Switzerland

SUMMARY Patients with the Peutz-Jeghers syndrome carry a slight, though definite, increased risk of gastrointestinal carcinoma. The malignant potentiality of Peutz-Jeghers hamartomatous polyps, generally considered benign, is supported by this report. Two cases of metastasising gastrointestinal carcinoma associated with the Peutz-Jeghers syndrome are described in a 56 year old female and her 29 year old son. Both mother and son died from duodenal and gastric carcinomas respectively, which developed in hamartomatous polyps with extensive metastases. Both cases also showed dysplastic areas within hamartomatous polyps. These features indicate that hamartomatous polyps may, in some cases, be the precursors of digestive tract carcinomas.

The Peutz-Jeghers syndrome is an association of mucocutaneous pigmentation and intestinal polyposis, with an autosomal dominant inheritance (Jeghers *et al.*, 1949; Dormandy, 1957). There have been conflicting views about the risk of associated intestinal cancer: about 20% of earlier reports described malignant changes within the polyps (Bailey, 1957); later on, however, a review of the literature failed to document any case of death or metastases that could be attributed to such malignant changes (Bartholomew *et al.*, 1957). The discrepancy was explained by the misinterpretation of the true nature of the polyps, first considered as adenomas and later identified as hamartomas, without special tendency to malignancy (Bartholomew *et al.*, 1957; Rintala, 1959). Some histological features of hamartomatous polyps (frequent mitotic figures, apparent penetration within the intestinal wall, and cellular hyperchromatism) were erroneously interpreted as malignant changes. However, since 1957, there have been several reports of true intestinal carcinoma in patients with the syndrome, involving mostly the upper part of the gastrointestinal tract (Payson *et al.*, 1967; Dozois *et al.*, 1969; Bussey, 1970). At present, it seems reasonable to admit that patients with the Peutz-Jeghers syndrome carry an increased risk of

intestinal cancer, estimated at about 2-3% (Reid, 1974).

This report deals with the follow-up of two familial cases of the Peutz-Jeghers syndrome previously described 19 years ago (Mégevand, 1959). The interest lies in the fact that both developed carcinoma of the upper digestive tract with metastases and subsequent death. Histological evidence favouring malignant changes of hamartomatous polyps is provided.

Report of cases

CASE 1

A married woman aged 56 years was first admitted to the Geneva University Hospital in July 1968 for weight loss and vomiting. Small bowel resections had been performed in 1931 and 1933 for intussusception and intestinal obstruction due to intestinal polyposis. On microscopic examination, polyps were described as adenomatous, with infiltration of the submucosa and muscular layers by frequent mitotic figures and glandular cells. At this time an invasive cancer was diagnosed, but the patient remained perfectly well until the present admission (Mégevand, 1959).

On physical examination, gingival pigmented spots were noted. A barium meal showed numerous polyps of the small bowel and a stenosis on the third part of the duodenum. At laparotomy, several pedunculated polyps were found in the duodenum, with a carcinomatous infiltration of the superior mesenteric vessels

¹Address for reprint requests: B. Cochet, Clinique Médicale Thérapeutique, Hôpital Cantonal, CH 1211 Geneva 4, Switzerland.

Received for publication 4 August 1978

and pancreas. Multiple pedunculated polyps were found in the upper jejunum, and a 40 cm resection was carried out with a duodenoileal anastomosis leaving the tumour in place. Several polyps in the whole length of the colon and rectum were also removed. Her condition steadily deteriorated until January 1969, when she was readmitted with a three week history of cholestatic jaundice. Laparotomy disclosed a voluminous tumour on the third part of the duodenum, a dilated common bile duct, and multiple hepatic metastases. A cholecystogastrostomy and a gastroenterostomy were carried out. The patient died two months later.

Pathology

The 1968 specimen was a 40 cm jejunal segment with about 10 pedunculated polyps measuring 0.5 to 5 cm diameter. The five colonic polyps (1.5-3 cm in diameter) had a narrow pedicle and a puckered surface. Microscopically the jejunal polyps were hamartomatous; their surface was covered with a nearly normal jejunal mucosa; the pedicle sub-

divided into ramifications containing branching bundles of smooth muscle cells. The rectal and colonic polyps were also hamartomatous. One of the rectal polyps showed a nest of severe dysplasia (Fig. 1a and b): the cells were of varying size, cubical or cylindrical, basophilic, forming stratified bands or pseudo-polyps; their nuclei were large, rounded, or oval, containing one or several small distinct nucleoli; mitoses were rather numerous.

The necropsy disclosed a peritonitis related to a perforated stomal ulcer. The duodenum was the site of a large tumour invading the bile duct and the pancreas. Metastases were found in the liver and lymph nodes. The colon and rectum contained about 20 pedunculated polyps. On microscopic examination, the duodenal tumour was a well-differentiated invasive adenocarcinoma, partly papillary and mucinous. In some places it was difficult to distinguish (Fig. 2) the carcinomatous areas from the foci of dysplasia recalling that seen in one of the rectal polyps. In the papillary structures, which were well individualised from the invaded duodenal wall, one

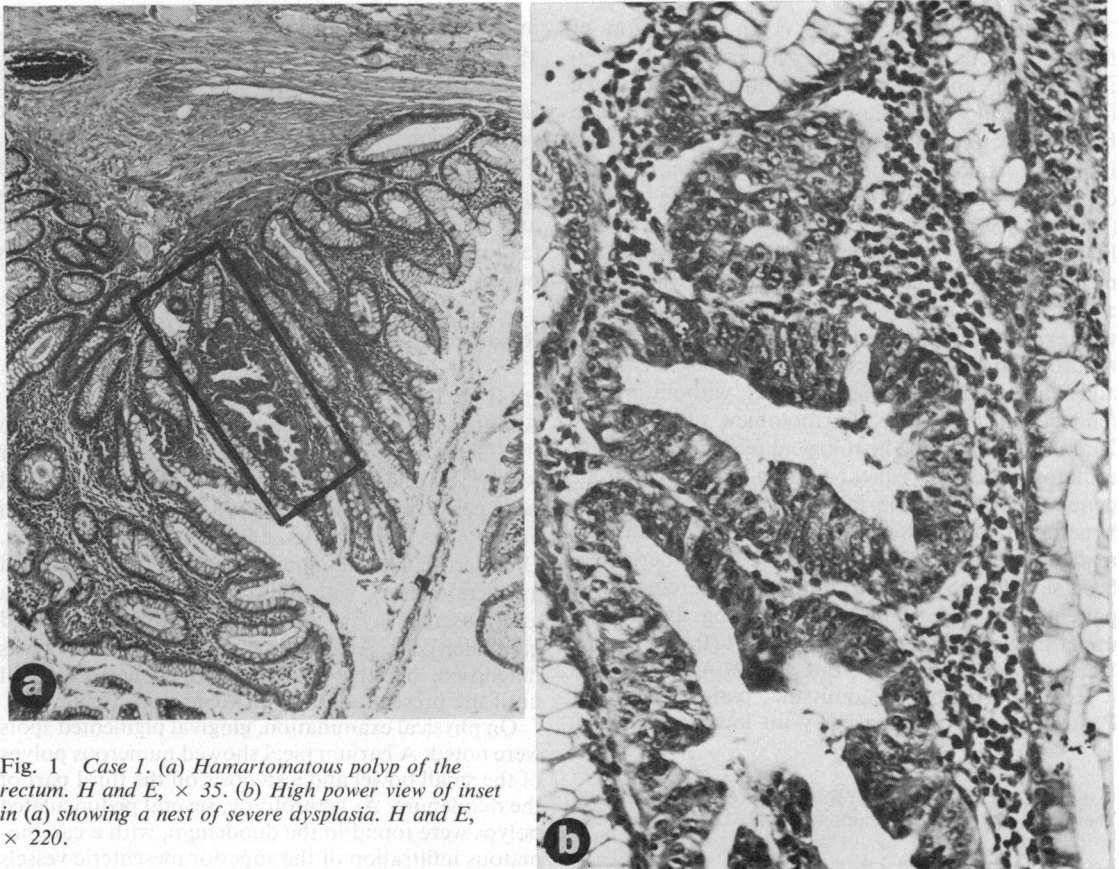


Fig. 1 Case 1. (a) Hamartomatous polyp of the rectum. H and E, $\times 35$. (b) High power view of inset in (a) showing a nest of severe dysplasia. H and E, $\times 220$.

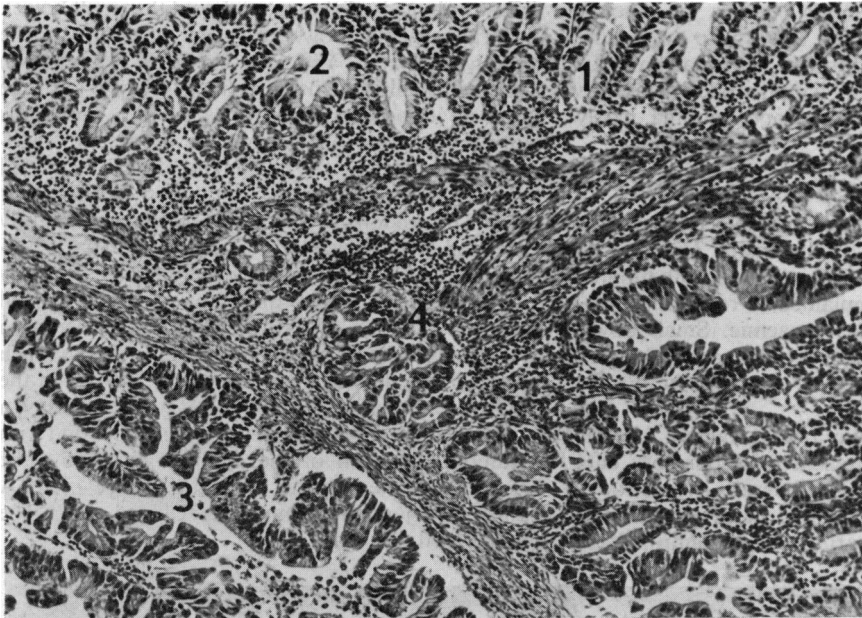


Fig. 2 Case 1. Detail of duodenal carcinoma. Normal mucosa (1), with some slightly dysplastic glands (2). Adenocarcinoma (3). Severely dysplastic glands (4). In between: strands of branching smooth muscle fibres. *H and E, × 85.*

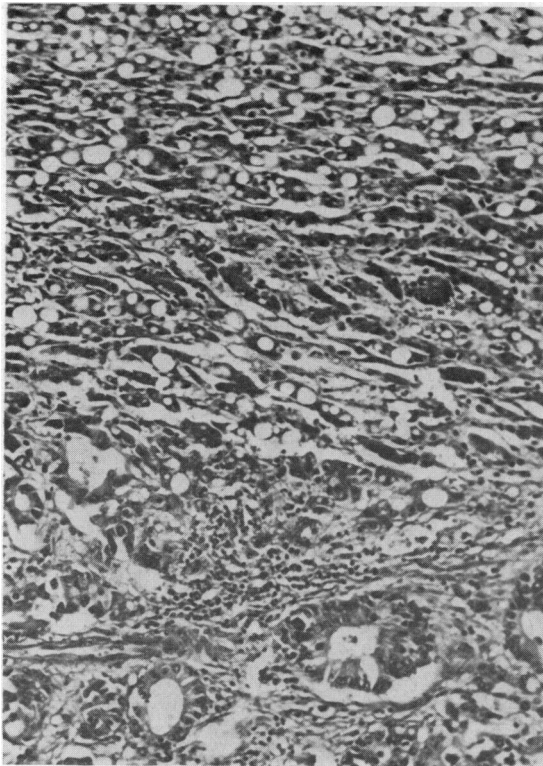


Fig. 3 Case 1. Liver: metastasis of duodenal carcinoma. *H and E, × 180.*

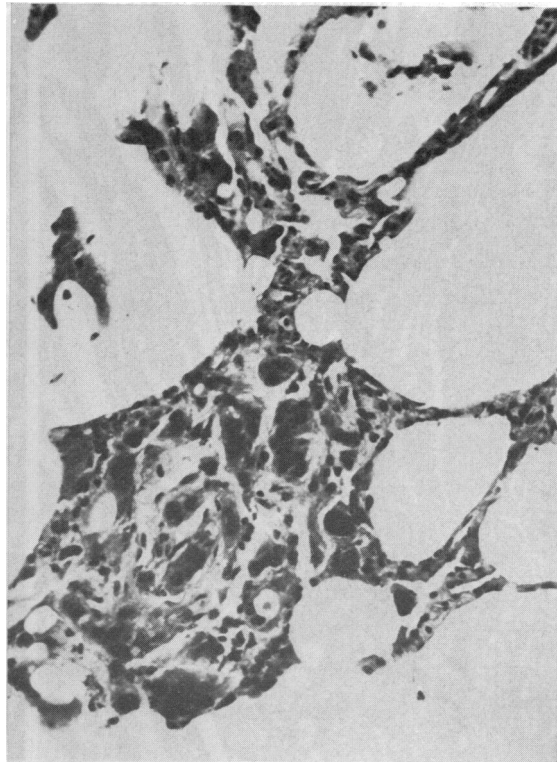

Fig. 4 Case 2. Lung: metastasis of gastric carcinoma. *H and E, × 220.*

could find small branching bundles of smooth muscle cells, in some places these were even quite convoluted like those found in a hamartomatous polyp. Liver (Fig. 3) and lymph node metastases showed a well-differentiated adenocarcinoma, partly mucinous.

CASE 2

The 29 year old son of the previous patient was admitted to the Geneva University Hospital in December 1974 for dizziness and vague abdominal pains. As a child he complained of recurrent abdominal pain and was often anaemic. Small bowel resections were performed in 1954 and 1962 for intussusception and intestinal obstruction due to multiple jejunal polyps.

On physical examination, buccal mucosa, cheeks, lips, and fingers were pigmented. Laboratory data were normal, except for a moderate hypochromic anaemia and a slightly raised level of carcino-embryonic antigen. A barium meal confirmed the

diffuse polyposis of the stomach and the small bowel. A barium enema showed a cluster of polyps in the rectosigmoid area. The panendoscopic examination disclosed multiple pedunculated polyps in the stomach, duodenum, and distal colon; numerous biopsies and excisions were made. Persistent abdominal pain, frequently related to food intake, and weight loss required a new admission in December 1975. The abdomen was diffusely tender, slightly distended with peristaltic waves seen on the abdominal wall. A tender, soft sausage-shaped mass was felt in the right upper quadrant. A barium meal disclosed a major dilatation of the upper jejunum proximal to a 8 cm irregular stenosis. In the stomach several filling defects were noted, particularly in the fundus along the greater curvature. At laparotomy, a generalised peritoneal carcinomatosis was found with a tumoral invasion of the jejunum narrowing the lumen. Multiple hepatic metastases were seen. A palliative jejunocolostomy was carried out. The patient died four days later.

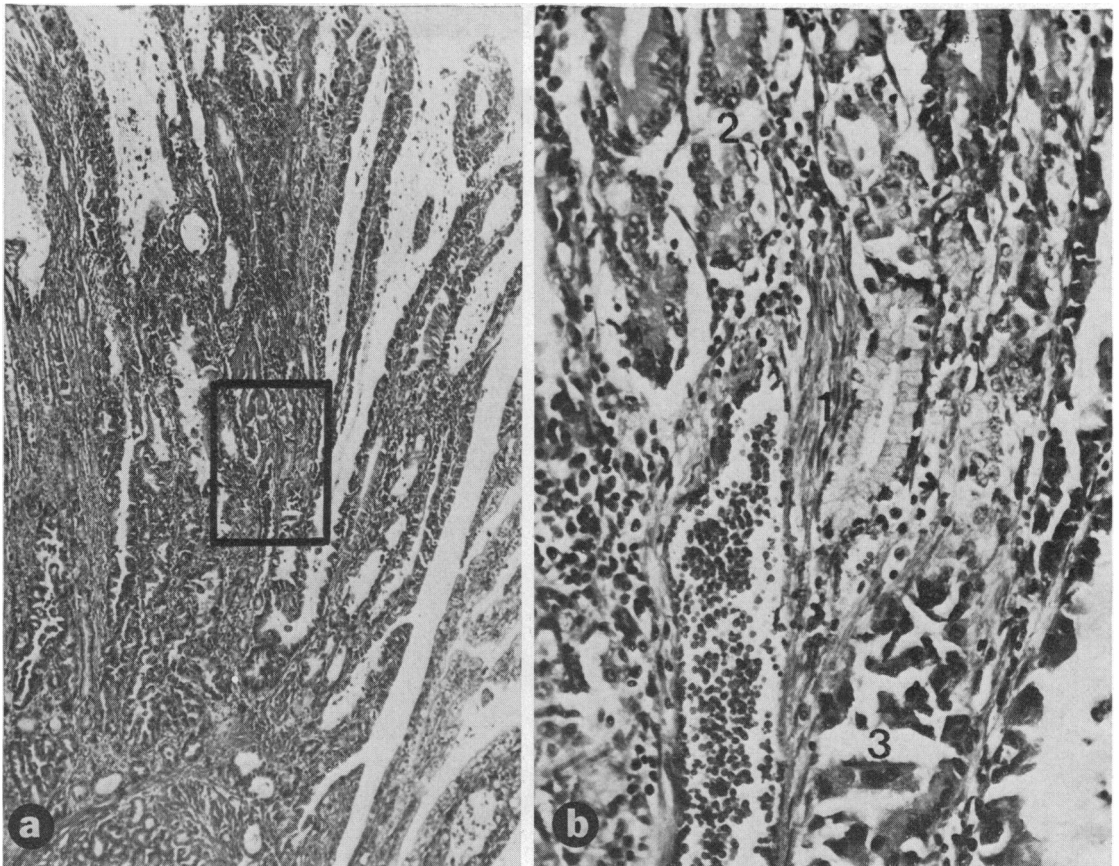


Fig. 5 Case 2. (a) Gastric carcinoma. H and E, $\times 35$. (b) High power view of inset of (a) showing vertical smooth muscle bundles (1), normal gastric glands (2), and carcinomatous glands (3). H and E, $\times 220$.

The patient's brother and sister, born in 1943 and 1950, were thoroughly investigated, and no feature of Peutz-Jeghers syndrome was found.

Pathology

The segments of small bowel resected in 1954 and 1962 disclosed multiple pedunculated polyps, varying in size from 5 mm to 3.5 cm. The histological picture was typical of hamartomatous polyps. The biopsies of gastric, duodenal and rectal polyps taken in 1974 showed a similar benign structure.

The necropsy showed a peritonitis due to a stomal dehiscence. The stomach, small and large intestine, and rectum were the site of multiple polyps. In the subcardial area, a 5 cm fungating carcinoma was found, invading the serosa, with a peritoneal carcinomatosis and obstruction of the proximal

jejunum. Metastases were found in the lymph nodes, liver, lungs (Fig. 4), and adrenals. Besides hamartomatous polyps, a biliary hamartoma of the liver was found. On microscopic examination, the gastric tumour was seen to be a well-differentiated invasive adenocarcinoma, partly papillary. In several places the muscularis mucosa was rather well preserved, continuing toward the surface of the mucosa with branching bundles of smooth muscle covered with normal gastric or carcinomatous glands (Fig. 5a and b). The branching of these bundles differed from the pattern of parietal muscle cells which were associated by the carcinomatous infiltration (Fig. 6). Apart from the polyps, the gastric mucosa showed moderate superficial gastritis. All the polyps examined (stomach, duodenum, jejunum, and colon) were hamartomatous. It has to be emphasised that the duodenal polyps contained dysplastic glands (Fig. 7a and b).

Discussion

The relationship of the Peutz-Jeghers syndrome to intestinal carcinoma is still disputed. It has been suggested that the cancer may sometimes develop from hamartomatous polyps found in the syndrome (Reid, 1974). As developmental anomalies, hamartomas are benign; however, occasional neoplastic change may occur (Morson and Dawson, 1972). Examples of adenocarcinomas arising in hamartomatous polyps in the Peutz-Jeghers syndrome have been documented (Warren *et al.*, 1965; Williams and Knudsen, 1965; Shibata and Phillips, 1970). The case reported by Horn *et al.* (1963) undoubtedly showed a carcinoma *in situ* in a small hamartomatous polyp.

In the cases reported here, both the gastric and duodenal carcinomas were of a very large size and, on gross inspection, one could argue against primarily malignant changes of hamartomatous polyps. However, there was definite histological evidence indicating the development of the carcinoma within hamartomatous polyps. Both gastric and duodenal carcinomas are enclosing smooth muscle strands in a branching pattern, similar to that found in hamartomatous polyps. As well as in the gastric carcinoma, branches of this tree-like pattern are covered either by normal gastric glands or carcinomatous glands. The vicinity of benign and malignant tissues thus provide evidence that the carcinoma originated within a hamartomatous polyp. Additional evidence of such malignant changes are provided by the dysplastic areas observed in one hamartomatous polyp of the rectum (case 1) and in several hamartomatous polyps of the duodenum (case 2). Moreover, foci of severe epithelial dysplasia adjacent to carcinomatous areas in case 1 suggest that such changes

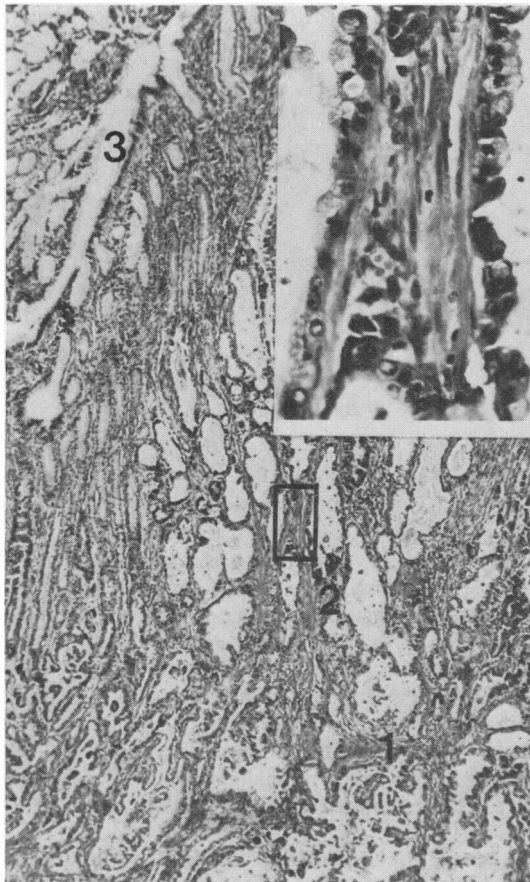


Fig. 6 Case 2. Part of gastric carcinoma, showing muscularis mucosae infiltrated by carcinoma (1), vertical smooth muscle bundles (2) covered with carcinomatous glands (detail in inset), and normal gastric glands (3). H and E, $\times 35$.

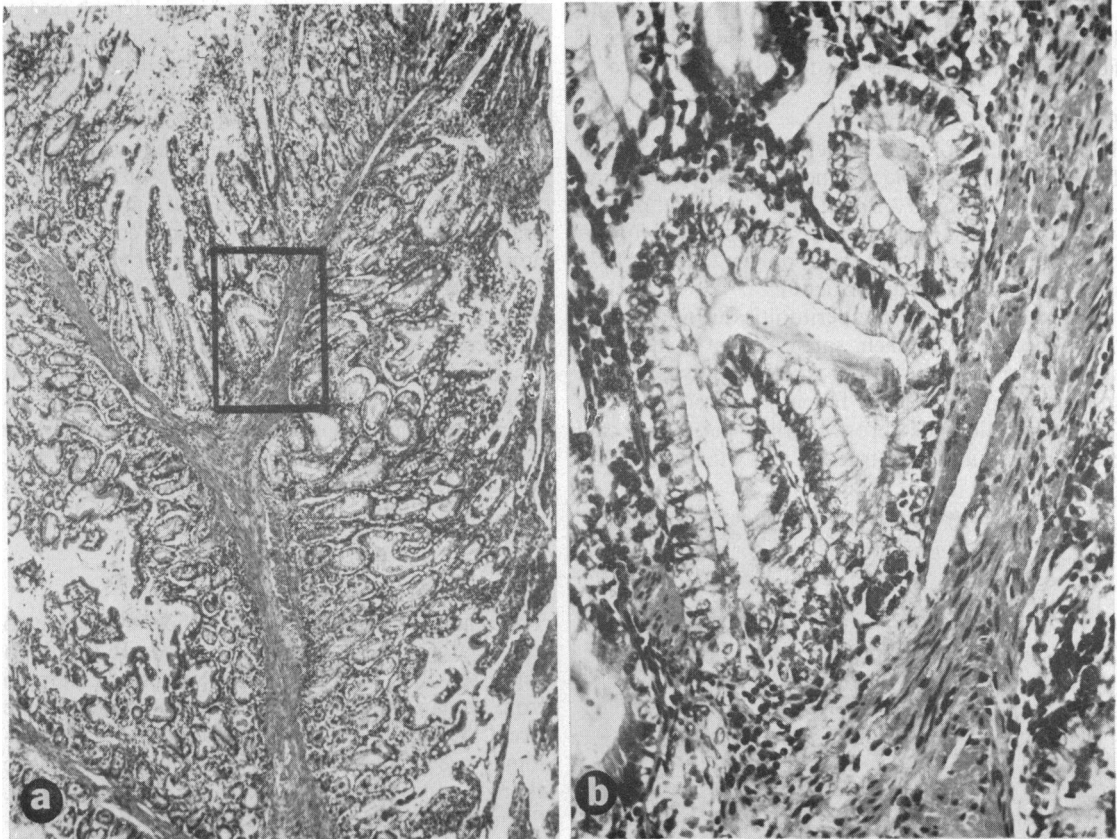


Fig. 7 Case 2. (a) Part of duodenal hamartomatous polyp. H and E, $\times 35$. (b) High power view of inset in (a) showing a nest of moderate epithelial dysplasia. H and E, $\times 220$.

within the polyps preceded the development of an invasive carcinoma.

An indirect argument favouring the malignant potentiality of hamartomatous polyps could be the occurrence of digestive carcinoma in two close relatives. The familial occurrence of cancer is a striking feature of this report, and strengthens the view of a genetic malignant trait.

Wennstrom *et al.* (1974) suggested that digestive tract carcinomas in the Peutz-Jeghers syndrome patients may arise from coincidental adenomatous polyps. That could be true at least in the large bowel where there have been a few reports of carcinomas, sometimes associated with adenomatous polyps (Altmeier, 1969; Shibata and Phillips, 1970; Dodds *et al.*, 1972). However, one would question whether adenomatous polyps are the common precursors of carcinoma in the syndrome. These polyps are rare in the small bowel, which is, by contrast, a frequent site of carcinoma in Peutz-Jeghers patients. It should be stressed that, in the two cases reported here, all

the polyps examined were hamartomatous, and there were no adenomatous polyps; moreover, one rectal polyp disclosed a nest of severe dysplasia.

In conclusion, these two cases of Peutz-Jeghers syndrome in the same family (mother and son) presented metastasising adenocarcinomas of the upper digestive tract and strongly support the belief that the risk of intestinal cancer in Peutz-Jeghers patients, though small, does exist. Although hamartomatous polyps are usually considered to be benign lesions, in both instances they have disclosed histological features of malignancy indicating they were the precursors of the carcinomas (Carrel, 1978).

We would like to thank Dr B. C. Morson for reviewing the histological sections, Professor R. Mégevand and Dr Y. Granges, Department of Surgery, Dr R. de Peyer, Gastroenterology Unit, Department of Medicine, for their assistance, and Mr E. Denking and Mr J. C. Rumbeli for the photographs.

References

- Altemeier, W. A., (in discussion), Dozois, R. R., Judd, E. S., Dahlin, D. C., and Bartholomew, L. G. (1969). The Peutz-Jeghers syndrome—is there a predisposition to the development of intestinal malignancy? *Archives of Surgery*, **98**, 509-517.
- Bailey, D. (1957). Polyposis of gastrointestinal tract: the Peutz syndrome. *British Medical Journal*, **2**, 433-439.
- Bartholomew, L. G., Dahlin, D. C., and Waugh, J. M. (1957). Intestinal polyposis associated with mucocutaneous melanin pigmentation (Peutz-Jeghers syndrome). *Gastroenterology*, **32**, 434-451.
- Bussey, H. J. R. (1970). Gastrointestinal polyposis. *Gut*, **11**, 970-978.
- Carrel, J. (1978). *Syndrôme de Peutz-Jeghers: cancer digestif chez deux membres d'une même famille*. M.D. Thesis: University of Geneva.
- Dodds, W. J., Schulte, W. J., Hensley, G. T., and Hogan, W. J. (1972). Peutz-Jeghers syndrome and gastrointestinal malignancy. *American Journal of Roentgenology*, **115**, 374-377.
- Dormandy, T. L. (1957). Gastrointestinal polyposis with mucocutaneous pigmentation (Peutz-Jeghers syndrome). *New England Journal of Medicine*, **256**, 1093-1103, 1141-1146, and 1186-1190.
- Dozois, R. R., Judd, E. S., Dahlin, D. C., and Bartholomew, L. G. (1969). The Peutz-Jeghers syndrome—is there a predisposition to the development of intestinal malignancy? *Archives of Surgery*, **98**, 509-517.
- Horn, R. C. Jr., Payne, W. A., and Fine, G. (1963). The Peutz-Jeghers syndrome (gastrointestinal polyposis with mucocutaneous pigmentation): report of a case terminating with disseminated gastrointestinal cancer. *Archives of Pathology*, **76**, 29-37.
- Jeghers, H., McKusick, V. A., and Katz, K. H. (1949). Generalised intestinal polyposis and melanin spots of the oral mucosa, lips and digits: a syndrome of diagnostic significance. *New England Journal of Medicine*, **241**, 993-1005, and 1031-1036.
- Mégevand, A. (1959). Polyposé viscérale et pigmentation mélanique cutanéomuqueuse (syndrome de Peutz). *Archives Françaises de Pédiatrie*, **16**, 353-361.
- Morson, B. C., and Dawson, I. M. P. (1972). *Gastrointestinal Pathology*. Blackwell: Oxford.
- Payson, B. A., and Moumgis, B. (1967). Metastasizing carcinoma of the stomach in Peutz-Jeghers syndrome. *Annals of Surgery*, **165**, 145-151.
- Reid, J. D. (1974). Intestinal carcinoma in the Peutz-Jeghers syndrome. *Journal of the American Medical Association*, **229**, 833-834.
- Rintala, A. (1959). The histological appearance of gastrointestinal polyps in the Peutz-Jeghers syndrome. *Acta Chirurgica Scandinavica*, **117**, 366-373.
- Shibata, H. R., and Phillips, M. J. (1970). Peutz-Jeghers syndrome with jejunal and colonic adenocarcinomas. *Canadian Medical Association Journal*, **103**, 285-287.
- Warren, K. W., Kune, G. A., and Poulantzas, J. K. (1965). Peutz-Jeghers syndrome with carcinoma of the duodenum and jejunum. *Lahey Clinic Foundation Bulletin*, **14**, 97-102.
- Wennstrom, J., Pierce, E. R., and McKusick, V. A. (1974). Hereditary benign and malignant lesions of the large bowel. *Cancer*, **34**, 850-857.
- Williams, J. P., and Knudsen, A. (1965). Peutz-Jeghers syndrome with metastasizing duodenal carcinoma. *Gut*, **6**, 179-184.