

Mackenzie D H

(1975) *Recent Advances in Pathology*, vol 9. Ed. C V Harrison & K Weinbren. Churchill & Livingstone, Edinburgh; pp 183–216

O'Brien J E & Stout A P

(1964) *Cancer* 17, 1445–1455

Soule E H & Enriques P

(1972) *Cancer* 30, 128–143

Taylor G I & Daniel R K

(1973) *Journal of Plastic and Reconstructive Surgery* 52, 111–117

(1975) *Journal of Plastic and Reconstructive Surgery* 56, 243–253

Atypical necrolytic migratory erythema in association with a jejunal adenocarcinoma¹

N P J Walker BSC MRCP

Addenbrooke's Hospital, Cambridge CB2 2QQ

Necrolytic migratory erythema has been thought to be a specific eruption associated with glucagonoma. More recently it has been described in association with other non-malignant disorders. A case is reported with a jejunal adenocarcinoma, an association not previously described, in which the clinical appearance was atypical but the histological features were characteristic.

Case report

A 69-year-old male farmworker presented in May 1979 with a ten-day history of abdominal pain and distension. There was no relevant past medical history. Clinical examination and investigations showed a hiatus hernia, small bowel obstruction and a microcytic, hypochromic anaemia. At laparotomy a jejunal adenocarcinoma was resected. The postoperative course was satisfactory until he was admitted five months later with subacute small bowel obstruction; this settled with conservative therapy. On admission he was noted to have five areas of vesiculation and crusting up to 3 cm in diameter, on the left ankle, right forearm, right cheek and back, and an apparently gradually extending area of annular erythema on the right thigh. There was florid oral ulceration but the tongue and perineum were entirely normal. The eruption progressed over eight weeks: older lesions slowly enlarged, with some apparently healing centrally, and new lesions appeared (Figure 1). He developed an acute bilateral conjunctivitis. Investigations showed a raised alkaline phosphatase and patchy uptake on a liver scan. The rash was presumed to be related to dissemination of his malignancy. There was no response to potent topical steroids or prednisolone 100 mg daily. His condition gradually deteriorated and he was in considerable discomfort until death.

Post-mortem examination showed no evidence of metastases, or other neoplasia; death was due

¹ Case presented to Section of Dermatology, 18 December 1980. Accepted 18 August 1981

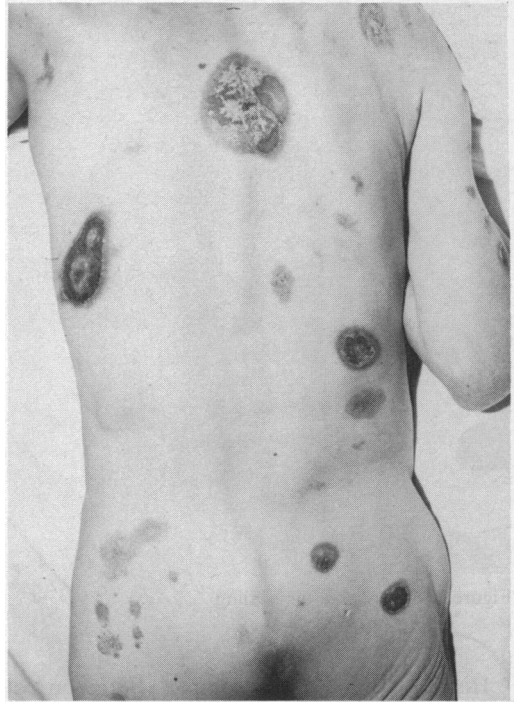

Figure 1. The eruption six weeks after it was first observed. Note the crusting, annular erythema and ulceration

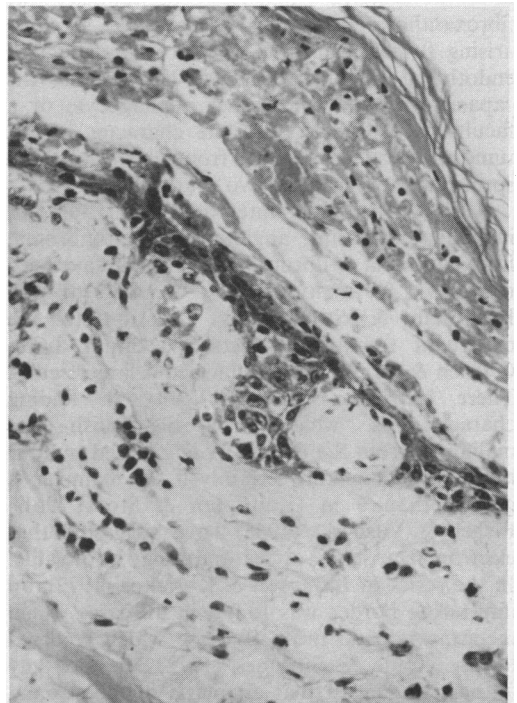


Figure 2. Skin biopsy, showing dyskeratosis, parakeratosis and necrosis of the epidermis

to bronchopneumonia. Results of other investigations conducted post mortem were as follows: serum zinc 7 µmol/l (normal range 11–18), glucagon 7 µmol/l (normal <30), polypeptide 310 pmol/l (normal <100), amino acid analysis relatively normal (elevated tyrosine and phenylalanine).

Skin biopsies (Figure 2), taken at various times, all showed similar changes of varying degree. Focal dyskeratosis and parakeratosis, with scattered foci of necrotic keratinocytes, progressed to confluent eosinophilic coagulative necrosis of the superficial layer. There was a chronic inflammatory cell infiltrate in the upper dermis; direct immunofluorescence was negative.

Discussion

Necrolytic migratory erythema is a well recorded clinical entity (Becker *et al.* 1942, McGavran *et al.* 1966, Church & Crane 1967, Wilkinson 1971). It consists of three main features: waves of extending annular or circinate erythema; superficial necrosis with shedding of skin; and complete resolution of an involved area within two weeks. The term became linked with diabetes mellitus and hyperglucagonaemia, due to an α-cell secreting pancreatic tumour, as the 'glucagonoma syndrome' (Mallinson *et al.* 1974). Amino acid analysis often showed a reduction in blood levels and it was reported recently that amino acid infusion improved the skin lesions in a patient with a glucagonoma (Norton *et al.* 1979).

In December 1979 three cases of necrolytic migratory erythema were reported (Goodenberger *et al.* 1979, Doyle *et al.* 1979), two in association with subtotal villous atrophy of the jejunal mucosa and one with hyperglucagonaemia and cirrhosis but no pancreatic tumour.

The eruption in our patient was not typical as the rash was not periorificial, and the tongue was not sore and red. The individual lesions extended more slowly and some showed no tendency to heal. However, the histological changes were characteristic of those seen in glucagonoma syndrome.

There is no evidence that our patient had a glucagonoma or other apud-cell tumour, though there is the possibility that significant hyperplasia was present. Serum amino acid analysis reflected our patient's general debility, but there were none of the features seen with a glucagonoma. The result of the slightly low serum zinc level was only available post mortem and zinc therapy was not tried. However, the concentration in this case is not one at which zinc deficiency has previously been reported as causing such a severe eruption.

The mechanism of the eruption in our patient, as also in the glucagonoma syndrome, is uncertain. More than twenty polypeptide

hormones have so far been isolated from the gastrointestinal tract. For many, such as gastrin, the structure, function, clinical and pathological significance are well understood. For others, the clinical and possible pathological roles have yet to be fully delineated, but it is known that a single tumour can be the source of more than one polypeptide (Belchetz *et al.* 1973). Perhaps a polypeptide other than glucagon can be responsible for similar clinical and histopathological findings.

Acknowledgement: I wish to thank Dr J R Anderson, Dr S R Bloom, Dr R H Champion, Dr B Cox, Dr L S Culank, Dr F C Harris, Dr N P Smith and others, especially Alison Rayner, for their help.

References

- Becker S W, Kahn D & Rothman S (1942) *Archives of Dermatology and Syphilology* **45**, 1069–1080
 Belchetz P E, Brown C L, Makin H L J, Trafford D J H, Mason A S, Bloom S R & Ratcliffe J G (1973) *Clinical Endocrinology* **2**, 307–316
 Church R E & Crane W A J (1967) *British Journal of Dermatology* **79**, 284–286
 Doyle J A, Schroeter A L & Rogers R S III (1979) *British Journal of Dermatology* **101**, 581–587
 Goodenberger D M, Lawley T J, Strober W, Wyatt L, Sangree M H jr, Sherwin R, Rosenbaum H, Braverman I & Katz S I (1979) *Archives of Dermatology* **115**, 1429–1432
 Mallinson C M, Bloom S R, Warin A P, Salmon P R & Cox B (1974) *Lancet* *ii*, 1–5
 McGavran M H, Unger R H, Racant L, Polk H C, Kilo C & Levin M E (1966) *New England Journal of Medicine* **274**, 1408–1413
 Norton J A, Kahn R, Schiebinger R, Gorschboth C & Brennan M F (1979) *Annals of Internal Medicine* **91**, 213–215
 Wilkinson DS (1971) *Proceedings of the Royal Society of Medicine* **64**, 1197–1198

Crohn's disease treated by elemental diet¹

C Ó'Moráin MB MRCPi

(for H B Valman MD FRCP)

Division of Clinical Sciences

Clinical Research Centre, Harrow HA1 3UJ

Short stature and delayed sexual maturation are manifestations of Crohn's disease which are difficult to treat in adolescent patients. Total parenteral nutrition (TPN) provides nutritional support and allows the diseased bowel to 'rest', and has been reported to be an effective means of inducing remission and restabilizing linear growth (Strobel *et al.* 1979). TPN is not without risk and requires careful and expert supervision. An

¹ Case presented to Section of Paediatrics, 28 November 1980. Accepted 20 May 1981