

# Problems in the Surgical Management of Thymic Tumors\*

LAMAR SOUTTER, M.D.,\*\* SHELDON SOMMERS, M.D.,\*\*\*  
ARNOLD S. RELMAN, M.D.,† CHARLES P. EMERSON, M.D.††

In the past few years increasing interest has been shown in thymomas because of their association with other disorders and their high rate of malignancy. Unfortunately, they are quite variable in their growth and histologic patterns, and no single system of nomenclature has been agreed upon by pathologists. In presenting 13 thymomas from the Boston City and Massachusetts Memorial Hospitals, we have attempted to describe clearly our tumors in generally acceptable terminology. New slides have been made when necessary to complete our studies. A correlation has been made between pathology, clinical behavior, and treatment. Most interesting has been the frequency of associated diseases. Our findings have to a large extent been correlated with the current literature.

## PATHOLOGY

Proper classification of thymic neoplasms as benign or malignant is difficult, and requires a close collaboration between the surgeon and pathologist, so that all available information may be utilized. Microscopically the presence of anaplastic tumor growth and obvious invasion are uncom-

mon, and as in the case of some neoplasms of salivary gland and thyroid a cancer may be recognized only by finding local invasive penetration of the fibrous tumor capsule or lymphatics. Multiple blocks chosen to include the periphery of the thymoma and any capsule are desirable.

Neoplasms of thymic tissue may arise from: (1) the parenchyma, or thymic reticulum, at present considered as of entodermal embryologic origin, (2) the lymphocyte component, and (3) the supporting connective tissues, most commonly fat. True thymomas are variously subdesignated, ranging from the detailed embryologic terminology of Loewenhaupt<sup>22</sup> to the preference of Castleman<sup>5</sup> for lumping all the subtypes together.

An analogy exists with neoplasms of the thyroid and salivary glands, which have in common with thymomas a branchial cleft origin, a tendency to local unobtrusive cancerous invasion, and the posing of difficult problems in diagnosis and classification to the average pathologist. Thymic parenchymal tumors in the present classification have been termed either adenoma or carcinoma.

Our 13 tumors fell into the following classifications: trabecular adenoma, one; reticular perithelial spindle cell adenoma, three; glandular adenoma, one; and adeno-squamous, one. Among the carcinomatous neoplasms, one each of the following tumors were found: trabecular, reticular perithelial spindle cell, reticular clear cell, glandular, and squamous. No undifferential or squamous adenomas were found, nor were there any undifferential or adeno-squamous carcinomas. A lymphosarcoma

\* Presented before the American Surgical Association, Chicago, Illinois, May 8-10, 1957.

\*\* Associate Professor of Surgery, Boston University.

\*\*\* Associate Professor of Pathology, Boston University.

† Associate Professor of Medicine, Boston University.

†† Associate Professor of Medicine, Boston University.




FIG. 1. A thymic adenoma, reticular spindle cell type, weighing 270 Gm., from a 48-year-old woman who had refractory anemia with a late postoperative remission.

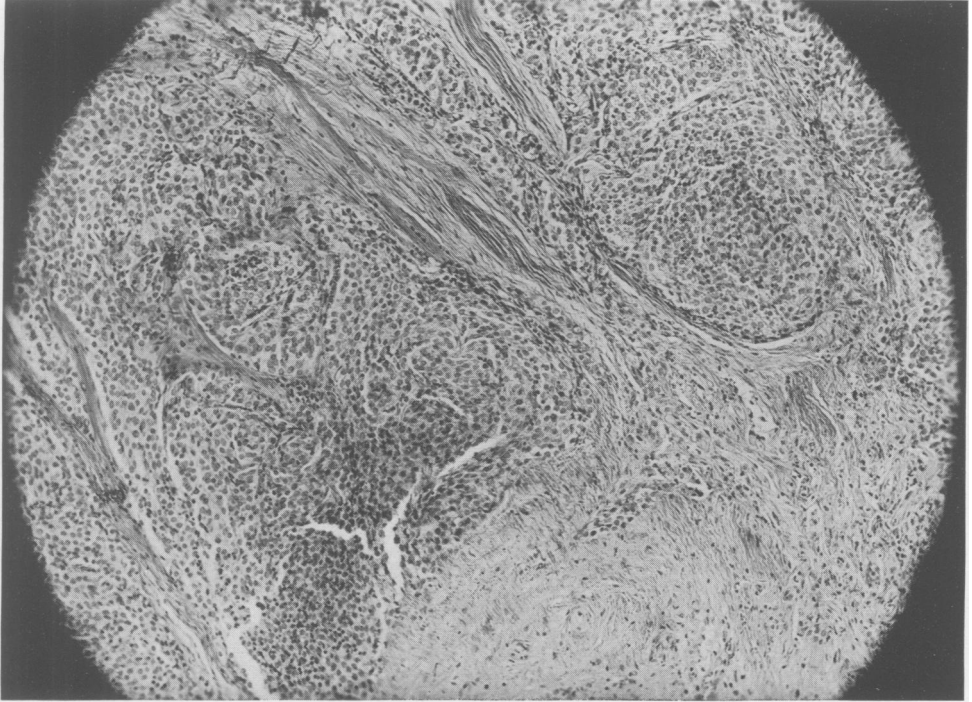
and a malignant lymphocytoma are included. Cysts, lipomas, embryonal carcinomas, teratomas, and so forth have been omitted.

Grossly, most thymomas are lobulated masses composed of firm yellow-tan moist tissue intersected by white fibrous trabeculae and surrounded by a fibrous capsule (Fig. 1). Microscopically, the most common pattern is a spindle cell growth with perithelial whorls, termed reticular perithelioma by Pope and Osgood (Fig. 2).<sup>26</sup> Less commonly, the reticular cells have a clear vacuolated cytoplasm and form groups that imitate lymphatic germinal centers.

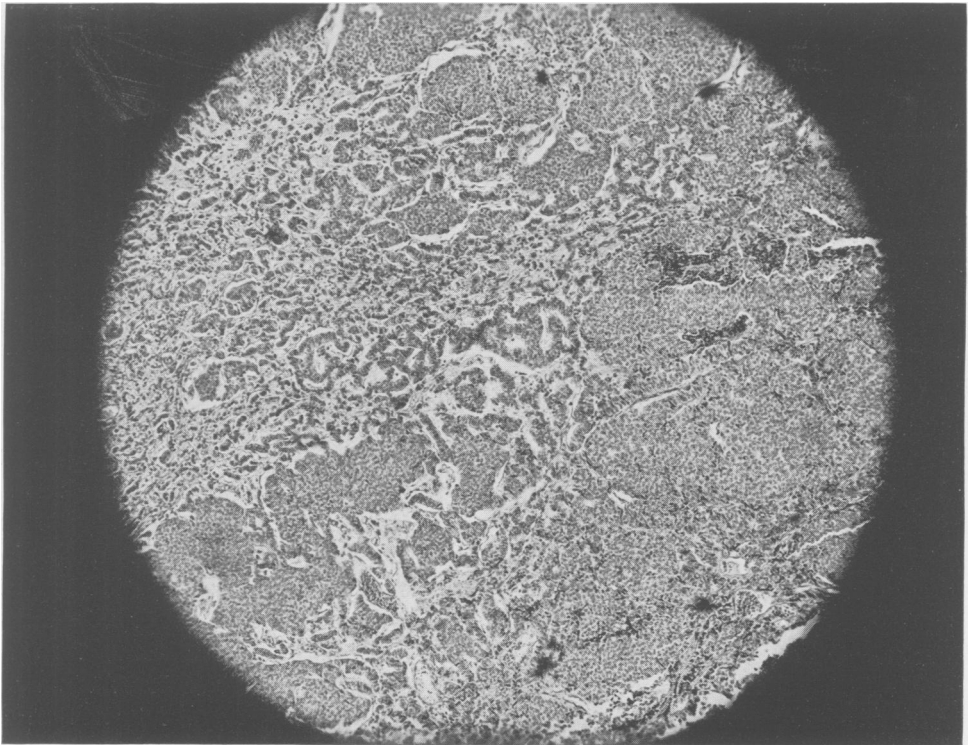
Other thymic adenomas and carcinomas have predominantly trabecular or glandular patterns reminiscent of adamantinomas, embryonal thyroid adenomas or certain salivary tumors. Poorly differentiated adenocarcinomatous growth characterizes the thymic carcinomas that accompany Cushing's syn-

drome (Fig. 3). Adenosquamous and squamous neoplasms produce more or less numerous characteristic or malformed Hassall's corpuscles, the histologic hallmark of adult thymus (Fig 4).

Primary thymic lymphomas, while common in mice, are rare in humans. The difficulties of distinguishing between hyperplasia and malignant lymphoid neoplasia are well known, but cytologic anaplasia and an infiltrative invasion of the fibrous capsule, trabeculae and vessel walls are useful indices of lymphoma (Fig. 5). The term benign thymic lymphomas is best avoided, and instead the designation thymic hyperplasia appears preferable. Myasthenic patients may show either thymic neoplasia or hyperplasias involving both reticulum cells and lymphocytes. Our cases with hypoplastic anaemia were observed to have malformed lymphocyte nuclei with a coarse clumped nuclear chromatin, similar to cyto-



**FIG. 2.** Spindle cell thymic reticular carcinoma, of low-grade malignancy, that invaded the pericardium of a 56-year-old man. There has been no recurrence for 4 years after removal. All photomicrographs are from slides stained with hematoxylin and eosin.  $\times 125$ .



**FIG. 3.** Glandular thymic carcinoma, of the pattern observed with Cushing's syndrome, from the surgically resected specimen weighing 1398 Gm.  $\times 125$ .

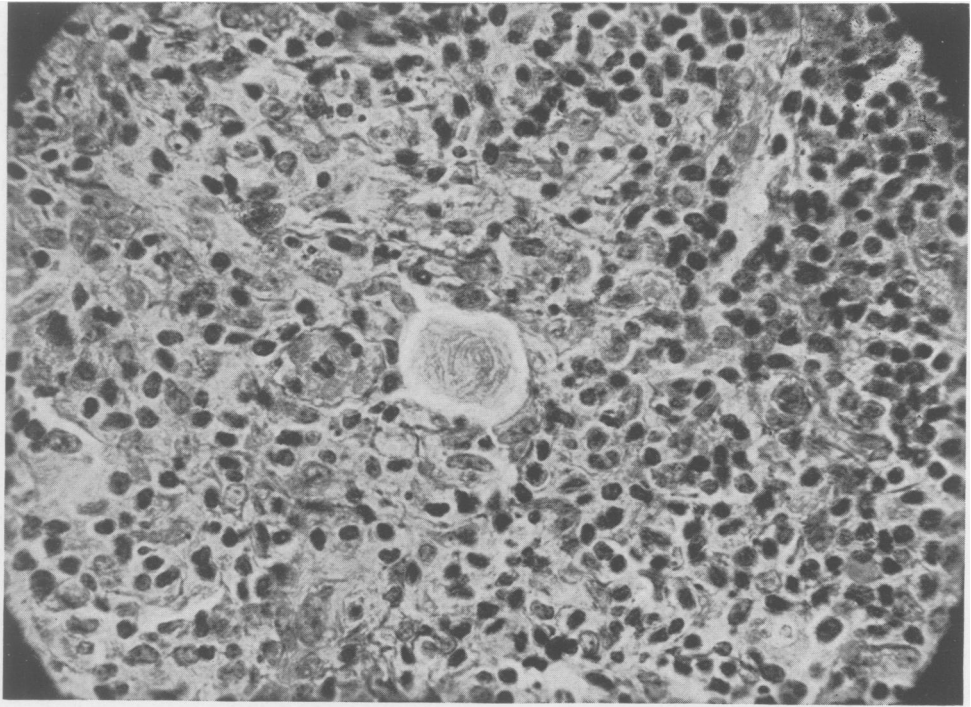


FIG. 4. Simulation of a Hassall's body by metastatic squamous thymic carcinoma in a cervical lymph node, from a 38-year-old man.  $\times 600$ .

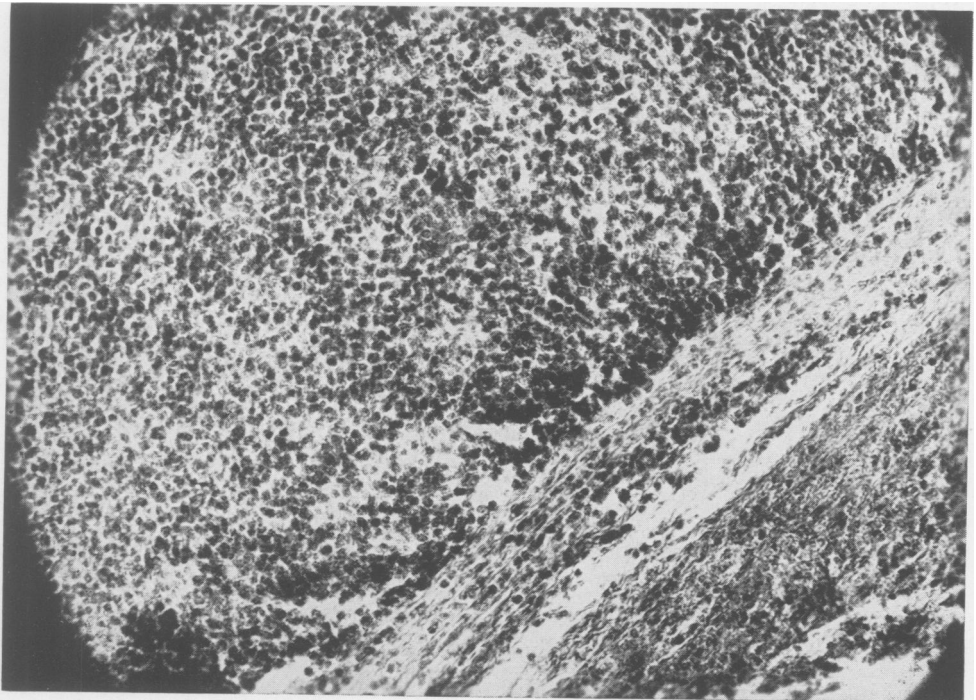


FIG. 5. Primary thymic lymphosarcoma, with invasion of the fibrous capsule by lymphoblastic cells, from a woman aged 67 years who died apparently of pulmonary complications.  $\times 500$ .

TABLE 1. A Comparison of the Incidence and Type of Spread of Malignant Thymic Tumors as Reported in Several Recently Published Series of Cases. The Fifth is Our Own

	No. of Tumors	Malignant	Local Invasion	Implants	Distant Metastases
Seybold <i>et al.</i>	45	11	10	2	0
Binkley <i>et al.</i>	21	16	7	0	0
Effler & McCormack	19	16	10	4	1
Ringertz & Lidholm	19	4	1	2	0
Soutter <i>et al.</i>	13	7	7	1	2
Totals	117	54	35	9	3

logically abnormal components found in the bone marrow.

#### CLINICAL CORRELATION

Seven of our tumors were classified as malignant on the basis of anaplasia or local invasion. One of these, a trabecular carcinoma, had two intrathoracic implants. Two other patients, one with a glandular carcinoma and Cushing's syndrome and the other with a squamous carcinoma had microscopic evidence of embolic spread to lymph nodes isolated from the tumor mass. The last patient, in addition, had suggestive evidence of a blood borne metastasis in the form of a sharply localized pain occurring in the sacrum which disappeared after radiotherapy and nitrogen mustard administration. No bony lesion has been demonstrated radiologically; a biopsy has not as yet been performed. A comparison of our cases with others reported recently in the literature is presented in Table 1.

Seybold and his associates<sup>31</sup> found 11 malignant tumors out of 45, 10 showed local invasion, two had spread by implantation, but none had distant metastases. Gray,<sup>15</sup> in a later report from the same clinic, stated that among 75 thymic tumors no distant metastases had occurred. Binkley and his associates<sup>3</sup> found 16 to be malignant among 19 thymic tumors. Seven had invaded locally, but there was no distant or embolic spread. Effler and McCormack<sup>12</sup> reported 16 out

of 19 thymomas as malignant, 10 with local invasion, four with implants, and 1 with lymph borne metastases to distant nodes. Only four of Ringertz and Lidholm's<sup>29</sup> 19 tumors were malignant. Despite the variations among these series of cases, it is reasonable to conclude that thymomas are malignant about 50 per cent of the time, and that local invasion into the pericardium and lung or about the great vessels occurs in roughly one out of three. Implants in the chest cavity may be found in a sixth of the malignant tumors, but lymphatic embolic spread is rare.

Clinically, thymomas are both difficult to diagnose and to treat. Other tumors of the thymus including metastases to it from the lung or other organs are difficult to separate diagnostically from thymomas without actual biopsy. In our own experience, transthoracic exploration through the sternum or the side of the thorax towards which the tumor projected has provided a satisfactory exposure for diagnosis of five benign and four malignant tumors.

We agree with Castleman<sup>5</sup> that to insure a correct diagnosis, a large piece of tumor should be obtained. In two of these cases, furthermore, a gross penetration of tumor into surrounding structures provided more conclusive evidence of malignancy than did microscopic sections. The four remaining tumors were diagnosed microscopically at autopsy.

Evidence of malignancy was suggested by the presence of the superior vena cava syndrome in four patients with malignant tumors. It was absent in all of the patients with benign growths and in three whose thymic carcinomas were located in the lower mediastinum. Six of the patients with thymic cancers had had pneumonia or lung abscess, but so had two with benign growths. Chest pain of variable nature was experienced by all suffering from malignant thymomas and three without cancer.

#### TREATMENT

Surgical removal of thymoma at an early date is indicated for therapeutic as well as diagnostic reasons. Despite the fact that these tumors, if malignant, remain relatively localized for long periods of time, their tendency to invade surrounding structures and wrap themselves about the great vessels may later prevent surgical eradication. Among our malignant tumors, only one, a reticular carcinoma, was completely resectable, but some pericardium had to be taken with the tumor. This patient is alive and well four years later. In another, a complete resection including pericardium and left lung was feasible, but the patient died of cardiac arrest. In a third patient, enough of the thymic carcinoma was removed to relieve compression of the vena cava, but extensive involvement of the left lung hilum and great vessels prohibited more complete extirpation. The other four patients were proved to have inoperable growths, one at the time of surgery and the rest at autopsy. One patient survived seven years after biopsy of a thymic lymphosarcoma. The third patient is fairly well under treatment over a year after partial thymic resection. One of the patients with a benign thymoma died of a widespread strongyloides infestation without operation.

Three patients with malignant tumors died without operation. The extent of a malignant thymic lymphocytoma with com-

pression of both major bronchi was responsible for terminal pneumonia in a child of nine years. Myasthenia gravis complicated by pneumonia caused the death of a second case. The last patient died of a lung abscess secondary to bronchial obstruction. Surgical resection of the benign tumors posed no unusual problems. Of the five patients so treated, two are alive and well. One died of hepatitis nine years postoperatively, a second of hypertension eight years later, and the last of agammaglobulinemia and infection six years postoperatively. None had any evidence of recurrent tumor.

Treatment of thymic carcinoma by irradiation is often effective. No very definite correlation can be made with cell type of the tumors because of the variations of pathological diagnosis. Our own experience is confined to two cases. One, a lymphosarcoma in a woman of 77, failed to respond to a small dose of irradiation (1500 roentgens). The tumor was so indolent, however, that it showed no particular growth over the course of the next six years, but ultimately did grow and probably caused the pneumonia from which she died at another hospital. No autopsy was performed. The second patient, a 37-year-old man whose squamous cell carcinoma could only be partially resected, received 1,025 roentgens to his anterior mediastinum. He returned a year later with the main tumor mass still smaller than it had been postoperatively but with enlarged glands in the neck, axillae and groins, and with extension of the tumor into the left lung. A lymph node removed from the neck contained tumor. He had had a possible area of blood borne metastasis in his sacrum treated radiologically at another hospital. His response to nitrogen mustard (0.6 milligrams per kilogram body weight in divided doses) was excellent; palpable lymph nodes diminished rapidly in size. They returned, however, six weeks later along with a cough and general malaise. His response at that time to triethylene melamine, 15 milligrams per week,

TABLE 2. *The Relationship of Thymoma to Certain Diseases with Which It Has Been Associated*

	Incidence or No. of Cases	Frequency of Malignancy	No. Resected	Results of Resection
Myasthenia Gravis	29.4%*	40%*		Variable
Cushing's Syndrome	9 Cases	100%	2	Died
Hypoplastic Anemia	16 Cases	0	10	Variable
Acquired Agammaglobulinemia	4 Cases	0	3	Unfavorable

\* Castleman & Norris found 97 thymomas among 330 patients with myasthenia. 40% of 30 tumors in Eaton & MacDonald's series were demonstrated surgically to be invasive or have metastases.

was negligible, but when 40 milligrams of prednisone daily was added, his symptoms again regressed. The patient is now well enough to be able to work. Others have reported a favorable response to irradiation.<sup>12</sup>

There is some reason, based upon the responsiveness of the thymus to the secretions of other glands, to think that its tumors might be modified by the administration of hormones. Hammar<sup>16</sup> was the first to show that the gland reaches its maximal growth at puberty, then slowly decreases in size. Castration in animals, on the other hand, will prevent thymic involution. The administration of estrogens or androgens will hasten it. Adrenocortical steroids, stress, wasting disease, or infections will cause the gland to shrink. The gland will enlarge, however, in the presence of acromegaly, Addison's disease, or thyrotoxicosis.<sup>32</sup> Thymic tumors may, of course, be autonomous and independent of factors influencing thymic size, but others as well as ourselves have found thymic tumors responsive to adrenocortical secretions.<sup>33</sup>

#### ASSOCIATED DISEASES

The functions of the thymus remain obscure, but the relationship of tumors or hyperplasia of the gland to certain diseases is one of growing importance. Specifically, these diseases are myasthenia gravis, Cushing's syndrome, hypoplastic anemia, and agammaglobulinemia (Table 2). Among our thirteen patients with solid thymic neoplasms, one had myasthenia gravis and a

second developed it after resection of a thymoma. One patient had Cushing's syndrome, two had hypoplastic anemia, and one of these later developed agammaglobulinemia.

Castleman and Norris<sup>16</sup> found thymomas in 29.4 per cent of persons suffering from myasthenia gravis; Eaton and Clagett<sup>11</sup> reported that 40 per cent of the thymomas they found associated with this disease were malignant. One of our patients with myasthenia gravis had a trabecular carcinoma which was invasive and had spread by implantation, as determined at autopsy. The other patient was a 48-year-old female with hypertension. She returned 22 months after the removal of a thymoma because of myasthenia gravis of five weeks duration. She had a very favorable response to the removal of the residual gland and is alive and well eight years later. Her hypertension and that of another patient in this series were unaffected by thymectomy. Gray<sup>15</sup> has reported five cases of myasthenia occurring subsequent to excision of a thymic tumor. This experience makes us believe that the entire gland should be removed along with the tumor when possible in treating thymomas.

The occurrence of thymoma in Cushing's syndrome is rare. Cope and Raker,<sup>9</sup> despite diligent search, could not find a single one in 46 cases of Cushing's syndrome and Knowlton<sup>20</sup> found none in a series of 38 cases. Castleman, who has reviewed the pathologic material on the eight known



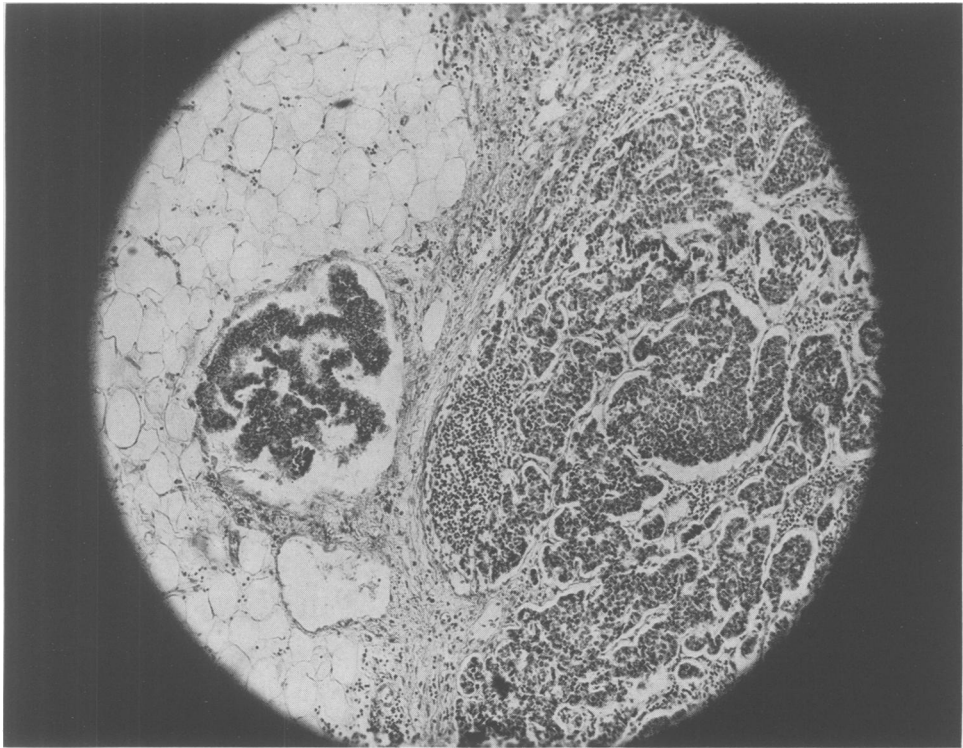


FIG. 6. Metastatic embolic spread of glandular thymic carcinoma to a mediastinal lymph node, from the same case of Cushing's syndrome illustrated in Figure 3.  $\times 25$ .

cases to date, has been struck by the similarity of microscopic pattern among them (Fig. 6). In fact, when he examined the tumor from our patient microscopically, he remarked without foreknowledge that the patient must have Cushing's syndrome. Most of these tumors have been small and encapsulated but mitotic figures were frequent. One other case besides our own had lymphatic metastases. Two others showed calcification. For the sake of brevity, we listed the important data on our patient in Table 3. He was a 32-year-old ex-marine who entered the hospital because of a chest tumor (Fig. 7). Since this tumor was demonstrated by serial roentgenograms to be growing rapidly, we determined to remove it after a ten day preparation with testosterone propionate and restoration of his electrolyte balance. The tumor invaded the pericardium and left lung and was en-

wrapped about the great vessels. He died of cardiac arrest when the pericardium was opened. Resuscitative measures were unavailing. The patient's tumor measured  $25 \times 26 \times 9.5$  centimeters and weighed 1396 grams (Fig. 8). It had metastasized to a single lymph node at a distance from the tumor. The adrenals weighed a total of 29 grams and showed adrenal cortical hyperplasia. A chemical analysis of the tumor failed to demonstrate the presence of any ketonicsteroids. The only other reported operative removal of a thymoma in this disease also resulted in a fatality.<sup>17</sup>

There have been 16 cases of thymic neoplasms associated with acquired idiopathic hypoplastic anemia recorded in the literature. Matras and Priesel first reported this syndrome on the basis of autopsy findings in 1928.<sup>24</sup> Since then similar autopsy cases have been reported by Opsahl;<sup>25</sup> Radojevic



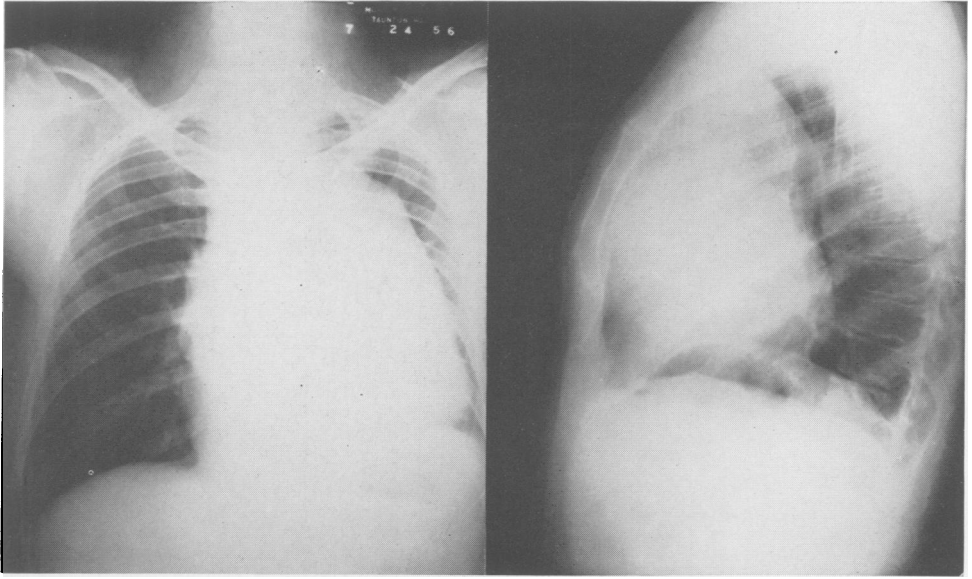


FIG. 7. Chest roentgenograms of a patient with glandular carcinoma of the thymus and Cushing's syndrome.

and Hahn;<sup>27</sup> Weinbaum and Thompson;<sup>35</sup> Davidsohn;<sup>10</sup> and Stibbe.<sup>34</sup> In addition, Wintrobe had a patient with thymic hyperplasia and aplastic anemia.<sup>36</sup> In 1945, Humphreys and Southworth<sup>18</sup> reported that the excision of a thymic tumor had cured a patient with aplastic anemia. Other thymic resections in this disease have been published

by Chediak, Fuste, and Rosales;<sup>8</sup> Chalmers and Boheimer<sup>7</sup> (two cases); Bakker;<sup>1</sup> Ramos;<sup>28</sup> Bayrd and Bernatz<sup>2</sup> (two cases); and our own two patients previously described by Ross, Finch, Street, and Strieder.<sup>30</sup> The tumors have been benign in appearance and encapsulated. Ours were similar to each other and fall into the group called

TABLE 3. *Essential Data Obtained Upon Our Patient with Cushing's Syndrome*

Appearance: Moon face, protuberant abdomen, wasting of limbs.	
Strength: Weak, uncertain on feet.	
Mental State: Disoriented, periods of coma.	
History: 6 months of renal stones, "diabetes," polydipsia, polyuria, 60 lb. weight loss, malaise, easy fatigability, hoarseness.	
Lab. Findings:	
Blood	Urine
F.B.S.—93 to 144 mg. %	Sugar—3+
Hgb.—14.3 Gm.	11-Oxysteroids—41 mg.,
W.B.C.—5000	after ACTH—86 mg.,
CO <sub>2</sub> —34.5 mEq./L.	then 124 mg.
Chlorides—98 mEq./L.	
Na—144 mEq./L.	17-Ketosteroids—49 mg.,
K—2.8 mEq./L.	after ACTH—60 mg.,
Ca—4.2 mEq./L.	then 100 mg.
Albumin—3.6 Gm. %	
Globulin—2.6 Gm. %	

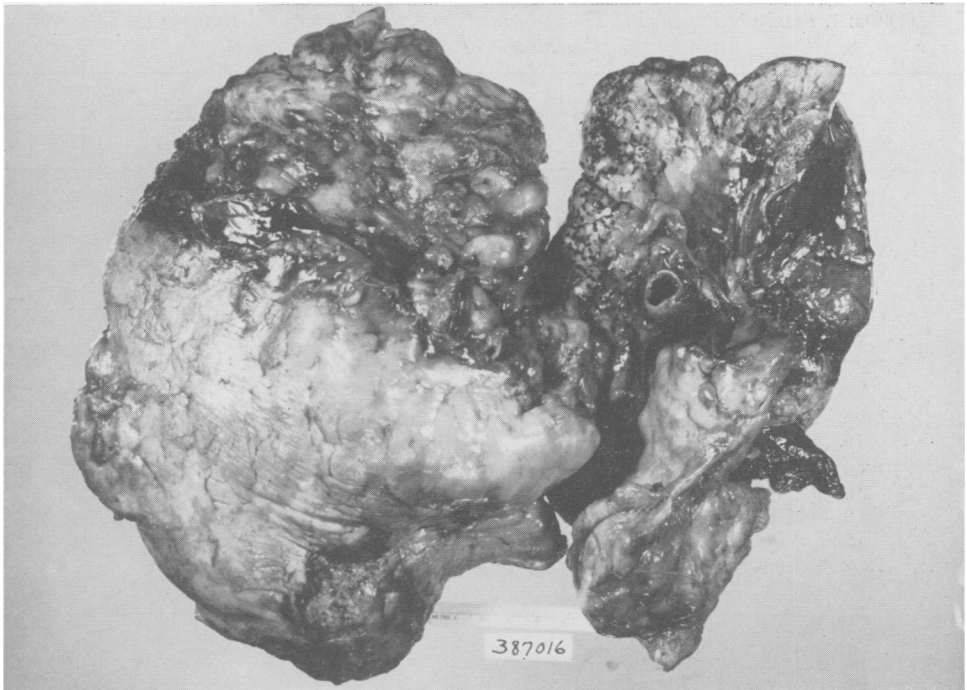


FIG. 8. The tumor and the left lung of the patient with Cushing's syndrome. A portion of the tumor separated from the main mass and invading the lung can be seen attached to it.

reticular spindle cell perithelial type. The results of thymectomy are variable and are listed in Table 4. Humphrey's patient died of pneumonia ten months after surgery. We have no further report on Chediak's patient who also was apparently cured. Two patients had an immediate reticulocyte response to surgery, but one, Bakkar's, died three weeks later of myocarditis. The other, Chalmer's first case, had a relapse but was again improved following splenectomy and treatment with ACTH. A remission was ultimately achieved by a subsequent course of ACTH. Late improvement has occurred in two other patients. The first of these (Chalmer's second case) did not show any improvement until after splenectomy and ACTH administration. Both of Chalmer's patients showed no response to ACTH prior to thymectomy. Our second case (E. T.) was reported by Ross in 1954 as failing to respond to surgery. This was true for four

years following excision of her thymoma by John W. Strieder in 1951. During this time, she continued to show a lack of erythropoiesis and required over 30 transfusions a year. In 1955, however, her transfusion requirements dropped to 11; in 1956, to one; and when last seen, her hemoglobin was 10.8 grams, a bone marrow biopsy showed erythropoiesis, and she felt well.

There have been four anemic patients who have shown no response to thymectomy. The first was a 77-year-old man described by Ramos who died postoperatively. The next two are Bayrd's cases reported five months and two years after surgery, and the last is our first case (L. L.) who died six years after thymectomy of cardiac failure, agammaglobulinemia, diabetes, and sepsis without ever showing any improvement. She had had a splenectomy prior to thymectomy. She was unaffected by ACTH administration. Altogether she received a total

TABLE 4. Results of Resection of Thymoma in Hypoplastic Anemia as Reported in the Literature. Cases 9 and 10 Are Our Own

Case	Author	Age and Sex	Myasthenia	Result		Other Treatment
				Immediate	Late	
1	Humphreys & Southworth, 1945	58, F	0	Cured	Died	0
2	Chediak <i>et al.</i> , 1953	47, M	0	Cured	—	—
3	Chalmers & Boheimer, 1954	45, M	Yes	Improved	Remission	Splenectomy, ACTH
4	Chalmers & Boheimer, 1954	62, F	0	Unimproved	Improved	Splenectomy, ACTH
5	Bakker, 1954	62, F	Yes	Improved	Died	0
6	Ramos, 1956	77, M	0	Died	—	—
7	Bayrd & Bernatz, 1957	68, M	0	Unimproved	—	—
8	Bayrd & Bernatz, 1957	58, M	0	Unimproved	Unimproved	?
9	Ross, Soutter <i>et al.</i> , 1954 & '57	44, F	0	Unimproved	Unimproved, Died	Splenectomy, ACTH
10	Ross, Soutter <i>et al.</i> , 1954 & '57	45, F	0	Unimproved	Remission	—

of 230 transfusions. At autopsy three accessory spleens, adrenal atrophy, hepatomegaly, total absence of thymic tissue, hemosiderosis and erythroid aplasia of the bone marrow were among the principle findings. The combined results of the ten thymectomies reported to date are, therefore, two cures, two patients with early improvement, two with late, one operative death, and three who had shown no response.

Bruton,<sup>4</sup> in 1952, described agammaglobulinemia as a clinical entity. At first it was believed to be sex linked and congenital, but acquired cases in adults have been appearing in the literature with increasing frequency. Some 24 cases have now appeared including our own. The onset of the disease is heralded by bouts of infection, usually pulmonary<sup>14</sup> or dermatologic. Laboratory studies have demonstrated very low levels or absence of circulating isoagglutinins, antibodies, and gamma globulin. The patients show little or no immunological response to challenge doses of antigens. The cause of the disease is not known.

Three cases associated with chronic lymphocytic leukemia have been reported.<sup>19</sup> Good was the first to publish the association of a thymoma with this disease.<sup>13</sup> In his case, the diagnosis of agammaglobulinemia was not made until two years after resection. A low serum protein (5.4 grams) at the time of operation and attacks of pneumonia prior to surgery suggest that the disease may have been present earlier. Another case was reported by Martin, Gordon, and McCullough<sup>23</sup> of a woman who had had a small anterior mediastinal shadow irradiated after she had been suffering from infections for about a year. The mass shrank, she continued to have infections, particularly pulmonary ones, and ultimately (seven years after irradiation) the diagnosis of hypogammaglobulinemia was established. Ramos described a third case of a man with hypoplastic anemia, thymoma, and agammaglobulinemia diagnosed at the same time.<sup>28</sup> The tumor had been present for two years. The patient had infections for only a few months. He died after resection of the thymoma (Table 5).

TABLE 5. *The Relationship of the Onset and Treatment of Thymoma to Agammaglobulinemia. The Tumors appeared before Agammaglobulinemia was diagnosed in all Instances*

Case No.	Author	Tumor		Agammaglobulinemia		Result of Treating Thymus
		Found	Treated	1st Symptoms	Diagnosed	
1	Good, 1954	1951	1951	1950	1953	Unimproved
2	Martin <i>et al.</i> , 1956*	1947	1947	1946	1954	Unimproved
3	Ramos, 1956	1953	1955	1955	1955	Died
4	Soutter <i>et al.</i> , 1957	1945	1949	1951	1955	Unimproved

\* A thymoma was not diagnosed in this case. Irradiation was given for an anterior mediastinal mass.

Our own patient (L. L.) has previously been referred to as a case of hypoplastic anemia. Briefly, her thymoma was first detected in 1945, she had a splenectomy in 1948, and then a thymectomy in 1949. Prior to thymectomy, her Coombs' test had repeatedly been positive in high dilutions (1:600). During the course of the next year, the strength of the reactions diminished. The test remained weakly positive until 1953, when it became negative. In 1951, she began to be subject to a variety of infections, mostly pulmonary, which became quite frequent by 1955. At that time, circulating isoagglutinins had disappeared from her blood, she made no response to challenge doses of various antigens and no gamma globulin was detectable in her serum by electrophoretic analysis. She responded poorly to treatment with gamma globulin and died in four months.<sup>21</sup>

DISCUSSION

The evident relationship of thymoma to myasthenia, Cushing's syndrome, hypoplastic anemia, and acquired agammaglobulinemia is interesting. Malignant thymomas have been present in all of the Cushing's syndrome cases and 40 per cent of those with myasthenia. The thymomas found in the other diseases are apparently non-malignant. Removal of the thymoma is, therefore, more strongly indicated in the first two diseases for treatment of the tumor itself. The

risk is not considered great in myasthenia if the disease is well under control. The risk of thymectomy in Cushing's syndrome, judging by Hubble's and our own experience is probably prohibitive, and the operation should be postponed until a good response to adrenalectomy has been achieved. Treatment of the thymic neoplasm with radiation therapy might control it until its resection became feasible. The function of the thymus in myasthenia is still enigmatic. In Cushing's syndrome thymoma has been rare. In all the cases to date, the cellular pattern of the tumors have been quite similar and in each, hyperplastic adrenal cortex has been found at autopsy. This evidence might suggest that the adrenal secretions provoked the tumor, but it must be kept in mind that the usual thymic response to adrenal cortical overactivity is to shrink. In both hypoplastic anemia and acquired agammaglobulinemia, the rarity of the diseases and the rarity of thymoma makes the association of the two appear something more than a coincidence. If not coincidental, what is the relationship? Spontaneous remissions occur in myasthenia gravis but in idiopathic hypoplastic anemia they are so rare as to be negligible. Hence, four favorable early hematopoietic responses to thymectomy and two late ones suggest a causative relationship. One can also postulate that the removal of an unfavorable influence upon the bone marrow will not necessarily result in its resuming erythro-

poietic activity, particularly if its potentiality for cellular proliferation is permanently damaged. This may explain our late remission. Whether or not thymectomy in the absence of a tumor would be helpful in this disease is a matter of conjecture.

In agammaglobulinemia, the relationship is very obscure. In two of the cases (Good's and our own), the diseases became full blown sometime after thymectomy. In Martin's case, the disease developed after irradiation of an anterior mediastinal shadow. These three cases, particularly our own, suggest a causative relationship between thymic treatment and the disease. It is probably incorrect to reach any firm conclusion on this scanty evidence, particularly as Ramos' patient had the disease prior to thymic removal. Viets, furthermore, has seen 125 patients who have undergone thymectomy. Among the survivors, he has stated, no undue infection has been seen.<sup>35</sup> It is concluded none the less that thymectomy was not beneficial and, perhaps, that all patients after thymectomy for any cause should be observed for the development of agammaglobulinemia.

#### CONCLUSION

Thirteen cases of thymoma have been discussed in regard to their treatment and their association with certain other disorders. The frequent development of malignancy in thymomas is considered an indication for their removal whenever possible. The sensitivity of some thymic tumors to irradiation and to hormonal therapy is offered as an alternative when adequate surgery is impossible.

The effect of thymectomy upon myasthenia gravis is unpredictable, upon Cushing's syndrome has been harmful, in hypoplastic anemia is often helpful, and in agammaglobulinemia is of no known benefit.

#### ACKNOWLEDGMENT

The authors wish to express their appreciation to Drs. Stanley L. Robbins, Henry M. Lemon, and Herbert H. Wotiz for assistance in gathering material for this paper. They also wish to thank Dr. John W. Strieder for permission to include some of his cases.

#### BIBLIOGRAPHY

1. Bakker, P. M.: Enkele opmerkingen bij twee gezwellen van de thymus. *Nederl. tijdschr. v. geneesk.*, **98**: 386, 1954.
2. Bayrd, E. D. and P. E. Bernatz: Benign Thymoma and Agenesis of Erythrocytes. *J. A. M. A.*, **163**: 723, 1957.
3. Binkley, F. M., J. D. Thoburn, H. B. Stephens and O. V. Grimes: Mediastinal Tumors of Thymic Origin. *Calif. Med.*, **78**: 267, 1953.
4. Bruton, O. C.: Agammaglobulinemia. *Pediatrics*, **9**: 722, 1952.
5. Castleman, B.: Tumors of the Thymus Gland. Atlas of Tumor Pathology, Section V, Fascicle 19, Armed Forces Institute of Pathology. Washington, D. C., 1955.
6. Castleman, B. and E. A. Norris: The Pathology of the Thymus in Myasthenia Gravis. *Medicine*, **28**: 27, 1949.
7. Chalmers, J. N. M. and K. Boheimer: Pure Red Cell Anaemia in Patients with Thymic Tumours. *Brit. M. J.*, **2**: 1514, 1954.
8. Chediak, A. B., R. Fuste and G. V. Rosales: Timoma y anemia aplastica. *Arch. Hosp. Univ. Habana*, **5**: 27, 1953.
9. Cope, O. and J. W. Raker: Cushing's Disease. *New Eng. J. Med.*, **253**: 119, 1955.
10. Davidsohn, I.: Hemochromatosis, Thymoma, Severe Anemia and Endocarditis in a Woman. *Illinois M. J.*, **80**: 427, 1941.
11. Eaton, L. M. and O. T. Clagett: Thymectomy in the Treatment of Myasthenia Gravis. *J. A. M. A.*, **142**: 963, 1950.
12. Effler, D. B. and L. J. McCormack: Thymic Neoplasms. *J. Thoracic Surg.*, **31**: 60, 1956.
13. Good, R. A.: Agammaglobulinemia. *Bull. Univ. Minn. Hosp.*, **26**: 1, 1954.
14. Good, R. A. and W. F. Mazzitello: Chest Disease in Patients with Agammaglobulinemia. *Dis. Chest*, **29**: 9, 1956.
15. Gray, H. K.: Discussion of Effler, D. B. and L. J. McCormack: Thymic Neoplasms. *J. Thoracic Surg.*, **31**: 79, 1956.

16. Hammar, J.: *Über Gervicht, Involution und Persistenz der Thymus im Postfötalleben des Menschen.* Arch. J. Anat. u. Phys., Anat. Abtlg. Suppl., 92: 91, 1906.
17. Hubble, D.: *Cushing's Syndrome and Thymic Carcinoma.* Quart. J. Med. (new series), 18: 133, 1949.
18. Humphreys, G. H. II, and H. Southworth: *Aplastic Anemia Terminated by Removal of a Mediastinal Tumor.* Am. J. M. Sc., 210: 510, 1945.
19. Jim, R. T. S. and E. H. Reinhard: *Agammaglobulinemia and Chronic Lymphocytic Leukemia.* Ann. Int. Med., 44: 790, 1956.
20. Knowlton, A. J.: *Cushing's Syndrome.* Bull. New York Acad. Med., 29: 441, 1953.
21. Lambie, A. T., B. W. Burrows and S. C. Sommers: *Clinical Pathological Conference—Mediastinal Tumor, Refractory Anemia and Agammaglobulinemia.* Am. J. Clin. Path. (in press), April 1957.
22. Lowenhaupt, E.: *Tumors of Thymus in Relation to the Thymic Anlage.* Cancer, 1: 547, 1948.
23. Martin, C. M., R. S. Gordon and N. B. McCullough: *Acquired Hypoglobulinemia in an Adult.* New Eng. J. Med., 254: 449, 1956.
24. Matras, A. and A. Priesel: *Über einige Gewächse des Thymus.* Beitr. path. Anat., 80: 270, 1928.
25. Opsahl, R.: *Thymus karcinom og aplastik anemi.* Nord. med., 2: 1835, 1939.
26. Pope, R. H. and R. Osgood: *Reticular Perithelioma of the Thymus.* Am. J. Path., 29: 85, 1953.
27. Radojevic, S. and A. Hahn: *Berinflusst der Thymus die Zahl der Granulozyten? Strahlentherapie,* 53: 90, 1935.
28. Ramos, A. J.: *Diagnostic Problems: Presentation of a Case.* J. A. M. A., 160: 1317, 1956.
29. Ringertz, N. and S. O. Lidholm: *Mediastinal Tumors and Cysts.* J. Thoracic Surg., 31: 458, 1956.
30. Ross, J. F., S. C. Finch, R. B. Street and J. W. Strieder: *The Simultaneous Occurrence of Benign Thymoma and Refractory Anaemia.* Blood, 9: 935, 1954.
31. Seybold, W. D., J. R. McDonald, O. T. Clagett and C. A. Good: *Tumors of the Thymus.* J. Thoracic Surg., 20: 195, 1950.
32. Soffer, L. J.: *Diseases of the Endocrine Glands,* second edition. Lea and Febiger, Philadelphia, 1956, pp. 1032.
33. Soffer, L. J., J. L. Gabrilove and B. S. Wolf: *Effect of ACTH on Thymic Masses.* J. Clin. Endocrinol. & Metab., 12: 690, 1952.
34. Stibbe, P. O.: *Thymoom en aplastische Anaemie.* Nederl. tijdschr. v. geneesk., 99: 3782, 1955.
35. Viets, H. R.: *Personal Communication.*
36. Weinbaum, J. G. and R. F. Thompson: *Erythroblastic Hypoplasia Associated with Thymic Tumor and Myasthenia Gravis.* Am. J. Clin. Path., 25: 761, 1955.
37. Wintrobe, M. M.: *Clinical Hematology,* third edition. Lea and Febiger, Philadelphia, 1951, pp. 533.

---

#### DISCUSSION

DR. HUMPHREYS: Dr. Davis, members and guests: I agree with Dr. Davis that Dr. Soutter is to be congratulated on bringing up this perplexing subject. He has succeeded in proposing more questions than he has answered.

We have been interested in this problem for some time, both in relation to myasthenia gravis and the case that Dr. Southworth and I reported some years ago, to which Dr. Soutter alluded.

Recently Dr. Lattes, pathologist on our staff, reviewed all our cases and analyzed 80 cases of surgically resected thymomas. He specifically excluded all cases which metastasized, on the ground that these were not thymomas but carcinomas. Here we have a semantic problem, right away, in relation to the pathologist's attitude, since if one defines a thymoma as a tumor which does not metastasize, then, what is a malignant thymoma?

However, there were a number of these tumors which were malignant in the other sense that Dr. Soutter speaks of, that is, local invasion. There were 6 different pathologic types, of which the two commonest, lymphoid and epithelial, constituted 56 of the 80 cases. Twenty-one patients had myasthenia gravis; indeed, they were operated upon because they had it. However, only one of these has had a long-term apparent cure, of about 10 years. Forty-six were symptomatic in some other way.

Of the myasthenic cases, 13 were lymphoid, and the other were epithelial. There was one other case of aplastic anemia which also appeared to be relieved by removal of the thymus. The patient we reported apparently had an immediate response in terms of a reticulo-cytosis; she recovered from anemia and was able to repay the blood bank on