

**THE PARALYSIS OF INVOLUNTARY MUSCLE. Part II.**  
**On paralysis of the sphincter of the pupil with special**  
**reference to paradoxical constriction and the functions of**  
**the ciliary ganglion. BY H. K. ANDERSON, M.D. (Eight**  
**Figures in the Text.)**

*(From the Physiological Laboratory, Cambridge.)*

CONTENTS.

	PAGE
Introduction. Anatomical relations of the ciliary ganglion in the cat. Previous observations concerning the paralysed sphincter. Experimental methods . . . . .	156
Paradoxical pupil-constriction after excision of a ciliary ganglion . . . . .	159
Local paradoxical constriction of the pupil . . . . .	163
Causes of paradoxical pupil-constriction . . . . .	166
Paradoxical pupil-constriction after section of an oculomotor nerve . . . . .	169
On the functions and nature of the ciliary ganglion . . . . .	170
Summary . . . . .	174

*Introduction.* After excision of a superior cervical ganglion or section of a cervical sympathetic nerve the paralysed pupil under certain conditions becomes larger than the control. This paradoxical effect has been called paradoxical pupil-dilatation<sup>1</sup>. Similarly after excision of a ciliary ganglion or section of an oculomotor nerve the paralysed pupil sometimes becomes the smaller of the two pupils. This corresponding effect I shall call paradoxical pupil-constriction.

In a previous paper<sup>2</sup> I have confirmed the truth of Lewandowsky's<sup>3</sup> view that paradoxical dilatation depends primarily upon an increased excitability of the paralysed muscle, and in the present series of observations I shall show that paradoxical constriction is similarly caused<sup>4</sup>.

<sup>1</sup> Langendorff. *Klin. Monatsch. f. Augent.* xxviii. p. 133. 1900.

<sup>2</sup> Anderson. *This Journal*, xxx. p. 290. 1903.

<sup>3</sup> Lewandowsky. *Sitz. d. k. preuss. Akad. d. Wiss. zu Berlin*, 1900, p. 1136.

<sup>4</sup> Cf. also preliminary communication, *Proc. Phys. Soc.* May, 1902. *This Journal*, xxviii. p. xv.

*Anatomical relations of the ciliary ganglion in the cat.* The short ciliary nerves in the cat may be divided for convenience into the malar and nasal branches. The former pass upwards on the outer side of the optic nerve, and when stimulated cause contraction of the malar portion of the sphincter: the latter pass inwards under this nerve and cause contraction of the nasal portion. Both nasal and malar branches are joined between the ganglion and the eyeball by long ciliary nerves. The chief ciliary ganglion is sessile on the oculomotor branch to the inferior oblique muscle, but accessory ganglia are found on the ciliary branches, and chiefly where long and short ciliary nerves join. Jegorow<sup>1</sup>, who has given an admirable account of the anatomy of the ciliary ganglion and its branches in several species of animals, was unable to find in the cat any long ciliary branch joining the ganglion directly, but he traced some long ciliary fibres backwards to the ganglion by way of a short ciliary branch and thought these fibres ended among the cells of the ganglion. He therefore regarded them as its long root. I have confirmed the presence of such fibres myself by dissection, and 10 days or more after the removal of a ciliary ganglion I have traced sound medullated fibres passing backwards from a long ciliary nerve to the cut end of the malar short ciliary branches. In one experiment there were 30 sound fibres (exp. 1), in another 12. But I do not think they end in the ganglion. They probably pass through it, and may have supplied the six sound fibres I found in the oculomotor branch to the inferior rectus muscle after degeneration of all the fibres in the oculomotor trunk.

Jegorow failed to detect any branch from the sympathetic to the ciliary ganglion in cats and I have failed to find any myself, but it is impossible to decide even by microscopical examination whether non-medullated fibres pass through this ganglion by an indirect course, *e.g.* whether any pass backwards through the malar short ciliary branches to the ganglion and thence to the nasal ciliary branches. But the passage of pupil-dilatator fibres through the ciliary ganglion was not supported by the following observations. (1) After section of all the long ciliary nerves no dilatation of the pupil was detected on stimulating the cervical sympathetic, a result previously obtained in the dog by Jegorow<sup>2</sup>. No dilatator fibres passed, therefore, directly through the ganglion. (2) Stimulation of the central end of the cut malar ciliary branches near the ganglion caused no dilatation of the nasal portion of the pupil, and

<sup>1</sup> Jegorow. *Archiv Slav. de Biol.* III. p. 64. 1887.

<sup>2</sup> Jegorow. *Archiv f. (Anat. und) Physiol.* 1886, p. 173.

reversely, stimulation of the central end of the nasal branches caused no dilatation of the malar portion. There was no evidence, therefore, of the indirect passage of fibres through the ganglion suggested above. (3) The removal of the ciliary ganglion (after section of the oculomotor nerve) did not diminish the degree of dilatation observed on minimal stimulation of the sympathetic, nor its extent when dilatation had been limited to the nasal side by section of the malar branches close to the eyeball. There was no evidence, therefore, that any dilatator fibres looped back through the ciliary ganglion, and then issued again by the same short ciliary branch. From these observations I conclude that the dilatator tract is not injured by the removal of a ciliary ganglion or section of the short ciliary branches near their origin. In these experiments eserine was applied to the eyes first if the pupil-constrictor tract was to be divided. By this method it is much easier to detect slight dilatation of the pupil than when the pupil is already widely dilated.

*Previous observations concerning the paralysed sphincter.* Jegorow<sup>1</sup> in 1887 removed the ciliary ganglion in two dogs and soon after the operation observed immobility and maximal dilatation of the pupil. In the first experiment he noticed a slight constriction of the pupil on the 6th day, but the light-reflex returned on the 16th. In the second experiment, the light-reflex had not returned on the 40th day when the dog was killed, and no evidence of regeneration was found, yet the pupil was constricted on the 6th day, dilated on the 8th, strongly constricted on the 12th, much dilated on the 14th, somewhat constricted on the 18th, and moderately constricted subsequently. But the cornea was perforated on the 16th day, and adhesions were formed between it and the iris. In another experiment<sup>2</sup> Jegorow noticed a temporary constriction of the pupil on the 8th and 10th days, after section of the oculomotor nerve in the orbit centrally of the ganglion though the nerve seemed not to have reunited with the ganglion even on the 36th day. But Braunstein<sup>3</sup> says there was scarcely any change in the pupil of a rabbit even a year after section of an oculomotor nerve within the skull, and records no change in the dilated pupil of the cat after similar section of this nerve for shorter periods.

*Experimental methods.* All the operations involved in my experiments were performed under anæsthesia with strict antiseptic precautions.

<sup>1</sup> Jegorow. *Archiv Slav. de Biol.* iii. p. 325. 1887.

<sup>2</sup> Jegorow. *Ibidem*, p. 335.

<sup>3</sup> Braunstein. *Zur Lehre v. d. Innerv. d. Pupillenbewegung*, Wiesbaden, 1894, pp. 126 and 91.

First the eyelids were closed. A Y-shaped incision was then made through the skin and fascia, beginning in front of the auditory meatus and branching above and below the orbit. A portion of the zygoma and external wall of the orbit was removed and the temporal muscle retracted. After hæmorrhage had been stopped the periosteal sheath of the orbit was opened, its edges held apart by weighted hooks, and the external rectus muscle drawn upwards by a retractor, which was used at the same time to protrude the eyeball slightly. No ocular muscle was cut. The ciliary ganglion was found by tracing the nerves to the inferior oblique muscle centrally. This nerve is easily found where it lies on the inferior rectus. The same operation was used for the section of the short ciliary branches or for the division of the oculomotor nerve. My method of operating is, therefore, practically the same as that used by Jegorow<sup>1</sup>.

To decide whether there was tone in the paralysed sphincter I have examined the eyes in the dimmest light sufficient for the observation of the pupils. In this way the paralysed sphincter is compared with a much relaxed sphincter on the control side.

PARADOXICAL PUPIL-CONSTRICTION AFTER EXCISION  
OF A CILIARY GANGLION.

Under normal conditions the pupil is widely dilated after the excision of a ciliary ganglion and larger than the control, even in dim light. But if a cat is killed a few days after this operation the paralysed pupil contracts and becomes smaller than the control. For example, in exp. 1, 10 days after the removal of the left ciliary ganglion the cat was again anæsthetised and then bled to death as soon as the eyes had been photographed. The period of anæsthesia was very short and all further operative procedure was carefully avoided; yet soon after death the paralysed pupil began to contract and to become smaller than the control which had dilated widely, Fig. 1 *b*. This paradoxical effect at first was slight, but gradually increased, till 20 hours after death the paralysed pupil was very small, Fig. 1 *d*, though the control was still very large. At this time the difference between the pupils was almost exactly the reverse of that seen when the eyes were examined in bright light before the cat was bled, Fig. 1 *a*.

<sup>1</sup> Jegorow. *Archiv Slav. de Biol.* III. p. 322. 1887.

EXP. 1. Cat. Left ciliary ganglion excised. Left pupil after the operation nearly maximal.

10th day. Left pupil still nearly maximal. No light-reflex. Ether given. When the cat was fully anæsthetised the eyes were photographed, Fig. 1 *a*. The cat was then bled to death. 10 minutes later the eyes were photographed again, Fig. 1 *b*. The left pupil was now appreciably smaller than it had been before the cat was bled. 3 hours later the left pupil was slightly smaller than before, but the right was still maximal, Fig. 1 *c*. Next morning the left pupil was almost a slit, but the right was not much smaller, Fig. 1 *d*.

There were no degenerating fibres in the long ciliary nerves, but the fibres of the short ciliary branches were all degenerated except 30 medullated fibres. These were traced from a long ciliary nerve to the cut end of the malar ciliary branches. There were no degenerating fibres in the third, fourth, fifth, or sixth nerves.

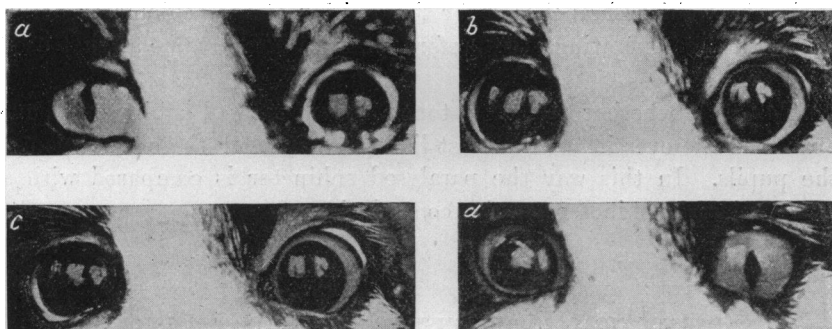


Fig. 1.

A similar paradoxical effect was seen after dyspnoea. For example, in exp. 2 I removed the left ciliary ganglion and then 19 days later in the final stage of the experiment I cut the right short ciliary branches close to the ganglion and also both cervical sympathetic nerves. Before this second operation the left pupil had been widely dilated and larger than the right, even in very dim light, but after it both pupils were equal. About half-an-hour later, however, the left pupil had contracted and was smaller than the right. But the difference between the pupils was very slight, the left being 10 mm. wide and the right 11 mm. During the next hour, in which the cat was (under anæsthetics) rendered dyspnoeic several times, for a minute or more each time, the left pupil decreased from 10 mm. to 2.5 mm. But the right pupil remained 11 mm. wide except when dyspnoea caused convulsions and then both pupils dilated momentarily. Dyspnoea had, therefore, excited contraction in the sphincter after degenerative section of the nerves but not after simple section. The gradual change in the relative difference between the pupils will be readily seen on comparing Fig. 2 *a* with Figs. 2 *b, c, d*.

It will be noticed that atropine did not relax the sphincter at the end of the experiment. But this fact will be discussed in a later paper.

Exp. 2. Adult cat. Left ciliary ganglion excised. Left pupil after operation maximal, but next day visible rim of iris about 1 mm. wide.

19th day. No change in the left pupil, no light-reflex.

- 11.25. Chloroform, tracheotomy, then equal parts of ether and chloroform. Both cervical sympathetic nerves cut in the neck.
- 11.35. Right short ciliary nerves cut close to the ganglion.
- 11.47. Pupils now equal. Rim of iris about 2 mm. wide on each side.
- 12.23. Left pupil slightly smaller, 10 mm. wide; right, 11 mm., Fig. 2 a.
- 12.25. Air tube closed for 1 min.
- 12.27. Left pupil, 9 mm.; right, 11 mm.
- 12.28. Air tube closed for 1 min.
- 12.30. Left pupil, 8.5 mm.; right, 11 mm.
- 12.40. Air tube closed three times for 1 min. each time. Left pupil, 7 mm.; right, 11 mm., Fig. 2 b.
- 1.6. After three more periods of dyspnoea, each lasting 2 mins., left pupil, 4 mm.; right, 11 mm.
- 1.8. At the end of another period of dyspnoea, lasting 90 secs., left pupil, 7.5 mm.; right, 12 mm.
- 1.10. Left pupil, 4 mm.; right, 11 mm., Fig. 2 c.
- 1.30. Left pupil, 2.5 mm.; right, 11 mm.
- 1.55. Pupils unchanged. 1 c.c. atropine injected into vein.
- 1.57. No change in pupils.
- 2.5. No change, Fig. 2 d.
- 2.6. .5 c.c. lactic acid injected. Left pupil became a slit almost immediately, the right contracted to medium size.

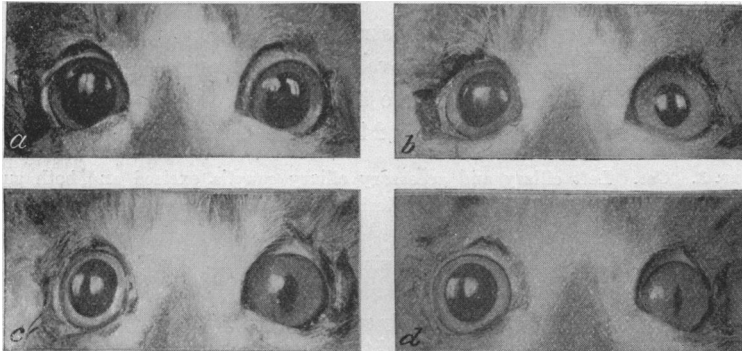


Fig. 2.

But dyspnoea did not always cause paradoxical constriction so readily as in exp. 2 (cf. exp. 4), nor have I ever seen such constriction after merely pressing on the trachea for a short time. Even in a young kitten this did excite a paradoxical effect after removal of a ciliary

ganglion, though paradoxical dilatation is most readily evoked in this way in young kittens.

Paradoxical constriction occurs, therefore, after excision of a ciliary ganglion under conditions corresponding in many ways with those which excite paradoxical dilatation. But the onset of the paradoxical effect differs in the two cases. Paradoxical dilatation is evoked more readily by dyspnoea, and is always very pronounced soon after death, whereas paradoxical constriction (in the absence of previous dyspnoea) is generally very slight soon after death, but becomes more pronounced some hours afterwards. These differences to some extent, however, may be more apparent than real because the conditions which excite paradoxical effects are favourable to dilatation, even in the normal eye.

Paradoxical constriction was also seen in a cat which died from disease 70 days after the removal of a ciliary ganglion. This effect occurs, therefore, independently of previous anaesthesia. In exp. 2 also the paradoxical constriction was very slight, even an hour after anaesthesia had been established, though readily increased by dyspnoea afterwards. But deep and prolonged anaesthesia may excite paradoxical constriction by causing dyspnoea (cf. exp. 6).

In the cat mentioned above regeneration had begun between the oculomotor nerve and the accessory ganglia before the 70th day, but this did not prevent the onset of a paradoxical effect in this cat or in another in which the short ciliary nerves had partially regenerated 66 days after their division.

In exp. 3 also paradoxical constriction was seen after dyspnoea and death on the 82nd day after removal of the left ciliary ganglion, but in this case the paradoxical difference between the pupils was reversed on the following morning and during 24 hours afterwards.

Exp. 3. Cat. Left ciliary and accessory ciliary ganglia excised and both superior cervical ganglia removed to neutralise the lesion of the long ciliary sympathetic fibres on the left side.

82nd day. Left pupil almost maximal since the operation. No light-reflex.

11.15. Ether.

11.27. Left pupil very large, but distinctly smaller than right, which is maximal.

1.12. Left pupil slightly smaller than right, but both very large. Cat bled.

1.25. Both pupils maximal.

2.5. Left pupil again distinctly smaller than right, but both very large.

5.5. Both pupils slightly smaller.

83rd day. 11.0. Both pupils smaller, but right now much smaller than left. This relation between the pupils continued till the following morning.

A reversal of the paradoxical effect was also seen in exp. 4, but in this case the reversal was only temporary.

Exp. 4. Cat. Left ciliary ganglion excised.

39th day. Left pupil almost maximal. No light-reflex. Both sympathetic nerves cut.

45th day. Left pupil slightly smaller since the section of the sympathetics, but no paradoxical effect even in dim light.

12.15. Ether, then ether and chloroform.

1.7. Even after repeated closure of the air tube for a minute or more the left pupil has not become appreciably smaller. Also no change in the left pupil after clamping the left carotid for 3 mins. Under very deep anæsthesia the right pupil dilates till it becomes larger than the left.

3.45. The right ciliary ganglion has been removed. The left pupil has gradually become smaller during the past two hours, but the right is maximal. The left pupil is therefore now the smaller.

3.55. Cat bled.

5.0. Left pupil distinctly smaller than the right, which is maximal.

46th day. 11.0. Left pupil now larger than the right, but both are smaller than on the previous day.

3.0. Left pupil again smaller than the right, which has dilated considerably since the morning, though the left has scarcely dilated at all.

It is interesting to notice that the sympathetic tracts had been cut in both these experiments in which a subsequent reversal of the paradoxical effect occurred, but my experiments do not suffice to show whether this further lesion was the cause of the subsequent reversal of the paradoxical effect in expts. 3 and 4.

#### LOCAL PARADOXICAL CONSTRICTION OF THE PUPIL.

In exp. 5 only the malar portion of the sphincter was paralysed, the malar short ciliary branches being cut close to the ganglion before they had united with the long ciliary nerves. After the operation the nasal side of the pupil was almost straight in bright light but the malar side was dilated, Fig. 4, and this condition of the pupil continued till the cat was anæsthetised and the left oculomotor cut on the 17th day afterwards. The malar (paralysed) side of the pupil then became slightly straighter than the nasal, Fig. 4 *b*, and after the cat had been rendered dyspnœic this change in the shape of the pupil became more pronounced, Fig. 4 *c*. Finally the malar side became almost straight, though the nasal side was still much dilated, Fig. 4 *d*. After repeated dyspnœa, therefore, the shape of the pupil was almost exactly the reverse of the shape before the final experiment. Moreover, the puckering and lines of traction on the surface of the iris showed clearly that the paralysed portion of the sphincter was actively contracted, after the dyspnœa, Fig. 3. But the surface of the iris was almost smooth on the nasal side. In this



experiment the paradoxical constriction could not be attributed to a damaged blood supply because the constriction should have been more general if this had been the case.

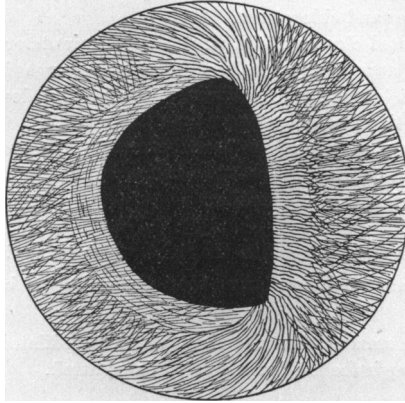


Fig. 3.

I stimulated the sympathetic several times in this experiment for a minute or more to see whether this would inhibit the paradoxical tone in the paralysed portion of the sphincter and thereby remove the irregularity of the pupil. But even during the stimulation the rim of iris was broader on the paralysed side than elsewhere, and after the stimulation had ceased the paralysed side of the pupil became straight again very quickly. These observations did not, it is true, exclude the possibility of slight inhibition of both the paralysed and normal portions of the sphincter but they certainly did not suggest effective inhibition of the paralysed portion.

Exp. 5. Cat. Malar short ciliary branches cut close to the ciliary ganglion on the left side.

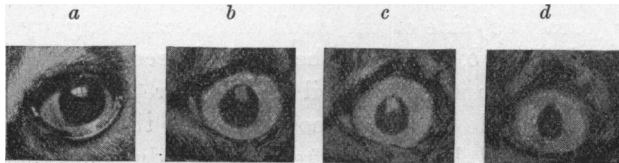


Fig. 4.

17th day. The malar side of the pupil has been much dilated since the operation, Fig. 4 a.

3.15. Chloroform, then equal parts of ether and chloroform.

3.45. Both sympathetics cut, also left oculomotor nerve within the skull.

- 4.0. Left pupil now as in Fig. 4 b.
- 4.10. Air tube closed. Malar side of pupil becomes straighter than before.
- 4.13. Air tube closed again.
- 4.15. Malar side of pupil now almost straight; nasal side dilated, Fig. 4 c.
- 4.22. Left sympathetic stimulated for 1 min. The left pupil dilates, but the irregularity of the pupil remains; the rim of iris is 3.5 mm. on the malar side and only 2 mm. on the nasal. After the stimulation the malar side of the pupil very quickly becomes straight again. This observation was repeated many times.
- 4.45. Pupils as in Fig. 4 d.

Similar results were also obtained in exp. 6 in which both the long and short ciliary branches were cut on the malar side.

Exp. 6. Cat. Long and short malar ciliary branches cut on left side.

14th day. Since the operation the pupil has been much dilated on the malar side, Fig. 5 a, but the nasal side has been almost straight in bright light.

- 11.12. Chloroform, then ether and chloroform.
- 11.45. Cat deeply under anæsthesia. Malar side of pupil is now straighter, Fig. 5 b.
- 12.22. When the anæsthetic is given in excess slight corrugations appear over the paralysed portion of the sphincter, and the rim of iris on this side becomes slightly wider at the same time as the rim elsewhere becomes narrower. But it was necessary almost to kill the cat with anæsthetics before this result was obtained. Similar results were obtained when the cat was rendered dyspnoic, or made to breathe air mixed with CO<sub>2</sub>.
- 1.25. Both sympathetics cut and stimulated. The left pupil dilates little if at all in the region of the paralysis.
- 1.30. Cat bled to death.
- 1.37. Rim of iris wider on malar side than elsewhere, Fig. 5 c. Control pupil maximally dilated. Paralysed portion of iris wrinkled over sphincter, especially at two points.
- 2.20. Malar side of pupil much the straighter.
- 3.20. Malar side of pupil now almost straight, Fig. 5 d. Surface of iris wrinkled over paralysed portion of sphincter, especially at the same two points. The iris here protrudes into the pupil.
- 5.30. Both pupils smaller, but shape and relative size of the pupil unchanged.

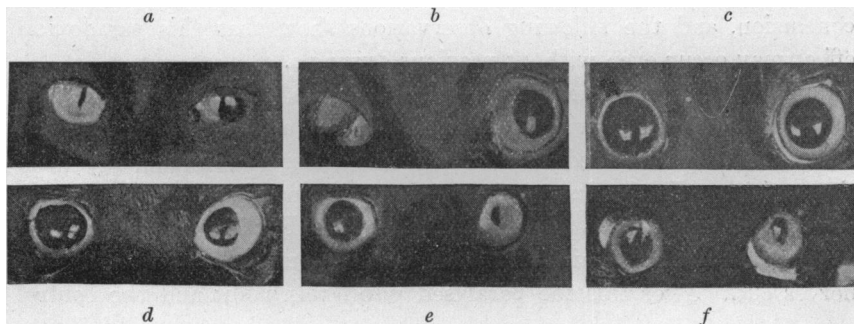


Fig. 5.

15th day. Left pupil as in Fig. 5 e. Considerable constriction of the whole paralysed pupil as well as local constriction.

16th day. Left pupil as in Fig. 5 f.

#### THE CAUSES OF PARADOXICAL PUPIL-CONSTRICTION.

The dilatator tract was not injured, so far as I could detect, by the removal of the ciliary ganglion; and even if it had been, this lesion under the conditions of the experiments would have caused paradoxical dilatation and not paradoxical constriction. Moreover, exps. 5 and 6 showed that the paralysed portion of the dilatator without doubt contracted more strongly than the control portion both after dyspnoea and after death. It remained, therefore, to account for paradoxical increase of contraction. This obviously did not depend directly upon nervous impulses, because it was generally greatest several hours after death. Again, experiments by many observers discussed elsewhere<sup>1</sup> show that in the cat efferent fibres pass to the iris only by the oculomotor and sympathetic nerves. Yet section of the sympathetic did not evoke a paradoxical effect even when this nerve was cut several weeks after the removal of the ganglion (cf. exp. 4, also exps. 3 and 6), and stimulation of the sympathetic did not inhibit the contracture of the paralysed portion of the sphincter in exp. 5. The paradoxical increase of contraction did not depend, therefore, upon the loss of inhibitory impulses. It must therefore have been caused by a local stimulation of the sphincter and have been primarily due to an increase of excitability in this muscle after paralysis (cf. exp. 2).

My observations do not decide whether dyspnoea excites paradoxical constriction directly by the lack of oxygen or excess of carbonic acid, or indirectly by leading to the formation of some other substance, *e.g.* sarcolactic acid, but exps. 2 and 4, taken together, point rather to the latter conclusion, and the following observations show that this paradoxical effect may occur even without previous dyspnoea.

In all the previous experiments and in others like them the paralysed pupil was almost maximal after excision of a ciliary ganglion, but in two cats pronounced constriction was observed on the day after the excision. In the first of these (exp. 7) the paralysed pupil 28 hours after the operation was only half the full size (Fig. 6 a). The cat was then anaesthetised again and both the oculomotor and sympathetic nerves cut. After this the paralysed pupil was a slit and the control

<sup>1</sup> Anderson. *This Journal*, xxx. p. 22. 1904.

was maximal, Fig. 6 c. After death also the paradoxical effect was very great.

Exp. 7. Young cat. Left ciliary ganglion excised.

3 hours after the operation, left pupil nearly maximal, no response to light. 24 hours after the operation, pupils in daylight as in Fig. 6 a. There is a primary dilatation of the left pupil followed by oscillations of the edge of the iris when the eyelids are opened after they have been closed for a short time<sup>1</sup>. If the cat is restless during an observation the right pupil becomes momentarily larger than the left: it is also the larger pupil in very dim light. 28 hours after the operation, ether given.

- 3.15. Light anæsthesia, right pupil much smaller than left.  
Deep anæsthesia, right pupil dilates till it is larger than the left.  
Both cervical sympathetic nerves cut and stimulated. Left sympathetic nerve gives full and rapid dilatation of pupil.
- 3.42. Lighter anæsthesia, right pupil much smaller than left, even in rather dim light.  
Deep anæsthesia, right pupil gradually becomes larger than left, Fig. 6 b.  
Lighter anæsthesia, pupils equal: on pinching skin the right pupil becomes much the larger: on stimulating end of int. saphenous nerve the right pupil becomes maximal, but left is not changed. The left, therefore, is smaller than the right.
- 4.20. Right pupil now  $\frac{3}{4}$  full size, but left is now a slit.
- 4.30. Both oculomotor nerves cut inside skull.
- 4.35. Pupils now as in Fig. 6 c.  
Left oculomotor stimulated, no change in pupil: right oculomotor nerve, quick constriction of pupil.
- 4.50. Both trigeminal nerves cut close to brain: no change in pupils.
- 5.0. Cat killed by pithing medulla.
- 6.0. Right pupil maximal, left a slit.
- 8.0. The same.
- 10.30. The same.

Next morning. Right pupil widely dilated, left has dilated to about 2 mm. in width.

Next day. Both pupils have dilated more, but the left is much the smaller.




Fig. 6.

In the second experiment the pupil contracted to a slit on the day after the removal of the left ciliary and superior cervical ganglia, but gradually dilated, till it was almost maximal again on the 10th day. It then did not change for 3 months afterwards. No such constriction

<sup>1</sup> This dilatation of the pupil, as I have shown, is caused not by the readmission of light but by touching the eyelids. Cf. this *Journal*, xxx. p. 18. 1903.

occurred in eight other cats from which the superior cervical ganglion was removed either at the same time as the ciliary ganglion or afterwards, and at first I attributed this abnormal onset of constriction to a direct injury of the eye or its vessels. But in a later experiment this explanation could not be upheld. In this cat the left ciliary ganglia had been removed for 208 days and the pupil during this time had been almost maximal. But the left superior cervical ganglion was then removed with the result that the left pupil became moderately constricted next day and for a few days afterwards. In connexion with these experiments I would mention two others also in which there was a corresponding onset of paradoxical dilatation. In the first this occurred on the day after the excision of the left superior cervical ganglion only; in the second, it occurred on the 209th day after the excision of this ganglion as a consequence of the removal of the left vagus ganglion on the preceding day. But in both the paradoxical effect disappeared after a few days. I am therefore inclined to attribute the onset of a paradoxical effect in all these exceptional experiments to the absorption of some substance from the recent wound. This view might also account for the alternation of constriction and dilatation in Jegorow's second experiment quoted above. Jegorow himself attributed the constriction in his dog to pressure of cicatricial tissue on the ciliary nerves, but it is difficult to understand how this could have caused the later constriction because the cut ciliary nerves would have lost their irritability even as early as the 6th day.

I did not know till my experiments were finished that Roebroek<sup>1</sup> had observed local dilatation of the pupil after cutting three long ciliary nerves. This dilatation was in the region of the paralysed portion of the iris and it is attributed by Winkler<sup>2</sup> to a long-continued irritation of the cut nerves. But in exp. 8 I cut the malar long ciliary branches before they had joined the short ciliary and in this cat observed no local dilatation on the malar side under normal conditions. On the contrary, the malar side of the pupil was afterwards slightly straighter than the nasal. The paralysed pupil did not, it is true, contract quite so well as the control, but this slight general dilatation was afterwards explained by the degenerating fibres found in the short ciliary branches<sup>3</sup>.

<sup>1</sup> Roebroek. *Het ganglion supremum colli nervi Sympathici*, Utrecht, 1895, p. 85.

<sup>2</sup> Winkler. *Commun. à 5<sup>me</sup> Congr. de nat. et méd. hollandais*, Avril, 1895; *Flandre méd.*, No. 17, 1895.

<sup>3</sup> This lesion was probably caused by traction applied to the ciliary ganglion during the operation.

Roebroeck does not mention the condition of the short ciliary nerves at the end of his experiment, and he was prevented by the death of the cat from observing the effect upon the pupil of stimulation of the oculomotor nerve. It is possible, therefore, that he may have cut the long ciliary nerves after they had joined the short ciliary, as I did unwittingly in exp. 6. In his drawing of the pupil (Fig. 3, Pl. III) the lines on the surface of the iris suggest local relaxation of the sphincter. Again, no dislocation of the pupil is shown in this figure. But in exp. 8 there was considerable dislocation of the pupil when dyspnœa had excited paradoxical contraction in the paralysed malar portion of the dilatator.

EXP. 8. Cat. Long ciliary nerve cut on the left optic nerve just before its union with an accessory ganglion upon the short ciliary branches.

9th day. Since the operation the pupil has dilated less on the malar than on the nasal side. In stronger light the malar side of the pupil becomes straight before the nasal side, but the left pupil does not as a whole contract quite as well as the control.

3.0. Chloroform, then ether and chloroform.

3.12. After repeated dyspnœa the left pupil dilated on the malar side and the whole pupil is seen to be dislocated towards this side.

3.27. Left sympathetic stimulated. Left pupil dilates well on nasal side but not on malar side.

3.31. After closure of air tube for 1 min. dislocation of pupil to malar side very great.

The irregular form and dislocation of the left pupil continued after death. Some hundreds of degenerating fibres were found in the short ciliary nerves near the ganglion, but the great majority of the fibres were sound.

#### PARADOXICAL PUPIL-CONSTRICTION AFTER SECTION OF THE OCULOMOTOR NERVE.

In exp. 9 the left oculomotor nerve was cut centrally of the ciliary ganglion. After the operation the pupil remained almost maximal and gave no response to light. On the 7th day the cat was anæsthetised. The pupil did not become appreciably smaller, however, after anæsthesia had been established, nor after two short periods of dyspnœa, but half-an-hour after the cat had been bled to death the left was distinctly the smaller of the two pupils. This difference was greater an hour later. The control pupil meanwhile had not become smaller.

EXP. 9. Cat. Left oculomotor nerve cut in the orbit centrally of the ciliary ganglion.

7th day. Left pupil has remained widely dilated since operation.

1.30. Ether and chloroform given in equal parts.

The left pupil did not become smaller on very deep anæsthesia, nor after two periods of dyspnœa lasting for 75 secs. and 125 secs. respectively.

2.20. Cat bled to death.

- 2.30. Left pupil very slightly the smaller.  
 3.0. Left pupil distinctly smaller, Fig. 7 *a*.  
 4.0. Left pupil much smaller, right still widely dilated, Fig. 7 *b*.

Next morning. Both pupils smaller, but left much the smaller of the two pupils, Fig. 7 *c*; on the second morning after death the same relation between the pupils continued, but both had dilated slightly.

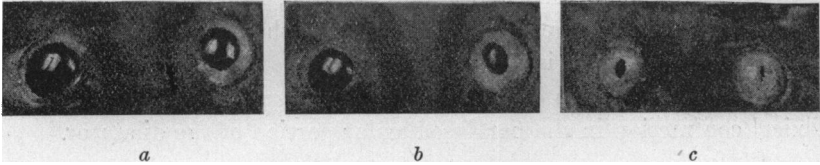


Fig. 7.

Exp. 9 shows that paradoxical constriction may occur as soon as 7 days after section of an oculomotor nerve. But paradoxical dilatation was not seen by Langley in a cat which had been killed 7 days after section of the cervical sympathetic, although it occurred after longer division of this nerve<sup>1</sup>. The early onset of paradoxical constriction after section of an oculomotor nerve was also observed in the following series of experiments in which the nerve was cut on one side and the ciliary ganglion removed on the other.

#### ON THE FUNCTIONS AND NATURE OF THE CILIARY GANGLION.

In order to investigate whether the decentralised ganglion sends nervous impulses either motor or inhibitory to the sphincter muscle, I cut the oculomotor nerve in one orbit and removed the ganglion from the other. Under normal conditions the following results were obtained. In five experiments, lasting 6 to 12 days, the pupils were equal, and in three they were again equal till regeneration began. In two the pupil on the side without the ganglion was slightly the smaller, in one it was slightly the larger. But even in these the inequality did not persist. It had almost disappeared on the third day when one of these cats was killed, and in the other two the pupils were equal after the second day till the cats were killed 4 and 9 days later. Under normal conditions, therefore, there was no suggestion of the passage of augmentor or inhibitory impulses from the decentralised ganglion in 8 out of 11 experiments, and in the remainder the transitory inequality seemed to be merely an accidental effect of the recent operation.

<sup>1</sup> Anderson. *This Journal*, xxx. p. 297. 1904.

I am unable, therefore, to support Jegorow's<sup>1</sup> suggestion that the decentralised ciliary ganglion augments the tone of the sphincter. There was a suggestion of this in three other experiments in which the dilated pupil began to constrict slightly some months after section of the oculomotor nerve within the skull. But this suggestion was false. In each cat I<sup>2</sup> eventually elicited a distinct light-reflex after the application of physostigmine to the eyes although I quite failed to do so under normal conditions, even 9 months later in one cat. Again, after section of an oculomotor nerve in the orbit I observed slight constriction of the pupils some days before I could detect a light-reflex although the constriction was almost certainly caused by the beginning of regeneration. The absence of the normal light-reflex cannot, therefore, be accepted as a proof of the absence of regeneration in the oculomotor nerve.

The effect of dyspnœa or death usually differs to a greater or less extent upon the denervated and decentralised sides, but the differences are not constant in different experiments. In four experiments lasting 12, 10, 6, and 12 days the pupil became distinctly larger on the denervated side, both during dyspnœa and after death (cf. exp. 10). In two experiments (6 and 12 days) a similar result was obtained during dyspnœa and for some time after death, but about 8 hours after death the relative size of the pupils underwent a reversal. In one experiment the pupil on the denervated side became smaller than on the other side about 3 hours after death, and in one experiment not only was it smaller after death, but smaller also during dyspnœa before death in the anæsthetised animal (exp. 11).

I cannot at present account for these differences. I carefully avoided stimulation of the branches of the decentralised ganglion because I had previously found that this caused residual contraction in the sphincter. But I tested the vitality of the ganglion by examining its branches microscopically and never found them degenerated. I also verified the absence of any lesion in the long ciliary nerves on either side. It is possible that these differences may have been caused by accidental injury of the eye or its vessels on one side or the other. But I saw no sign of this. A longer duration of the experiments would no doubt have minimised this last possible source of error, but unfortunately the oculomotor nerve may begin to reunite with the ganglion even as soon as the 10th day when this nerve is cut in the orbit.

<sup>1</sup> Jegorow. *Archiv Slav. de Biol.* III. p. 338. 1887.

<sup>2</sup> Anderson. *Proc. Phys. Soc.*, May, 1905. *This Journal*, xxxii.



Exp. 10. Cat. Right ciliary ganglion excised; left oculomotor nerve cut in orbit centrally of the ciliary ganglion.

10th day. Both pupils have been widely dilated and equal since the operation. No response to light has been detected on either side.

3.13. Ether given, then equal parts of ether and chloroform.

3.50. Both pupils equal and almost maximal, Fig. 8 *a*.

4.0. Air tube closed, left pupil became smaller afterwards.

Both cerv. symp. nerves now cut: their stimulation causes dilatation equally quick and marked on the two sides.

Air tube closed twice. Both pupils have become smaller, but the left pupil is the smaller of the two, Fig. 8 *b*.

4.25. Left pupil has decreased in size more rapidly than the right, Fig. 8 *c*.

4.30. Cat nearly killed by mixing CO<sub>2</sub> with the air breathed. Neither pupil became appreciably smaller at the time.

4.33. Cat bled from carotid artery.

4.43. Both pupils have become smaller, but the left is the smaller of the two, Fig. 8 *d*.

5.5. Both pupils have dilated, but the left more than the right, yet the left is still the smaller pupil, Fig. 8 *e*.

Next morning. Both pupils are much smaller, but the relation between them is unchanged, Fig. 8 *f*.

Dissection showed that the long ciliary nerves had not been cut on the right side. Their fibres also were not degenerated. The left short ciliary nerves were sound except the few præ-ganglionic fibres passing to the accessory ganglia.

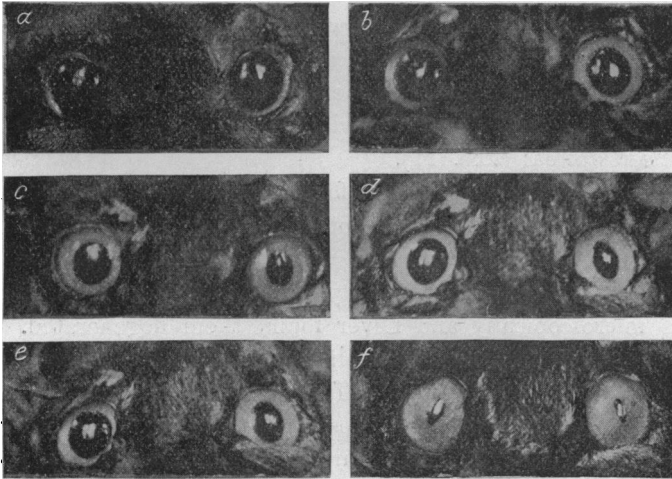


Fig. 8. *a*. Under anæsthesia. *b*. After dyspnoea. *c*. After further dyspnoea. *d*. 10 minutes after death. *e*. Half-an-hour after death. *f*. Morning after death.

Exp. 11. Cat. Right ciliary ganglion excised, left oculomotor nerve cut in the orbit. 7th day. Pupils equal since the operation.

3.27. Ether, then ether and chloroform. Pupils equal, 13 mm.

- 3.53. After repeated dyspnœa, left pupil slightly smaller than the right.  
 4.6. Both sympathetic nerves cut.  
 4.24. After further dyspnœa, left pupil 11 mm.; right 12 mm.  
 4.47. After further dyspnœa, left 10 mm.; right 8·5 mm.  
 4.53. Left pupil 9 mm.; right 6 mm.  
 5.6. 1 c.c. 1% atropine injected.  
 5.11. Pupils the same. 1 c.c. 1% atropine injected.  
 5.18. Left pupil 8 mm.; right 5 mm. 1 c.c. 1% atropine injected.  
 5.19. Pupils unchanged. Cat bled to death.  
 5.37. Left pupil 5 mm.; right 3·5 mm.  
 6.15. Left pupil scarcely larger than right.  
 8th day. 11.0. Both pupils equal, 2 mm.  
 2.0. Left pupil slightly the smaller, both pupils larger.

In this experiment atropine did not relax the constriction of the pupils nor prevent further constriction afterwards, but further discussion of this observation is deferred to a later paper.

Jegorow<sup>1</sup> thinks that the ciliary ganglion may have a trophic influence upon the cornea because he has found corneal lesions after its excision. In three of my experiments also I noticed a slight opacity in the cornea after excision of the ganglion but this soon disappeared. Moreover, the position of the lesion was very suggestive of its cause because it coincided with the portion of the cornea uncovered when the lids were half closed. I therefore closed the lids at the beginning of the subsequent operations and kept them closed till the end. No opacity then occurred even a year after excision of the ganglion. I therefore attribute such lesions of the cornea to accidental injury during the operation.

Marina<sup>2</sup>, on the other hand, thinks that the ciliary ganglion is 'truly a centre for the sphincter iridis,' and composed of both motor and sensory cells because he has observed chromatolysis in dogs and monkeys in some cells of this ganglion after cauterising the cornea, and in more of its cells after lesions of the iris and ciliary body. Bernheimer<sup>3</sup> also supports this view on similar evidence. But I have failed, as others have, to observe any movement of the pupil on stimulating the cornea or on varying the light when the oculomotor nerve has been cut in the orbit or within the skull. Moreover, Langley and I<sup>4</sup> did not find a single sound medullated fibre in the oculomotor nerve of a monkey which had been cut within the skull 56 days previously by Sherrington, who kindly

<sup>1</sup> Jegorow. *Arch. Slav. de Biol.* III. pp. 331 and 345.

<sup>2</sup> Marina. *Riv. di Path. nerv. e ment.* III. p. 529. 1898.

<sup>3</sup> Bernheimer. *Archiv f. Ophthalm.* LIV. p. 526.

<sup>4</sup> Langley and Anderson. *This Journal*, XVII. p. 184. 1894. In our paper the nerve was stated in error to have been taken from a cat.

gave it to us. Reversely, in the cat (exp. 1) I found no degenerating fibres in the oculomotor nerve 10 days after the removal of a ciliary ganglion and none in the fourth, fifth, or sixth nerves. If, therefore, cells comparable with the cells of posterior root ganglia are present in the ciliary ganglion they must belong to a type of cell not yet demonstrated and send non-medullated processes to the central nervous system. The cells of the ciliary ganglion do not differ, therefore, in this respect from the cells of the ganglia of the sympathetic system<sup>1</sup>.

#### SUMMARY.

If a cat is partially asphyxiated (under anæsthetics) or killed a few days or weeks after the removal of a ciliary ganglion or after the section of an oculomotor nerve the paralysed pupil becomes smaller than the control; and if only some of the ciliary branches have been cut, the paralysed portion of the sphincter under the same conditions contracts more strongly than the remainder. Such paradoxical effects I have called paradoxical pupil-constriction.

My observations show that these results are primarily due to an increased excitability of the paralysed sphincter muscle and that they are evoked by a local stimulation of it.

I have obtained no evidence of the passage of augmentor or inhibitory impulses from the decentralised ciliary ganglion.

No medullated fibres degenerate in the third, fourth, fifth, or sixth nerves after the removal of a ciliary ganglion, a fact which shows that no nerve cells of the type of spinal ganglion cells are present in the ciliary ganglion.

The removal of a ciliary ganglion does not cause lesions of the cornea.

The expenses connected with these experiments have been defrayed by a grant received from the Royal Society.

<sup>1</sup> Langley and Anderson. *This Journal*, xvii. p. 185, 1894 (inferior mesenteric ganglia); Langley, *Ibid.* xx. p. 76, 1896 (lumbar ganglia); *Ibid.* xxv. p. 468, 1900 (cervical and upper thoracic ganglia); and *Brain* (ganglia of solar plexus), 1903, p. 22.