

Perforation of Meckel's Diverticulum by Foreign Body: *

Case Report and Review of the Literature

CARL W. ROESSEL, M.D.

*From the Department of Surgery, The Hunterdon Medical Center,
Flemington, New Jersey*

PERFORATION of a Meckel's diverticulum by a foreign body is a rare occurrence and as a rule is not mentioned in the list of complications arising from the presence of this remnant of the vitello-intestinal duct.

The first reported case was in 1899, by Blanc; a review of the literature reveals that 36 cases have been reported to date.^{1,6} The following case report of a 16-month-old male infant brings the total to 37. It is of particular interest because the history of an ingested foreign body was known, its position closely followed by x-rays, and the diagnosis of incarceration of the foreign body in a Meckel's diverticulum entertained prior to operation.

Case Report

R. H., a 16-month-old male infant, was brought to our emergency room at 5:00 p.m. on September 7, 1961 shortly after he swallowed a piece of costume jewelry. An x-ray film of the abdomen (Fig. 1a) revealed a metallic foreign body in the shape of a Liberty Bell in the stomach near the pylorus.

The infant was admitted to the hospital for further observation. A healthy infant in no distress, he was given a regular diet and allowed normal activities.

On the morning of September 8, another x-ray film of the abdomen showed the foreign body in the right lower quadrant (Fig. 1b). Films on September 11 (Fig. 1c), September 14, and September 21 (Fig. 1d) demonstrated the foreign body in a constant position.

It is interesting that during this entire two-week period in the hospital the infant ate and slept well, engaged in normal activities, was in

no distress, and presented normal physical findings on repeated examinations.

With an obvious arrest of the foreign body in a constant position for at least ten days, the possibility of incarceration in a Meckel's diverticulum was entertained. Accordingly, on September 21, shortly after the last x-ray, the infant was given general inhalation anesthesia and the abdomen entered through a lower right pararectal incision. The foreign body could be palpated behind the cecum. Further exploration revealed a moderately inflamed Meckel's diverticulum loosely adherent to the under surface of the cecum. There was no local leakage. The foreign body was found to be snugly incarcerated in the diverticulum with the ends of the crossbar just protruding through the serosa on either side of the tip of the diverticulum (Fig. 2a). The diverticulum, together with the foreign body, was excised and the defect in the side of the ileum closed in a transverse direction with through and through interrupted catgut and an outer row of interrupted silk sutures. The lumen of the bowel was not compromised. The postoperative course was uneventful and the infant was discharged from the hospital on September 25, 1961.

Discussion

Meckel's diverticulum is found in 2.0 or 3.0 per cent of all cases coming to autopsy. It is said to be more common in males than in females, the ratio being about 3:1. In reviewing cases of foreign body perforation (including the above case) there were 29 males and eight females. Six males were under 12 years of age. The author's case was by far the youngest, the age range being from seven to 75 years in the previously reported cases.

In the majority of perforations, history of an ingested foreign body was lacking

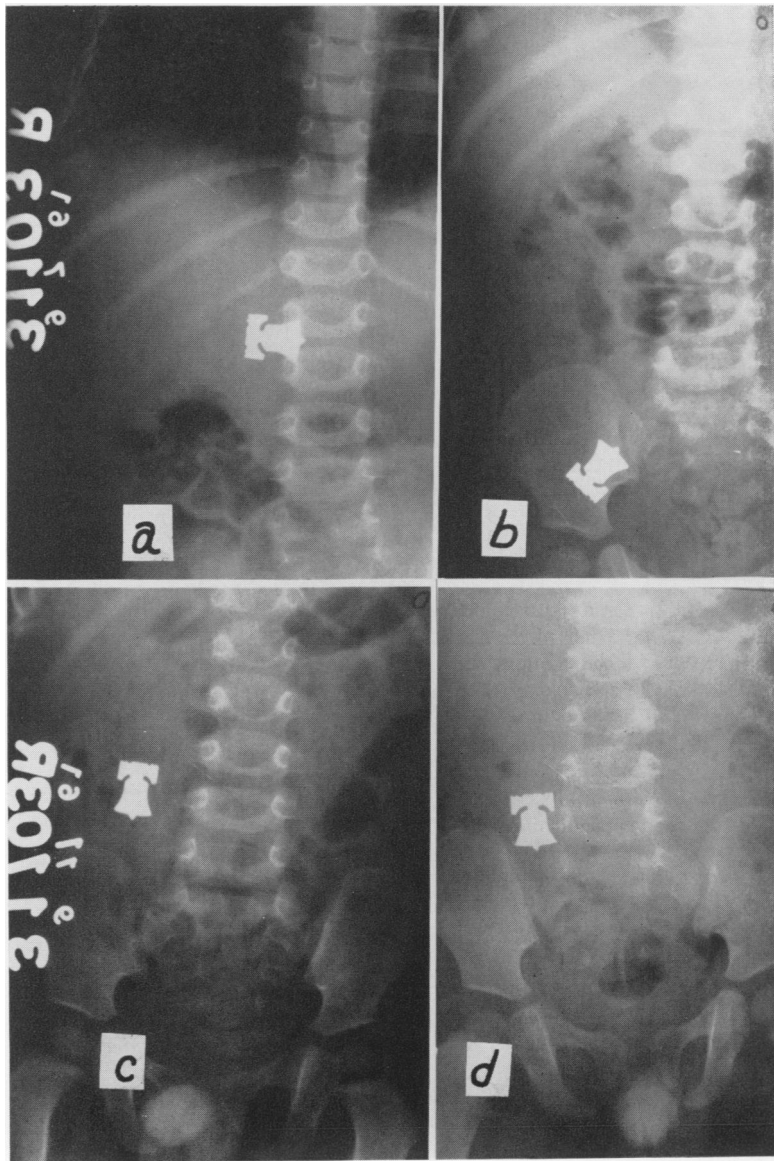
* Submitted for publication January 17, 1962.

and operation usually was done on the basis of a diagnosis of *appendicitis*. In those cases where foreign body ingestion was known it was correctly implicated as the cause of symptoms prior to operation (Table 1). In one case⁸ without a history of a swallowed foreign body a primary diagnosis of *acute appendicitis* was made. However, the possibility of foreign body perforation or inflammation of Meckel's diverticulum was also considered.

Three deaths were recorded. The case of Piquand and Granet (1900),^{1, 6} a 45-year-old woman died of peritonitis five days after hospitalization and autopsy revealed a fish bone perforation of a Meckel's diverticulum. The cases of Hagler and Stewart (1920)^{1, 6} and Tamraz (1940)¹¹ died of postoperative complications.

Ward-McGuard¹² suggests that the mechanism of perforation is a combination of local inflammation due to irritation of the

FIG. 1a. Flat film of abdomen 9-7-61 (admission). b. Flat film of abdomen 9-8-61 (morning after admission). c. Flat film of abdomen 9-11-61. d. Flat film of abdomen 9-21-61 (c. and d. show F. B. arrested in R. L. Q.).



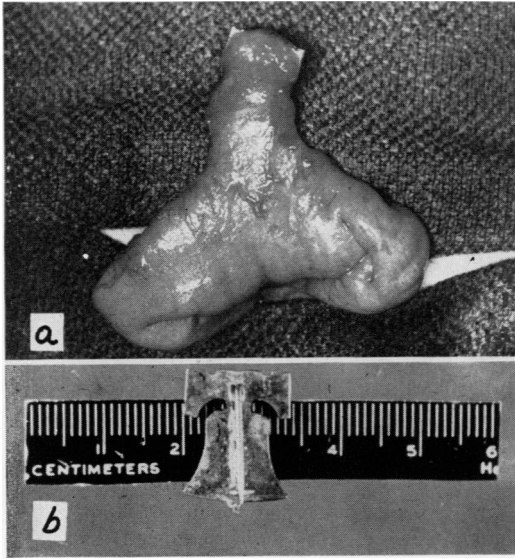


FIG. 2a. Photograph of small bowel, Meckel's diverticulum with contained foreign body during operation. b. Removed foreign body.

foreign body, and pressure necrosis of the diverticular wall secondary to attempts by peristalsis to push the foreign body toward the tip of the diverticulum.

Persson (1939)⁶ gives a review of 15 cases and Alhadeff (1955)¹ includes these in his excellent summary of 27 cases.

TABLE 1

Preoperative Diagnosis	No.
Without History of Ingested F. B.	
Appendicitis	26
Abdominal abscess	1
Perforated viscus	1
Intestinal obstruction (appendix previously removed)	1
"Other than appendicitis"	1
Congenital anomaly	1
No operation—F. B. found at autopsy	1
With History of Ingested F. B.	
Appendicitis due to F. B.	1
F. B. perforation of intestine	2
F. B. perforation of sigmoid	1
F. B. incarcerated in Meckel's diverticulum (author's case)	1
Total	37

In reviewing case histories the frequent diagnosis of *appendicitis* was not surprising. In the majority, where perforation was slow, symptoms tended to be rather mild and extended with intermittent pains in the right lower quadrant. Tenderness usually was found in the lower right abdomen, together with slight temperature elevation and increase in leukocytes. In a few cases, where perforation was apparently rapid, signs and symptoms were more acute and severe and suggested a diagnosis of "acute appendicitis with perforation."

It would appear that a correct preoperative diagnosis in the absence of a history of ingested foreign body would be most fortuitous. On the other hand, in those cases where there is a history of a swallowed foreign body, the correct diagnosis might well be considered preoperatively.

Summary

1. Thirty-six cases of foreign body perforation of a Meckel's diverticulum appearing in the literature have been briefly reviewed and an additional case presented.

2. The probability of making a correct preoperative diagnosis without knowledge of an ingested foreign body appears remote.

3. In cases with a history of foreign body ingestion and arrest the correct diagnosis might well be entertained preoperatively.

TABLE 2

Type of Foreign Body	No.
Fish bone	21
Needle or pin	4
Wood splinter	5
Rolled tomato skin	2
Bone and wood	1
Cabbage stalk	1
Grape seeds	1
Prune pit	1
Costume jewelry (author's case)	1
Total	37

Bibliography

1. Alhadeff, R.: Perforation of Meckel's Diverticulum by Foreign Body and Review of the Literature (27 Cases). *Brit. J. Surg.*, **42**: 527, 1955.
2. Bematz, P. E.: Unusual Conditions Simulating Acute Appendicitis (Case of Fish-bone Perforation of Meckel's Diverticulum). *Proc. Staff Meet. Mayo Clinic*, **31**:3, 1956.
3. Fontaine, R. and R. Bauer: Knitting Needle Arrested in Meckel's Diverticulum. *Revue de Chirurgie*, **52**:71, 1933.
4. Gillette, W. R. Jr. and P. E. Zolfowski: Perforation of Meckel's Diverticulum by Foreign Body (2 Cases, Bone and Wood, Fishbone). *Am. J. Surg.*, **94**:666, 1957.
5. John, E. L.: Perforation of Meckel's Diverticulum by a Pin. *Brit. J. Surg.*, **43**:216, 1955.
6. Persson, T.: Perforation of Meckel's Diverticulum by a Foreign Body (15 Cases). *Acta Chir. Scan.*, **82**:530, 1939.
7. Prencipe, L.: Perforation by Foreign Body of Fibroangiomatous Meckel's Diverticulum (Prune Pit). *Riv. Pat. Clin.*, **15**:503, 1960.
8. Rawlinson, J. K. M.: Fishbone Perforation of Meckel's Diverticulum. *Brit. J. Surg.*, **43**: 444, 1956.
9. Reinalda, R.: A Case of Meckel's Diverticulum Perforated by a Fishbone. *Geneesk. gids.*, **36**:383, 1958.
10. Rumore, A.: Perforation of Meckel's Diverticulum by Grape Seeds. *Med. J. Australia*, **45**: 110, 1958.
11. Tamraz, J. M.: A Case of Acute Gangrenous Diverticulitis (Meckel's) with Perforation due to Fish Bone. *Military Surgeon*, **87**:328, 1940.
12. Ward-McGuard, N. N.: Perforated Meckel's Diverticulum by Tomato Skin. *Lancet*, **1**: 349, 1950.