

# Rupture of Duodenum Following Blunt Trauma: \*

## Report of a Case with Avulsion of Papilla of Vater

JAY C. FISH,\*\* CAPT., MC, GEORGE L. JOHNSON, MAJ., MC

*From the Department of Surgery, Martin Army Hospital, Fort Benning, Georgia*

PRIOR TO the advent of the high velocity automobile missile, blunt trauma to the duodenum was the result of a variety of abdominal mishaps. Only four of Cohn's<sup>2</sup> 25 cases of retroperitoneal rupture of the duodenum reviewed in 1952 were sustained in automobile accidents. In contrast, later cases from Cleveland and Waddell's<sup>1</sup> review and isolated reports<sup>3</sup> during the past 2 years involve the automobile in 24 of 41 cases.

Other than perforation, intramural hematoma also may result from blunt trauma. This lesion differs from duodenal rupture in several respects. Hematomas occur more frequently in children (about 60% of reported cases),<sup>4</sup> are associated with minor trauma in patients with bleeding disorders or who have been given anticoagulant therapy and are more often found in the region of the ligament of Treitz.<sup>4</sup> Rupture of the duodenum from blunt trauma is now more frequently due to an automobile accident, more frequent in adults and most often (about 85%) in the second or third portion of the duodenum (Fig. 1).

### Mechanism of Injury

The mechanism of injury varies. The idea of pinching a hole into the duodenum caught between the steering wheel and the spine seems plausible but does not hold when the distribution of force is studied (Fig. 1). Undoubtedly, injuries to the

short segment of duodenum lying anterior to the vertebral column result from a direct crushing blow. The remainder of the duodenum is relatively invulnerable to direct injury as it falls away from the anterior spine to lie in the right or left paravertebral gutters.

Rupture of a closed loop, presuming the pylorus proximally and the acute angulation of the ligament of Treitz distally to constitute barriers, has been proposed as a mechanism.<sup>1</sup>

Another mechanism may be more tenable and is illustrated by a recent patient seen at Martin Army Hospital.

### Case Report

A 23-year-old man was involved in an automobile accident on 9/6/63. He was admitted to Martin Army Hospital an hour later with a laceration of the scalp and complaints of right flank pain. His abdomen was soft without muscle guarding or rebound tenderness. There was no external evidence of injury to the trunk. Routine laboratory tests, chest and abdominal x-rays were negative. He remained under observation until about 9 hours post injury, when his abdominal pain suddenly became much worse and he developed a rigid, quiet abdomen.

At operation 200 ml. of bloody fluid were found in the peritoneal cavity. The omentum adjacent to the second portion of the duodenum was necrotic and surrounded by white plaques of soapy fat. On elevating the second and third portions of the duodenum, a considerable amount of bile-stained intestinal fluid was encountered coming from a 2-cm. laceration in the posteromedial wall just below the inferior edge of the pancreas. The surrounding tissue was friable and considerably digested by spilled duodenal contents. The surface of the head of the pancreas was similarly inflamed but not otherwise injured. The duodenal

\* Submitted for publication November 2, 1964.

\*\* Present address: Department of Surgery, University of Texas Medical Branch, Galveston, Texas.

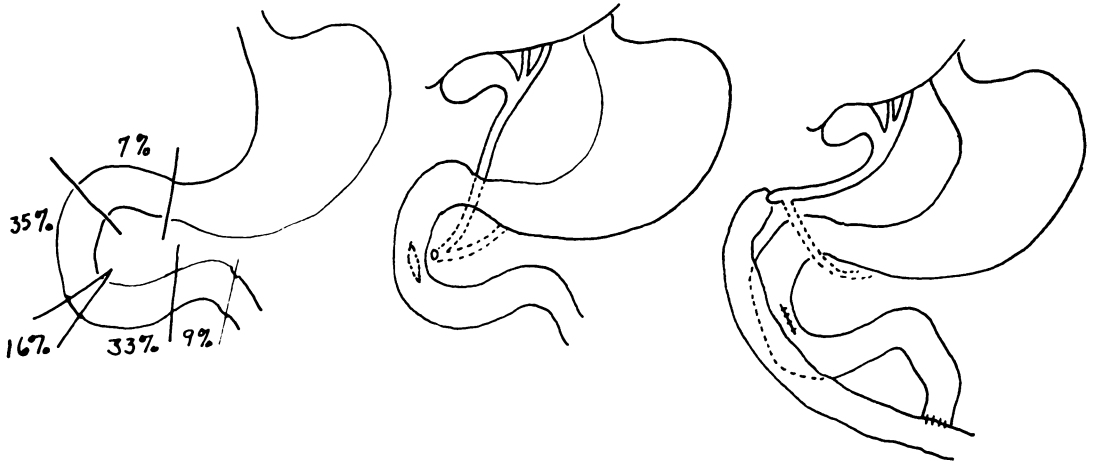


FIG. 1. (Left) Distribution of injuries to the duodenum from blunt trauma.

FIG. 2. (Center) Diagrammatic illustration of the injury. The papilla of Vater containing the pancreatic and common bile ducts is avulsed from the duodenum.

FIG. 3. (Right) Diagrammatic illustration of the repair. The duodenal rent is closed. The papilla of Vater is placed into the end of a Roux en-Y loop of jejunum.

rent was closed. Further exploration disclosed a 1-cm. patch of mucosa attached to a stalk at the inferior edge of the pancreas. Probing this stalk antegrade into the pancreas and retrograde down the common bile duct established that it was the papilla of Vater, avulsed from the duodenum (Fig. 2). Since the duodenum was so friable, the ampulla was inserted into a Roux en-Y limb of proximal jejunum. The anastomosis was performed by suturing the open end of jejunum to the cap-

sule of the pancreas around the ampulla (Fig. 3). Two drains were placed in the area of injury. The postoperative course was uneventful. T-tube cholangiograms at 10 and 27 days showed no ductal dilatation or stenosis. The T-tube was removed 1 month postoperative.

**Comment.** It is of interest that these patients may not have abdominal symptoms initially. If the leak is confined to the

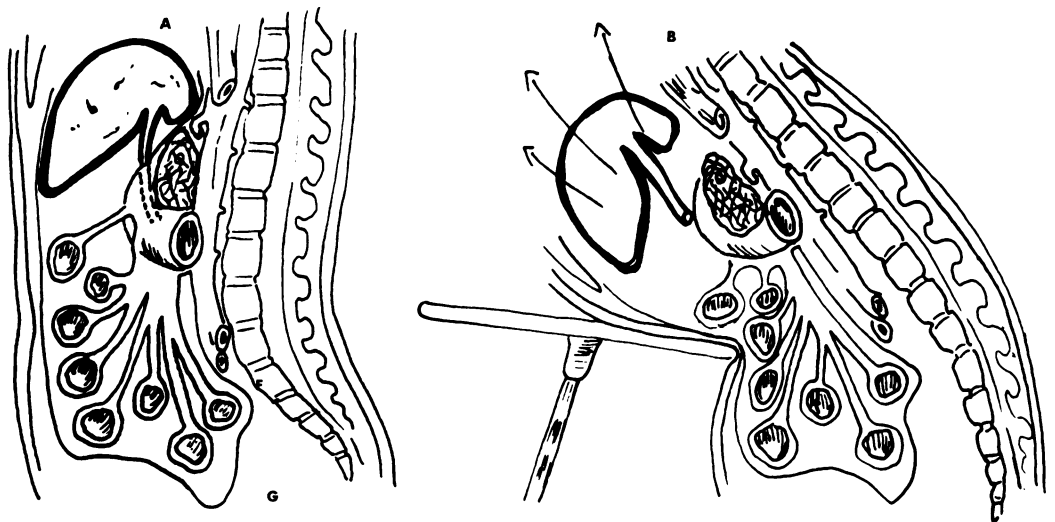


FIG. 4. A. Diagrammatic longitudinal section of the abdomen. B. Mechanism of duodenal injury illustrated by a steering wheel compressing the abdomen. The liver is driven cephalad by the compression of the abdomen and by the deceleration force. Traction is exerted along the common bile duct tearing the more static duodenum in the region of the papilla of Vater.

retroperitoneal area, vague pain in the back or epigastric area may be the only complaint, but if the digestive action of leaking duodenal contents penetrates the overlying posterior peritoneum into the free peritoneal cavity, symptoms such as in this case or in any acute perforated duodenal ulcer are produced.

Instances of patients with this injury for 2½, 5, 6, 14, 18 and 210 days with few symptoms are recorded in the literature.<sup>1</sup> In these patients the leak was probably confined to the retroperitoneal space.

### Discussion

In the literature on retroperitoneal rupture of the duodenum from blunt abdominal trauma, no other instance of avulsion of the papilla of Vater was found. Transection or tears at the junction of the second and third portions of the duodenum are reported.<sup>1</sup> The effect of a decelerating force transmitted to the upper abdomen by an automobile steering wheel is difficult to evaluate when the duodenum is involved. In this case it appears that the injury was produced by traction on the common duct upward against a stable duodenum. It may be that a force compressing the costal arches and anterior abdomen drives the liver and diaphragm upward while the pancreatoduodenal area remains relatively stable or lags behind the

movement of the liver and diaphragm. Traction would then be exerted by the common duct and hepatoduodenal ligament on the static duodenum with a resultant rip of the bowel distal to insertion of the common duct (Fig. 4).

### Summary

Blunt abdominal trauma resulting from an automobile accident is becoming a more frequent injury.

A case of traumatic avulsion of the papilla of Vater successfully treated by closure of the duodenal rent and Roux en-Y drainage of the papilla is presented. The mechanism of injury to the second and junctional area between the second and third portions of the duodenum is suggested as being due to traction tears mediated through the hepatoduodenal ligament and common bile duct.

### References

1. Cleveland, H. C. and W. R. Waddell: Retroperitoneal Rupture of the Duodenum due to Nonpenetrating Trauma. *Surg. Clin. N. Amer.*, **43**:413, 1963.
2. Cohn, I., Jr., H. R. Hawthorne and A. S. Frobese: Retroperitoneal Rupture of the Duodenum in Nonpenetrating Abdominal Trauma. *Amer. J. Surg.*, **84**:293, 1952.
3. Gould, R. J. and W. T. Thorworth: Retroperitoneal Rupture of the Duodenum due to Blunt Nonpenetrating Abdominal Trauma. *Radiology*, **80**:743, 1963.
4. Moore, S. W. and M. E. Erlandson: Intramural Hematoma of the Duodenum. *Ann. Surg.*, **157**:798, 1963.

*Continued from page 885*

Surgical Treatment of Chronic Internal Carotid Artery Occlusion by Saline Endarterectomy

Significance of Pyruvate and Lactate According to Volume of Blood Transfusion in Man: Effect of Exogenous Bicarbonate Buffer on Lactacidemia

Congenital Lobar Obstructive Emphysema: Report of 8 Patients and Review of Literature

Choledochoduodenostomy with Reference to Secondary Cholangitis: 15-Year Review of 24 Cases

Surgical Correction of Tuberculous Pseudoaneurysm of Upper Abdominal Aorta: First Reported Case

Aneurysm of the Portal Vein and Portal Hypertension: First Reported Case

*Continued on page 932*