

Variation in Size of the Gastric Antrum: Measurement of Alkaline Area Associated with Ulceration and Pyloric Stenosis

W. M. CAPPER, F.R.C.S., T. J. BUTLER, M.D., F.R.C.S.,
K. G. BUCKLER,* F.R.C.S., C. P. HALLETT,** M. B., CH.B.

*From the Royal Infirmary, Southmead and Frenchay Hospitals, and the Department
of Physiology, University of Bristol, England*

THE ESSENCE of the surgical treatment of duodenal ulceration is adequate reduction of gastric hypersecretion. The extent of reduction that may be achieved by various procedures is summarized in Table 1.

The combination of antrectomy and vagotomy as the most effective method of reduction of secretion has a sound physiologic basis in that it removes both the neural and hormonal stimuli for such secretion. Other advantages of this operation include:

1. A large part of the stomach is retained, permitting a good food intake, without serious postcibal symptoms.

2. Duodenal continuity can usually be maintained. This is essential for maximal absorption.⁴

3. Ulcer recurrence, as well as the other sequelae of gastrectomy, are minimal.

4. Duodenal inhibitor mechanisms are retained, at least in part.

Although not all surgeons believe that antrectomy and vagotomy is universally indicated, all would agree with the criteria to be observed if the antrum is retained—it should be denervated, remain in the food stream, and be free from stasis.²³

The problem of antrectomy involves *recognition and accurate definition of the*

antrum. The ulcerogenic nature of retained antral tissue is well recognized and has been stressed by Harrison *et al.*¹⁵ Pe Thein and Schofield²⁷ demonstrated in dogs that only a small part of the antrum need be retained to maintain the hormonal phase of gastric secretion. All surgeons are familiar with the large increase in recurrent ulceration (up to 20–30%) that may follow Polya gastrectomy if a small piece of antral tissue is included inadvertently in the duodenal stump, where it may be bathed constantly in alkaline secretion. Antral tissue may also be left in the gastric remnant after gastrectomy^{8, 22} and may determine the site of further ulceration.

Review of Literature

There are several considerations relevant to the size and features of the gastric antrum.

Anatomic. The descriptions in the classical anatomic works—Gray,¹³ Cunningham,⁷ Last,¹⁸ Callander⁵—merely indicate its location in the distal part of the stomach and are of little surgical application.

Macroscopic Appearance of Mucosa. In complete contrast to postmortem specimens, the antrum in life is covered by flat mucosa, whereas that of the fundus is rugose. Landboe-Christensen¹⁷ compared the visible antrofundic junction with histologic studies and found approximate coincidence. Antral mucosa extended along 43.7 to 56.3 per cent of the lesser curvature

Submitted for publication March 12, 1965.

* Research Fellow, Medical Research Council, 1962–64.

** In receipt of part-time research grant, Medical Research Council, 1963–65.

TABLE 1. *Extent of Reduction of Gastric Secretion Achieved by Various Surgical Procedures*

Operation	% Reduction
Partial gastrectomy	50-90 (variable)
Vagotomy	65
Antrectomy	65
Vagotomy plus antrectomy	95

and 15 to 16 per cent of the greater curvature. Dean and Mason⁸ found good correlation between the naked-eye junction and histologic confirmation. The special points to be noted are the irregularity of the line of the antrofundic junction and the presence of a wide border zone. Using the special technic of pH monitoring (vide infra), we have found naked-eye assess-

TABLE 2. *Summary of Surgical Procedures for Antrectomy*

Authors	Scope of Resection
1. Farmer and Smithwick ¹⁰ (1952)	Hemigastrectomy
2. Sauvage <i>et al.</i> ²⁸ (1953)	40% distal gastrectomy
3. Waddell and Bartlett ³⁰ (1957)	Hemigastrectomy
4. Edwards and Herrington ⁹ (1957)	Hemigastrectomy demarcated by 50% of less curvature and greater curvature
5. Welbourn and Johnston ³¹ (1961)	Distal gastrectomy demarcated by 50% of lesser curvature and 33% of greater curvature
6. Palumbo <i>et al.</i> ²⁶ (1962)	Distal 25% gastrectomy
7. Griffith <i>et al.</i> ¹⁴ (1963)	Hemigastrectomy
8. Nyhus <i>et al.</i> ²³ (1963)	Hemigastrectomy—all lesser curvature plus 2 cm. of duodenum
9. Goligher <i>et al.</i> ¹² (1964)	Distal gastrectomy—50% or 33%
10. Tanner ²⁹ (1964)	Distal gastrectomy—45% lesser curvature and 12% greater curvature
11. Oberhelman ²⁴ (1964)	Distal gastrectomy—40% lesser curvature and 13% greater curvature

ment of the antrofundic junction to be inaccurate (Fig. 1).

Histologic Studies. Detailed studies of this type constitute the most fundamental observations to date. Magnus²⁰ demonstrated the great variations in the area of antral mucosa and indicated that it could extend almost to the cardia, especially in patients with gastric ulcer. Oi *et al.*²⁵ in Japan reported that antral mucosa extends more than 10 cm. from the pylorus in 22 per cent of patients, reaching almost to the cardia in 10 per cent. Dean and Mason,⁸ using similar technics to those of Magnus,²⁰ found antral mucosa extending about 9 cm. from the pylorus along the lesser curvature and 7 cm. along the greater curvature.

With respect to surgery, histologic confirmation of removal of all antral mucosa must be retrospective, but a frozen section technic at operation, as suggested by Kay,¹⁶ may be used to define the antrofundic junction with moderate accuracy.

Surgical Considerations. The literature reveals a variety of procedures for antrectomy. Some of these are summarized in Table 2. The only point to be observed here is that these procedures were routine despite the variations in antral dimensions. Hemigastrectomy with vagotomy emerged not so much as a method of doing antrectomy but because it was found that vagotomy with more than 50 per cent gastric resection was likely to be followed by unastisfactory results.

Physiologic Considerations. It is evident that the antrum is more of a physiologic concept than an anatomic one. The antrum is best defined as the distal part of the stomach which contains and releases gastrin. The mucosa of this part is of "pyloric type" and the pH is in the neutral or alkaline range. For antrectomy to be adequate, this zone must be defined accurately and it also must be shown that the excised tissue contains all the gastrin-

secreting mucosa of the stomach. Exploration of these two features was the purpose of the studies presented here.

Direct Study of Antrum during Gastric Surgery

In vivo studies in animals have been made by Bockus,³ Lowicki and Littlefield¹⁹ and Moe *et al.*²¹ A preliminary report of our method in man was published in 1962.⁶ We have now studied more than 190 cases. It appears to us to be a simple, quick and accurate method of assessment.

Method. The stomach at operation is opened with a diathermy knife along the anterior gastric surface, half way between the lesser and greater curvatures along a line starting about 3 cm. from the pylorus and extending proximally for 7 cm. The edges are held by sutures and drawn back over towels until the gastric mucosa is adequately exposed. Bleeding is usually controlled by diathermy, but occasionally catgut sutures are necessary. Hemostasis is important; blood has buffering capacity and can alter pH readings.

Pilot Studies. In the initial studies, methyl orange, and later universal indicator paper, were used, being applied to the dried mucosal surface. It became apparent that the junction of the antrum and fundus was a readily defined line with irregular indentations which was not identical with the junction of the smooth and rugose mucosa (Fig. 1). It was easier to define when histamine was given. It was our practice after this to give an anti-histaminic agent (mepyramine malleate, 100 mg. intramuscularly) preoperatively, followed by histamine acid phosphate (0.04 mg./Kg. body weight subcutaneously), about 20 minutes before the investigation was made. Flow of acid is so rapid that constant suction and mopping are necessary to keep the field dry. It was also necessary to avoid any trauma which might cause bleeding of the mucosa. In

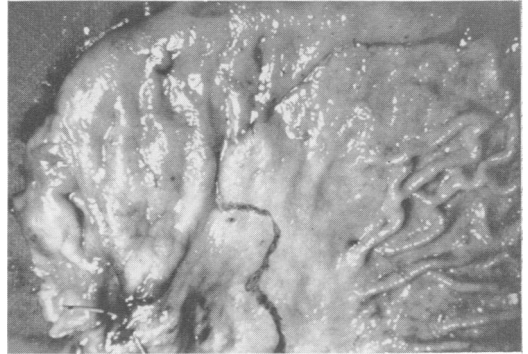

FIG. 1. Antro-fundic junction as monitored by pH estimation and marked by black line is distal to the end of rugose mucosa.

a few cases, fluorescein was used as an indicator, 10 ml. of 5 per cent solution injected intravenously. Fluorescein is destroyed in an acid medium, and under ultraviolet light the alkaline areas can be seen clearly. This method proved to be too cumbersome for use in the operating theater and was abandoned.

Present Technic. For the past 2 years we have used a pH meter with a flat-ended glass electrode to monitor the alkaline zone. This can be quickly and accurately mapped out, marked by diathermy, the stomach closed and the defined amount of distal stomach removed to achieve a complete antrectomy. The alkaline area is the same whether vagotomy is carried out before or after monitoring. We have found it best to mix 100 mg. mepyramine malleate with 2 mg. of histamine in a total volume of 10 ml. sterile saline and give this mixture intravenously at the rate of 5 ml. per hour using a "scolinater."²² The injection is begun 20 minutes before observations are made.

It soon became apparent that the size of the antrum varied considerably from person to person. It was decided to investigate this variation. A small esophageal tube graduated in centimeters is passed into the stomach and anchored exactly at the pylorus and also half way down the lesser curve. The length of the lesser curve,

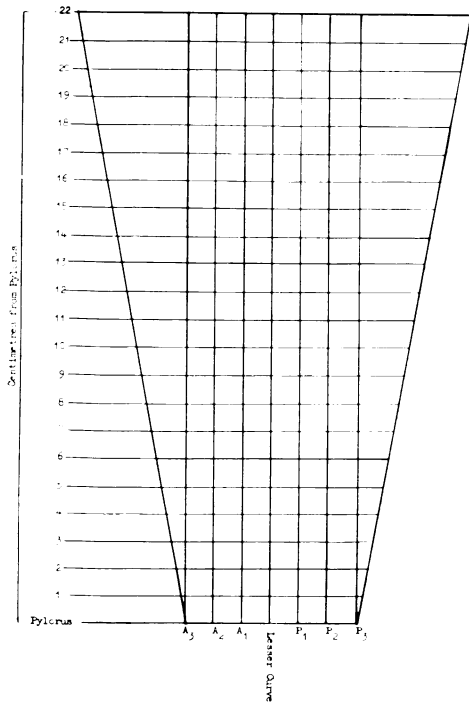
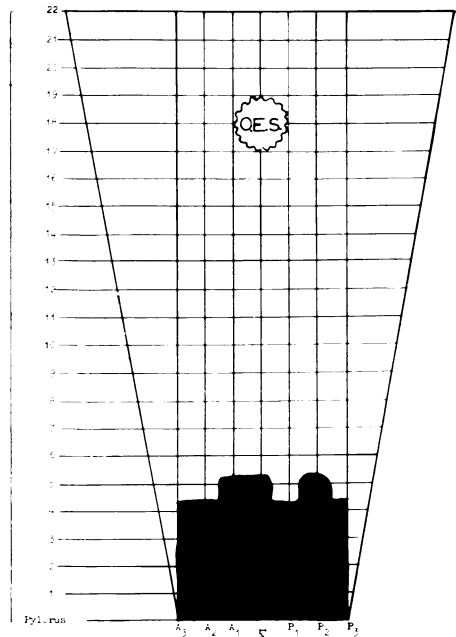


Fig. 2. Chart used for measuring the alkaline area of the live collapsed stomach.



GASTROTOMY FOR FOREIGN BODY ♂ Oct 24

Fig. 3. Alkaline area in a "normal" stomach.

which varies between 16 and 22 cm in the live collapsed stomach, is measured and the alkaline area marked in black on a special chart (Fig. 2) in cm., first along the lesser curve, then on the anterior wall (A1, A2, A3), and finally on the posterior wall (P1, P2, P3). The procedure so far has not led to increased morbidity.

Clinical Observations in 130 Cases

Normal (Fig. 3). It has not been possible to examine more than one "normal" case. In this instance gastrotomy had to be done to remove a long nail which had been swallowed.

Duodenal Ulcer (Fig. 4, 5). The alkaline area in these cases is usually normal or smaller than normal.

Gastric Ulcer (Fig. 6, 7). The alkaline area is very much larger than in the case of duodenal ulcer and may include the whole of the lesser curve with patches of

acid mucosa in various areas. In every case the ulcer was found in an alkaline area.

Channel Ulcer (Fig. 8). This was found only in 12 cases but seems to present a field similar to that of duodenal ulcer.

Combined Gastric Ulcer and Duodenal Ulcer (Fig. 9). Here the alkaline area is larger than in duodenal ulcer but not so large as in gastric ulcer alone.

Ulcerative Antritis (Fig. 10). In 15 cases a condition of subacute ulceration of the antrum was found. These patients presented with a classical history of peptic ulcer but barium meal x-rays and external examination of the stomach were negative. A gastrotomy was done, and ulcerative antritis, usually hemorrhagic, was found. Antrectomy gave relief of symptoms.

Pyloric Stenosis. In some cases the alkaline area in this condition was found to

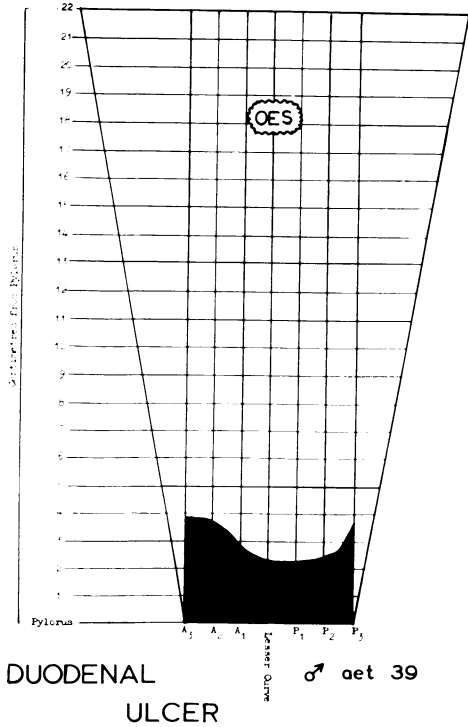


FIG. 4. Alkaline area in duodenal ulcer.

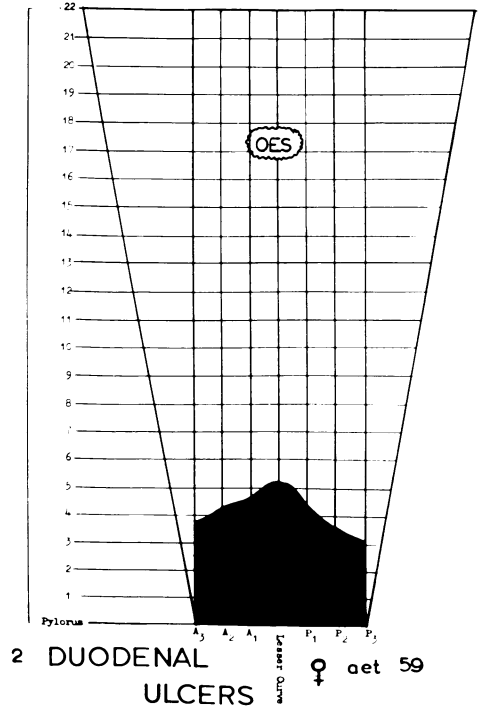


FIG. 5. Alkaline area in duodenal ulcer.

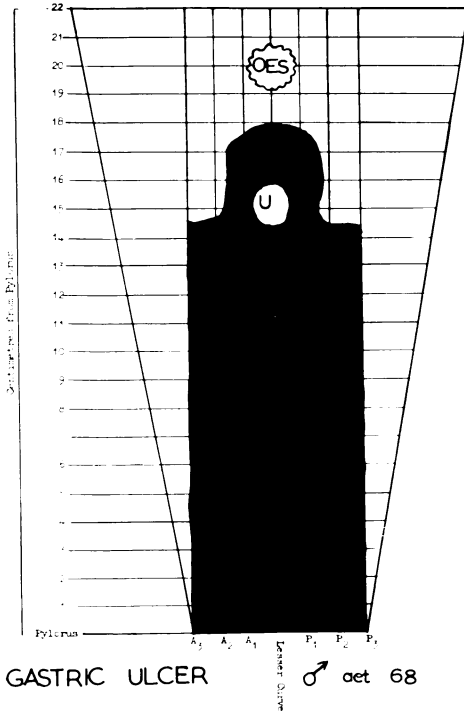


FIG. 6. Alkaline area in gastric ulcer.

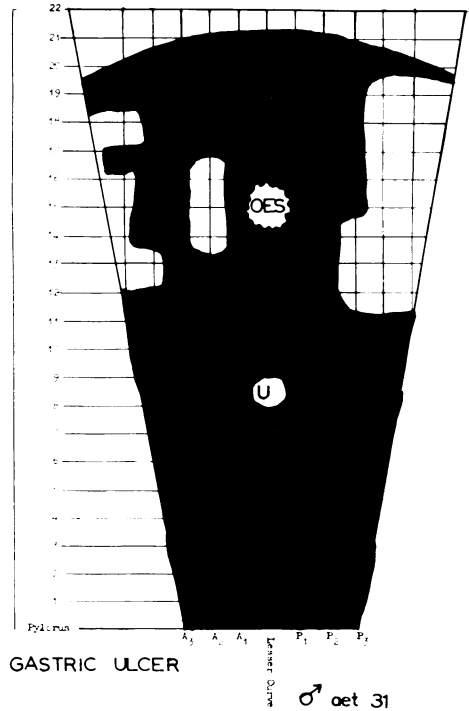
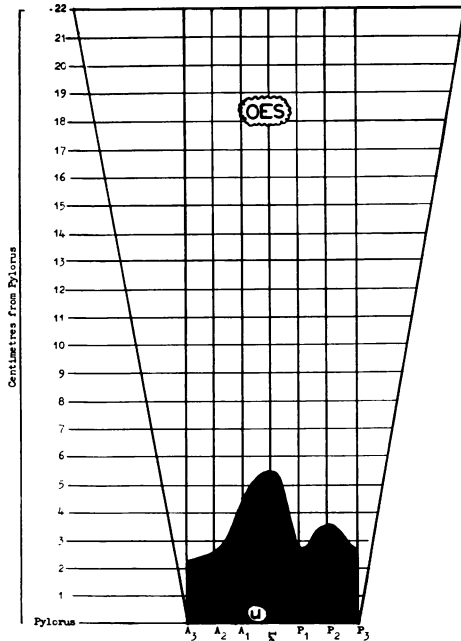
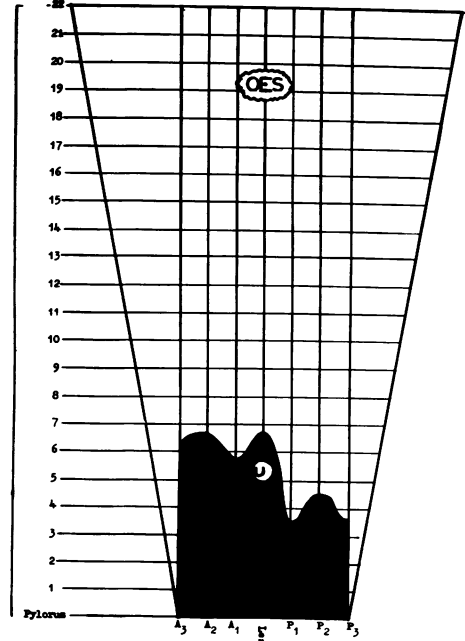


FIG. 7. Alkaline area in gastric ulcer.



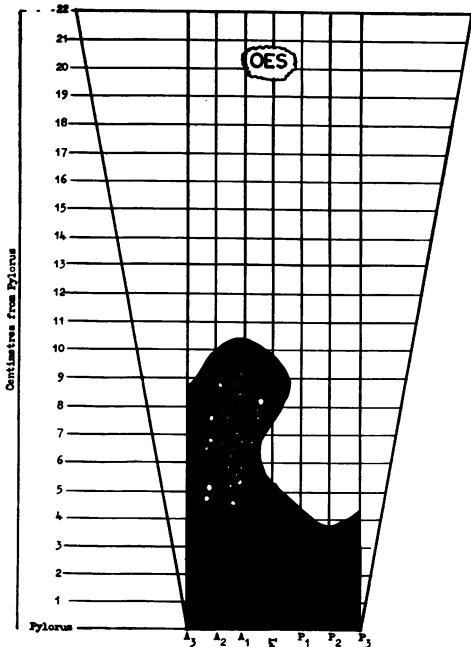
PYLORIC CHANNEL ULCER ♂ aet 61



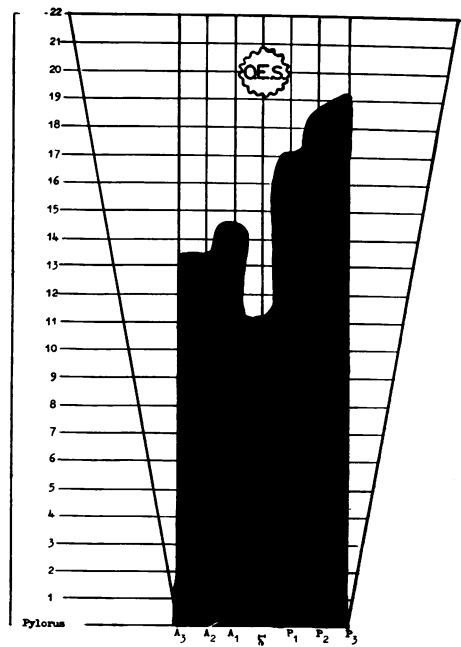
DUODENAL AND GASTRIC ULCERS ♂ aet 40

FIG. 8. Alkaline area in pyloric channel ulcer.

FIG. 9. Alkaline area in combined gastric ulcer and duodenal ulcer.



ULCERATIVE ANTRITIS ♀ aet 62



DUODENAL ULCER PIN-HOLE PYLORUS ♂ aet 57

FIG. 10. Alkaline area in ulcerative antritis.

FIG. 11. Alkaline area in pyloric stenosis.

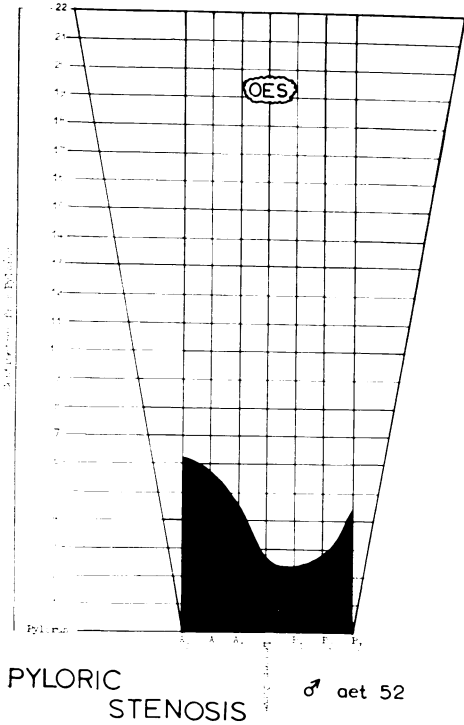


FIG. 12. Normal alkaline area in a case of pyloric stenosis.

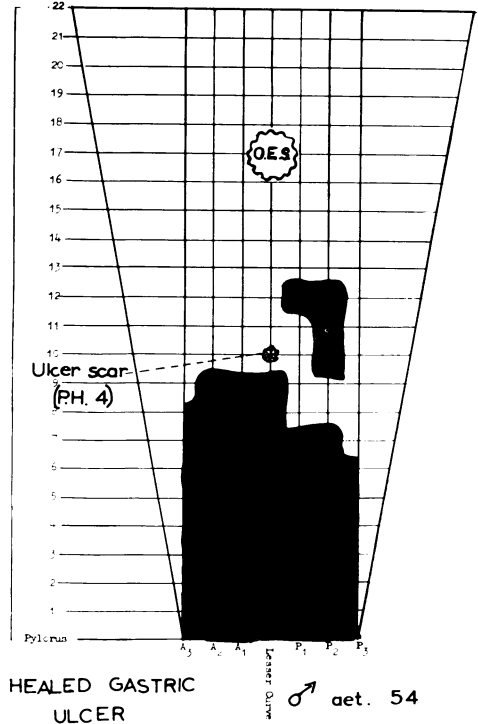


FIG. 13. Alkaline area in a case of a healed gastric ulcer.

be extensive (Fig. 11), in others it was normal (Fig. 12).

Healed Gastric Ulcer. A most interesting observation was made in four cases in which the gastric ulcer had healed. Figure 13 is a good example. A 54-year-old man had a large perforating ulcer about 3 years previously which had been treated medically. It was decided to operate if there was a recurrence. Symptoms did recur and on gastrotomy the ulcer scar, which was plainly visible on the external surface, was covered by acid-secreting mucosa (pH 4), and the antrofundic line was 1 cm. distal to it. These findings were confirmed by histologic study—there were oxyntic cells in the mucosa over the scar. The scar was similarly covered by acid mucosa in the three other cases.

Excised Ulcer (Fig. 14). A 70-year-old man had had a transthoracic operation 5½ years previously for hiatal hernia when

a lesser curve gastric ulcer was also found. The ulcer was excised and the gastric wound sutured transversely with fine steel wire. At the second operation for a small ulcer in the antrum, the wire suture clearly marked the site of the previous ulcer. It was surrounded and covered by acid epithelium.

Ulcer in "Alkaline Island" (Fig. 15). In four instances the ulcer was found in an island of alkaline mucosa surrounded by acid mucosa. Most of these findings have been confirmed by histologic examination.

Summary of Results. Table 3 shows the size of the alkaline area as measured between A3 and P3 in various pathologic conditions. Although 190 cases have been studied the table is confined to 130 cases. Results of the remainder have been discounted due to possible inaccuracy of the recordings resulting from acid overflow and other factors.

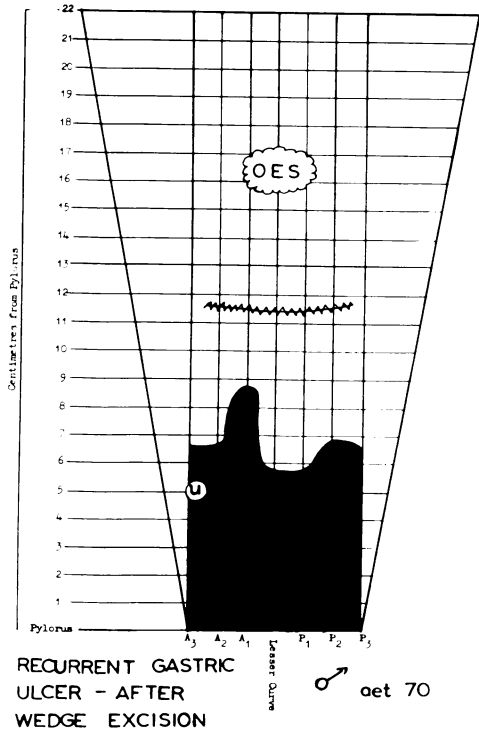


FIG. 14. Alkaline area in a case of recurrent gastric ulcer after wedge excision showing site of previous ulcer.

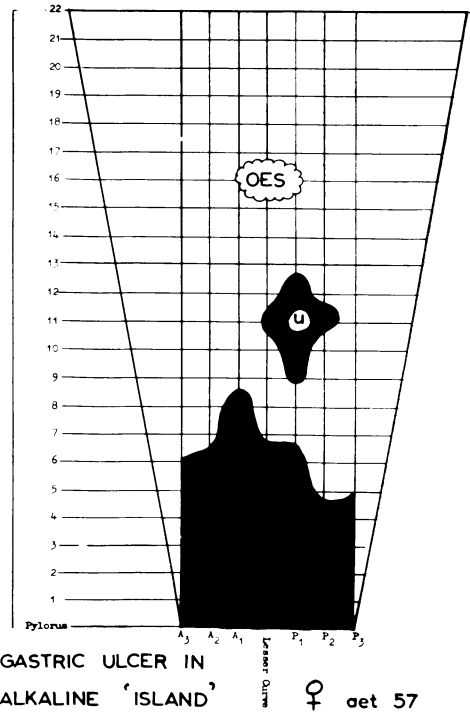


FIG. 15. Gastric ulcer in an alkaline "island."

Gastrin Assay Studies. While the pH monitoring tests were in progress, an investigation was carried out to check the gastrin content of the resected antra. This was an essential corollary to be certain that all the gastrin-containing mucosa was removed. This part of the investigation embraced gastrin assay of specimens in which the antral size was assessed by

TABLE 3. Size (Cm.²) of Alkaline Area (Gastric Antrum) in Various Pathologic Conditions*

	No. Cases	Mean Area	Range	Standard Deviation
Duodenal ulcer	64	31.0	8-64	10.6
Channel ulcer	12	33.3	15-65	15.4
Pyloric stenosis	29	40.8	15-98	19.7
Gastric and duodenal ulcers	12	45.6	32-69	10.6
Gastric ulcer	20	67.7	40-112	20.7

* Measured 3 cm. each side of lesser curve.

naked-eye appearance as well as in those defined by pH monitoring.

Large serial sections of the gastric mucosa were made and subjected to an extraction process yielding an unpurified, but histamine-free, extract. The method was basically that described by Blair *et al.*² A technic of assay on the rat^{3,4} was used to demonstrate the presence of gastrin in the extract and to give an approximate comparison of the gastrin content of the serial mucosal sections.

Preliminary studies of five "visually-assessed antra" indicated that gastrin was present in the whole antrum, in the distal two thirds, or only in the pyloric one third.

Eighteen antra demarcated by the pH monitoring technic have been subjected to assay, and in ten there was marked reduction in the gastrin content of the mucosa on the fundic side of the demarcation line

(Fig. 16, area C). In eight, only a small reduction could be demonstrated. Four of these eight, however, were from patients with pyloric stenosis, i.e. with an increased size of the antrum. One interpretation of this finding is that as far as gastrin content is concerned, the antrofundic line may be a wide "border zone" containing both antral and fundic mucosa.

These studies indicate that naked-eye assessment of the antrum is unsatisfactory and suggest that pH monitoring is a useful surgical technic to ensure adequate removal of antral mucosa in patients with duodenal ulcer, but without pyloric stenosis.

Discussion

The wide variation in antral size, especially when histologic criteria are used, has been reported in the literature. The present studies, based on functional criteria, confirm this—especially the difference between the small antrum of duodenal ulcer and the large one of gastric ulcer. In addition, the irregular expansion of the antrum proximally, in patients with pyloric stenosis following duodenal ulcer, has been demonstrated. It can be stated confidently that the antrum in duodenal ulceration, with recognized hypersecretion, is small, and minimal resection is required to achieve adequate antrectomy.

Gastric ulcers were observed only in alkaline zones of mucosa or in islands of alkaline mucosa within the fundic area. This confirms the histologic observations of Magnus.²⁰ When a gastric ulcer heals, however, the site may be covered by fundic mucosa. This corresponds with the clinical observation that healing of a gastric ulcer may be accompanied by an increase in acid secretion.

This observation, together with that of the increase in antral size in pyloric stenosis, suggests that the antrofundic junction is not static but may migrate up and down

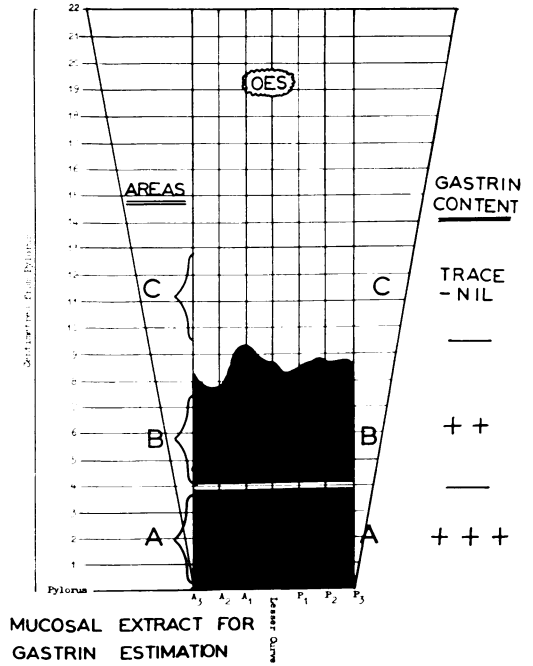


FIG. 16. Gastrin content of resected antra.

the stomach. The cause of this change and the resultant variation in the size of the antrum and of the parietal cell mass are unknown and needs further study. The speed of such change is also unknown and is undoubtedly related to the epithelial turnover rate of gastric mucosa. One question emerging from this work is whether variation in mucosal type is associated with a corresponding change in gastrin content. The alkaline area can be either normal antrum or fundic mucosa altered by a gastritis. Differentiation is often difficult histologically and, in the final analysis, it may be that it is necessary to determine the gastrin content of mucosa in order to reveal its true ancestry.

Summary

A method of monitoring the pH of gastric mucosa at operation is described. Observations made on 130 patients are presented.

The alkaline zone shows great variation in size. It is small in patients with duodenal

ulcer and channel ulcer, and is large in patients with gastric ulcer. When pyloric stenosis occurs, the alkaline zone increases in size.

Gastrin assay on the resected alkaline zone indicates that the pH monitoring system is an aid to precise antrectomy in patients with duodenal ulcer without associated stenosis.

When a gastric ulcer heals, the ulcerated area is covered by oxyntic cells.

Attention is drawn to the necessity of gastrin assay studies to identify the true nature and origin of alkaline mucosa in the stomach.

References

- Amure, B. O. and Ginsburg, M.: The Effects of Gastrin in the Rat. *J. Physiol. (Lond.)*, **170**:30, 1963.
- Blair, E. L., Harper, A. A., Larke, H. J., Reed, J. D. and Scratcherd, T.: A Simple Method of Preparing Gastrin. *J. Physiol. (Lond.)*, **156**:11, 1961.
- Bockus, H. L.: *Gastroenterology*, Vol. I. Philadelphia, W. B. Saunders Co., 1944. p. 225.
- Butler, T. J.: The Effect of Gastrectomy on Pancreatic Secretion in Man. *Ann. Roy. Coll. Surg. Engl.*, **29**:300, 1961.
- Callander: *Surgical Anatomy*, Anson, B. J. and Maddock, W. G., ed., 3rd Ed. Philadelphia, W. B. Saunders Co., 1952. p. 396.
- Capper, W. M., Laidlaw, C. D., Buckler, K. G. and Richards, D.: The pH Fields of the Gastric Mucosa. *Lancet*, **2**:1200, 1962.
- Cunningham, D. J.: *Textbook of Anatomy*, 10th Ed. London, Oxford Univ. Press, 1964. p. 405.
- Dean, A. C. B. and Mason, M. K.: The Distribution of Pyloric Mucosa in Partial Gastrectomy Specimens. *Gut*, **5**:64, 1964.
- Edwards, L. W. and Herrington, J. L.: Efficacy of 40 Per Cent Gastrectomy Combined with Vagotomy for Duodenal Ulcer. *Surgery*, **41**:346, 1957.
- Farmer, D. A. and Smithwick, R. H.: Hemigastrectomy Combined with Resection of the Vagus Nerves. *New Engl. J. Med.*, **247**:1017, 1952.
- Ghosh, M. N. and Schild, H. O.: Continuous Recording of Acid Gastric Secretion in the Rat. *Brit. J. Pharmacol.*, **13**:54, 1958.
- Goligher, J. C., Pulvertaft, C. N. and Watkinson, G.: Controlled Trial of Vagotomy and Gastroenterostomy, Vagotomy and Antrectomy, and Subtotal Gastrectomy in Elective Treatment of Duodenal Ulcer: Interim Report. *Brit. Med. J.*, **1**:455, 1964.
- Gray, H.: *Anatomy Descriptive and Applied*, 33rd Ed. London, Longmans, Green Co., 1962. p. 1440.
- Griffith, C. A., Stavney, L. S., Kato, T. and Harkins, H. N.: Selective Gastric Vagotomy Combined with Hemigastrectomy and Billroth I Anastomosis. *Amer. J. Surg.*, **105**:361, 1963.
- Harrison, R. C., Williams, H. T. G., Pisesky, W., Husain, S., Silbermann, O. H., Francis, G. J. and Irvine, J. W.: The Relative Importance of the Vagus Nerve, Antrum, Acid-Secreting Mucosa in Experimental Peptic Ulceration. *Surgery*, **50**:151, 1961.
- Kay, A. W.: *Gastro-Intestinal Surgery and Human Physiology*. *J. Roy. Coll. Surg. Edinb.*, **1**:275, 1962.
- Landboe-Christensen, E.: Extent of the Pylorus Zone in the Human Stomach. *Acta Path. Microbiol. Scand. Suppl.* **54**:671, 1944.
- Last, R. J.: *Anatomy, Regional and Applied*, 3rd ed. London, Churchill Ltd., 1963. p. 415.
- Lowicki, E. M. and Littlefield, J. B.: An Experimental Method of Precisely Defining the Dimensions of the Gastric Antrum. *Surg. Forum*, **12**:398, 1961.
- Magnus, H. A.: The Pathology of Peptic Ulceration. *Postgrad. Med. J.*, **30**:131, 1954.
- Moe, R. E., Nyhus, L. M. and Harkins, H. N.: The Use of Dye for Differentiating the Gastric Antrum from the Gastric Corpus. *Bull. Soc. Int. Chir.*, **22**:424, 1964.
- Nuboe, J. F.: Recurrent Ulceration after Surgical Treatment of Gastroduodenal Peptic Ulcer. *Ann. Roy. Coll. Surg. Engl.*, **28**:303, 1961.
- Nyhus, L. M., Condon, R. E. and Harkins, H. N.: The Evolution of Surgery for Duodenal Ulcer during Mid-Twentieth Century. *J. Roy. Coll. Surg. Edinb.*, **8**:91, 1963.
- Oberhelman, H. A.: Chapter 12 in Zimmerman, L. M. and Levine, R.: *Physiologic Principles of Surgery*, 2nd Ed. Philadelphia, W. B. Saunders Co., 1964. p. 499.
- Oi, M., Oshida, K. and Sugimura, S.: The Location of Gastric Ulcer. *Gastroenterology*, **36**:45, 1959.
- Palumbo, L. T., Sharpe, W. S., Lulu, D. J., Bloom, M. H. and Bloom, H. R.: Results in 300 Cases of Antrectomy with Bilateral Vagotomy for Chronic Duodenal Ulcer. *Surgery*, **51**:289, 1962.
- Pe Thein, M. and Schofield, B.: Release of Gastrin from the Pyloric Antrum Following Vagal Stimulation by Sham Feeding in Dogs. *J. Physiol. (Lond.)*, **148**:291, 1959.
- Sauvage, L. R., Schmitz, E. J., Storer, E. H., Kanar, E. A., Smith, F. R. and Harkins, H. N.: The Relation between the Physiologic Stimulatory Mechanisms of Gastric Secretion and the Incidence of Peptic Ulceration. *Surg. Gynec. Obstet.*, **96**:127, 1953.
- Tanner, N. C.: The Surgical Treatment of Peptic Ulcer. *Brit. J. Surg.*, **51**:5, 1964.
- Waddell, W. R. and Bartlett, M. K.: Antral Exclusion with Vagotomy for Duodenal Ulcer. *Ann. Surg.*, **146**:3, 1957.
- Welbourn, R. B. and Johnston, I. D. A.: The Assessment and Selection of Elective Operations for Peptic Ulceration. *British Surgical Practice, Surgical Progress*, London, Butterworths, 1961. p. 301.
- Woolmer, R.: Personal Communication, 1962.