

Endocardial Cushion Defects

FRANK GERBODE, M.D., PEDRO A. SANCHEZ, M.D., RUBEN ARGUERO, M.D.,
WILLIAM J. KERTH, M.D., J. DONALD HILL, M.D.,
PIETER A. DEVRIES, M.D., ARTHUR SELZER, M.D.,
SAUL J. ROBINSON, M.D.

*From the Department of Cardiovascular Surgery, Presbyterian Medical Center, and
the Heart Research Institute, Institute of Medical Sciences,
San Francisco, California*

THE REPAIR of endocardial cushion defects has become an established procedure in most centers. This analysis will attempt to establish the effectiveness of operative intervention, and more specifically to emphasize the importance of certain technical features of the procedure. A study of our patients who have had repair of the mitral and tricuspid valves has led to certain conclusions regarding the long-term results of operations.

From von Rokitansky⁹ in 1875 through Van Mierop *et al.*⁷ in 1962, several authors have classified and reclassified congenital heart defects related to a region known embryologically as the atrioventricular canal. These classifications for the most part have been based either on observed anatomical variations of lesions in what is believed to be the atrioventricular canal area of the developed heart or on anatomical variations plus conjecture as to the embryogenesis of the defect.

We use the term conjecture in regard to embryogenesis for no one to date has observed the maldevelopment of embryo hearts during the time when fusion and development of atrioventricular cushions is

normally taking place. Furthermore, it must be recognized that the so-called dorsal and ventral atrioventricular cushions are not anatomical landmarks or regions which are definable throughout embryonic development, but rather they evolve from general subendocardial layer of cardiac jelly and subsequently through a rather short period of time evolve into connective tissue structures in the region of the atrioventricular junction. The mode of development of the atrioventricular cushions from subendothelial or subendocardial tissue seems at first glance adequate support for the use of the term "endocardial cushion defect" as a generic term under which a number of closely related abnormalities could be grouped. Two significant points, however, mitigate against its use. First, from an historical standpoint, the term subendocardial cushion has been used to denote not only the prominences of the subendocardial layer in the region of the atrioventricular canal but also those within the infundibulum or conus of the developing heart. Second, there is the inference that these abnormalities are related primarily to a failure of development within the subendocardial layer. There is, in our opinion, no present evidence to support the view that the abnormalities are related to faulty development in this layer alone or even primarily. One might well specu-

Presented at the Annual Meeting of the American Surgical Association, May 11-13, 1967, Colorado Springs, Colorado.

Aided in part by grants from U.S.P.H.S. HE 06311 and HE 5349.

late on the question as to whether or not so-called "subendocardial cushion defects" are not the result of faulty muscular development. It is very clearly seen in early cardiac development that muscle tissue grows down into the cardiac jelly of the developing septum primum. It can also be clearly seen in viewing development of the human heart from age group 11 through 15 that the so-called widening and shift of the atrioventricular canal is primarily related to differential growth in the muscular walls of the atrial and ventricular chambers. Might it not also be possible that the cleft in the septal leaflet of the mitral valve is related to growth failure in the trabecular muscle of the left ventricle which evolve into the chordae tendineae? These are but a few examples of increasing knowledge, but persistent uncertainties, regarding embryological events in the developing heart. Though we attempt to isolate and discuss the abnormalities at the junction of the atria and ventricles as though they were isolated defects, it must be recognized that the offense to developing tissue may be more generalized within the heart. This is most interestingly demonstrated by the fact that perhaps our most valuable diagnostic criterion, derived from angiocardiography, shows an abnormally lengthened and narrowed aortic vestibule. This is found not only in complete atrioventricularis communis but also in the isolated persistent interatrial ostium primum. This defect of the aortic vestibule or junction of infundibulum with left ventricle bears witness to the fact that the development insult incurred by the lower portion of the atrial septum and atrioventricular junction was also sustained by the infundibulum or conus in the developing heart. With this in mind, we have elected to present our clinical findings within the framework of anatomical descriptions generally observable by clinician and anatomists alike. In this manner we hope that they are not incompatible with studies refer-

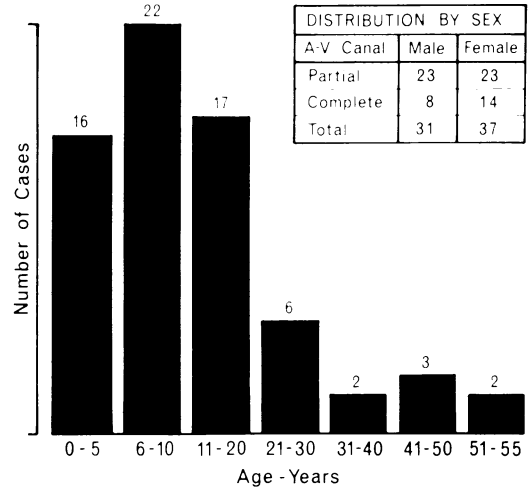


Fig. 1. Age and sex distribution of the 68 cases of endocardial cushion defects.

able to classifications of Wakai and Edwards¹⁰ or the several investigators before and after.

Clinical Material

The material is made up of 68 patients with various forms of endocardial cushion defects operated upon in the past 10 years. There were 31 men and 37 women; ages ranged from 2 to 54 years (Fig. 1).

For the purpose of analysis the classification of cases has been done on an anatomical basis (Tables 1 and 2). The partial atrioventricular canal group is made up of 46 cases which include some bizarre and complex anatomical derangements that did not fulfill the criteria for complete atrioventricular canal. There were 22 patients with complete atrioventricular canal who by definition had primum atrial defect, ventricular septal defect, cleft mitral and tricuspid valves in continuity regardless of which other defects were present. One pa-

TABLE 1. Endocardial Cushion Defects

Partial A-V canal	39
Partial A-V canal with VSD	7
Complete A-V canal	22
Total	68

TABLE 2. *Partial A-V Canal*

Ostium primum	6
Ostium primum plus	
Partial cleft mitral valve	5
Complete cleft mitral valve	6
Cleft of both mitral and tricuspid valves	20
Cleft mitral valve alone	2
Subtotal	39
Ostium primum and ventricular septal defect	
Normal valves	1
Complete cleft mitral	2
Ventricular septal defect	
Partial cleft tricuspid	1
Complete cleft tricuspid	2
Cleft mitral, multiple ventricular septal defect and muscle bar dividing tricuspid	1
Subtotal	7

tient had previously had a pulmonary artery banding for severe pulmonary hypertension in infancy.

Clinical Features

The clinical features in this larger group were fairly consistent and in general agreement with previous publications from this center on this subject.²⁻⁵ Forty-four per cent of the patients had a history of congestive failure in the past or at the time of operation. Twenty-four per cent had a history of cyanosis.

Briefly, the outstanding physical signs were a systolic murmur over the second left interspace, a "fixed" split of the second sound over this area, its intensity depending on the degree of pulmonary hypertension. Other murmurs reflected involvement of the tricuspid and/or mitral valves as follows.

A sibilant pansystolic murmur with a short diastolic murmur was present over the apex in those patients who had a mitral valve deformity (usually a cleft mitral valve).

A soft systolic and diastolic murmur localized to the fourth left interspace was

heard in virtually all patients with relative tricuspid stenosis, and if there was a cleft tricuspid valve this murmur was quite loud.

Finally, if the lesion represented an "incomplete" atrioventricular canal with an associated ventricular septal defect, a systolic thrill and a loud pansystolic murmur could be heard over the fourth left interspace.

Electrocardiograms showed a unique pattern of left axis deviation (superior frontal plane axis) with incomplete right bundle branch block and/or right ventricular hypertrophy in 84% of the cases. Those with an undeterminate or inferior frontal plane axis had pulmonary hypertension of moderately severe degree.

Roentgenograms showed cardiac enlargement and pulmonary hypervascularity. Those with mitral valve involvement showed left atrial enlargement. Table 3 depicts the degree of pulmonary hypertension in 59 patients.

Technical Considerations in the Complete Repair

Extracorporeal circulation with mild hypothermia (31° C.) was employed. In most instances exposure was through a right anterolateral thoracotomy incision. The right thoracotomy gives good visibility of the anatomy, and competence of the mitral valve is more accurately tested after repair. When a large ventricular defect was suspected we used a median sternotomy (Fig. 2-5).

TABLE 3. *Pressures in Right Ventricle and/or Pulmonary Artery*

Pressure	Partial	Complete
Normal	13	9
Elevated		
Mild (30-50 mm. Hg)	12	3
Moderate (50-80 mm. Hg)	6	4
Severe (over 80 mm. Hg)	8	4

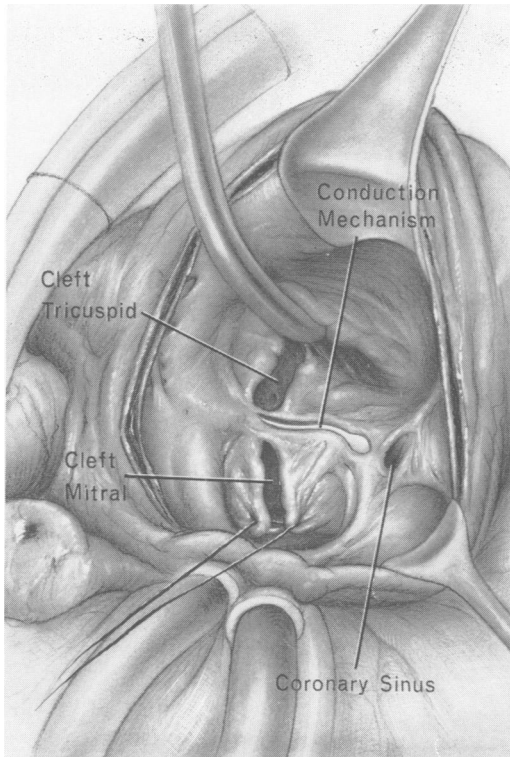


FIG. 2. The defect is visualized through the right atrium. The first step is the accurate approximation of the tips of the cleft mitral. The cleft is then closed with interrupted sutures down to the base. At this stage the valve is tested for insufficiency and changes made in the sutures if necessary.

After bypass was established a generous incision was made in the right atrium. The mitral valve was repaired first. A suture was placed in the thickened nodular area of the leaflets at the tip of the cleft to bring it precisely together. The cleft was then closed toward the base with interrupted silk sutures. When the ventricular defect was small it was closed with interrupted sutures, when medium-sized it was closed in continuity with the patch used to close the primum defect. In some of the large atrioventricular canal defects, it was necessary to utilize a separate transverse ventriculotomy to identify the limits of the respective valve areas and to close the ventricular septal defect with a separate patch from that used for the atrial repair. All

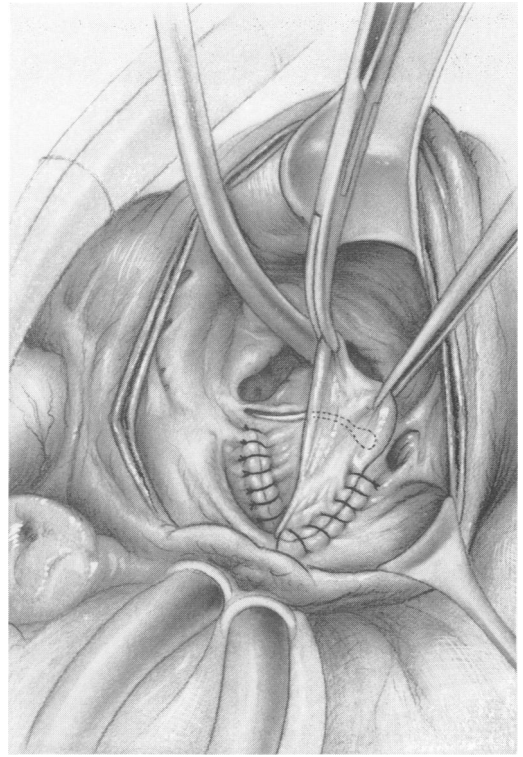


FIG. 3. The pericardial patch to close the primum defect is sewn along the "safe" edge of the defect for fixation. The area of the conduction mechanism is demonstrated.

ventricular defect patches were of Dacron. In the early operations a Dacron patch was used to close the atrial defect, however, we now prefer to use pericardium.

The conduction mechanism in this area begins between the coronary sinus and the right inferior rim of the primum defect (Fig. 2). It then runs parallel to the inferior rim of the defect to the ventricular septum where it then follows the left ventricular side of the septum. To avoid interrupting the conduction mechanism the sutures in this area are carried down onto the base of the septal leaflet of the tricuspid valve, placing the sutures parallel to the rim of the defect. The heart is kept beating throughout the procedure to detect any change in rhythm. The remainder of the patch is sewn in the customary manner (Fig. 3, 4). The cleft in the septal leaflet

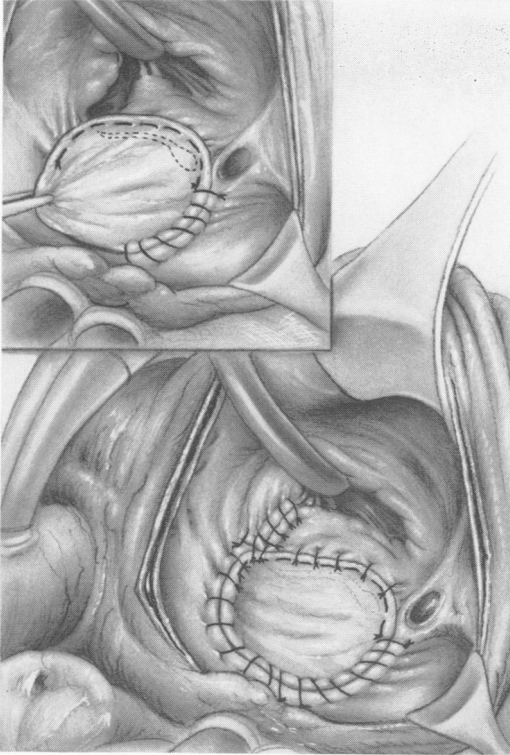


FIG. 4. The inferior rim of the defect is then closed by carrying the sutures up onto the base of the septal leaflet of the tricuspid valve and placing the sutures parallel to the rim so as not to engage part of the conduction mechanism. (Inset) The tricuspid defect is then shown closed with four interrupted sutures and the remainder of the patch sewn in the ordinary manner.

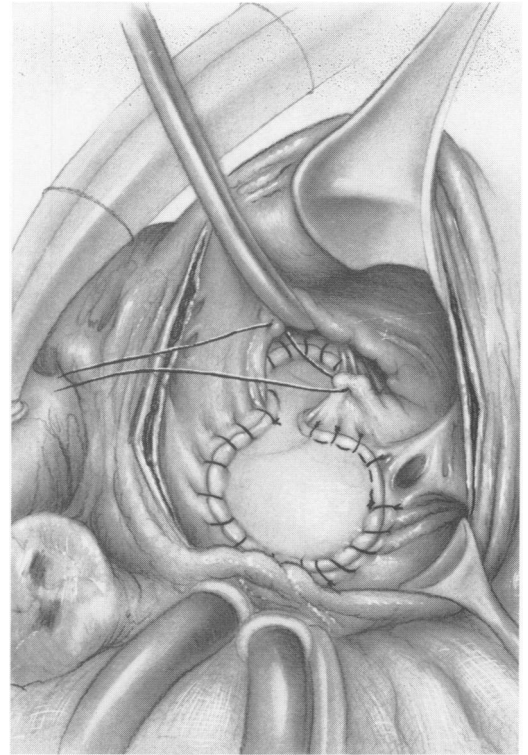


FIG. 5. If the ventricular septal defect is medium-sized a patch is used to close it in continuity with the patch closure of the atrial septal defect. A Dacron patch is used in this case. The sutures are kept on the right ventricular side of the ventricular septal defect. The first suture is shown being layed in the cleft septal leaflet of the tricuspid valve. Interrupted sutures are then used to close the defect down to its base.

of the tricuspid valve is then closed with interrupted sutures. Usually this is accomplished by finding the good free margins for suture.

Results

There have been seven hospital deaths in the partial atrioventricular canal group

TABLE 4. Results

	No.	Hospital Deaths	Late Deaths
Partial A-V canal	39	2 (5%)	3 (7%)
Partial A-V canal with ventricular septal defect	7	5 (71%)	1 (14%)
Complete A-V canal	22	4 (18%)	0 (0%)
Totals	68	11 (16%)	4 (6%)

(Tables 4 and 5). Only two of these have occurred since 1962. There have been four (8%) late deaths in this group (Table 4). Two of these occurred at 6 months, one at 2½ years and one at 3 years. Three of these four patients were operated upon before 1960. In the complete atrioventricular canal group there were four (18%) hospital deaths and no late deaths (Tables 4 and 7).

Four patients required reoperation for mitral insufficiency. Two of these occurred 3 and 7 years later. Two of these were adults (ages 55 and 54), one a full-grown teenager, and one a child. Both the adults required prosthetic valve replacements at

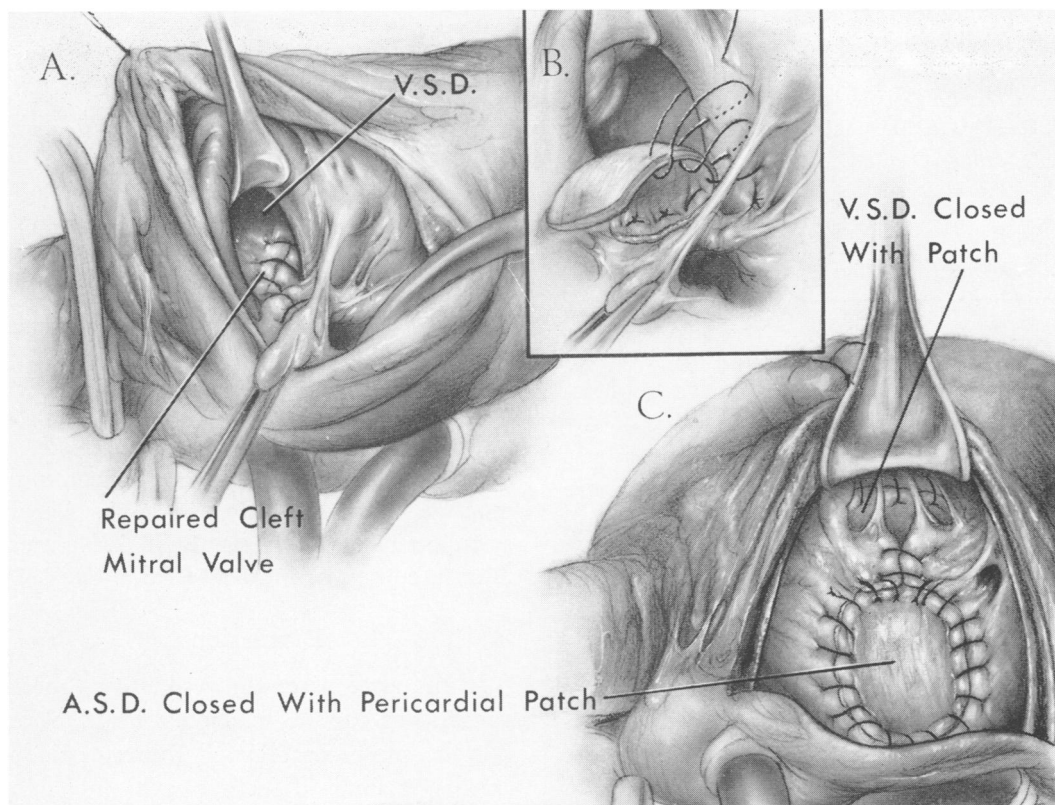


FIG. 6. In the presence of a large ventricular septal defect associated with an A-V communis two incisions are sometimes preferable—a generous right atriotomy and a transverse ventriculotomy. The first step is to identify and establish the juncture between the mitral and tricuspid aspects of the valve. The mitral valve cleft is then repaired through the right atrium. This creates a separate ventricular septal defect which is repaired with a Dacron patch from above, through the ventriculotomy. The initial sutures in the inferior aspect of the ventricular defect, close to the conduction mechanism, are taken through the annulus of the repaired mitral valve and on the right ventricular aspect of the ventricular septum until the insertion of the papillary muscle of the conus. For the remainder the sutures can be taken through the full thickness of the ventricular septum. The atrial septal defect is closed with a pericardial patch, following the technic described in Figure 4.

TABLE 5. *Early Causes of Death in Partial A-V Canal*

D. L.—1958	Unrecognized cleft mitral
R. B.—1958	Unrecognized cleft mitral
A. B.—1961	Complete heart block
A. D.—1961	Unsuspected fibromuscular subaortic stenosis
S. F.—1961	Absence of tissue of the aortic leaflet of the mitral valve
A. A.—1964	Multiple defects—valvular, supra-valvular, and infundibular pulmonary stenosis
C. L.—1966	Tricuspid muscle bar—multiple ventricular defects

TABLE 6. *Late Causes of Death in Partial A-V Canal*

I. H.—1959	Congestive heart failure. Died pre-cath. Persistent ventricular septal defect
M. H.—1960	Cause unknown. No autopsy
M. C.—1958	Common atrium. Successfully corrected. Died 6 months post-op. Cardiac heart failure
M. G.—1966	Common atrium, pulmonary stenosis successfully corrected. Died 6 months post-op. Cardiac heart failure

TABLE 7. *Early Causes of Death
in Complete A-V Canal*

L. N.—1959	Arrested during induction
S. G.—1963	Hemothorax and septicemia
M. T.—1964	Multiple defects—pulmonary stenosis, hypoplastic pulmonary artery, patent ductus arteriosus, outflow tract gusset
L. C.—1966	Membranous mitral valve

reoperation. These were the only two patients who had prosthetic valve replacements in the series. The pathology of the mitral valve in these two instances was similar. The annuli were dilated, but more specifically the chordae were stretched and elongated. Plastic repair was performed initially in one patient but immediately following operation it was evident that severe insufficiency was present. In the second patient, mitral and tricuspid insufficiency developed slowly over a 7-year period following the closure of a primum defect in the presence of normal valve cusps with dilated annuli. No anatomical clefts were found at the second operation. Both mitral and tricuspid valve replacements were performed in this patient.

Five patients developed transient atrioventricular dissociation which lasted 24 to 36 hours before reverting to sinus rhythm. Four patients developed complete atrioventricular block; only one of these has occurred in the last 49 consecutive cases. This young girl has not required a perma-

nent pacemaker. In four patients it was felt desirable to place wires for temporary pacing, although they were used in only one. This patient, an early one in the series, was a small child who had a poorly developed mitral valve. The repair failed and the child died in heart failure. Heart block was a contributing factor.

Follow-up findings have been made in 49 patients from 3 months to 7 years following operation. Ninety-three per cent have shown symptomatic improvement and a greater exercise tolerance. Roentgenograms of the chest have shown a decrease in cardiac size in 86% and reduced pulmonary hypervascularity in 93%. A soft systolic murmur is present in 72%. No murmurs are present in 28% (Table 8).

Discussion

In the analysis of the results, two major conclusions can be reached. First, that all but the most complicated forms of endocardial cushion defects can be operated upon with low risk. That experience has contributed to the great improvement in the completeness of the repair and in the mortality as shown by the results obtained in the past 5 years of operative experience as compared with the first 5 years.

Second, the late results have been very gratifying. Mitral stenosis has not been created, nor has it developed in any patient in this series. The mitral valve has functioned efficiently in all but four patients and these required reoperation. In three of these four cases a harsh loud systolic murmur was heard immediately following operation, indication of an inadequate primary repair. In only one patient, an adult, has insufficiency developed late, and this patient was one who did not have a primary mitral valve abnormality. A large primum defect had caused dilation of both mitral and tricuspid valves, with lengthening of the chordae. It was thought at the operation for closure of the primum defect

TABLE 8. *Follow-up Finding in 49 Patients
(3 Months to 7 Years)*

	No.	%
Improvement in symptomatology and exercise tolerance	46	93
Decrease in cardiac size	42	86
Decrease in pulmonary hypervascularity	46	93
Soft systolic murmur present	35	72
No murmurs present	14	28

that these would regress. However, with the passage of time they worsened considerably, caused severe heart failure, and subsequently required double valve replacement.

That endocardial cushion defects should not be operated upon because an adequate and lasting repair cannot be accomplished is not justifiable. Furthermore, it is our belief that any policy of deliberately avoiding repair of the mitral valve defect will lead to higher early mortalities, and a greater likelihood of increasing mitral incompetence.^{1, 8} If failure to secure a repair of the defects, and surgical heart block are no longer major problems, what then at this time is the major cause of death in these patients? If our experience may be used, two major causes are clear. They are the failure to appreciate preoperatively an inoperable situation of the mitral valve or ventricular septum, and the presence of severe associated multiple defects. These two causes accounted for five of our early deaths. The recognition of a severe anomaly of the mitral valve preoperatively is not easy. At the present time the precise visualization with left ventricular angiography is the best method. If an uncommon anomaly of the mitral valve is identified, suggesting the unsuitability for repair, consideration should be given to waiting until the patient is older as it is clear that mitral valve replacement in early childhood is not acceptable in the long run. It is also quite evident from our experience that if a satisfactory mitral valve repair is not accomplished, severe circulatory difficulties will be encountered in the immediate post-operative period.

The presence of severe pulmonary hypertension or bidirectional shunting has not been an absolute contraindication to operation.⁶

The management of the child with severe congestive heart failure in infancy caused by endocardial cushion defects is

still a problem. If the child is less than 3 years of age we prefer not to do open-heart surgery. This is because the mitral valve leaflets are too friable to hold sutures well. After the age of 3 or 4, however, the edges of the cleft have become thickened and fibrotic from turbulence fibrosis and will hold sutures well. In the event that complete repair is not elected because of age, we prefer to do a pulmonary artery banding knowing well we may be increasing the severity of mitral insufficiency.

Summary

The classification, clinical features, operative technic, causes of death and long-term results among 68 instances of endocardial cushion defects are reviewed.

There were five early or late deaths in the past 43 consecutive operated cases.

In the absence of complicating factors such as severe multiple defects, inoperable lesions of the mitral valve or other unsuspected lesions the operative risk is negligible.

Our experience indicates that congenital cleft mitral valves should be repaired whenever encountered.

Three patients developed complete heart block among the first 19 patients operated upon; only one patient developed complete heart block in the last 49 consecutive cases.

The operative risk is greatly increased when there are severe associated cardiac abnormalities. Whenever possible these should be identified preoperatively by selective angiography and cardiac catheterization.

The late results have been so excellent that the argument for not operating upon these patients is refuted.

Early and late results depend upon accuracy of the surgical correction of the lesion. The mitral valve must always be made competent to avoid early and late complications.

References

1. Frater, R. W. M.: Persistent Common Atrioventricular Canal: Anatomy and Function in Relation to Surgical Repair. *Circulation*, 32:120, 1965.
2. Gerbode, F.: Surgical Repair of Endocardial Cushion Defect. *Ann. Chir. Thorac. Cardio-Vasculaire*, 1:753, 1962.
3. Gerbode, F., Johnston, J. B., Robinson, S. J., Harkins, G. A. and Osborn, J. J.: Endocardial Cushion Defects: Diagnosis and Technique of Surgical Repair. *Surgery*, 49:69, 1961.
4. Gerbode, F. and Sabar, E. F.: Endocardial Cushion Defects. Diagnosis and Surgical Repair. *J. Cardio. Surg.*, 5:223, 1964.
5. Gerbode, F., Sabar, E. F. and Main, F. B.: Endocardial Cushion Defects. Diagnosis and Surgical Repair. *Bull. Intl. Chir.*, 23:446, 1964.
6. Lindesmith, G. G., Meyer, B. W., Chapman, N., Stanton, R. E. and Jones, J. C.: The Surgical Repair of Endocardial Cushion Defects. *Ann. Thor. Surg.*, 2:399, 1966.
7. Van Mierop, L. H. S., Alley, R. D., Kausel, R. D. and Stranahan, A.: The Anatomy and Embryology of Endocardial Cushion Defects. *J. Thorac. Cardio. Surg.*, 43:71, 1962.
8. Van Mierop, L. H. S. and Alley, R. D.: The Management of the Cleft Mitral Valve in Endocardial Cushion Defects. *Ann. Thorac. Surg.*, 2:416, 1966.
9. von Rokitansky, C.: Die Defecte der Scheidewände des Herzens: Pathologisch-Anatomische Abhandlung, Wien, W. Braumüller, 1875.
10. Wakai, C. S. and Edwards, J. E.: Pathologic Study of Persistent Common Atrioventricular Canal. *Amer. Heart J.*, 56:779, 1958.

DISCUSSION

DR. DWIGHT C. McGOON (Rochester, Minn.): Dr. Creech, Gentlemen: We have long looked to Dr. Gerbode for his descriptions of techniques and methods which have been valuable to us in adapting our own methods. In no areas have his results been more outstanding, in my opinion, than in this area of endocardial cushion defects.

Although we can compare our results reasonably favorably in the partial A-V canal group with his, so far as operative mortality is concerned, we, along with others, have noted a high incidence of residual mitral insufficiency following operation, using what I believe to be the same technique; so this is a question I would like to raise—why should this difference exist?

In the complete A-V canal group we have not been able to obtain the operative mortality rate which Dr. Gerbode has recorded. The three other groups, including our own, who reported results in this area in 1964 had a mortality rate which was nearly prohibitive, ranging from 63 to 75%. At that time Drs. Gerbode and Sabar reported one death in 13 such operations, if I interpret the data correctly.

Since 1964 we improved our results with a mortality rate in this period for the complete A-V canal of 25%; but still, taking the over-all results, ours are not really comparable to his, and one wonders again why this should be. I would ask him if he would have some trick or some lead to give us as to why this might be so different.

Since 1964 we have adopted a somewhat different technique for repairing the complete A-V canal. (Slide) Dr. Rastelli of our group has identified three different types of complete A-V canal. Fortunately, the most common is also the most ideal to repair, and in this situation the mitral portion of the leaflet is attached to the underlying

septum by means of chordae. We repaired these defects entirely through the atrium, having abandoned the separate ventriculotomy, and placed a pericardial or Teflon patch along the right aspect of the ventricular septum below, leaving all of the mitral tissue, or this common leaflet tissue, on the mitral side.

In closing, I would again like to ask Dr. Gerbode if he has any lead as to why we have residual mitral insufficiency in a high incidence in the partial A-V canal group, and why our mortality rates in the complete canal group have not totally approached his. Thank you. (Applause)

DR. DENTON A. COOLEY (Houston): Dr. Gerbode's results with surgical treatment of endocardial cushion defects have been better than ours. I suspect this may be due to a discrepancy in anatomic classification of the partial and complete types of A-V canal and to the large number of patients in our series less than 2 years of age who had severe or extensive canal defect.

During a 10-year period we operated upon 133 patients with endocardial cushion defects. Ninety-nine were partial canals (ostium primum with cleft mitral valve) with a 6% mortality. In 34 patients with a complete canal (atrioventricularis communis), surgical mortality was 56%. Mortality in patients less than 3 years of age was 91% and in those older than 3, it was 41%.

Because of our dissatisfaction with standard methods of surgical correction, we recently performed a more radical and definitive type of repair for complete A-V canal. The operation consists of excision of the remnants of mitral valve following which the atrioventricular septal defect is repaired with a Dacron patch and the mitral valve replaced by a low profile discoid prosthesis. The tricuspid valve is sutured when possible.