

---

# Complications of Venous Reconstruction in Human Orthotopic Liver Transplantation

---

JAN LERUT, M.D., ANDREAS G. TZAKIS, M.D., KLAUS BRON, M.D., ROBERT D. GORDON, M.D., SHUNZABURO IWATSUKI, M.D., CARLOS O. ESQUIVEL, M.D., PH.D., LEONARD MAKOWKA, M.D., PH.D., SATORU TODO, M.D., and THOMAS E. STARZL, M.D., PH.D.

---

In 313 consecutive recipients of 393 orthotopic liver grafts, there were 51 (16.3%) and nine (2.9%) patients who had pre-existing portal vein and inferior vena cava abnormalities, respectively. These abnormalities required adjustments in the transplant operation and were a source of morbidity and mortality. The incidence of thrombosis of the reconstructed portal vein was 1.8%. Only three (0.8%) vena caval thromboses were seen after 393 liver replacements. Venous stenoses or disruptions were rare. Six women with the Budd-Chiari syndrome had liver replacement. Although this disorder is a veno-occlusive disease, five of the recipients achieved prolonged survival, only one had recurrence of disease, and three are alive after 2-6 years.

**A**LTHOUGH THE RESULTS after orthotopic liver transplantation (OLT) have greatly improved in recent years,<sup>1-3</sup> about 10% of the grafts are still lost from technical surgical complications of which the majority are hepatic artery thromboses and problems with biliary tract reconstruction.<sup>1,4,5</sup> A smaller number of liver recipients have pre-existing or postoperative defects of the portal venous or vena caval system.<sup>1</sup>

We report the number, nature, treatment, and outcome of these venous complications in a series of 393 OLTs performed on 313 consecutive patients who were given new livers after the introduction in 1980 of cyclosporine-steroid therapy for immunosuppression. In addition, anomalies, congenital or acquired, of the vena cava, portal vein, and hepatic veins will be described as well as the technical modifications mandated by these anatomic variations.

---

Supported by Research Project Grant No. AM-29961 from the National Institutes of Health, Bethesda, Maryland.

Reprint requests: Thomas E. Starzl, M.D., Department of Surgery, University of Pittsburgh School of Medicine, 3601 5th Avenue, Pittsburgh, PA 15213.

Submitted for publication: October 3, 1986.

*From the Departments of Surgery and Radiology, University of Pittsburgh Health Center, University of Pittsburgh, and the Veterans Administration Medical Center, Pittsburgh, Pennsylvania*

---

## Methods and Materials

The 313 consecutive recipients were treated between March 1, 1980 and December 31, 1984. There were 177 adults and 136 children. Sixty-eight patients had a second transplantation during the same period, and 12 patients required a third graft. All patients were followed for at least 1 year after OLT or until death. There were 33 deaths within the first 3 months including 12 intraoperative or perioperative deaths. Thus, 280 (89.4%) patients lived for more than 3 months after operation.

Accounts have been published on the majority of these cases.<sup>1-3</sup> Immunosuppression was done with cyclosporine and steroids<sup>1,2</sup> to which polyclonal antilymphocyte globulin (ALG) was occasionally added until the autumn of 1983 for the control of intractable rejection. Since September 1984, monoclonal ALG (OKT3, Orthoclone®) has been used for the same purpose.<sup>6</sup> In a small number of patients, azathioprine was added to maintenance therapy of cyclosporine and prednisone.

In the following account, emphasis will be placed on details of donor and recipient management that had obvious or potential implications for the venous reconstructions that are part of OLT.

### *Recipient Workup*

Ultrasound examination of the recipient portal vein and inferior vena cava was routinely performed. In the event of ambiguous findings, or if it was believed that thrombosis of the portal vein had occurred, visualization

of the vessel often was attempted with mesenteric angiography or by transhepatic catheterization of the portal vein. The inferior vena cava occasionally was studied by inferior vena cavography.

#### *Donor Operation*

The donor hepatectomies were part of a multiple organ procurement procedure previously described.<sup>7</sup> Cannulas that were used to infuse fluid into the portal vein were placed distally so the plastic material was not in contact with vein wall to be left in the recipient. Any abnormalities of the venous system were noted. At the end of the donor operation, free iliac arterial and venous grafts were always obtained<sup>7</sup> in case they were needed for the recipient operation. Often, grafts of the inferior vena cava and abdominal and/or thoracic aorta were also removed and stored in standard tissue culture medium.

No effort was made to clean the liver graft perfectly during the donor operation. This work, including cleaning of the hepatic artery and portal vein and development of the venous anastomotic cuffs for their anastomoses, was done at the back table after the liver had been brought to the recipient operating room.

#### *Recipient Operation*

During the time when the diseased liver is being removed and while the liver graft is being sewn into place, the portal vein and inferior vena cava must be obstructed. Since February 1983, a nonheparin pump-driven venovenous bypass has been used systematically in adults and in selected children to decompress the occluded venous pools.<sup>8-10</sup> Entry into the splanchnic venous system is with a plastic cannula inserted through the transected recipient portal vein. Entry into the inferior vena caval system is *via* a cannula inserted through the saphenous vein into the iliac venous system or distal inferior vena cava. The venous blood collected through these cannulas is pumped into the upper half of the body through a cannula inserted into the central axillary vein.

The details of hepatectomy and of vascular reconstruction have been thoroughly described.<sup>11,12</sup> The native and grafted livers include a segment of the inferior vena cava from above the renal veins to the diaphragm. This segment removed with the native liver is replaced with the vena cava that comes with the liver graft. A cuff of the transected recipient vena cava at the diaphragm is fashioned by joining the vena cava and the main hepatic veins into a cloaca.<sup>11</sup> In patients with cirrhosis, the hepatic veins may be drawn by fibrosis into the liver or into the diaphragm necessitating closure of one of the hepatic veins to obtain adequate cuff length. The backwall of both the upper and

lower vena cava anastomoses must be sutured with an intraluminal technique.<sup>11,12</sup>

One of the most disastrous mistakes that can be made in liver transplantation is to begin to sew the new liver in without having prepared adequate venous cuffs. With the venovenous bypass in place, it is possible to fashion vena caval cuffs and to skeletonize an adequate length of the portal vein while the bypass is functioning. If the transected portal vein contains new or old thrombus, it is necessary to consider a single venovenous bypass from the systemic system to the axillary vein. The penalty for using a splanchnic venous bypass in the presence of a portal thrombosis may be the propagation of a lethal pulmonary embolus through the bypass system.

If the portal vein has a major old thrombus, the most drastic resolution has been to dissect back the abnormal vessel to the junction of the splenic and superior mesenteric veins, to anastomose a free iliac vein graft from the donor onto the confluence of these tributaries, and to anastomose the portal vein of the new liver to the iliac vein graft.<sup>13,14</sup>

Great attention is paid to avoiding vascular anastomotic strictures, particularly of the portal vein and hepatic artery. Special techniques are used that leave extra Prolene® suture material where the knots are tied so that the suture material can work its way back into the anastomosis after the vessels have been opened. This has been called the "growth factor technique" and it is particularly important with the small vessels of pediatric grafts and recipients.<sup>15</sup>

#### *Retransplantation*

When retransplantation becomes necessary, the operation is greatly simplified if vascular cuffs from the first graft can be retained. A suprahepatic venous graft is almost always left in place,<sup>11</sup> and less commonly, a piece of infrahepatic vena cava from the first graft is retained. A graft of a previously placed portal vein was left behind in only nine of the 80 retransplantations, and an arterial remnant was used only three times.

The foregoing techniques required modification in the event of anatomic abnormalities or variations.

### **Results**

#### *Pre-existing Abnormalities of the Inferior Vena Cava*

Nine (2.9%) of the 313 recipients had pre-existing abnormalities of the inferior vena cava. Five were children with biliary atresia (Table 1). In two of the five recipients, the inferior vena cava between the renal vein and the diaphragm was absent, and the main hepatic veins of the diseased liver emptied into a cloaca that communicated

TABLE 1. Pre-existing Inferior Vena Caval Abnormalities in Nine (2.9%) of 313 Recipients (1980-1984)

Description of Abnormality	Liver Disease	No. of Patients	Technical Adjustment(s)
Absent retrohepatic IVC (Fig. 1A)	Biliary atresia	2	Suprahepatic graft IVC anastomosis to recipient hepatic vein cloaca or right atrium; ligation infrahepatic IVC of graft (Fig. 1C)
Extrahepatic IVC; main hepatic veins into cloaca (Fig. 1B)	Biliary atresia	2	Upper graft IVC anastomosis to hepatic vein cloaca; ligation infrahepatic IVC of graft (Fig. 1D)
Absent superior vena cava; innominate vein drainage to IVC (Fig. 1E)	Biliary atresia	1	Anomaly not recognized; brain death resulted from innominate hypertension during IVC occlusion of anhepatic period
Thrombosis IVC	Budd-Chiari syndrome	2	Thrombectomy IVC, in one case including renal, iliac, and femoral veins
Aneurysm IVC	After portal systemic shunt	2	Conventional IVC anastomoses with adjustment for size discrepancy; shunt taken down

IVC = inferior vena cava.

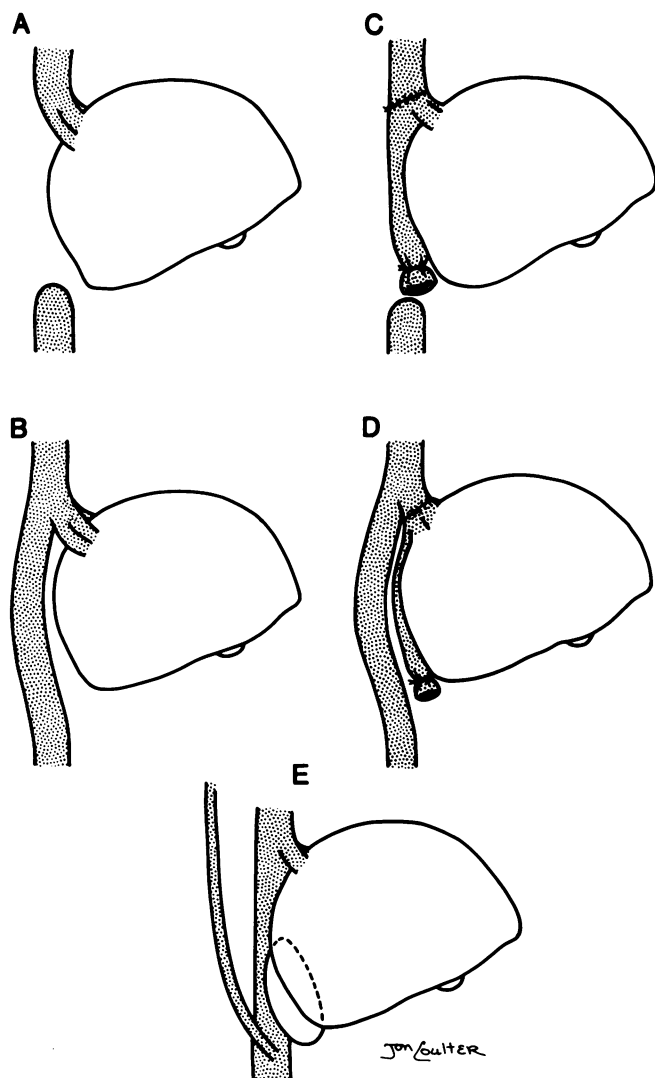


FIG. 1. Abnormalities of the inferior vena cava (IVC) in children with biliary atresia. A. Absent retrohepatic IVC. B. Separated retrohepatic IVC. C. Technical adjustment for A. D. Technical adjustment for B. E. Anomalous drainage of innominate veins into the IVC (see text).

directly with the right atrium (Fig. 1A). In two other children with biliary atresia, the retrohepatic inferior vena cava was present, but it was completely separate from the liver and its upper end received a cloaca into which all of the hepatic veins emptied (Fig. 1B). In all four children, the upper vena cava cuff of the homograft was sutured to the hepatic vein cloaca, and the lower vena cava cuff of the graft was tied off or oversewn<sup>11</sup> (Figs. 1C and D). Thus, the recipient operation was actually simpler than usual. There were no subsequent complications. Three of these four children also had hypoplasia or early extrahepatic bifurcation of the recipient portal vein (see later).

A fifth child with biliary atresia was discovered at autopsy to have an absent superior vena cava with drainage of both innominate veins into the inferior vena cava below the renal veins (Fig. 1E). During the anhepatic phase when the inferior vena cava was cross-clamped for about 40 minutes, extreme venous hypertension in the craniofacial area developed, which caused irreversible brain damage and death 2 days later.

In four adult patients (Table 1), there were two examples each of inferior vena caval thrombosis and aneurysmal dilatation. The thromboses, which in one patient extended to the renal, iliac, and femoral veins, were in patients with Budd-Chiari syndrome and were removed by thrombectomy at the time of the transplantation. Both women also had fresh thrombi in the portal vein. Venovenous bypass could not be used in either patient because of fear of pumping emboli to the lungs. There were no complications after transplantation. Both recipients were placed on chronic anticoagulant therapy.

The two adults with aneurysmal dilatation of the inferior vena cava had undergone previous portal systemic shunting. It was necessary to accept and correct 2:1 and 3:1 size disparities in the lower vena caval anastomoses, but the results were satisfactory. The pre-existing portal systemic shunts were taken down.

TABLE 2. Portal Vein Abnormalities in 51 (16.3%) of 313 Recipients (1980–1984)

	No. of Patients	Principal Association(s)	Technical Adjustment(s)
Thrombosis	22	9 none; 9 previous shunt or other hilar operation; 2 Budd-Chiari; 2 tumor	Thrombectomy; dissection to SV-SMV confluence; iliac vein or pulmonary artery graft to add length
Hypoplasia	20	14 biliary atresia*; 5 cirrhosis; one sclerosing cholangitis	Dissection to SV-SMV confluence; vein graft sometimes
Phleboscrosis	8	4 previous shunt or other hilar operation; 4 unknown	Dissection to SV-SMV confluence; vein graft sometimes
Absent portal vein	1	Biliary atresia; previous hilar dissection	Portacaval transposition

\* One patient also had very low bifurcation to right and left portal branches.

SV = splenic vein.  
SMV = superior mesenteric vein.

### Abnormalities of the Portal Vein

Surgically significant abnormalities of the recipient portal vein were present in 51 (16.3%) of the 313 recipients. The most frequent and most serious condition was portal vein thrombosis (Table 2). A reason for the thrombosis was not obvious in nine patients, but in nine others there had been previous hilar dissections or attempts to control portal hypertension with portal-systemic shunts, splenectomy, or operations to interrupt venous collaterals. In one patient (Fig. 2), the portal vein had been tied off during hepatic lobectomy. Two patients with Budd-Chiari syndrome had relatively fresh thrombi that could be extracted easily, and there were two examples of tumor thrombi from hepatomas.

Portal vein hypoplasia was found in 20 recipients of whom 14 had the diagnosis of biliary atresia with at least one previous attempt at portoenterostomy (Table 2). Hypoplasia was defined in pediatric patients by a portal vein diameter after full dissection of less than 3.5 mm (Fig. 3). It was suspected that the development of collaterals in the adhesions that resulted from portoenterostomy increased the "steal" of venous blood from the splanchnic bed, thereby promoting the involution of the portal vein in the hilum. The combined incidence of portal venous or vena caval abnormalities, or both, was 17 (23.3%) of 72 children with biliary atresia.

The other common portal venous abnormality was sclerosis (Table 2). This was a feature of the portal veins of patients who had previously undergone portal-systemic shunts, but it also was seen in previously unoperated recipients. In two patients in whom an end-to-side portacaval shunt was taken down during transplantation, the calcium-containing wall of the sclerotic portal vein could not be sutured because of its fragility, and both patients bled to death in the operating room.

The technical adjustments required by portal vein abnormalities included thrombectomy or retrograde dissection of the abnormal portal vein to the confluence of the splenic and superior mesenteric veins. Usually, the portal vein of the liver graft could be anastomosed to this confluence, but in nine patients, a free graft of donor iliac

vein, pulmonary artery, or inferior vena cava was used to add length (Fig. 4). None of these grafts have failed to our knowledge.

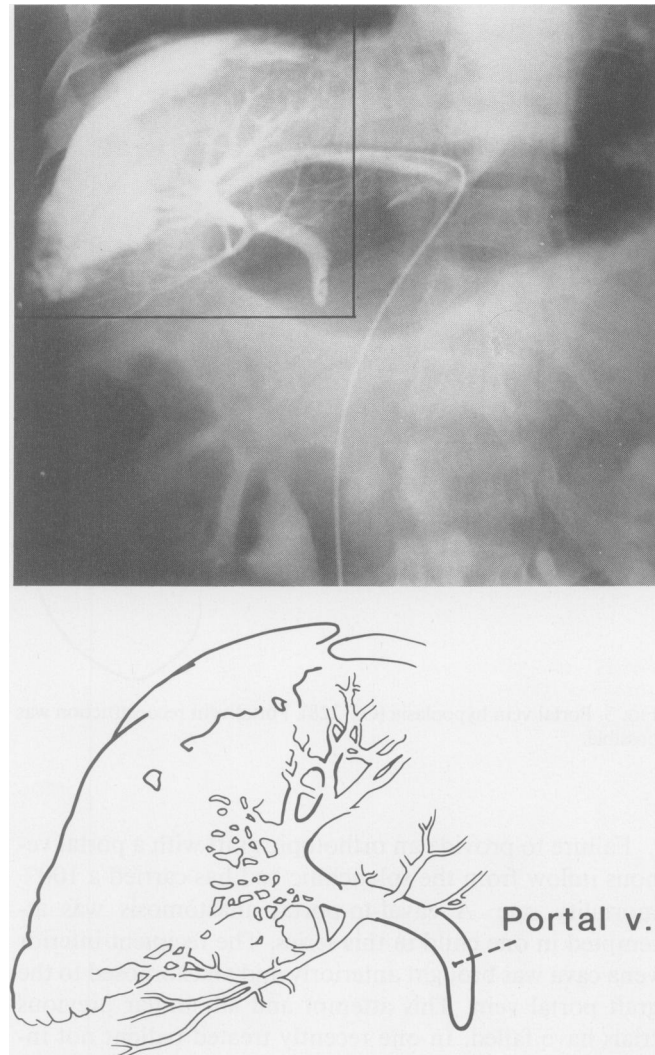


FIG. 2. Demonstration by transhepatic portography and enlarged schematic representation of complete portal vein occlusion (OT 288). The portal vein had been tied off months previously during hepatic lobectomy. The reconstruction at the time of transplantation is shown in Figure 4.

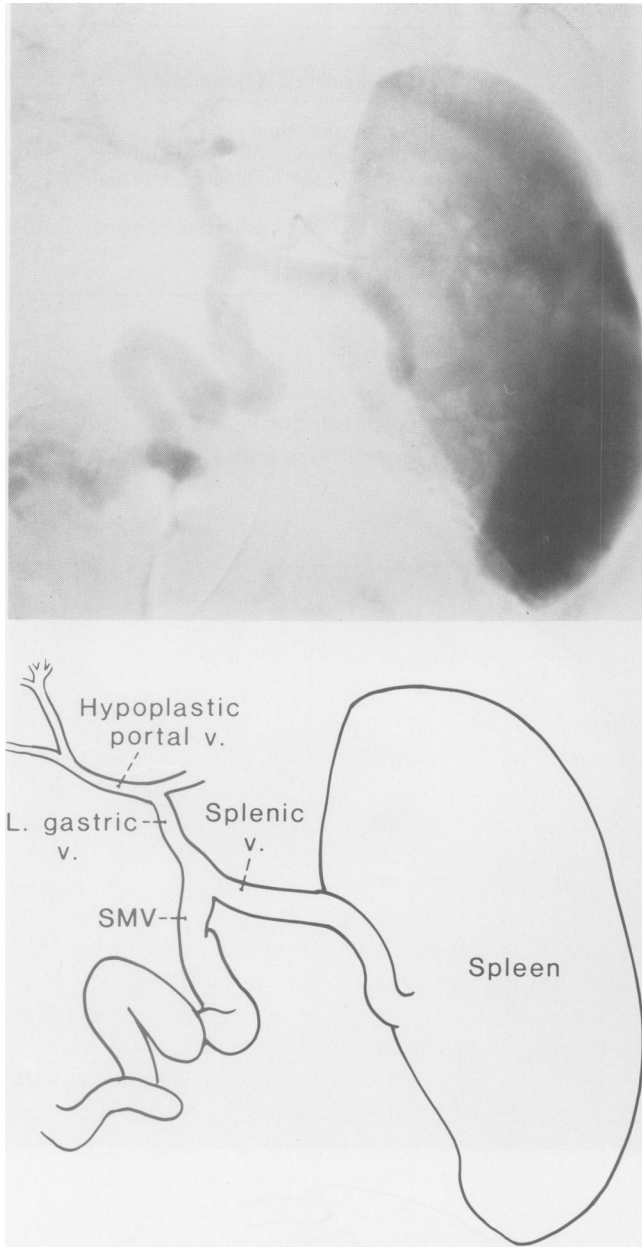


FIG. 3. Portal vein hypoplasia (OT 228). Portal vein reconstruction was possible.

Failure to provide an orthotopic graft with a portal venous inflow from the splanchnic bed has carried a 100% mortality rate. A caval-to-portal anastomosis was attempted in one child in this series. The recipient inferior vena cava was brought anteriorly and anastomosed to the graft portal vein. This attempt and all similar previous trials have failed. In one recently treated patient not included in this series, a long iliac vein graft was anastomosed to the superior mesenteric vein well below the transverse mesocolon, brought up into the hilum behind

the neck of the pancreas, and successfully anastomosed to the portal vein of the transplanted liver.

The jeopardy in which previous operations can place the liver transplant recipient has been well recognized.<sup>1</sup> The adverse influence of procedures used to treat portal hypertension is seen in Table 3. Twenty-one (6.7%) of the 313 recipients had undergone a portal-systemic shunt or splenectomy. In 14 of the 21 recipients, the portal vein was not normal at the time of transplantation, and in seven of these, the portal vein was thrombosed or absent. The technical adjustments made at the time of transplantation were not successful in six of the 14 patients (Table 3).

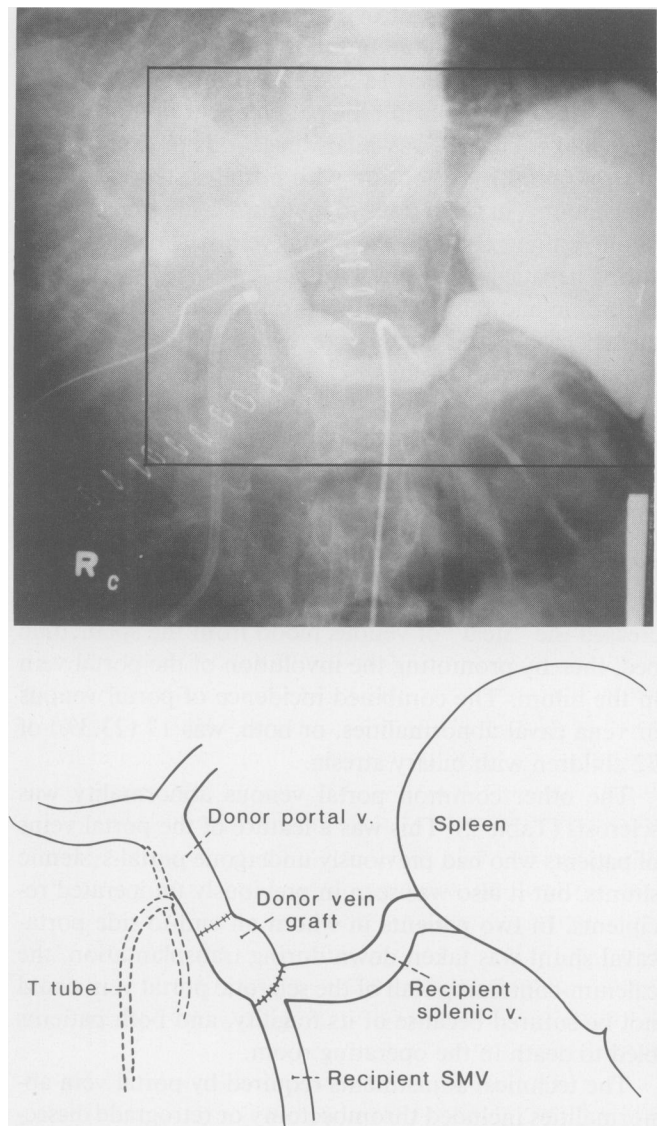


FIG. 4. Selective angiography after transplantation confirms the patency of a venous vessel graft used for the patient depicted in Figure 2 (OT 288). The recipient is well after 4 years.

TABLE 3. Relation between Previous Operations on the Splanchnic Circulation and Portal Vein Complications

Type of Operation	No. of Patients	Abnormal Portal Vein at OLT	Technical Solution	Outcome
Portacaval shunt	7	3 thrombosed	Thrombectomy	1 completely successful; 2 thrombosed but survived (Table 4)
Central splenorenal shunt	2	2 sclerotic	No solution	2 died of bleeding
Mesocaval shunt	3	2 small	Shunts ligated	2 survived
Splenectomy	9	2 small	2 shunts ligated; 1 had thrombosed	2 survived
		3 thrombosed	Thrombectomy and dissection to confluence of SV-SMV	1 died late thrombosis
		1 sclerotic	Dissection to confluence	1 survived
		1 absent	Portacaval transposition	Died, no hepatic function
Total	21	14		

OLT = orthotopic liver transplantation.  
SV = splenic vein.

SMV = superior mesenteric vein.

Shunts located at a distance from the hilum (splenorenal and mesocaval) caused less intraoperative danger and were taken down to ensure optimal blood supply to the liver (Table 3).

#### Portal Vein Thrombosis

A portal vein thrombosis developed after operation in seven (2.2%) of the 313 patients. The incidence relative to the 393 grafts was 1.8%.

The pertinent features of the seven patients are shown in Table 4. Four of the seven recipients had a satisfactory early convalescence. The diagnosis was suspected or made when evidence of portal hypertension developed, including variceal hemorrhage, persistence of esophageal varices on a barium swallow, and splenomegaly and hypersplenism.

Portal flow was restored in only one of these four patients 8 months after transplantation. A high-grade stenosis developed at the anastomosis in this patient (OT 193) (Fig. 5). The portal vein thrombosed completely during the next few days. She had thrombectomy and reperformance of the portal vein anastomosis (Fig. 6). At this extraordinarily difficult operation, a partial biliary tract obstruction was also relieved. In a second patient, the esophageal varices were controlled with sclerotherapy alone (OT 226). In another recipient (Fig. 7), a distal splenorenal shunt became necessary because of recurrent hemorrhage 20 months after liver transplantation. In the latter two patients, the hilar portal vein of the graft has been revascularized by venous collaterals so that there was a high volume of residual hepatopetal flow (Fig. 7, bottom).

The four patients whose early course was considered satisfactory had a pre-existing and unrecognized throm-

bosis of the portal vein, splenic vein, and superior mesenteric vein. At the time of transplantation, thrombectomy of the superior mesenteric vein was possible, but by the time angiography was performed 2 weeks later, the lumen was greatly attenuated in size, and much of the splanchnic flow was going through gastroesophageal collaterals (Fig. 8). When the patient died 14 months later, the portal vein and the superior mesenteric vein had clotted.

The other three patients were desperately ill after operation. Acute liver failure developed in two patients (OT 259 and 273) and they were submitted to retransplantation; one patient survived. The third patient (OT 214) had retransplantation after chronic rejection of his first graft. At the time of the transplantation, there was a major size disparity between the donor and recipient, so great that the abdomen could not be closed. A Silastic® bag was placed over the wound temporarily, and closure affected 2 days later. The reconstructed portal vein may have been buckled at that time. It was thrombosed 2 months later at the time of autopsy.

Four of the seven patients whose portal veins clotted are still alive, 3–5 years later; three patients have their original grafts and one patient was rescued with retransplantation (Table 4).

#### Vena Caval Thrombosis

There were three postoperative inferior vena caval thromboses, all originating at the lower vena caval anastomosis. The only survivor was the child whose portal vein was also clotted and who had prompt retransplantation (Table 4). A second child died almost 4 months after transplantation with slowly declining liver function beginning 1 month after operation. This child had a car-

TABLE 4. Postoperative Portal Vein and Inferior Vena Caval Thromboses after 393 OLTs in 313 Patients

OLT#	Diagnosis	Age (Years)	Contributing Factor(s)	Manifestation	Diagnosis Confirmed	Liver Function with Complication	Outcome
<b>Portal Vein Thrombosis</b>							
193	Congenital cholestasis	9 <sup>10</sup> / <sub>12</sub>	Not obvious	Esophageal variceal bleeds 7 months after operation; hypersplenism	Transhepatic portography	Good	Portal anastomosis revised 8 months, well 4- <sup>3</sup> / <sub>4</sub> years
214b	Alagilles syndrome	3	First graft rejected; donor too big at retransplantation	Not suspected	Autopsy	Poor	Died 59 days of pneumonia and liver failure
218	Glycogen storage disease I	17	End-to-side portacaval shunt 9 years earlier	Variceal hemorrhage several months after OLT	Angiography	Good	Treated with sclerotherapy; distal splenorenal shunt after 20 months; well 4.25 years
226	Alpha-1-antitrypsin deficiency	3.5	Portal thrombectomy and end-to-side portacaval shunt 8 days earlier	Persistent esophageal varices	Angiography	Good	Treated with sclerotherapy; well 4 years
259	Biliary atresia	3.5	Portal vein hypoplasia	Liver failure	At retransplantation	Poor	Retransplantation after 13 days; died 23 days
273	Alpha-1-antitrypsin deficiency	2.5	None obvious	Variceal Hemorrhage at day 2; liver failure	Ultrasound, angiography, and retransplantation	Poor	Retransplantation at day 9, well 3- <sup>1</sup> / <sub>2</sub> years
403	Sclerosing cholangitis	37	Previous splenectomy; thrombosis portal, splenic, and superior mesenteric veins at transplant thrombectomy	Variceal hemorrhage from day 25 on	Angiography after 3 weeks, autopsy	Good	Treated with sclerotherapy. Died after 14 months from acute liver failure and GI bleeding
<b>Inferior Vena Cava Thrombosis</b>							
216	Biliary atresia	2 <sup>7</sup> / <sub>12</sub>	Cardiac arrest during perforation of lower caval anastomosis	Not suspected	Autopsy	Poor	Died after 110 days of liver failure and sepsis
273	(See #273 above)		—	—	Ultrasound, angiography, and retransplantation	Poor	Retransplantation at day 9, well 3- <sup>1</sup> / <sub>2</sub> years
434b	Chronic active hepatitis	17	Poor operation	Hepatic and renal failure; swelling lower legs	At retransplantation	Poor	Retransplantation after 4 days; thrombectomy inferior vena cava and left renal vein. Died 9 days later



diac arrest during performance of the lower vena caval anastomosis, and the suturing had been completed with the utmost dispatch under bad circumstances. The third patient had had multiple technical complications during a very difficult operation (Table 4).

*Portal Vein Pseudostenosis*

A 5-year-old boy (OT 286) had stenosis of the portal vein. His liver had been severely injured during procurement and preservation with a serum oxaloacetic transaminase level that rose to 10,000 IU on the first postoperative day. He required ventilatory support for 12 post-

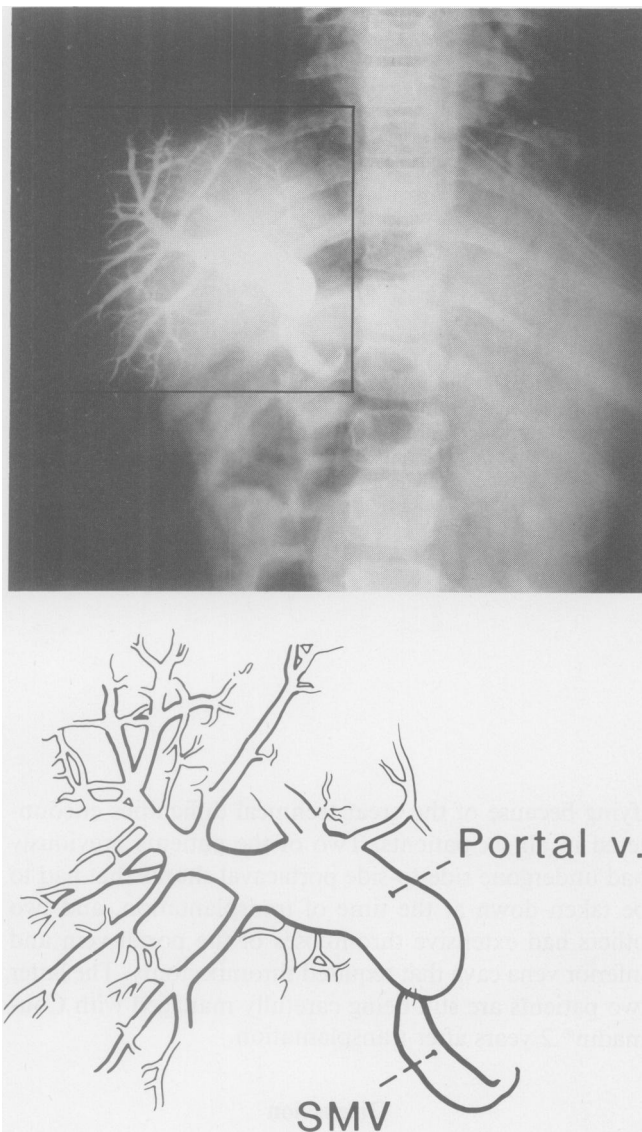


FIG. 5. Stenosis of the portal anastomosis diagnosed by transhepatic portography.

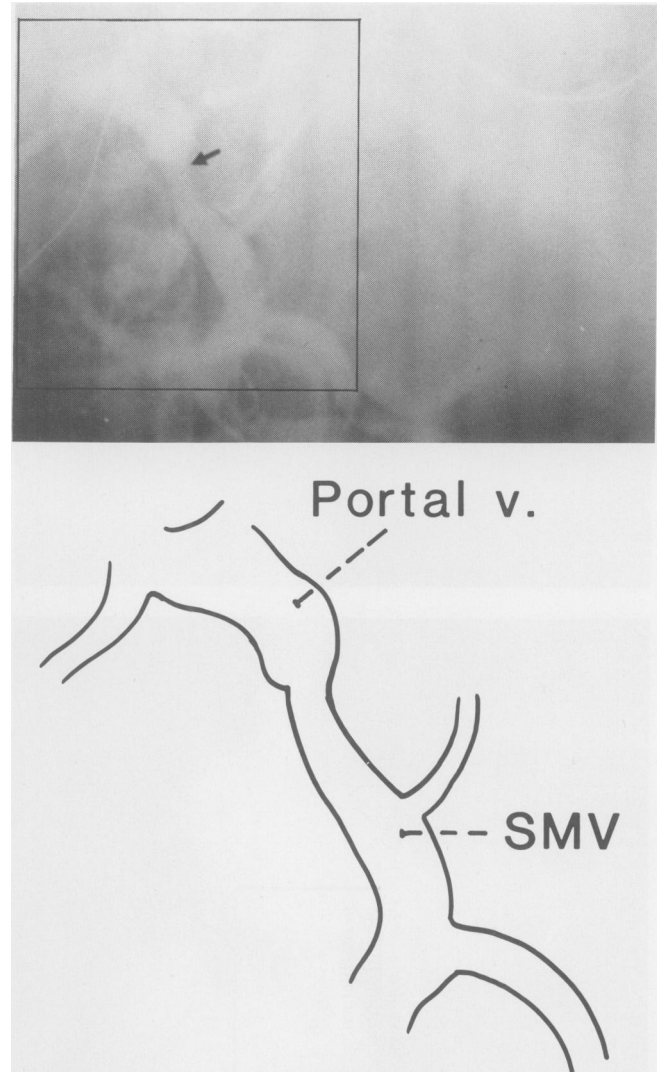


FIG. 6. Treatment of the lesion shown in Figure 5 by resection of the stenosis, thrombectomy, and re-anastomosis (OLT 193). The patient is alive 5 years later.

operative weeks. After recovering, angiography was obtained that seemed to show a high-grade stenosis at the portal vein anastomosis. A decision was made to defer reoperation, and 3 months later, repeat angiography showed a normal reconstructed portal vein. Three other examples of pseudostenosis have been seen, apparently because of anastomosis of smaller hypoplastic recipient portal veins to larger donor portal veins.

*Portal Vein Disruption*

A 47-year-old woman had disruption of a choledoch-choledochostomy. The biliary fistula eroded the anterior wall of the portal vein anastomosis 2 weeks later causing a fatal hemorrhage.



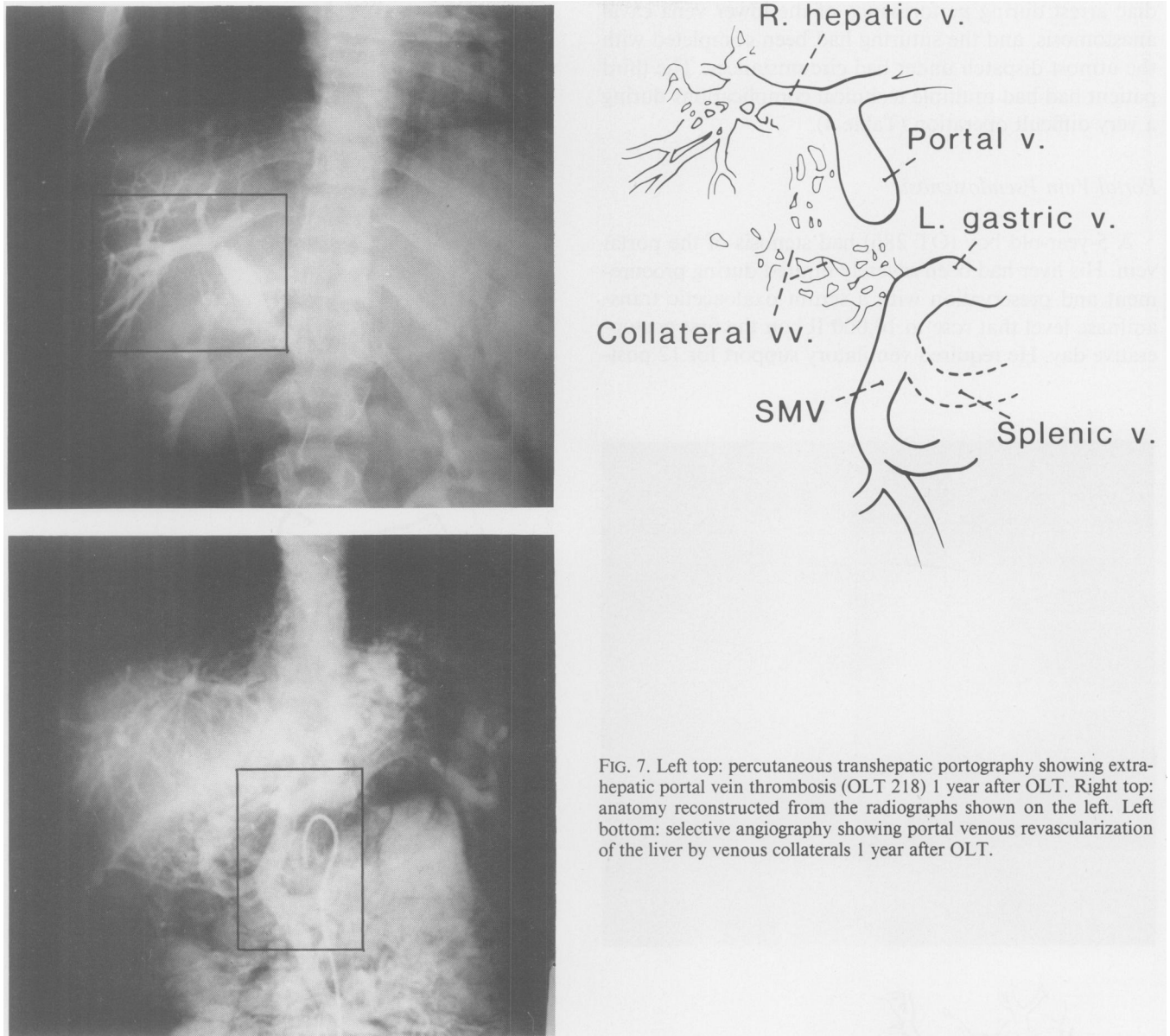


FIG. 7. Left top: percutaneous transhepatic portography showing extrahepatic portal vein thrombosis (OLT 218) 1 year after OLT. Right top: anatomy reconstructed from the radiographs shown on the left. Left bottom: selective angiography showing portal venous revascularization of the liver by venous collaterals 1 year after OLT.

### *The Budd-Chiari Syndrome*

The six women with this diagnosis were 16–40 years old (mean:  $26.1 \pm 8.9$  years SD). One patient died of infection 24 days after operation; but the other five patients had prolonged survival. One patient died at 452 days of recurrent Budd-Chiari syndrome after anticoagulant therapy was discontinued in preparation for a closed liver biopsy<sup>16</sup>; another death after 20 months was of a teenaged girl a few days after retransplantation for chronic rejection.

The other three patients are alive after 2, 2, and 6 years, respectively. The survival of half of the patients was grat-

ifying because of the great technical difficulties encountered in all six patients. Two of the patients previously had undergone side-to-side portacaval shunts that had to be taken down at the time of transplantation, and two others had extensive thromboses of the portal vein and inferior vena cava that required thrombectomy. The latter two patients are still being carefully managed with Coumadin® 2 years after transplantation.

### **Discussion**

Most surgeons practicing today, and even those who are still young, will remember the pessimism with which

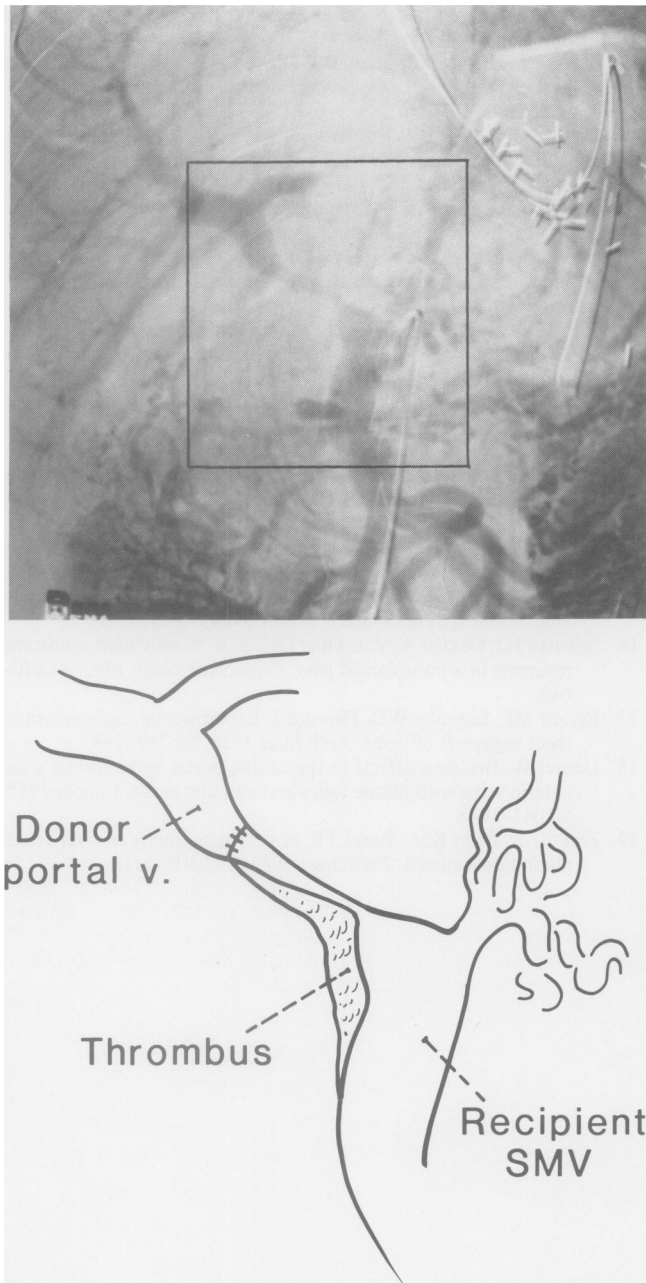


FIG. 8. Severe stenosis of the mesenteric vein and important gastroesophageal collaterals at selective angiography 3 weeks after OLT (OT 403). At the time of transplantation, phlebothrombectomy of the splenomesenteric confluence had to be performed.

grafting of the portal vein or inferior vena cava was viewed, whether using natural vessels or prostheses.<sup>17,18</sup> The doctrine that such grafts would easily clot was so pervasive that the venous system of hepatic homografts was seen by many early workers as the most important potential technical problem with liver replacement. Such concerns have become increasingly remote with the lack of venous complications in chronically surviving animals after liver

replacement<sup>11</sup> and now with confirmatory human experience.

In humans, thrombosis of either the portal vein or inferior vena cava after liver replacement has been almost exclusively seen in pediatric recipients, and even in the smallest of these patients, thrombotic venous problems have been unusual. This low incidence has been all the more remarkable because of the common presence of factors that could have, and possibly should have, predisposed to venous thrombosis. About one in six of the liver recipients has had an abnormal portal vein or vena cava to which the vessels of the new liver had to be anastomosed, and in children with biliary atresia, the incidence of these dangerous situations has been one in four.

Solutions to the pre-existing anatomic problems required a number of variations from the standard operation. The variations included the liberal use of free vein grafts in the portal system; none of these grafts are known to have clotted. In fact, the use of such free grafts would seem to be preferable in many situations to thrombectomy or other expedients in which a perfect technical result cannot be obtained.

Finally, the success obtained with the Budd-Chiari syndrome, a disorder caused by perturbations of coagulation, is worth noting. Although one of the six recipients with this disease died early after operation of acute rejection, the other five had long survival without recurrent disease. In one of these patients whose chronic anticoagulant therapy was unwisely stopped more than a year after operation, a lethal recurrence then developed.<sup>16</sup>

It could be speculated that the small number of graft thromboses reported here is only the visible part of a true incidence from which silent thromboses have been excluded. The argument could follow that the remarkably effective revascularization of the liver with collaterals after portal vein thrombosis documented in two of our patients could explain the retention of good liver perfusion and the preservation of hepatic function in other patients in whom the complication has not been diagnosed.

However, there would be little justification for such a conclusion since real time ultrasonography has allowed discriminating study of all of the vascular structures of the graft in a noninvasive way. In our center, ultrasonography is used repeatedly during the early convalescence to check the state of the various vessels, and it has become part of the late follow-up care. The increased use of the imaging techniques has been part of the background that has made liver transplantation increasingly practical.<sup>19</sup>

In the years ahead, the growth of the portal and vena caval systems of our many pediatric recipients will be exceptionally interesting to watch. A special technique has been used for all venous anastomoses, whereby slack is left in the Prolene suture used for the continuous anas-

tomoses.<sup>15</sup> This excess Prolene, euphemistically called a "growth factor," can be drawn slowly into an expanding anastomosis, keeping pace with growth needs. This was particularly well seen in one of our patients whose pseudostricture at a portal venous anastomosis disappeared completely over a period of months at the same time as the disparity in donor and recipient vessel size corrected itself. This kind of adjustment is especially important in children with biliary atresia in whom a hypoplastic portal vein is the single most common pre-existing abnormality. The hypoplasia is probably due to shunting of blood away from the portal vein *via* collaterals established in the adhesions caused by portoenterostomy at an earlier age.

### References

1. Starzl TE, Iwatsuki S, Van Thiel DH, et al. Evolution of liver transplantation. *Hepatology* 1982; 2:614-636.
2. Starzl TE, Iwatsuki S, Shaw BW Jr, Gordon RD. Orthotopic liver transplantation in 1984. *Transplant Proc* 1985; 17:250-258.
3. Starzl TE, Iwatsuki S, Shaw BW Jr, et al. Immunosuppression and other nonsurgical factors in the improved results of liver transplantation. *Sem Liver Dis* 1985; 5:334-343.
4. Tzakis AG, Gordon RD, Shaw BW Jr, et al. Clinical presentation of hepatic artery thrombosis after liver transplantation in the cyclosporine era. *Transplantation* 1986; 40:667-671.
5. Iwatsuki S, Shaw BW Jr, Starzl TE. Biliary tract complications in liver transplantation under cyclosporine-steroid therapy. *Transplant Proc* 1983; 15:1288-1291.
6. Fung JJ, Demetris AJ, Porter KA, et al. Use of OKT3 with cyclosporine and steroids for reversal of acute kidney and liver allograft rejection. *Nephron* (In press).
7. Starzl TE, Hakala TR, Shaw BW JR, et al. A flexible procedure for multiple cadaveric organ procurement. *Surg Gynecol Obstet* 1984; 158:223-230.
8. Griffith BP, Shaw BW Jr, Hardesty RL, et al. Venovenous bypass without systemic anticoagulation for transplantation of the human liver. *Surg Gynecol Obstet* 1985; 160:270-272.
9. Shaw BW Jr, Martin DJ, Marquez JM, et al. Venous bypass in clinical liver transplantation. *Ann Surg* 1984; 200:524-534.
10. Kam I, Lynch S, Todo S, et al. Low flow venovenous bypasses in small animals and pediatric patients undergoing liver replacement. *Surg Gynecol Obstet* 1986; 163:33-36.
11. Starzl TE (with the assistance of Putnam CW). Experience in Hepatic Transplantation. Philadelphia: W. B. Saunders Co, 1969; 112-144; 203-206, 303-305.
12. Starzl TE, Iwatsuki S, Esquivel CO, et al. Refinements in the surgical technique of liver transplantation. *Sem Liver Dis* 1985; 5:349-356.
13. Starzl TE, Halgrimson CG, Koep LJ, et al. Vascular homografts from cadaveric organ donors. *Surg Gynecol Obstet* 1979; 149:737.
14. Shaw BW Jr, Iwatsuki S, Bron K, Starzl TE. Portal vein grafts in hepatic transplantation. *Surg Gynecol Obstet* 1985; 161:66-68.
15. Starzl TE, Iwatsuki S, Shaw BW Jr. A "growth factor" in fine vascular anastomoses. *Surg Gynecol Obstet* 1984; 159:164-165.
16. Seltman HJ, Dekker A, Van Thiel DH, et al. Budd-Chiari syndrome recurring in a transplanted liver. *Gastroenterology* 1983; 84:640-643.
17. Bryant MF, Lazenby WD, Howard J. Experimental replacement of short segments of veins. *Arch Surg* 1958; 76:289-293.
18. Daurel W. Bridging defects in the canine portal and superior mesenteric veins with plastic tubes and vascular grafts. *Cancer* 1952; 5:1041-1048.
19. Zajko AB, Bron KM, Starzl TE, et al. Angiography of liver transplantation patients. *Radiology* 1985; 157:305-311.