

## SHORT REPORTS

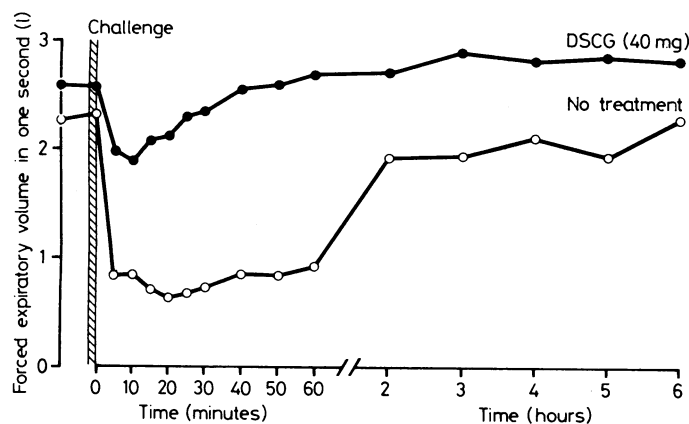
### Occupational asthma caused by allergy to pigs' urine

We report a case of asthma due to occupational exposure to pigs. The cause of the symptoms was exposure to the urine of the animals. This was proved by provoking acute asthma with an inhalation challenge of an extract of pigs' urine at a concentration of 1 g/l. On a second occasion this asthmatic response was blocked by prior treatment with 40 mg sodium cromoglycate (Intal). The patient's serum contained specific IgE antibody to the urine extract which was not found in unexposed controls.

#### Case report

The patient, a 21-year-old eczematous woman who enjoyed a vigorous sporting life, playing squash and hockey to a high standard, had not suffered respiratory symptoms since the age of 3. During her second year at university studying agricultural sciences her class visited a pig house. Within two to three minutes she had to leave because she felt as if she was being "stifled with a plastic bag." She took about an hour to recover her breath and within a few minutes her eczema had begun to itch, and this took a further two hours to settle. One year later, within five minutes after starting to watch a laparotomy on a pig, she again became short of breath. Her only other exposure to these animals had been during a visit to the pig house in her first year, when she remained symptomless.

Skin-prick tests yielded positive reactions to grass, house-dust mite, horse, cat, dog, and pork extract. Pigs' urine (50 ml) was filtered, sterilised, and freeze dried as described<sup>1</sup> and reconstituted in Coca's solution at 0.1 and 1.0 g/l. Skin testing produced a 3 mm weal with the solution at 1.0 g/l. After inhaling a nebulised dose (0.0015 g) for one minute her forced expiratory volume in one second (Vitalograph) fell by 70% from 2.3 to 0.7 l. The same test was conducted one week later after 40 mg of sodium cromoglycate had been given by inhalation 10 minutes before the challenge. On this occasion her forced expiratory volume in one second fell by nearly 28% from 2.5 to 1.8 l. In each case recordings were made for a further five hours throughout



Results of two inhalation tests performed one week apart. On each occasion subject inhaled nebulised pigs' urine 1 g/l for 60 seconds. Asthmatic response was inhibited with sodium cromoglycate (DSCG) 40 mg given 10 minutes before test.

the day. No non-immediate reaction developed (figure). A radioallergosorbent test performed with the same urine extract showed her blood to contain specific IgE antibody, 23.9% of the counts added in the assay being bound, as compared with 0.73% with cord blood and a mean of 0.69% with six blood-bank controls.

#### Comment

Asthma has resulted from inhaling certain proteins in the urine of mice, rats, guinea-pigs, and rabbits in sensitised subjects but not from inhaling the animal serum.<sup>1,2</sup> Our patient's sensitivity to pigs' urine raises the possibility that urine of other mammals may also cause asthmatic symptoms. Previous studies have shown that atopic people are more at risk of developing asthma from exposure to environmental antigens than non-atopic persons.<sup>3</sup> Our patient was highly atopic and eczematous.

We thank Professor M Lessof for permission to investigate this patient and Dr D S Fernando for referring her.

- 1 Harries MG, Burge PS, O'Brien IM. Occupational type bronchial provocation tests. Part 1: testing with soluble antigens given by inhalation. *Br J Ind Med* 1980;37:248-51.
- 2 Newman-Taylor AJ, Longbottom JL, Pepys J. Respiratory allergy to urine proteins of rats and mice. *Lancet* 1977;ii:847-9.
- 3 Burge PS, Edge G, O'Brien IM, Harries MG, Hawkins R, Pepys J. Occupational asthma in a research centre breeding locusts. *Clin Allergy* 1980;10:355-9.

(Accepted 30 November 1981)

Department of Medicine, Guy's Hospital, London SE1 9RT  
M G HARRIES, MRCP, lecturer in medicine

Department of Allergy and Clinical Immunology, Cardiothoracic Institute, London SW3 6HP  
O CROMWELL, PHD, lecturer

### Sustained ventricular fibrillation in deep accidental hypothermia

Cardiac arrhythmia is an important cause of death in deep accidental hypothermia (temperature <30°C) in otherwise healthy patients. Superficial or core rewarming is the most important treatment. I report a case in which the patient had continuous ventricular fibrillation for three hours 40 minutes and was rewarmed with simple and inexpensive equipment that is generally available in any hospital. To my knowledge this is the longest period of ventricular fibrillation in deep hypothermia in which resuscitation has been successful.

#### Case report

A 33-year-old previously healthy man had ingested 300 mg chlorprothixene hydrochloride and 6 mg flunitrazepam during an attack of acute depression. He had afterwards slept on an exposed hill and had been found unconscious 12 hours later. The air temperature had been approximately 4°C.

On admission to hospital his spontaneous respiration stopped, and an electrocardiogram recorded over two minutes showed asystole, which was converted to ventricular fibrillation after intravenous adrenaline. His pupils did not react to light, and there was general hyporeflexia. Rectal temperature was 24°C measured with a laboratory thermometer. Arterial blood pH and serum potassium, chloride, and sodium and blood glucose concentrations were normal. Packed cell volume was raised (55%).

External cardiac massage at a reduced rate and artificial ventilation were started. Arterial blood pH was kept alkaline at around 7.5-7.6 and serum potassium concentration monitored within normal limits. Sodium chloride 0.9% solution and plasma prewarmed to 37°C were given intravenously. The room temperature was kept at 30°C, and he was wrapped in layers of pre-warmed wool carpets. His temperature fell 1°C during the first 10 minutes of resuscitation but then rose steadily to 28°C after a further three hours 30 minutes.

Electrocardiography showed continuous ventricular fibrillation throughout this period. DC defibrillation was tried at 24°C, 26°C, and 27°C, together with lignocaine 100 mg intravenously at 26°C and 27°C, both with no effect. When his temperature reached 28°C he was electroconverted to nodal rhythm and external cardiac massage was stopped. At 30°C there was spontaneous sinus rhythm. At 31°C the blood pressure became measurable with a sphygmomanometer and arm cuff. Spontaneous respiration started after 16 hours of treatment with a ventilator. Two days later he was alert; at discharge he had some soreness over the sternum but no other physical abnormality.

#### Comment

The amount of drugs ingested by this patient was far below the level at which cardiac and respiratory complications would be expected, and his condition was probably caused by hypothermia. The cerebrum can withstand an increasingly longer period of cardiac arrest with