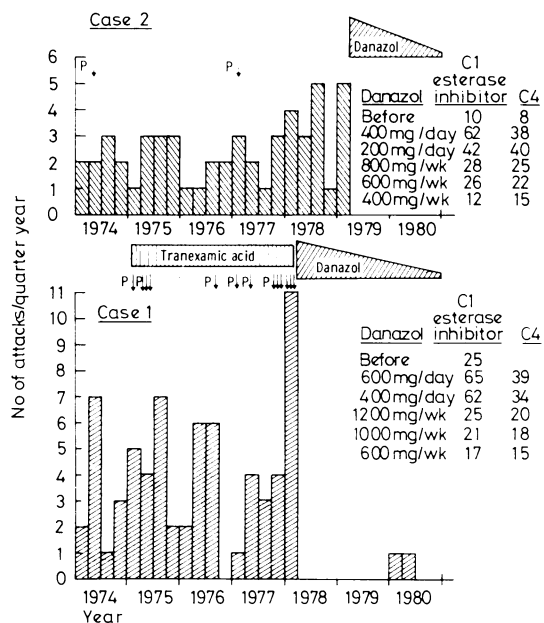


## Management of hereditary angio-oedema with low-dose danazol

Hereditary angio-oedema is an uncommon autosomal dominant disorder associated with low serum concentrations of C1 esterase inhibitor. It presents as recurrent swelling of the face, limbs, gut wall, or upper airway and is associated with considerable morbidity and mortality. Acute attacks affecting the airway are best treated with infusion of fresh-frozen plasma. Long-term prevention of attacks with antifibrinolytics or androgens has often been unsatisfactory owing to poor disease control or unacceptable side effects.<sup>1</sup> Danazol (dosage 600 mg/day), an androgen derivative, has recently been used successfully in preventing attacks while causing few side effects.<sup>2</sup> The dose needed and the method of monitoring treatment, however, have not been established. We present two cases showing one approach.



Effect of danazol on number of attacks of hereditary angio-oedema and concentrations of C1 esterase inhibitor (expressed as % of standard) and C4 (mg/100 ml) in cases 1 and 2. (P ↓ denotes hospital treatment with fresh-frozen plasma.)

### Case reports

**Case 1**—The patient, a 32-year-old man, had had recurrent attacks of hereditary angio-oedema since the age of 8. He had required numerous hospital admissions because of orolaryngeal swelling and abdominal pain. His father had died aged 42 of laryngeal obstruction after years of recurrent attacks of hereditary angio-oedema. From 1974, when he came under our care, he kept a daily symptom diary (figure). In January 1975 an emergency laparotomy for acute abdominal pain disclosed only free peritoneal fluid. Tranexamic acid for three years made little difference to his symptoms. Attacks were interfering increasingly with his job as a welder. Danazol (600 mg/day) was started in April 1978: his symptoms stopped immediately and concentrations of C1 esterase inhibitor rose. The dose was subsequently reduced slowly to 200 mg three times a week. Although the concentrations of C1 esterase inhibitor and C4 fell steadily, he had only two mild attacks (figure). He had no side effects except mild alopecia.

**Case 2**—This patient, a brother of the man reported on above, was a 30-year-old plate-metal worker who had had repeated attacks of hereditary angio-oedema since aged 16. The daily symptom diary that he had kept from 1974 showed that he had had up to five attacks a quarter until danazol was started in May 1979 (figure). The dose was reduced gradually to 300 mg/week with no attacks and no side effects. Concentrations of C1 esterase inhibitor and C4 rose dramatically when danazol was started and dropped progressively to pretreatment values as the dose was reduced (figure).

### Comment

Danazol was extremely effective in preventing attacks of hereditary angio-oedema in these cases. The protective effect was maintained even as the dose was reduced progressively from 600 mg/day towards

300 mg/week. Both patients were eventually able to do hard physical work, one on off-shore oil rigs.

The mode of action of danazol is not clear. Danazol increases concentrations of C1 esterase inhibitor and C4 within a few days of the start of treatment,<sup>2</sup> and the concentrations seem to be directly related to the dose used,<sup>3</sup> as shown in our cases. Complete disease control may be maintained, however, even as the concentrations fall back to pretreatment values as the dose is reduced.<sup>4</sup> This may be either because danazol exerts an effect independent of the concentration of C1 esterase inhibitor or because only small increases in this concentration are necessary to prevent activation of the complement cascade.

Although danazol appears to have few side effects,<sup>2,5</sup> nobody has taken it over a long period, as may be necessary for patients with hereditary angio-oedema. The minimum effective dose, which is probably less than 200 mg/day, should therefore be found for each patient. This may be arrived at by titrating it against the patient's symptoms rather than serum concentrations of C1 esterase inhibitor. Our cases show that symptom diaries are ideal for controlling the treatment of such a chronic disease.

Measurements of complement concentrations were performed by the department of immunology, Queen's Medical Centre, Nottingham.

Requests for reprints should be sent to DD.

<sup>1</sup> Frank MM, Gelfand JA, Atkinson JP. Hereditary angioedema; the clinical syndrome and its management. *Ann Intern Med* 1976;**84**:580-93.

<sup>2</sup> Gelfand JA, Sherins RJ, Alling DW, Frank MM. Treatment of hereditary angioedema with danazol. Reversal of clinical and biochemical abnormalities. *N Engl J Med* 1976;**295**:1444-8.

<sup>3</sup> Pitts JS, Donaldson VH, Forristal J, Wyatt RJ. Remissions induced in hereditary angioneurotic oedema with an attenuated androgen (danazol): correlation between concentrations of C1-inhibitor and the fourth and second components of complement. *J Lab Clin Med* 1978;**92**:501-7.

<sup>4</sup> Warin AP, Gatecliff M, Greaves MW, Warin RP, Williamson DM. The treatment of hereditary angio-oedema with low dose androgenic drugs. *Br J Dermatol* 1979;**101**, suppl:18-9.

<sup>5</sup> Atkinson JP. Diagnosis and management of hereditary angioedema. *Ann Allergy* 1979;**42**:348-52.

(Accepted 21 January 1981)

Department of Thoracic Medicine, City Hospital, Nottingham NG5 1PD

J T MACFARLANE, MA, MRCP, senior medical registrar  
D DAVIES, MD, FRCP, consultant physician

## Infantile acne associated with transient increases in plasma concentrations of luteinising hormone, follicle-stimulating hormone, and testosterone

I report a case of infantile acne associated with transient increases in concentrations of luteinising hormone, follicle-stimulating hormone, and testosterone and postulate that these abnormalities were due to delay in maturation of the hypothalamic "gonadostat."

### Case report

The boy (figure) was admitted aged 11 months with a four-week history of vomiting and a rash on the cheeks, present since the age of 6 weeks. Examination showed obvious recent weight loss and malar acne. Genitalia were normal, the testes size being 1-2 ml. The vomiting proved to be due to rumination.

A random plasma cortisol concentration was raised at 859 nmol/l (31.1 µg/100 ml), thought to be consistent with stress. Bone age, determined radiologically, was about 1 year. An echoencephalogram and renal-adrenal ultrasound examination were normal. A skull x-ray film showed possible slight enlargement of the pituitary fossa. Random concentrations of luteinising and follicle-stimulating hormones at 13 months were raised at 5.4 U/l and 17.1 U/l respectively (normal values at this age <2.5 U/l and <2 U/l respectively). His rumination settled and he thrived, but he was readmitted at 15 months in view of the abnormal findings. The acne persisted despite treatment, but examination was otherwise normal, although penis