

PAPERS AND SHORT REPORTS

Electrocardiographic signs of pulmonary hypertension in children who snore

A R WILKINSON, M S McCORMICK, A P FREELAND, D PICKERING

Abstract

Two children presented with sleep disturbance due to enlarged tonsils and adenoids. One child died during induction of anaesthesia, and postmortem examination showed hypertrophy of the right ventricle and atrium. As a result a prospective survey was carried out of children undergoing tonsillectomy or adenoidectomy, or both. During a nine-month period an electrocardiogram was taken in 92 children. Three electrocardiograms (3.3%) showed evidence of right heart strain. The children with abnormal electrocardiograms had symptoms of sleep disturbance with apnoea, snoring, and daytime somnolence. These symptoms and the electrocardiographic changes were reversed by adenotonsillectomy.

The prevalence of pulmonary hypertension in children with enlarged tonsils and adenoids is still underestimated. When signs and symptoms of sleep disturbance, particularly snoring, are present an electrocardiogram should be obtained and a cardiologist's opinion sought before embarking on routine surgery in view of the potentially fatal consequences.

Introduction

Cor pulmonale due to chronic upper airway obstruction was first described in children by Menashe *et al* in 1965.¹ Other reports have described a wide range of symptoms with which this syndrome may present: lethargy, enuresis, behaviour disturbance, and poor school performance are common.^{2,3} Disorders of sleep leading to daytime somnolence commonly occur, but snoring is often overlooked as a serious sign.⁴

Departments of Otolaryngology and Paediatrics, Radcliffe Infirmary and John Radcliffe Hospital, Oxford OX3 9DU

A R WILKINSON, MB, MRCP, lecturer in paediatrics
M S McCORMICK, MB, FRCS, registrar in otolaryngology
A P FREELAND, MB, FRCS, consultant otolaryngologist
D PICKERING, MB, FRCP(ED), consultant paediatrician

We describe two children who presented with nasal obstruction, otitis media, and snoring, one of whom died during induction of anaesthesia. After seeing these children we obtained a prospective series of electrocardiograms in children awaiting adenoidectomy and tonsillectomy to determine the incidence of electrocardiographic signs of pulmonary hypertension.

Case reports

CASE 1

A 3-year-old girl was referred to an otolaryngologist because of nasal obstruction, snoring, and general ill health. Physical examination showed large tonsils and adenoids and serous otitis media. Her height and weight were below the third centile for her age. She was admitted for adenoidectomy and aspiration of the middle ear with insertion of grommets but was found to be anaemic (haemoglobin 7.9 g/100 ml, serum iron 2.5 μ mol/l (14 μ g/100 ml)) and the operation was postponed.

While she was in hospital the nursing and medical staff noticed that she had noisy breathing and disturbed sleep. Episodes of apnoea were terminated with loud snoring after which she woke. This pattern was repeated throughout the night. A chest radiograph showed an enlarged heart (cardiothoracic ratio — 0.63). Electrocardiography showed right-axis deviation, right atrial hypertrophy, and right ventricular hypertrophy (fig 1). The iron-deficiency anaemia was corrected and a




FIG 1—Case 1. Electrocardiogram.

chest infection treated. After three weeks her condition had apparently improved sufficiently for her to proceed to operation. Shortly after induction of anaesthesia she had a cardiac arrest and resuscitation was unsuccessful. Postmortem examination showed gross hypertrophy and dilatation of the right ventricle and atrium. Section of the lung showed

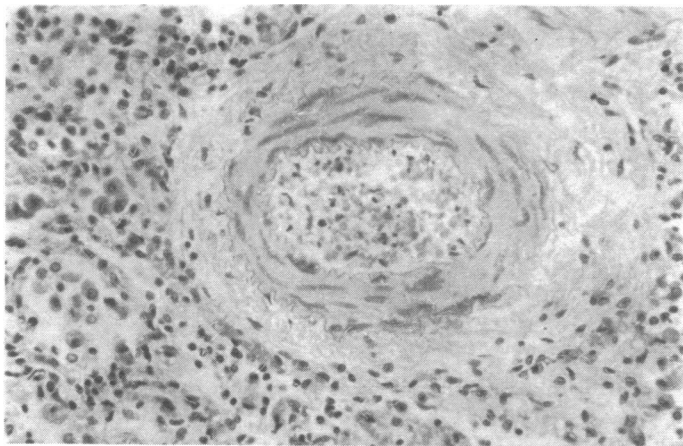


FIG 2—Case 1. Photomicrograph of lung tissue $\times 160$ (original magnification).

medical hypertrophy in the small pulmonary arteries (fig 2). There was no other disease of the heart or lungs to explain the pulmonary hypertension.

CASE 2

A 2½-year-old boy was examined because of persistent nasal obstruction and snoring while asleep. He was small (10th centile) with serous otitis media and large adenoids. His tonsils were also large but healthy. The middle-ear effusion was aspirated and grommets inserted, and adenoidectomy was performed simultaneously. Postoperatively it was noticed that his snoring occurred at the end of prolonged periods of apnoea during sleep. Prolonged periods of upper airway obstruction were relieved only by a large increase in respiratory effort, and restoration of the airway was marked by a loud snore. A cardiologist's advice was sought regarding further investigation. An electrocardiogram showed right-axis deviation, right atrial hypertrophy, and right ventricular hypertrophy. Cardiac catheterisation was performed; pulmonary artery pressure was 45 mm Hg, and other causes of pulmonary hypertension were excluded. At this time he was sleeping for about 18 hours a day. The large tonsils were removed without any complications, and this resulted in a pronounced improvement in his sleeping pattern and general health. Five weeks later electrocardiography showed that the right atrium and right ventricle had returned to normal (P wave in lead II 3.5 to 1.5 mm and S wave in V6 12 mm to 4 mm).

Prospective electrocardiographic survey

METHODS

The two cases reported above suggested that some children with considerable pulmonary hypertension due to upper airway obstruction may present not with acute respiratory failure⁵ or heart failure⁶ but with failure to thrive and chronic nasal obstruction leading to snoring and apnoea at night. We therefore carried out a prospective study of children who were to undergo adenoidectomy or tonsillectomy, or both. In nine months 92 children aged between 1 and 13 years underwent 12-lead electrocardiography before their operation. All electrocardiograms were reviewed by a paediatric cardiologist (DP).

RESULTS

Three of the 92 electrocardiograms were abnormal and showed signs of right-axis deviation, right ventricular hypertrophy, or right atrial hypertrophy. In each case these changes reverted to within normal limits after adenoidectomy, performed with tonsillectomy in two cases. The three cases are described below.

Case 3—A 6-year-old asthmatic boy was assessed because of serious

otitis media, persistent nasal obstruction, and a history of daytime drowsiness. After failure of conservative treatment myringotomy, grommet insertion, and adenoidectomy were performed. His tonsils, though large, had not caused any symptoms, but the electrocardiogram showed right atrial and ventricular hypertrophy and so they were removed. Figure 3 shows preoperative and postoperative electrocardiograms. The P waves in lead II diminished from 3 to 2 mm and the S wave in lead V6 from 6 to 2 mm. His mother reported that his general alertness and health improved greatly after relief of the upper airway obstruction.

Fig 3 case 3

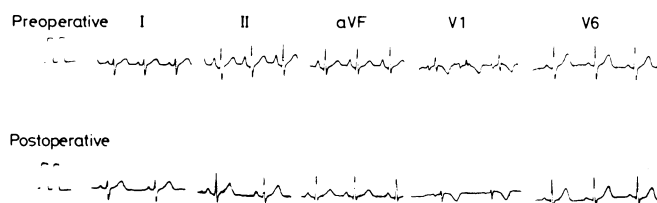


Fig 4 case 4

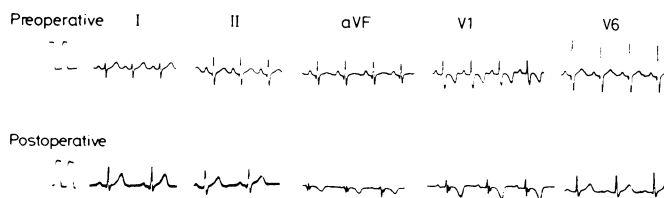

FIG 3—Case 3. Preoperative and postoperative electrocardiograms.

FIG 4—Case 4. Preoperative and postoperative electrocardiograms.

Case 4—A 3-year-old boy had persistent episodes of nasal obstruction with mucopurulent rhinorrhoea but no associated ear or throat symptoms. His father, a local general practitioner, described exactly what happened to his son during sleep. Periods of apnoea lasting for more than 10 and occasionally as long as 30 seconds were followed by increased respiratory effort during which loud snoring occurred and after which the patency of his airway was apparently restored. Figure 4 shows preoperative and postoperative electrocardiograms. Right-axis deviation reverted to normal and the S waves in V6 changed from 5 to 1.5 mm. His parents reported an appreciable improvement in his general health and normal quiet breathing during sleep after his operation.

Case 5—A 7-year-old asthmatic boy with persistent serous otitis media and snoring was admitted for myringotomy, grommet insertion, and adenoidectomy. His preoperative electrocardiogram showed early right ventricular hypertrophy with an upright T wave in lead VI. This abnormality was reversed after surgery.

Results of additional investigations—A polygraphic study during sleep was carried out in case 3. An electrocardiogram, electroencephalogram, chin-muscle electromyogram, and breathing were recorded simultaneously. Air movement at the nose was detected by analysis of respired carbon dioxide using a mass spectrometer (BOC MS2). Chest and abdominal movement was recorded with two magnetometer coils placed laterally just below the costal margin. Oxygen tension was measured by a transcutaneous electrode. He was observed throughout the night. Sleep was characterised by periods of quiet sleep lasting only 10-15 minutes punctuated by episodes of airway obstruction during which increasing effort occurred without nasal air flow. Each episode was terminated by loud snoring and arousal, often followed by waking. The airway was then re-established and regular breathing occurred until the beginning of the next episode. Oxygen tension decreased from a normal value of 70-80 mm Hg to about 30 mm Hg during the disturbed breathing. No cardiac arrhythmia was detected and he did not have any periods of rapid-eye-movement sleep during the study, which lasted 10 hours. Soft-tissue cinefluoroscopy was performed in case 4 to assess the movement of the soft palate in relation to the adenoids, the tonsils, and the pharynx as a whole. The adenoidal pad obstructed the postnasal space, but there was normal soft-palate movement and no evidence of pharyngeal collapse on inspiration.

Discussion

Chronic alveolar hypoventilation due to upper airway obstruction has been documented in many adults since the first report by Burwell *et al* in 1956.⁷ The prevalence of a similar syndrome in children due to hypertrophy of the tonsils and adenoids is probably greatly underestimated if only the extreme forms with congestive failure are considered. The most severe form of this syndrome was first described in 1965.^{1, 2} Abnormally high carbon dioxide tension and pulmonary hypertension has been found in children with this severe form, with relief of symptoms and a return to more normal haemodynamics after the tonsils and adenoids have been removed.^{5, 6, 8} The range of symptoms in less severe cases, however, is not well documented, and not all children with huge tonsils develop signs of respiratory obstruction. Macartney *et al*⁸ suggested that in some children there may be an increased reactivity of the pulmonary vasculature to hypoxia such as that shown in 20% of normal people at altitude and in some children with small ventricular septal defects.⁹

In children with less severe forms of this syndrome the risk of exacerbating hypoventilation by inducing anaesthesia was predicted by Macartney *et al*,⁸ and Ainger reported two deaths.⁵

The results of this study suggest that over 3% of children with chronic otitis media and inflamed adenoids or tonsils may have electrocardiographic signs of early pulmonary hypertension. Specific questioning about sleep pattern should be part of the assessment of any child before the tonsils and adenoids are removed. If there is a history of disturbed sleep, snoring, or daytime drowsiness electrocardiography is indicated; if signs of right heart strain are found particular attention should be paid

to the induction of anaesthesia and close monitoring during surgery will be necessary to prevent an otherwise unexpected death.

This study was supported in part by grants from the Peel Medical Research Trust, the Foundation for the Study of Infant Deaths, and Action Research.

References

- 1 Menashe VD, Farrehi C, Miller M. Hypoventilation and cor pulmonale due to chronic upper airway obstruction. *J Pediatr* 1965;**67**:198-203.
- 2 Noonan JA. Reversible cor pulmonale due to hypertrophied tonsils and adenoids: studies in two cases. *Circulation* 1965;**32**,suppl 2:164.
- 3 Luke MJ, Mehrizi A, Falger GM, Rowe RD. Chronic nasopharyngeal obstruction as a cause of cardiomegaly, cor pulmonale, and pulmonary edema. *Pediatrics* 1966;**37**:762-8.
- 4 Simmons FB, Guilleminault C, Dement WC, Tilkian AG, Hill M. Surgical management of airway obstructions during sleep. *Laryngoscope* 1977;**87**:326-38.
- 5 Ainger LE. Large tonsils and adenoids in small children with cor pulmonale. *Br Heart J* 1968;**30**:356-62.
- 6 Levy AM, Tabakin BS, Hanson JS, Narkewicz RM. Hypertrophied adenoids causing pulmonary hypertension and severe congestive heart failure. *N Engl J Med* 1967;**277**:506-11.
- 7 Burwell CS, Robin ED, Whaley RD, Bickelmann AG. Extreme obesity associated with alveolar hypoventilation—a Pickwickian syndrome. *Am J Med* 1956;**21**:811-8.
- 8 Macartney FJ, Panday J, Scott O. Cor pulmonale as a result of chronic nasopharyngeal obstruction due to hypertrophied tonsils and adenoids. *Arch Dis Child* 1969;**44**:585-92.
- 9 Grover RF, Vogel JHK, Averill KH, Blount SG. Pulmonary hypertension: individual and species variability relative to vascular reactivity. *Am Heart J* 1963;**66**:1-3.

(Accepted 7 April 1981)

THE BAY TREE. This is so well known that it needs no description: I shall therefore only write the virtues thereof, which are many.

I shall but only add a word or two to what my friend has written, *viz*, that it is a tree of the sun, and under the celestial sign Leo, and resists witchcraft very potently, as also all the evils old Saturn can do to the body of man, and they are not a few; for it is the speech of one, and I am mistaken if it were not Mizaldus, that neither witch nor devil, thunder nor lightning, will hurt a man in the place where a Bay-tree is. Galen said, that the leaves or bark do dry and heal very much, and the berries more than the leaves; the bark of the root is less sharp and hot, but more bitter, and hath some astringency withal whereby it is effectual to break the stone, and good to open obstructions of the liver, spleen, and other inward parts, which bring the jaundice, dropsy, etc. The berries are very effectual against all poison of venomous creatures, and the sting of wasps and bees; as also against the pestilence, or other infectious diseases, and therefore put into sundry treacles for that purpose; they likewise procure women's courses, and seven of them given to woman in sore travail of child-birth, do cause a speedy delivery, and expel the after-birth, and therefore not to be taken by such as have not gone out their time, lest they procure abortion, or cause labour too soon. They wonderfully help all cold and rheumatic distillations from the brain to the eyes, lungs or other parts; and being made into an electuary with honey, do help the consumption, old coughs, shortness of breath, and thin rheums; as also the megrim. They mightily expel the wind, and provoke urine; helps the mother, and kill the worms. The leaves also work the like effect. A bath of the decoction of leaves and berries, is singularly good for women to sit in, that are troubled with the mother, or the diseases thereof, or the stoppings of their courses, or for the diseases of the bladder, pains in the bowels by wind and stoppage of the urine. A decoction likewise of equal parts of Bay-berries, cummin seed, hyssop, origanum, and euphorbium, with some honey, and the head bathed therewith, wonderfully helps distillations and rheums, and settles the palate of the mouth into its place. The oil made of the berries is very comfortable in all cold griefs of the joints, nerves, arteries, stomach, belly, or womb, and helps palsies, convulsions, cramp, aches, tremblings, and numbness in any part, weariness also, and pains that come by sore travelling. All griefs and pains proceeding from wind, either in the head, stomach, back, belly, or womb, by

anointing the parts affected therewith: And pains in the ears are also cured by dropping in some of the oil, or by receiving into the ears the fume of the decoction of the berries through a funnel. The oil takes away the marks of the skin and flesh by bruises, falls, etc. and dissolves the congealed blood in them. It helps also the itch, scabs, and weals in the skin. (Nicholas Culpeper (1616-54) *The Complete Herbal*, 1850.)

ALKANET. Besides the common name, it is called Orchanet, and Spanish Bugloss, and by apothecaries, Enchusa.

Of the many sorts of this herb, there is but one known to grow commonly in this nation; of which one take this description: It hath a great and thick root, of a reddish colour, long, narrow, hairy leaves, green like the leaves of Bugloss, which lie very thick upon the ground; the stalks rise up compassed round about, thick with leaves, which are less and narrower than the former; they are tender, and slender, the flowers are hollow, small, and of a reddish colour. It grows in Kent near Rochester, and in many places in the West Country, both in Devonshire and Cornwall. They flower in July and the beginning of August, and the seed is ripe soon after, but the root is in its prime, as carrots and parsnips are, before the herb runs up to stalk.

It is an herb under the dominion of Venus, and indeed one of her darlings, though somewhat hard to come by. It helps old ulcers, hot inflammations, burnings by common fire, and St. Anthony's fire, by antipathy to Mars; for these uses, your best way is to make it into an ointment; also, if you make a vinegar of it, as you make vinegar of roses, it helps the morpew and leprosy; if you apply the herb to the privities, it draws forth the dead child. It helps the yellow jaundice, spleen, and gravel in the kidneys. Dioscorides saith it helps such as are bitten by a venomous beast, whether it be taken inwardly, or applied to the wound; nay, he saith further, if any one that hath newly eaten it, do but spit into the mouth of a serpent, the serpent instantly dies. It stays the flux of the belly, kills worms, helps the fits of the mother. Its decoction made in wine, and drank, strengthens the back, and eases the pains thereof: It helps bruises and falls and is as gallant a remedy to drive out the small pox and measles as any is; an ointment made of it, is excellent for green wounds, pricks or thrusts. (Nicholas Culpeper (1616-54) *The Complete Herbal*, 1850.)